

Clinical Article

Endoscopic Management of Cranial Arachnoid Cysts Using Extra-Channel Method

Myung-Hyun Kim, M.D., Ph.D.,¹ Hae-Dong Jho, M.D., Ph.D.²

Department of Neurosurgery,¹ Ewha Womans University School of Medicine, Seoul, Korea

Department of Neurological Surgery,² Allegheny General Hospital School of Medicine, Pittsburgh, Pennsylvania, USA

Objective : Arachnoid cysts (ACs) can be cured by making the definite and wide communication between the cyst and arachnoid space using endoscopy, but often it is impossible only through the usual working-channel (intra-channel) procedures. We discuss and propose a more valuable endoscopic technique with the presentation of our series of cases.

Methods : We treated 9 patients with cortical AC in various locations with extra-channel endoscopic techniques. The patients ranged in age from 3 years to 60 years (mean age, 37.2 yrs). The follow-up period ranged from 12 to 26 months (mean follow-up duration, 17.2 months). All patients had large AC compressing the adjacent brain with clinical symptoms or signs. The authors performed extensive fenestration via single burr hole with the aid of endoscope. Being bypassed the rigid endoscope, through the space between the shaft of endoscope and guiding cannula (extra-channel method), fenestration procedures were done in the dry fields.

Results : Eight (88.9%) patients had been treated successfully with endoscope. One patient required shunt procedure. Among the eight patients who were treated with endoscopic procedure, 6 patients (66.7%) showed cyst reduction, and two (22.2%) showed disappearance of cyst.

Conclusion : We suggest that extra-channel method will be simple and easy to perform using more valuable instruments with wider working area, and may promise better results compared to the conventional intra-channel endoscopic procedures.

KEY WORDS : Cranial arachnoid cyst · Endoscopic procedure · Fenestration.

INTRODUCTION

Arachnoid cysts (ACs) are intra-arachnoid collections of cerebrospinal fluid (CSF)⁸, and are regarded as a developmental abnormality of the arachnoid, originating from a splitting or duplication of this membrane¹⁹. Surgical treatment is necessary for patients with raised intracranial pressure and corresponding clinical symptoms. Many operative procedures for the control of ACs have been recommended, however it remains controversial as to which is the best method. Recently, endoscopic procedures have been recommended as the first surgical option for cerebral AC^{1,5,6,12,13,18}. Several kinds of endoscopic procedures have been reported according to the location of lesion^{12,13}. We describe our

technique and it is compared with the others.

MATERIALS AND METHODS

Clinical materials

Details of each case are given in Table 1. Five cysts were located in the posterior cranial fossa, three in the middle cranial fossa, and one in parietal region. All patients showed clinical manifestations of increased intracranial pressure requiring prompt surgical intervention and corresponding radiological findings. We operated on all patients with extra-channel endoscopic method.

Surgical technique (extra-channel endoscopic method)

All procedures were performed under general endotracheal anesthesia. The field of operation was prepared and draped to allow immediate open microsurgical intervention in cases of complications. We used a rigid endoscope (Karl Storz, Germany) with or without frameless stereotaxy (Ste-

• Received : April 14, 2010 • Revised : May 6, 2010

• Accepted : May 23, 2010

• Address for reprints : Myung-Hyun Kim, M.D., Ph.D.
Department of Neurosurgery, Ewha Womans University School of Medicine, 911-1 Mok-dong, Yangcheon-gu, Seoul 158-710, Korea
Tel : +82-2-2650-5088, Fax : +82-2-2650-5088
E-mail : kimmh@ewha.ac.kr

Table 1. Clinical characteristics of 9 patients with cerebral arachnoid cysts

Case	Sex/Age	Clinical findings	Location	Procedure	Follow up	Outcome	Image change
1	M/3	Headache, vomiting	Middle fossa	Cysto-cisternostomy	18 Mo	No Cx	Cyst disappeared
2	M/25	Headache, vomiting	Middle fossa	Cysto-cisternostomy	12 Mo	no Cx	Cyst reduction
3	F/26	Rt UE weakness	Middle fossa	Cysto-cisternostomy	26 Mo	No Cx	Cyst reduction
4	F/29	Vomiting, Balancing disorder	Posterior fossa	Cysto-cisternostomy Shunt	19 Mo	shunt	Cyst reduction
5	F/42	Nausea, dizziness	Posterior fossa	Cysto-cisternostomy	12 Mo	No Cx	Cyst reduction
6	M/45	Vomiting, vertigo	Posterior fossa	Cysto-cisternostomy	22 Mo	No Cx	Cyst reduction
7	M/45	Headache	Posterior fossa	Cysto-cisternostomy	16 Mo	No Cx	Cyst reduction
8	M/60	Headache, cerebellar sign	Posterior fossa	Cysto-cisternostomy	16 Mo	No Cx	Cyst disappeared
9	F/60	Seizure, generalized	Parietal	Cysto-ventriculostomy	14 Mo	No Cx	Cyst reduction

Cx : complication, F : female, M : male, Mo : month, Rt : right, UE : upper extremity

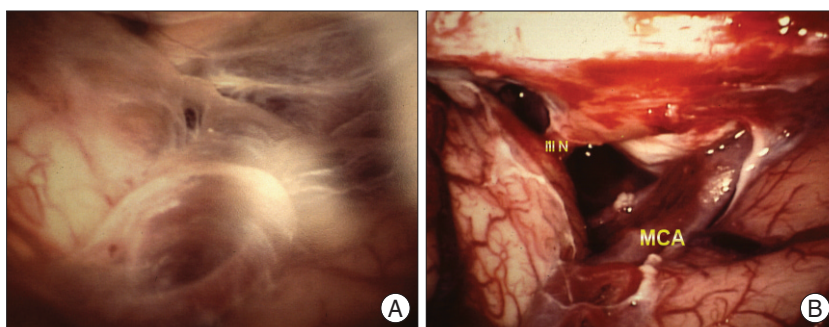


Fig. 1. Operative findings in case 3. A : Arachnoid cyst located in the sylvian region showing a third cranial nerve (III) through its semi-transparent membrane and a tiny hole on the outer surface of cyst. B : After extensive fenestration, a third nerve and vascular structures were exposed. MCA : middle cerebral artery, III N: oculomotor nerve.

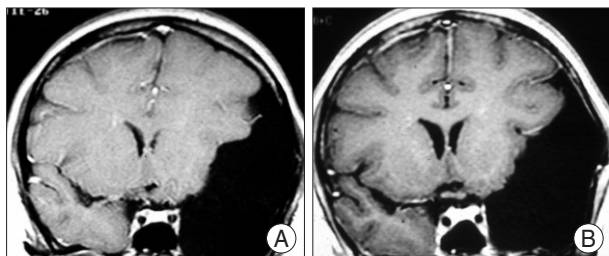


Fig. 2. Radiologic findings in case 3. A : Coronal T1-weighted magnetic resonance image revealing an arachnoid cyst in the middle cranial fossa with compression of lateral ventricle and midline shifting. B : Coronal T1-weighted magnetic resonance image obtained 18 months after surgery, demonstrating cyst reduction.

alth, USA).

A burr hole was made according to the best trajectory guided by frameless stereotaxy. After dural opening, the outer membrane was coagulated and incised. The endoscopy with self-cleansing system equipped sheath (Buxter, USA) was inserted freehand into the cyst to explore. After orientation, endoscope was fixed by modified Greenberg retractor. The fluid content in the cyst was sucked out and fenestration procedure was started. The whole procedures was performed through the relatively the wide space between the shaft of endoscope and margin of burr hole. Through this space, we could use various endoscopic instru-

ments, monopolar Bovie-sucker (Valleylab, USA), dissectors, forceps and scissors (Fig. 1A, B, 3B), including even the microscopic instruments. Usually, cysto-cisternostomy was performed by creating one or more wide openings to the cyst. Closure was done as usual manner.

Unlike conventional intra-channel endoscopic method (Fig. 3A), we could use almost every kind of endoscopic instruments and several kinds of microscopic instruments during extra-channel method (Fig. 3B). Furthermore, every procedure was done in dry fields, which gave us more clear operative fields, convenient hemostasis.

RESULTS

The follow-up periods were ranged from 12 to 26 (mean 17.2) months. Symptoms were relieved in all patients, but one patient required shunt. There was no mortality and morbidity as a result of this procedure. The follow-up magnetic resonance images or computed tomography scans revealed a decrease in the size of the cysts (Fig. 2). The operation time was from 1 hour to 2 hours and the hospital stay was only 1 day.

DISCUSSION

Arachnoid cysts most probably arise by way of anomalous splitting and duplication of the endomeninx⁴⁾ and the concept of a ball-valve mechanism in the expansion of AC has attained broad agreement^{11,14)}. Becker et al.²⁾ found a positive correlation of relative AC volume to age in large arachnoid cysts and argued in favor of the existence of a subgroup of expansile lesions. A subgroup of large AC appears to expand

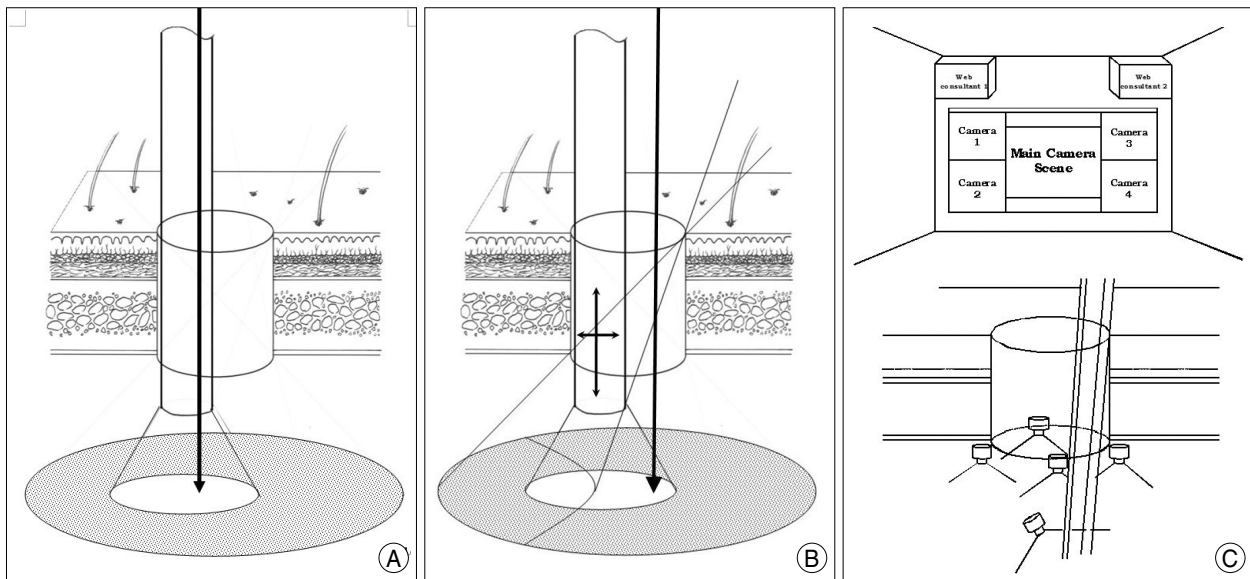


Fig. 3. Schematic drawing of our endoscopic extra-channel procedures. A : Intra-channel method. We can work only through the narrow instrument channel (long, ended arrow) of endoscope, so working area will be small (white round area), and instrument will be limited. B : Extra-channel method. We could handle the larger instruments more easily through the wide space beside the endoscope (long, ended arrow) instead of long, narrow instrument channels. But, the effective working area will be eroded by endoscope itself. This 'hidden area' will not hinder the operation itself, but may block the prompt approach to the certain area of endoscopic field. It can be overcome by replacement of endoscope (small arrows). C : In the future, the clinical application of micro-video camera can rescue us from these troubles we were in.

with time, while the majority of small AC remains unchanged.

Controversy exists concerning the treatment of ACs. There is no doubt that surgical treatment is necessary for patients with raised intracranial pressure and corresponding clinical symptoms, even if the communicating type, and those complicated by intra-cystic or subdural hemorrhage. ACs combined with subdural hematoma or fluid collection should be followed-up²⁴⁾ and if communication is inadequate, they should be considered as a surgical candidate. Conservative management can be considered for those patients complaining of mild symptoms or presenting cranial deformity alone. Diagnostic evaluation should include, after the initial identification of intracranial ACs, the detection of mass effect, determination of the type of communication between cyst and subarachnoid space, and recognition of the presence, location and severity of obstructive hydrocephalus and cisternal block¹⁰⁾.

ACs have been treated by cyst fenestration/resection^{13,16)} or by cystoperitoneal shunting^{5,8)}, however, controversy continues regarding which surgical treatment is best. Furthermore, both procedures have some limitations to be the first line of treatment for AC^{3,5,7,9-11,15,16,18,22,23)}. Endoscopic techniques can replace open surgery or shunting procedures with similar or even better results. Many authors have been regarded endoscopic fenestration as the first option of treatment^{1,5,6,8,12,18,20,21)}.

To treat AC, fenestrations need to be definite and large

enough to communicate the cyst and intact cisternal spaces freely without re-closure. Usual endoscopic technique (intra-channel) is making one or more fenestrations using various endoscopic instruments through the limited instrumental channels of endoscopy^{1,5,6,8,13,18,20,21)}. This may be successful, but often there can be difficulties to control bleeding and manipulate the cyst wall because the instruments should be handled only via long, narrow channels. The continuous movement of the endoscope to control the trajectory of instruments may cause troublesome bleeding and disorientation. Moreover, surgery in the wet field will cause more light reflection and air-fluid level what make us difficult to see underlying structures through the cyst wall, and we cannot see any more even by the presence of minor bleeding (Fig. 3A). But in the dry field, the structures opposite to the cyst can be seen more clearly, which are crucial for the fenestration procedures under the similar situations. The larger instruments can be handled more easily, through the wider space between the endoscope and guiding cannula, instead of long, narrow instrument channels (Fig. 3B). Also, we can dissect the cyst wall from the underlying structures like usual microscopic surgery. In this point, our technique is similar to the 'endoscope-guided microneurosurgery', proposed by Hopf and Perczky¹²⁾. Whereas we perform all our endoscopic procedures through the single burr hole without microscope in their procedure, they need a small craniotomy and use the endoscope as an assistance of microscope, 'looking around the corner'.

Still there are some limitations in our procedure. First, as shown at Fig. 3B, the effective working area will be eroded by endoscope itself. This 'hidden area' will not hinder the operation itself, but may block the prompt approach to the certain area of endoscopic field. It can be overcome by replacement of endoscope. Secondly, the limited illumination and view angle of endoscope can make 'blind spots' in the corner of operation fields, especially in the lesion with complex, large cavity. Finally, the surgeons cannot look behind along the shaft of endoscope. This may cause unexpected harmful events during endoscopic procedures. The imaging technology will be advanced day after day¹⁷⁾. We hope that in the future, the clinical application of micro-video camera can rescue us from these troubles (Fig. 3C).

Although the follow-up period is too short to make statements on long-term outcome, the authors recommend extra-channel endoscopic approach for treatment of arachnoid cysts. Should the endoscopic procedure be failed, established treatment options can subsequently be performed without additional risk.

CONCLUSION

We conclude that extra-channel method will be simple and easy to perform with using more valuable instruments. It can give us wider working area, and promise better results to the conventional intra-channel endoscopic procedures.

References

1. Auer LM, Holzer P, Ascher PW, Heppner F : Endoscopic neurosurgery. *Acta Neurochir (wien)* 90 : 1-14, 1988
2. Becker T, Wagner M, Hofmann E, Warmuth-Metz M, Nadjmi M : Do arachnoid cysts grow? : A retrospective CT volumetric study. *Neuroradiology* 33 : 341-345, 1991
3. Bhandary JS : Non-communicating supratentorial subarachnoid cysts. *J Neurol Neurosurg Psychiatry* 35 : 763-770, 1972
4. Brackett CE, Rengachary SS : Arachnoid cysts in Youmans (ed) *Neurological surgery*, ed 2. Philadelphia: Saunders, 1982, pp1436-1446
5. Caemaert J, Abdullah J, Calliauw L, Carton D, Dhooge C, van Coster R : Endoscopic treatment of suprasellar arachnoid cysts. *Acta Neurochir (Wein)* 119 : 68-73, 1992
6. Choi JU, Kim DS, Huh R : Endoscopic approach to arachnoid cyst. *Childs Nerv Syst* 15 : 285-291, 1999
7. Choux M, Raybaud C, Pinsard N, Hassoun J, Gambarelli D : Intracranial supratentorial cysts in children excluding tumor and parasitic cysts. *Child's Brain* 4 : 15-32, 1978
8. Ciricillo SF, Cogen PH, Harsh GR, Edwards MS : Intracranial arachnoid cyst in children. A comparison of the effects of fenestration and shunting. *J Neurosurg* 74 : 230-235, 1991
9. Galassi E, Piazza G, Gaist G, Frank F : Arachnoid cysts of the middle cranial fossa : a clinical and radiological study of 25 cases treated surgically. *Surg Neurol* 14 : 211-219, 1980
10. Gentry LR, Menezes AH, Turski PA, Smoker WR, Cornell SH, Ramirez L : Suprasellar arachnoid cysts : 2. Evaluation of CSF dynamics. *AJNR Am J Neuroradiol* 7 : 87-96, 1986
11. Hoffman HJ, Hendrick EB, Humphreys RP, Armstrong EA : Investigation and management of suprasellar arachnoid cysts. *J Neurosurg* 57 : 597-602, 1982
12. Hopf NJ, Perczek A : Endoscopic neurosurgery and endoscope-assisted microneurosurgery for the treatment of intracranial cysts. *Neurosurgery* 43 : 1330-1336; discussion 1336-1337, 1998
13. Kim MH : The role of endoscopic fenestration procedures for cerebral arachnoid cysts. *J Korean Med Sci* 14 : 443-447, 1999
14. Kumagai M, Sakai N, Yamada H, Shinoda J, Nakashima T, Iwama T, et al. : Postnatal development and enlargement of primary middle cranial fossa arachnoid cyst recognized on repeat CT scans. *Childs Nerv Syst* 2 : 211-215, 1986
15. Lange M, Oeckler R : Results of surgical treatment in patients with arachnoid cysts. *Acta Neurochir (Wein)* 87 : 99-104, 1987
16. Oberbauer RW, Haase J, Pucher R : Arachnoid cysts in children : a European co-operative study. *Childs Nerv Syst* 8 : 281-286, 1992
17. Oka K : Introduction of the videoscope in neurosurgery. *Neurosurgery* 62 : ONS337-ONS340; discussion ONS341, 2008
18. Pierre-Kahn A, Capelle L, Brauner R, Sainte-Rose C, Renier D, Rappaport R, et al. : Presentation and management of suprasellar arachnoid cysts. Review of 20 cases. *J Neurosurg* 73 : 355-359, 1990
19. Santamarta D, Aguas J, Ferrer E : The natural history of arachnoid cysts: endoscopic and cine-mode MRI evidence of a slit-valve mechanism. *Minim Invasive Neurosurg* 38 : 133-137, 1995
20. Schroeder HW, Gaab MR, Niendorf WR : Neuroendoscopic approach to arachnoid cysts. *J Neurosurg* 85 : 293-298, 1996
21. Spacca B, Kandasamy J, Mallucci CL, Genitori L : Endoscopic treatment of middle fossa arachnoid cyst : a series of 40 patients treated endoscopically in two centres. *Childs Nerv Syst* 24 : 2009 [Epub ahead of print]
22. Sprung C, Mauersberger W : Value of computed tomography for the diagnosis of arachnoid cysts and assessment of surgical treatment. *Acta Neurochir Suppl (Wein)* 28 : 619-626, 1979
23. Stein SC : Intracranial developmental cysts in children : treatment by cystoperitoneal shunting. *Neurosurgery* 8 : 647-650, 1981
24. Yamanouchi Y, Someda K, Oka N : Spontaneous disappearance of middle fossa arachnoid cyst after head injury. *Childs Nerv Syst* 2 : 40-43, 1986