

# Microimplant mandibular advancement (MiMA) therapy for the treatment of snoring and obstructive sleep apnea (OSA)

Joachim Ngiam, BDS,<sup>a</sup> Hee-Moon Kyung, DDS, MSD, PhD<sup>b</sup>

This case report describes the treatment of a 66 year old adult patient with a diagnosis of severe obstructive sleep apnea who was intolerant of nasal continuous positive airway pressure (nCPAP) treatment and oral appliance therapy. An alternative treatment of snoring and obstructive sleep apnea (OSA) with 2 orthodontic microimplants anchored to the mandible providing skeletal anchorage for mandibular advancement was implemented. After a 2 week healing period, a custom designed facemask provided extraoral anchorage to which the microimplants were connected to for titratable mandibular advancement. Microimplant Mandibular Advancement (MiMA) therapy resulted in resolution of the symptoms of severe OSA with a reduction of the apnea-hypopnea index (AHI), snoring and OSA symptoms. (**Korean J Orthod** 2010;40(2):115-126)

**Key words:** Severe obstructive sleep apnea, Microimplant, Mandibular advancement

## INTRODUCTION

Sleep disordered breathing (SDB) describes a spectrum of abnormal breathing during sleep ranging for primary snoring, hypopneas (partial obstruction) to periods of obstructive sleep apnea (OSA) where there is a complete cessation of breathing. This condition is characterized by repetitive periods or partial or complete airway obstruction during sleep resulting in oxygen desaturation, sleep fragmentation and frequent arousals. This common sleep disorder affects 4% of men and 2% of women in the western population. In the Korean population, its prevalence was noted to be

4.5% in men and 3.2% in women<sup>1</sup> with the presence of excessive daytime sleepiness affecting 12.2% of the population.<sup>2</sup> OSA has been implicated in cardiac disease, hypertension, mortality, stroke and sudden death. More recently, snoring has been associated with an increased risk in carotid atherosclerosis<sup>3</sup> and periodontal disease.

Continuous positive airway pressure (CPAP) therapy, first introduced by Sullivan et al. in 1981<sup>4</sup> remains the gold standard treatment of choice. Although highly effective, its cumbersome nature, noise, cost and poor patient compliance due to side effects are well documented in the literature.

In the last two decades, a multitude of oral appliances to treat mild/moderate conditions of SDB have reported varying success. Oral appliances are thought to act primary by mechanically advancing the mandible and tongue so as to increase the pharyngeal lumen size.<sup>5</sup> They have potential advantages over nasal CPAP as they are less obtrusive, quieter, less costly and portable. Recently, some studies have advocated the use of oral appliances for the treatment of severe OSA pa-

<sup>a</sup>Orthodontic Postgraduate, <sup>b</sup>Chairman and Professor, Department of Orthodontics, School of Dentistry, Kyungpook National University.

Corresponding author: Hee-Moon Kyung.

Department of Orthodontics, School of Dentistry, Kyungpook National University, 188-1, Samduk 2-ga, Jung-gu, Daegu 700-412, Korea.

+82 53 600 7372; e-mail, hmkjung@knu.ac.kr.

Received November 27, 2009; Last Revision February 15, 2010;

Accepted February 18, 2010.

DOI:10.4041/kjod.2010.40.2.115

tients that are intolerant of CPAP therapy.<sup>6</sup> Despite the reported successes in case reports and randomly controlled studies, most authors have emphasized the need for long term monitoring under the supervision of a multi-disciplinary team.

Side effects due to oral appliance therapy are well documented in the literature. The majority of studies indicate that side effects are transient ranging from excessive salivation, xerostomia, tooth movement, overbite/overjet changes and TMJ pain. Some studies however depict irreversible changes in jaw relationship and occlusal contacts.<sup>7,8</sup> Occlusal changes occur as a result of reciprocal forces transmitted to the teeth and surrounding soft tissues.

Recently, the introduction of orthodontic microimplants as an adjunct to conventional orthodontics for the provision of anchorage control has been advocated.<sup>9</sup> They are smaller, more cost effective and less traumatic to insert when compared to endosseous dental implants. Clinical applications of orthodontic microimplants are diverse and include molar intrusion,<sup>10</sup> molar uprighting,<sup>11</sup> open bite correction,<sup>12</sup> en masse retraction,<sup>13</sup> group distal movement and occlusal plane correction.<sup>14</sup> Success rates and guidelines for insertion, placement and the avoidance of complications are well documented in the literature.<sup>15,16</sup>

Practice parameters recommended by the American Academy of Sleep Medicine (AASM) confer guidelines that oral appliances (OA) are indicated for mild to moderate cases of OSA where patients cannot tolerate CPAP. Also, CPAP therapy is indicated for severe cases of OSA as a first line of therapy before OA consideration.<sup>17</sup>

In light of the above AASM recommendations and advances in orthodontic microimplant anchorage, we present a case report of an adult patient with a history of intolerance to both CPAP and OA therapy. To address the issue of the lack of dental units for oral appliance support, we present this case report as an introduction to the novel concept of microimplant mandibular advancement (MiMA) therapy as an alternative method of mandibular forward repositioning.

We hypothesize that microimplants are able to provide skeletal anchorage for mandibular advancement for the treatment of snoring and OSA. The advantages

of this novel treatment modality may include the ability to treat patients with excessive missing teeth, complete edentulism, periodontally compromised teeth, exaggerated gag reflex, CPAP and oral appliance intolerance. Additionally, the benefit of increased oral volume for improved breathing providing an alternative treatment modality for mandibular advancement is proposed as a novel concept.

## DIAGNOSIS AND ETIOLOGY

We present the case of a 66 year old male patient with a body mass index of 26.1 kg/m<sup>2</sup> who was referred by a sleep disorder specialist for the provision of a mandibular advancement splint (MAS) device. The patient was diagnosed with severe OSA by the referring sleep specialist and had previously rejected nasal CPAP treatment and uvulopalatopharyngoplasty (UPPP) surgery.

The clinical history of the patient revealed typical signs of sleep disordered breathing including, excessive daytime sleepiness, chronic snoring, witnessed apneas by partner and tiredness upon awakening. TMJ examination was normal showing no signs contraindicating mandibular advancement therapy.

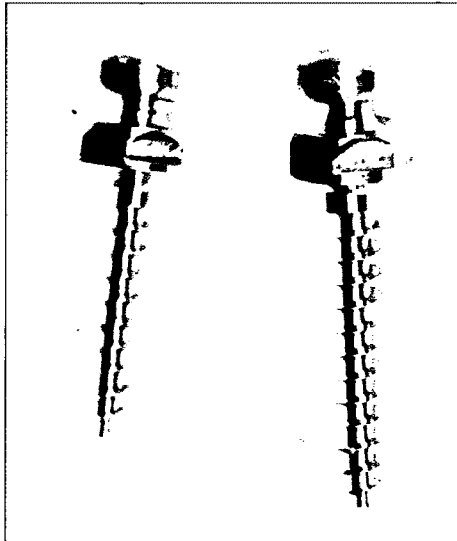
An intraoral examination revealed a single upper left central missing in the upper arch. The presence of a fixed 2 unit cantilevered bridge with cingulum rest on the adjacent left upper lateral tooth was noted. In the lower arch, bilateral partially edentulous saddles were noted with the 1st premolar missing on the left side and 1<sup>st</sup> premolar to 2<sup>nd</sup> molar missing on the lower right hand side.

## TREATMENT OBJECTIVES

As the patient presented with the chief complaint of excessive daytime sleepiness, loud snoring and diminished concentration, our immediate goal was the alleviation of these OSA symptoms. Our patient coped well functionally despite having numerous missing teeth in the lower arch. Hence, our secondary and longer term goal was the restoration of the lower edentulous sites.

### TREATMENT ALTERNATIVES

As the patient history revealed a rejection of CPAP therapy and the UPPP surgical alternative, a MAS device was proposed as a secondary treatment choice.



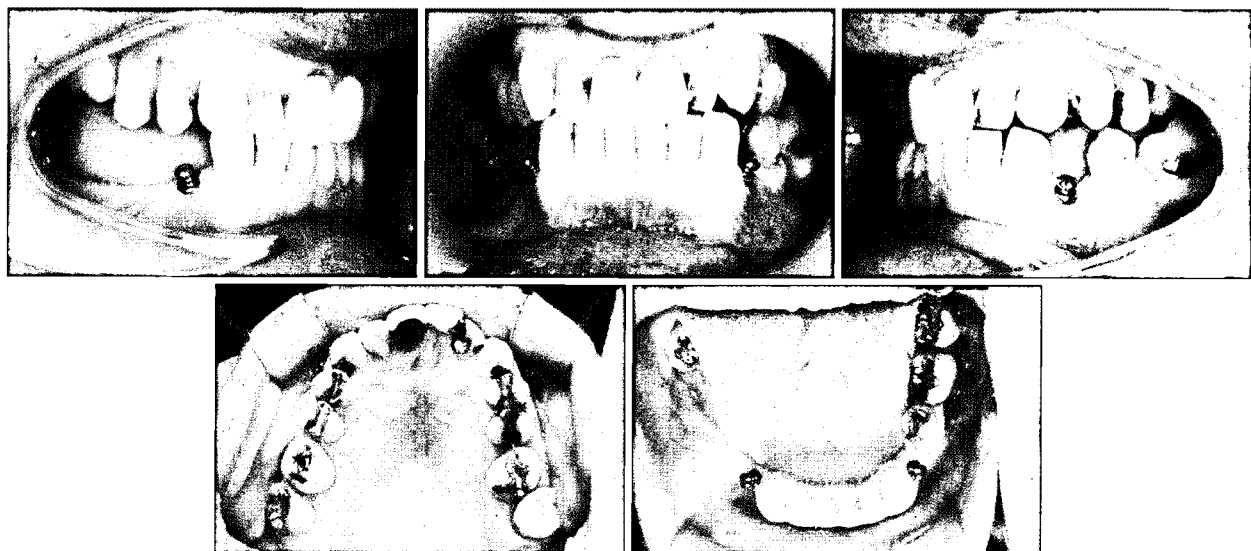
**Fig 1.** 2 Microimplants (Absoanchor, Dentos Inc. Daegu, Korea) made of titanium Grade 5 alloy fabricated with mushroom head for comfort (1.6 mm diameter, 8 mm or 10 mm length).

However, our patient persevered with the MAS oral appliance for only 3 months. On follow up, he complained of pain in the TMJ, an altered occlusion and some mobility in the upper 2 unit bridge and lower anterior teeth. Despite relieving the acrylic on the MAS appliance and further encouragement, the patient was no longer compliant and resistant to other oral appliance designs that were available.

Hence, microimplant mandibular advancement (MiMA) therapy with microimplants was proposed as an alternative means of skeletal anchorage for the purpose of mandibular forward repositioning. The novel concept of using microimplants for SDB treatment was discussed. Additionally, the risks and complications associated with microimplant treatment were discussed and informed consent obtained.

### TREATMENT PROGRESS

Following the insertion of 2 microimplants in the mandible, mandibular advancement was achieved with the use of intraoral attachments connecting the microimplants to a custom fabricated reverse pull facemask. Both objective and subjective outcome measurements were recorded during sleep with MiMA therapy and the results were compared to baseline values. The



**Fig 2.** 2 Microimplants (1.6 x 10 mm long) inserted by hand driver in the mandible distal to both lower canines. The self-tapping method was used under copious irrigation.

treatment protocol is summarised briefly below.

#### Microimplant type and insertion technique

1. Two orthodontic micro-implants (1.6 × 10 mm long, Absoanchor, Dentos Inc. Daegu, Korea) made of titanium Grade V alloy fabricated with a custom designed mushroom head for comfort and ease of auxiliary attachment were inserted under light anaesthesia (Fig 1).
2. Both the left and right microimplants in the mandible were inserted with the self-tapping method. A pilot drill of 1.3 mm was used to create a channel under copious irrigation. The 1.6 mm microimplants of 10 mm length were manually inserted with a hand driver distal to the lower canines (Fig 2). An angulation of 20 degrees to the long axes of the canine teeth was used and the choice of lengths of 8 mm or 10 mm microimplants were available for different locations and differing local factors such as bone quality and type, the proximity of adjacent root structures, the presence of missing teeth and soft tissue thickness.

Mechanical evaluation -Peak insertion torque (PIT) was measured with a precision advanced force/torque indicator (AFTI-Mecmesin, Mecmesin, West Sussex, UK) for both implants and the torque value of 7.6 Ncm and 8.2 Ncm was recorded on the left and right microimplants respectively.

3. Intra-oral attachment/Delayed loading- Force loading of both microimplants were delayed for 2 weeks. To each microimplant on each side of the mandible, a custom made "shepherd's crook" of variable

length was attached from a postero- anterior direction. Both left and right hook attachments extended bilaterally by means of a silicone insulated leader line extra-orally to the midsagittal plane (Fig 3) whereby they were connected to a custom fabricated reverse pull facemask (Fig 4).

4. Mandibular Advancement- was obtained by activating the titratable screw mechanism located on the facemask to a preordained level of advancement, in this patient 75% of the maximum protrusive capability. The 2 mandibular microimplants provided skeletal anchorage to which the hook attachments "pulled" on for mandibular advancement.
5. Outcome Measurements- baseline (T1) and follow up sleep studies (T2) with MiMA therapy were performed 6 months after microimplant insertion. The Sonomat is a non-invasive sleep recording system that records breathing sounds, snoring sounds, breathing movements and snoring movements. Objective

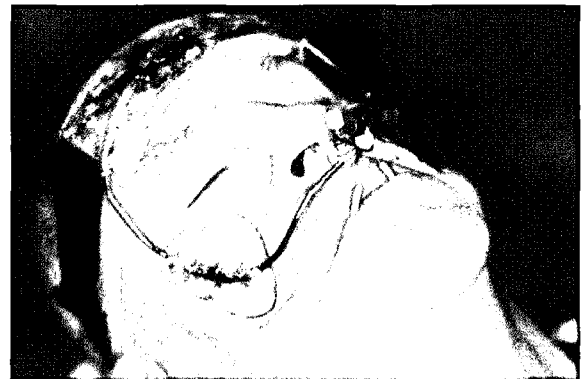

Fig 4. Custom fabricated facemask for mandibular advancement.

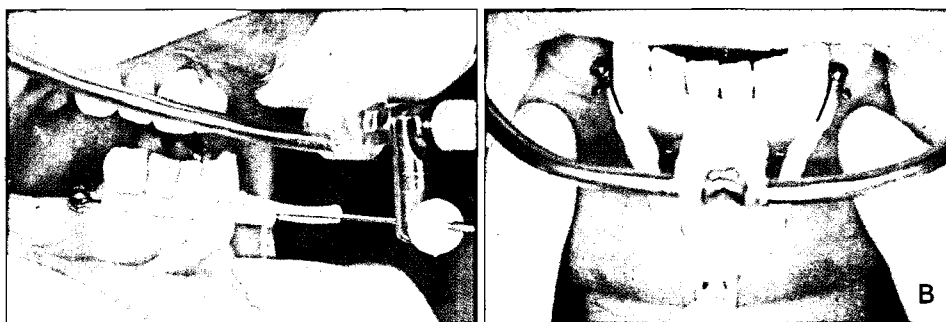


Fig 3. A, Microimplant attached to titratable connector; B, frontal view of both microimplants attached to a connector.

measurements recorded included the Apnea /hypopnea Index (AHI), snore Frequency (SF) and respiratory movement Index (RMI). Subjective measurements included Epworth Sleepiness Scale (ESS).

## RESULTS

A comparison of the ambulatory sleep studies before and after MiMA therapy is outlined in Table 1. The patient's apnea hypopnea index (AHI) decreased significantly from 52.5 to 4.1 events per hour. The snoring frequency (SF) is a quantitative measure of the frequency of snoring that occurs over total sleep time and is expressed as a percentage. In our patient, snoring frequency (SF) decreased from 45.6% to 9.1%. Movements as a result of respiratory events is quantified by the respiratory movement index (RMI). The patient's RMI decreased from 52.4 moves/hr to 11.5 moves/hr.

Subjective measures of improvement from 15 to 4 in the Epworth Sleepiness score (ESS) reflect the positive impact of MiMA therapy. These overall positive changes occurred interestingly despite a gain in the patient's BMI during the treatment period.

Cephalometric changes following MiMA therapy are shown in Table 2. There was no significant change in the skeletal analysis reflected in the SNA, SNB values, lower facial height and the mandibular plane angle. Dental analysis showed no significant change in the upper and lower incisors positions as shown in the U1

**Table 1.** Comparison of treatment results following MiMA therapy

| Sleep study variables    | Baseline (T1) | MiMA therapy (T2) |
|--------------------------|---------------|-------------------|
| AHI (events/hr)          | 52.5          | 4.1               |
| SF (%)                   | 45.6          | 9.1               |
| RMI (moves/hr)           | 52.4          | 11.5              |
| BMI (kg/m <sup>2</sup> ) | 26.1          | 27.6              |
| ESS                      | 15            | 4                 |

AHI, Apnea/hypopnea index; SF, snore frequency; RMI, Respiratory Movement Index; BMI, body mass index; ESS, Epworth Sleepiness Scale.

to SN and L1 to GoGn values. 6/ANS-PNS and 7/GoGn values remained relatively unchanged showing little change in the vertical position of the upper 1<sup>st</sup> molar and lower 2<sup>nd</sup> molar relative to the palatal plane and mandibular plane respectively.

The panoramic and lateral cephalometric views of the mandibular microimplants are shown in Fig 5. Although a 2D representation of the patient in an upright posture, the lateral cephalometric radiographs depict an increase in the retroglossal airway space in the sagittal plane.

## DISCUSSION

The use of CPAP or oral appliances (OA) for the treatment of snoring and sleep apnea is well documented in the literature. Poor CPAP compliance is a frequent occurrence with greater than 50% of patients terminating therapy due to nasal mask leaks or symptoms such as, dry nose, nasal congestion, mouth, throat

**Table 2.** Comparison of cephalometric analysis following MiMA therapy

|                               | Baseline (T1) | MiMA therapy (T2) |
|-------------------------------|---------------|-------------------|
| Skeletal                      |               |                   |
| Gonial angle (°)              | 139.3         | 139.5             |
| SNA (°)                       | 80.3          | 80.4              |
| SNB (°)                       | 77.1          | 76.9              |
| ANB (°)                       | 3.2           | 3.5               |
| Lower facial height -LFH (mm) | 75.6          | 75.5              |
| Mn plane angle (°)            | 34.2          | 34.7              |
| Dental                        |               |                   |
| U1 to SN (°)                  | 97.2          | 97.5              |
| L1 to GoGn (°)                | 74.7          | 74.6              |
| 6/ANS-PNS (mm)                | 21.7          | 21.9              |
| 7/GoGn (mm)                   | 22.97         | 22.88             |

LFH, ANS-Me (mm); Mn Plane angle, ANS-PNS to GoGn; 6/ANS-PNS, length of mesiobuccal cusp tip of upper 1<sup>st</sup> molar perpendicular to ANS-PNS; 7/GoGn, length of mesiobuccal cusp tip of lower 2<sup>nd</sup> molar perpendicular to GoGn.

discomfort with cold air and pressure sores.<sup>18</sup> Reports of compliance as high as 80% after 3 months and as low as 46% have been documented. Although randomized cross-over studies indicate that CPAP is more efficacious than OA's, generally patients prefer OA's to CPAP therapy.<sup>19</sup>

The use of OA's are indicated for patients who have mild to moderate OSA.<sup>17</sup> Our severe OSA patient however was intolerant to both CPAP and OA therapy. Short term side effects including discomfort of the oral musculature and TMJ region on waking, xerostomia and an altered dental occlusion have been reported.<sup>20,21</sup> The side effects of MAS therapy on occlusal changes experienced by the patient was consistent with that found in the literature. Pantin et al.<sup>22</sup> noticed that dental side effects were a common occurrence although transient in nature. Panula et al.<sup>7</sup> treated a 56 year old woman with an OA device and documented irreversible changes in her occlusion. These findings of occlusal alterations, overbite/over jet changes and TMD symptoms were documented by Rose et al.<sup>23</sup> and in longer term studies by de Almeida et al.<sup>24</sup> and Marklund et al.<sup>25</sup>

The use of prosthetic implants for the treatment of obstructive sleep apnea-hypopnea syndrome (OSAHS) is sparse in the literature. In a study by Hoekema et al.,<sup>26</sup> four out of six mild to moderately affected patients were treated effectively with a reduction of AHI to less than 5 events per hour. However, five out the six patients required four mandibular prosthetic implants with secondary treatment required for one patient requiring an additional six implants in the maxilla to support the mandibular repositioning appliance. Despite endosseous implant support, problems with pressure discomfort on the labial mucosa were still encountered. The marked increase in cost, surgical morbidity and prolonged treatment times of six months in this study limited the clinical feasibility of this treatment modality to a select few edentulous OSAHS patients.

A recent study by Flanagan et al.<sup>27</sup> involved a snore reduction appliance constructed for the atrophic mandible. Two endosseous implants were surgically placed in an atrophic mandibular ridge to retain a complete mandibular denture and, in turn, an overlying bimaxil-

lary removable snore reduction appliance. A dual laminate appliance was vacu-form fitted to the maxillary teeth and the mandibular denture and luted in a protrusive relation with cold cure acrylic. The appliance maintained the mandible in a protrusive position to open the upper airway to reduce snoring. Both these studies above involved the use of oral appliances or dentures attached to prosthetic implants used to boost anchorage and retention. The recruited candidates were mild to moderate in OSA severity and all patients were edentulous in the mandible.

More recently, orthodontic implants for the treatment of a fully edentulous OSA was documented by de Carlos et al.<sup>28</sup> Four orthoimplants were placed, two in the subanterior nasal spine area in the maxilla and the other two in the external oblique ridge in the mandible. Intermaxillary elastics were used for this 49 year old patient with marked improvement of the AHI value to 2.2 events per hour. Although the orthoimplants were not used to improve denture retention, this case reported treatment of a fully edentulous moderate OSA patient.

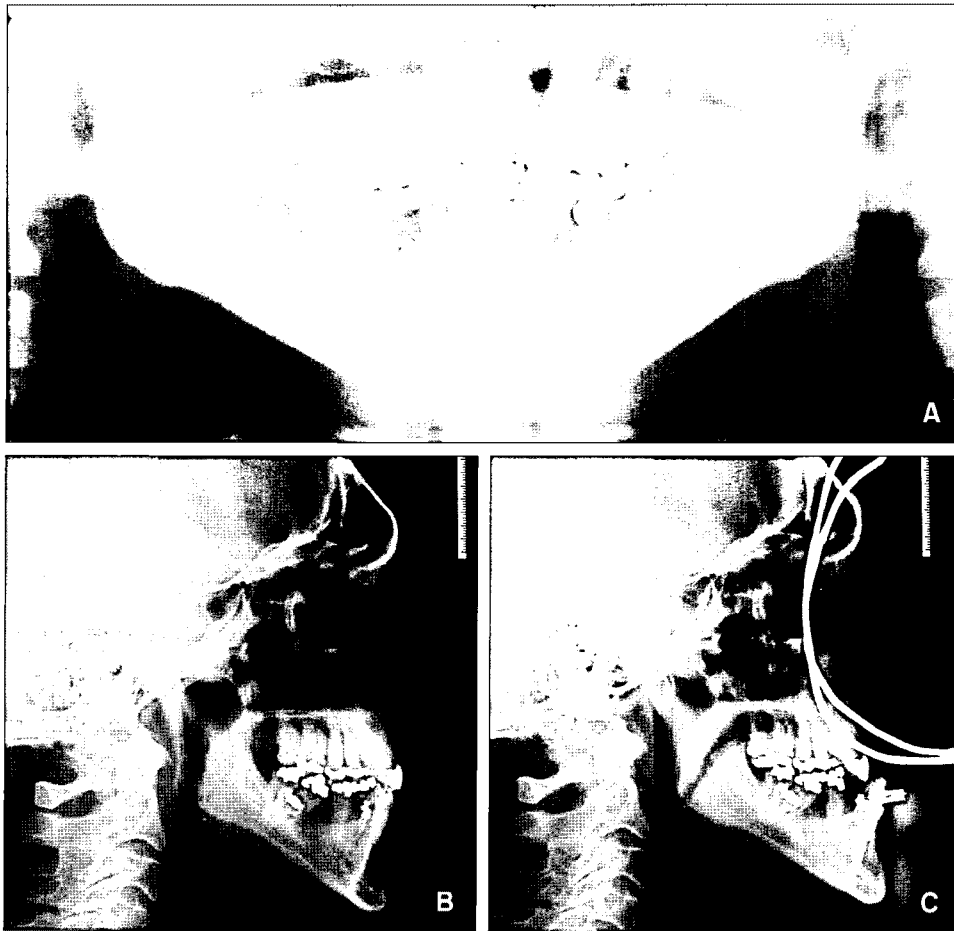
To our knowledge, our case report is the first to document the use of orthodontic implants for the treatment of a dentate severe OSA patient. In dentate patients, the issues of root proximity and cortical bone levels need to be taken into account. A study by Park et al.<sup>15</sup> showed that cortical bone thickness is thicker in the mandible and the density varies with each patient and the region of placement. Areas of thick cortical bone are thought to be more stable for microimplant placement.<sup>29</sup> Studies by Motoyoshi and coworkers<sup>30</sup> found that a cortical bone thickness of 1 mm improves the stability and success rate of mini-implants. However, the literature reveals that microimplant failures are more common in the mandible and a higher incidence on the right hand side has been reported.<sup>15</sup> The causes of mandibular microimplant failure are multi-factorial and controversial. It is thought that denser cortical bone in the mandible may result in heat generation and bone necrosis during site preparation. Also, occlusal forces generated from mastication have been thought to create a "jiggling" effect and play a role in destabilizing microimplants in the posterior mandible.<sup>31</sup>

The consensus of the waiting period for loading for

orthodontic implants is variable in the literature. Many authors believe they can be loaded immediately,<sup>9</sup> others allow periods of 2 weeks and up to 12 weeks before loading.

When evaluating the biomechanical performance of implants placed into bone, methods such as insertional torque and axial pull-out strength are commonly used. Insertional torque represents the frictional resistance between screw threads and bone and determines primary stability of the screw. Axial pull-out strength however is the result of bone failure<sup>32</sup> and quantifies the resistance to bone rupture in the long axis of the screw before bone rupture occurs.<sup>33</sup> Some studies reveal a correlation between insertion torque and axial pull-out strength,<sup>34</sup> although others have not found an association between the two.<sup>35</sup>

In our patient, a self tapping method by pre-drilling under copious irrigation with a 1.3 mm drill was used to minimize microimplant fracture and a 1.6 mm diameter  $\times$  10 mm long mini-implant was placed bilaterally distal to the lower canines (Fig 5A). Peak Insertion torque values of 7.6 and 8.2 Ncm was achieved as recommended by Motoyoshi et al.<sup>36</sup> for implant stability and a strict oral hygiene regimen was enforced as inflammation around a temporary anchorage device has been shown to be a key factor predicting microimplant failure.<sup>37</sup> Loading was delayed for 2 weeks and no mobility during the treatment phase was observed. Movement in orthodontic implants have been documented in studies showing tipping movements of 0.4 mm at the screw head of screws placed in the zygomatic buttress used for enmasse anterior retraction with nickel tita-



**Fig 5.** Panoramic radiograph of patient with 2 microimplants (1.6 mm diameter  $\times$  10 mm long) inserted in the mandible (A). Lateral view of 2 microimplants inserted in the mandible (B), and with MiMA therapy (C). An increase in retro-glossal airway size can be seen following mandibular advancement with MiMA therapy.

nium coil springs for 9 months.<sup>38</sup> No mobility was noted in our patient's mini-implants but due to the design of the mushroom head and shepherd's crook attachment, we anticipate that if it were to occur, uncontrolled tipping would result towards the adjustable connector.

In our patient, the primary aim was to treat the SDB with the secondary aim being the restoration of the edentulous sites. For this reason, our focus was the immediate alleviation of SDB symptoms without the use of OA's. The patient was presented with a series of treatment options. Beginning with the protocol described in the case report, each successful stage of SDB management presented the patient with more comprehensive treatment choices. Risks and complications inherent to mini-implants were discussed and informed consent was obtained.

In the event of treatment failure such as poor resolution of SDB symptoms, the removal of mini-implants would entail a simple and short chairside procedure whereby the screws could be removed in a counter-clockwise direction under local anaesthesia.<sup>9</sup> If mini-implant mobility or failure occurred with improvement in SDB symptoms, a new mini-implant could then be placed in an alternative site on an immediate basis. The lower cost, ease of placement and lower morbidity associated with mini-implants in MiMA therapy presented a more attractive option to our patient that had already rejected CPAP therapy, OA's and did not want a removable denture.

The alleviation of symptoms and improvement in the ESS scores by MiMA therapy motivated our patient to be more receptive to other treatment options. For example, additional mini-implants placed in the maxilla such as the anterior nasal spine or between the roots of the upper laterals and canines could be placed. Intra-oral attachments connecting the existing 2 lower mini-implants to additional upper maxillary mini-implants could provide a source of skeletal anchorage for mandibular advancement. This option would negate the need for the extra-oral facemask although varying lengths of intraoral attachment would be needed to regulate the amount of advancement.

The improvement of SDB symptoms also provided impetus for greater acceptance to more costly treatment

options which could concurrently address the restorative management of the lower edentulous sites. Although the 1.6mm diameter mini-implant demonstrated clinically its ability to resist movement during mandibular advancement during a short 6 month period, its long term performance is unknown and is currently being trialled in a larger sample study by the author. In the event of mini-implant loss or failure due to mobility, larger diameter implants could be used in the tooth sites 33 and 43. A customized crown abutment with a small buccal ball extension could be designed to connect the implant to facemask for mandibular advancement.

In this manner, mini-implants could conceivably serve as a first-line screening tool as described in MiMA therapy to assess the efficacy of mandibular advancement for the treatment of SDB. In edentulous patients as well as dentate patients, 1.6 mm diameter implants can be easily placed bilaterally between the roots of teeth in the lower arch. The mini-implants can be left indefinitely if stable and effective but a strict oral hygiene regimen is essential as inflammation has been shown to affect their long term success.<sup>15</sup>

In this patient, "necking" of the cortical bone had occurred in the area where the lower left first premolar had been extracted. We placed the microimplants at a 20 degree angulation with the aim to avoid the movable buccal frenum and increase bony purchase in attached gingiva. We note that if a more horizontal angulation was used, bicortical bony anchorage could have been attained and this has been found to increase implant stability considerably.<sup>39</sup> Freudenthaler and coworkers<sup>40</sup> used 12 bicortical screws immediately loaded for lower molar protraction and encountered buccal soft tissue impingement and inflammation in certain sites. This necessitated that some screws had to be repositioned. A lowered microimplant position however would also provide space for the possibility of a 3 unit bridge on the lower left side.

Current methods of OA therapy predominantly involve removable appliances that require tooth borne anchorage. Most adjustable oral appliances today incorporate advancement mechanisms such as screws or intraoral attachments to advance the mandible anteriorly. Studies indicate with increased use of OA's, long



term sequelae such as tooth movement and changes in occlusion will occur.<sup>23,41</sup> Clinical symptoms and the relapse of snoring or obstructive sleep apnea (OSA) are often observed in review appointments where in addition to occlusal changes, the patient or partner may state that they are snoring once more. Typically, the clinician may activate the OA advancement mechanism to further advance the mandible. These forces are distributed to the teeth and surrounding tissues and may again result in undesirable dental side effects. Kato et al.<sup>42</sup> found a dose dependent effect of mandibular positioning whereby each 2 mm of forward positioning resulted in a 20% improvement in the number and severity of nocturnal oxygen desaturation. With an increase in mandibular advancement, we speculate that undesired forces on the teeth would increase leading to greater dento-alveolar changes.

In this patient, both the skeletal and dental analyses outlined in Table 2 showed no significant changes. From a skeletal perspective, the mandibular plane and lower facial height remained unchanged following MiMA therapy. Inclinations of the upper and lower anterior teeth relative to the anterior cranial base and mandibular plane also remained unchanged. The vertical relationships of the upper 1<sup>st</sup> molar and the lower 2<sup>nd</sup> molar relative to the palatal plane and mandibular plane respectively affirm the stability of molar positions. This is in contrast to long term OA studies showing changes in the dental arch and occlusion.<sup>43,44</sup>

We reason that reciprocal forces generated by mandibular advancement in MiMA therapy are not dissipated to teeth and surrounding soft tissues but to bone via the mini-implant. This raises the question of the maximum pullout strength of a 1.6 mm × 10 mm long mini-implant. In a study by Huja et al.,<sup>29</sup> 2 mm diameter × 6 mm long screws were placed in 4 beagle dogs. The dogs were sacrificed 30 minutes after placement and the maximum force at pullout was recorded. Forces of 134.5 ± 24 N in the anterior mandibular region and 388.3 ± 23.1 N in the posterior mandibular region were recorded. An earlier study by Hitchon et al.<sup>45</sup> compared the pullout strengths of long 12 mm, 14 mm and 16 mm screws in human cadaveric cervical spines and concluded that the longest possible screw should be used for maximum pullout strength. A recent

animal study concluded that pull-out strength was at its maximum immediately after insertion and that cortical bone thickness decreases with time due to bone resorption.<sup>35</sup> In our view, the choice of a 1.6 mm × 10 mm long screw provided sufficient holding power without the costs and morbidity associated with larger diameter implants whilst avoiding root damage in this 6 month term study. Longer term studies however are needed to answer the questions of longevity and mini-implants response to SDB applications.

Another consideration with regard to the holding power of mini-implants relates to the stages of sleep. SDB events such as OSA and hypopnea are observed in stage 2 and rapid eye movement (REM) sleep. During MiMA therapy, the patient is conscious as he postures the lower jaw forward. As the connectors engage the mini-implants to the facemask, the mandible is held in the anterior position. When the patient falls asleep, he progresses through the sleep stages and REM sleep. REM sleep is associated with a reduction in postural muscle tone and is referred to as hypotonia. The body and mandible is in a paralysed-like state of muscle hypotonia and we speculate that less force is exerted on the mini-implants during these stages.

Deglutition and the muscular forces generated during swallowing is yet another factor that may predispose the orthodontic mini-implants to tangential loading. Studies by Sato et al.<sup>46,47</sup> explored the frequency of deglutition in both healthy and OSA patients and concluded that the occurrence was infrequent in both groups. In OSA patients, deglutition was episodic and absent for long periods and did not occur during apnea or hypopnea periods. The mean number of swallows per hour during total sleep time was 5.4 ± 3.1. Additionally, the study noted that deglutition was related to sleep stage. The mean number of swallows per hour was 6.2 ± 6.1 during stage 1 sleep, 6.0 ± 3.4 during stage 2 sleep, 3.0 ± 5.2 during stage 3 sleep, and 0 during stage 4 sleep. The deeper the sleep stage, the lower the mean deglutition frequency. Further research into the holding power of orthodontic mini-implants during a full sleep cycle is warranted and is currently being undertaken by the author.

The comparison of sleep study variables for our patient in MiMA therapy is shown in Table 1. Our pri-

mary goal of SBD treatment was not only to lower the number of respiratory events so as to reduce cardiovascular and other health related risks, but to relieve immediate symptoms, improve quality of life in a severe OSA patient intolerant of CPAP and OA's. The significant reduction in AHI values from 52.5 to 4.1 events per hour had a positive impact on sleep efficiency and quality of life for our patient. This finding is further reinforced by the fall in RMI values depicting a reduction in compensatory respiratory movements and sleep fragmentation. The reduction in ESS score from 15 to 4 show improvements in daytime sleepiness and neuro-cognitive function both of which have been implicated with motor vehicle accidents.<sup>48</sup>

A noteworthy observation in this patient is the fall in the frequency of snoring quantified by the Snore Frequency (SF). The Sonomat sleep study demonstrated a remarkable reduction in snore frequency of 45.6% to 9.1% of total sleep time following MiMA therapy. This observation is of clinical significance. Although primary snoring may not be represented in a AHI value, it is a very common symptom and a robust indication of upper airway obstruction which causes a vibratory insult that leads to inflammation in the pharyngeal soft tissue structures. Increasingly, recent evidence has associated this mechanism with endothelial dysfunction as a prelude to atherosclerosis in asymptomatic patients with mild sleep disordered breathing.<sup>3</sup>

The study has the limitation in that it is a short term study presenting a referred patient that was intolerant of CPAP and OA's. The level of SDB obstruction was clearly defined by the sleep physician to occur in the oropharynx and MiMA therapy provided a successful outcome. It is important to note that other levels of obstruction in whole or part arising in the nasopharynx, or hypopharynx can compound a complex multi-factorial condition that is difficult to treat. Weight gain, social habits and alcohol consumption can further decrease long term success. A multi-disciplinary approach in the management of SBD is encouraged as is the diligent monitoring on a long term basis.

This case report introduces MiMA therapy as a novel treatment modality that can be applied clinically in patients when there are insufficient teeth present for OA therapy, periodontally compromised patients with

unstable dental units, where the presence of an exaggerated gag reflex or unresolved OA side effects exist and complete edentulism. Patient selection should be on a case by case basis taking into account previous OSA treatment history and local factors for successful micro-implantation.

## CONCLUSION

In summary, our case report highlights the possibility of using orthodontic microimplants for the treatment of snoring and OSA patients. The favorable reductions in the AHI, snoring and respiratory movement indices as well as ESS scores in a severe OSA patient are encouraging. Mandibular advancement was achieved with a customized titrable facemask attached to 2 microimplants anchored to the mandible. The stable microimplants provided skeletal anchorage without exerting reciprocal forces to the dentition. Although further studies with longer follow up and larger study sample are warranted, we conclude that microimplant mandibular advancement (MiMA) therapy can provide an alternative treatment modality for patients who are intolerant of CPAP and oral appliance therapy.

- 국문초록 -

코골이 및 수면 무호흡 치료를 위한  
마이크로 임플란트를 이용한 하악골 전진술

Joachim Ngiam · 경희문

이 증례보고는 심한 수면무호흡증으로 진단된 환자로, 다른 구강 내 OSA 치료 장치와 nCPAP 치료에 적응을 못하는 66세 남자 환자였다. 하악골에 2개의 교정용 마이크로 임플란트를 식립한 후, 식립 2주 후부터 구강외 고정원인 개조된 안면마스크에서 마이크로 임플란트에 힘을 가하여 하악골을 전진시켰다. 마이크로 임플란트를 이용한 하악골 전진술 (MiMA)은 심한 수면 무호흡환자의 AHI (apnea-hypopnea index), 코골이 및 심한 수면 무호흡증상을 개선할 수 있었다.

주요 단어: 수면무호흡, 마이크로 임플란트, 하악골 전진

## REFERENCES

1. Kim J, In K, You S, Kang K, Shim J, Lee S, et al. Prevalence of sleep-disordered breathing in middle-aged Korean men and women. *Am J Respir Crit Care Med* 2004;170:1108-13.
2. Joo S, Baik I, Yi H, Jung K, Kim J, Shin C. Prevalence of excessive daytime sleepiness and associated factors in the adult population of Korea. *Sleep Med* 2009;10:182-8.
3. Lee SA, Amis TC, Byth K, Larcos G, Kairaitis K, Robinson TD, et al. Heavy snoring as a cause of carotid artery atherosclerosis. *Sleep* 2008;31:1207-13.
4. Sullivan CE, Issa FG, Berthoin-Jones M, Eves L. Reversal of obstructive sleep apnoea by continuous positive airway pressure applied through the nares. *Lancet* 1981;1:862-5.
5. Hwang SH, Park IS, Nam KY, Kim JB, Cho YW, Suh YS, et al. Cephalometric differences in obstructive sleep apnea between obese and non-obese Korean male patients. *Korean J Orthod* 2008;38:202-13.
6. Mehta A, Qian J, Petocz P, Darendeliler MA, Cistulli PA. A randomized, controlled study of a mandibular advancement splint for obstructive sleep apnea. *Am J Respir Crit Care Med* 2001;163:1457-61.
7. Panula K, Keski-Nisula K. Irreversible alteration in occlusion caused by a mandibular advancement appliance: an unexpected complication of sleep apnea treatment. *Int J Adult Orthodon Orthognath Surg* 2000;15:192-6.
8. Petit FX, Pepin JL, Bettiga G, Sadek H, Raphael B, Levy P. Mandibular advancement devices: rate of contraindications in 100 consecutive obstructive sleep apnea patients. *Am J Respir Crit Care Med* 2002;166:274-8.
9. Kyung HM, Park HS, Bae SM, Sung JH, Kim IB. Development of orthodontic micro-implants for intraoral anchorage. *J Clin Orthod* 2003;37:321-8.
10. Lee HA, Park YC. Treatment and posttreatment changes following intrusion of maxillary posterior teeth with miniscrew implants for open bite correction. *Korean J Orthod* 2008;38:31-40.
11. Park HS, Kyung HM, Sung JH. A simple method of molar up-righting with micro-implant anchorage. *J Clin Orthod* 2002;36:592-6.
12. Kuroda S, Katayama A, Takano-Yamamoto T. Severe anterior open-bite case treated using titanium screw anchorage. *Angle Orthod* 2004;74:558-67.
13. Yao CC, Lai EH, Chang JZ, Chen I, Chen YJ. Comparison of treatment outcomes between skeletal anchorage and extraoral anchorage in adults with maxillary dentoalveolar protrusion. *Am J Orthod Dentofacial Orthop* 2008;134:615-24.
14. Takano-Yamamoto T, Kuroda S. Titanium screw anchorage for correction of canted occlusal plane in patients with facial asymmetry. *Am J Orthod Dentofacial Orthop* 2007;132:237-42.
15. Park HS, Jeong SH, Kwon OW. Factors affecting the clinical success of screw implants used as orthodontic anchorage. *Am J Orthod Dentofacial Orthop* 2006;130:18-25.
16. Lee SY, Cha JY, Yoon TM, Park YC. The effect of loading time on the stability of mini-implant. *Korean J Orthod* 2008;38:149-58.
17. Kushida CA, Morgenthaler TI, Littner MR, Alessi CA, Bailey D, Coleman J Jr, et al. Practice parameters for the treatment of snoring and Obstructive Sleep Apnea with oral appliances: an update for 2005. *Sleep* 2006;29:240-3.
18. Pepin JL, Leger P, Veale D, Langevin B, Robert D, Levy P. Side effects of nasal continuous positive airway pressure in sleep apnea syndrome. Study of 193 patients in two French sleep centers. *Chest* 1995;107:375-81.
19. Clark GT, Blumenfeld I, Yoffe N, Peled E, Lavie P. A cross-over study comparing the efficacy of continuous positive airway pressure with anterior mandibular positioning devices on patients with obstructive sleep apnea. *Chest* 1996;109:1477-83.
20. Tegelberg A, Wilhelmsson B, Walker-Engstrom ML, Ringqvist M, Andersson L, Krekmanov L, et al. Effects and adverse events of a dental appliance for treatment of obstructive sleep apnoea. *Swed Dent J* 1999;23:117-26.
21. Battagel JM, Kotecha B. Dental side-effects of mandibular advancement splint wear in patients who snore. *Clin Otolaryngol* 2005;30:149-56.
22. Pantin CC, Hillman DR, Tennant M. Dental side effects of an oral device to treat snoring and obstructive sleep apnea. *Sleep* 1999;22:237-40.
23. Rose EC, Staats R, Virchow C Jr, Jonas IE. Occlusal and skeletal effects of an oral appliance in the treatment of obstructive sleep apnea. *Chest* 2002;122:871-7.
24. de Almeida FR, Lowe AA, Tsuiki S, Otsuka R, Wong M, Fastlicht S, et al. Long-term compliance and side effects of oral appliances used for the treatment of snoring and obstructive sleep apnea syndrome. *J Clin Sleep Med* 2005;1:143-52.
25. Marklund M, Franklin KA, Persson M. Orthodontic side-effects of mandibular advancement devices during treatment of snoring and sleep apnoea. *Eur J Orthod* 2001;23:135-44.
26. Hoekema A, de Vries F, Heydenrijk K, Stegenga B. Implant-retained oral appliances: a novel treatment for edentulous patients with obstructive sleep apnea-hypopnea syndrome. *Clin Oral Implants Res* 2007;18:383-7.
27. Flanagan D. A removable snore reduction appliance for a mandibular edentulous patient. *J Oral Implantol* 2009;35:221-4.
28. de Carlos F, Cobo J, Fernandez Mondragon MP, Alvarez Suarez A, Calvo Blanco J. Orthoimplants: an alternative treatment for SAHS? *Sleep Breath* 2009 Sep 18 (Epub ahead of print).
29. Huja SS, Litsky AS, Beck FM, Johnson KA, Larsen PE. Pull-out strength of monocortical screws placed in the maxillae and mandibles of dogs. *Am J Orthod Dentofacial Orthop* 2005;127:307-13.
30. Motoyoshi M, Inaba M, Ono A, Ueno S, Shimizu N. The effect of cortical bone thickness on the stability of orthodontic mini-implants and on the stress distribution in surrounding bone. *Int J Oral Maxillofac Surg* 2009;38:13-8.
31. Chen Y, Kyung HM, Zhao WT, Yu WJ. Critical factors for the success of orthodontic mini-implants: a systematic review. *Am J Orthod Dentofacial Orthop* 2009;135:284-91.
32. Huja SS, Rao J, Struckhoff JA, Beck FM, Litsky AS. Biomechanical and histomorphometric analyses of monocortical screws at placement and 6 weeks postinsertion. *J Oral Implantol* 2006;32:110-6.
33. McLain RF, Fry MF, Moseley TA, Sharkey NA. Lumbar pedi-

- cle screw salvage: pullout testing of three different pedicle screw designs. *J Spinal Disord* 1995;8:62-8.
34. Zdeblick TA, Kunz DN, Cooke ME, McCabe R. Pedicle screw pullout strength. Correlation with insertional torque. *Spine (Phila Pa 1976)* 1993;18:1673-6.
  35. Salmoria KK, Tanaka OM, Guariza-Filho O, Camargo ES, de Souza LT, Maruo H. Insertional torque and axial pull-out strength of mini-implants in mandibles of dogs. *Am J Orthod Dentofacial Orthop* 2008;133:790 e715-722.
  36. Motoyoshi M, Hirabayashi M, Uemura M, Shimizu N. Recommended placement torque when tightening an orthodontic mini-implant. *Clin Oral Implants Res* 2006;17:109-14.
  37. Chen YJ, Chang HH, Lin HY, Lai EH, Hung HC, Yao CC. Stability of miniplates and miniscrews used for orthodontic anchorage: experience with 492 temporary anchorage devices. *Clin Oral Implants Res* 2008;19:1188-96.
  38. Liou EJ, Pai BC, Lin JC. Do miniscrews remain stationary under orthodontic forces? *Am J Orthod Dentofacial Orthop* 2004;126:42-7.
  39. Brettin BT, Grosland NM, Qian F, Southard KA, Stuntz TD, Morgan TA, et al. Bicortical vs monocortical orthodontic skeletal anchorage. *Am J Orthod Dentofacial Orthop* 2008;134:625-35.
  40. Freudenthaler JW, Haas R, Bantleon HP. Bicortical titanium screws for critical orthodontic anchorage in the mandible: a preliminary report on clinical applications. *Clin Oral Implants Res* 2001;12:358-63.
  41. Ueda H, Almeida FR, Lowe AA, Ruse ND. Changes in occlusal contact area during oral appliance therapy assessed on study models. *Angle Orthod* 2008;78:866-72.
  42. Kato J, Isono S, Tanaka A, Watanabe T, Araki D, Tanzawa H, et al. Dose-dependent effects of mandibular advancement on pharyngeal mechanics and nocturnal oxygenation in patients with sleep-disordered breathing. *Chest* 2000;117:1065-72.
  43. Almeida FR, Lowe AA, Sung JO, Tsuiki S, Otsuka R. Long-term sequelae of oral appliance therapy in obstructive sleep apnea patients: Part I. Cephalometric analysis. *Am J Orthod Dentofacial Orthop* 2006;129:195-204.
  44. Almeida FR, Lowe AA, Otsuka R, Fastlicht S, Farbood M, Tsuiki S. Long-term sequelae of oral appliance therapy in obstructive sleep apnea patients: Part 2. Study-model analysis. *Am J Orthod Dentofacial Orthop* 2006;129:205-13.
  45. Hitchon PW, Brenton MD, Coppes JK, From AM, Torner JC. Factors affecting the pullout strength of self-drilling and self-tapping anterior cervical screws. *Spine (Phila Pa 1976)* 2003;28:9-13.
  46. Sato K, Nakashima T. Sleep-related deglutition in patients with sleep apnea-hypopnea syndrome. *Ann Otol Rhinol Laryngol* 2009;118:30-6.
  47. Sato K, Nakashima T. Human adult deglutition during sleep. *Ann Otol Rhinol Laryngol* 2006;115:334-9.
  48. Teran-Santos J, Jimenez-Gomez A, Cordero-Guevara J. The association between sleep apnea and the risk of traffic accidents. Cooperative Group Burgos-Santander. *N Engl J Med* 1999;340:847-51.