

Clinical Article

Three-Dimensional Digital Subtraction Angiographic Evaluation of Aneurysm Remnants after Clip Placement

Soon-Seob Ahn, M.D., Young-Don Kim, M.D.

Department of Neurosurgery, Daegu Catholic University College of Medicine, Daegu, Korea

Objective : The aneurysm remnants rate was evaluated via three-dimensional digital subtraction angiography (3D-DSA) in the postoperative evaluation of clipped aneurysms.

Methods : Data on surgically clipped aneurysms of anterior circulation obtained via postoperative 3D-DSA from February 2007 to March 2009 were gathered. The results of the postoperative 3D-DSA and of two-dimensional digital subtraction angiography (2D-DSA) for the detection of aneurysm remnants were compared, and an investigation was performed as to why 2D-DSA had missed some aneurysm remnants that were detected in the 3D-DSA. Various surgical factors that revealed aneurysm remnants in the 3D-DSA were also evaluated.

Results : A total of 39 neck remnants of 202 clipped aneurysms (19.3%) were confirmed in 3D-DSA, and these were classified according to Sindou's classification of aneurysm remnants. Patients with only a neck remnant found in the 3D-DSA represented 17.3% (35/202 aneurysms) of the whole series, and those with a residuum of neck plus sac found in the 3D-DSA represented 1.9% (4/202 aneurysms). The causes of aneurysm remnants were no full visualization (14/39, 35.9%), parent and perforator artery protection (10/39, 25.6%), clip design problems (8/39, 20.5%), and broad-necked aneurysm (7/39, 17.9%).

Conclusion : Patients with ≤ 2 mm aneurysm remnants showed an increased risk of undetectable aneurysm remnants in the 2D-DSA. The most frequent location of the missed aneurysm in 2D-DSA was the anterior communicating artery. 3D-DSA showed more aneurysm remnants than what is indicated in the existing literature, the 2D-DSA.

KEY WORDS : Digital subtraction angiography · Clipping · Remnant · Aneurysm.

INTRODUCTION

The performance of postoperative angiography in patients with aneurysm after clip placement depends on the surgeon's preference, and postoperative angiography is usually carried out using two-dimensional digital subtraction angiography (2D-DSA). A partially treated aneurysm, however, may lead to regrowth and rebleeding, and thus requires close attention, especially in young patients^{21,23}. The use of 3D-DSA has recently become increasingly popular in the neurosurgical field¹) as it provides greater detailed information for the evaluation of cerebral aneurysms compared with that of standard 2D and rotational DSA²⁰.

These authors wanted to detect aneurysm remnants more accurately via 3D-DSA after surgical clip placement to obtain baseline data for long-term follow-up. Moreover, to compare the results of the clip placement with those of the endovascular treatment carried out via 3D-DSA¹), it was thought that the proven rate of occlusion after surgical clip placement via 3D-DSA should be determined.

MATERIALS AND METHODS

From February 2007 to March 2009, surgically clipped aneurysms of anterior circulation obtained via postoperative 3D-DSA were gathered. Surgical clipping was routinely done, based mainly on preoperative multi-slice computerized tomographic angiography (MCTA), except in some special cases, and postoperative 3D-DSA data were obtained for the accurate evaluation of the operation and for the detection of aneurysm remnants. The medical records of all the patients were reviewed in detail to retrieve information

• Received : August 28, 2009 • Revised : December 31, 2009
• Accepted : January 31, 2010
• Address for reprints : Young-Don Kim, M.D.
Department of Neurosurgery, Daegu Catholic University College of Medicine, 3056-6 Daemyeong 4-dong, Nam-gu, Daegu 705-718, Korea
Tel : +82-53-650-4896, 4258, Fax : +82-53-650-4932
E-mail : shydshyd@cu.ac.kr

regarding clinical presentations, locations, sizes, and anatomical shapes of the aneurysms, as well as the occurrence of premature rupture, the types, and the numbers of clips. Surgical video recordings were reviewed in aneurysm remnants cases that were confirmed via postoperative 3D-DSA to determine their causes. DSA was performed with femoral catheterization, using the Seldinger technique with a biplane unit (Integris Allura 12 & 15 Biplane; Philips Electronics, Best, Netherlands). Four-vessel angiographies were obtained in the antero-posterior, lateral, and bilateral oblique projections for each catheterization. A non-ionic contrast material (Visipaque 320; Amersham Health, Cork, Ireland) was used for each injection. DSA was performed with a 2-cm field of view (FOV) and a 1024×1024 matrix. The spatial resolution was 2.5×2.5 mm. To obtain a three-dimensional image, 35 mL of the non-ionic contrast material was injected into the internal carotid or vertebral artery with a power injector at 4 mL/s and 500 psi. Another 12 mL of the non-ionic contrast material was injected into the internal carotid or vertebral artery with a power injector at 3 mL/s and 600 psi. A 180-degree rotational DSA was performed for 8 s. The obtained information was transferred to a computer (Dell Computers, USA) using a 3D reconstruction software (Integris 3D-RA, Philips Integris Systems). A volume-rendering technique was used to render the 3D-DSA images. The 2D-DSA and 3D-DSA images were then evaluated, focusing on any aneurysm remnant that may be present. All the raw 3D data sets were stored on the workstation's hard disc, and later in a compact disc. The raw data sets stored in compact discs can be reloaded in the workstation for real-time evaluation and new high-resolution reconstruction. Subsequently, the DSA images of the corresponding vascular trees were reviewed on a PACS workstation to detect aneurysm remnants and their locations.

An aneurysm remnant was defined as a filling with the contrast medium of its portion greater than 1 mm in size^{14,16}. The detected aneurysm remnants were classified according to Sindou's classification of aneurysm remnant (N-group : with only a neck remnant found in the 3D-DSA; N + S group : with a residuum of neck plus sac found in the 3D-DSA)¹⁹. Two neuroradiologists interpreted the DSA and 3D angiographic image, focusing on finding any residual aneurysm. The aneurysm remnants found in the 3D-DSA were measured using an internal digital caliper. The diagnostic performances of postoperative 3D-DSA and 2D-DSA in the detection of aneurysm remnants were compared via receiver operating characteristic (ROC) analysis, with a 95% confidence interval (CI). The Chi-square test was used to investigate the statistically significant variables in the coincidence between the postoperative aneurysm remnants

and the variable factors (clinical presentations, locations, sizes, and anatomical shapes of the aneurysms, the presence of premature rupture, and types and numbers of clips). An investigation was performed to determine why 2D-DSA missed some aneurysm remnants that had been detected by 3D-DSA.

RESULTS

From February 2007 to March 2009, 285 patients with subarachnoid hemorrhage were treated at authors' institution. A total of 202 patients with 250 clipped cerebral aneurysms met the inclusion criteria. There were 80 males and 122 females, and the mean age of the patients was 53.1 ± 17.8 years. Of the said patients, 161 had a single aneurysm and 41 had multiple aneurysms. Of the patients with multiple aneurysms, 34 had two aneurysms and seven had three aneurysms. Table 1 lists the demographic features of the patients and their aneurysms. Surgical clipping and postoperative DSA were performed within a mean interval of 21.3 ± 17.9 days (range : 3-128). All the patients were treated with pure titanium clips with various configurations (Sugita titanium aneurysm clip : Mizuho, Tokyo, Japan; Yasagil titanium aneurysm clip : Aesculap AG, Tuttlingen, Germany).

Using Sindou's classification of aneurysm remnants, 39 aneurysm remnants were detected (19.3%, 39/202). The patients with only a neck remnant (N-group) found in the 3D-DSA represented 17.3% (35/202 aneurysms) of the whole series, and those with a residuum of neck plus sac (N + S group) found in the 3D-DSA represented 1.9% (4/202 aneurysms). Four aneurysm remnants (4/39, 10.2%) in the N + S group required further treatment. Three patients were successfully treated with reoperation, and one patient was also successfully treated using the endovascular technique. Otherwise, in the postoperative 2D-DSA study, 22 aneurysm remnants were detected (10.8%, 22/202) : N-group in 2D-DSA represented 10.9% (22/202 aneurysms) of the whole series, and the N + S group in 3D-DSA represented 1.9% (4/202 aneurysms) (Table 2).

Of the 39 aneurysm remnants in 3D-DSA, those with size greater than 2 mm aneurysms represented 51.2% (20/39) of the whole series, and 2D-DSA missed three aneurysm remnants (15.0%, 3/20) that were detected in the 3D-DSA. 2D-DSA missed aneurysm remnants in all three cases as these were hidden by the multiple clips. The ≤ 2 mm aneurysm remnants in 3D-DSA represented 48.8% (19/39) of the whole series, and 2D-DSA missed 14 aneurysm remnants (73.6%, 14/19) that had been detected in the 3D-DSA. 2D-DSA missed aneurysm remnants because of such

Table 1. Characteristics of 202 aneurysms and 39 remnants

Characteristics	No. of clipped aneurysm (%)	Aneurysm remnant (%)
No. of patients		
Female	122 (60.4)	18 (8.9)
Male	80 (39.6)	21 (10.3)
Total	202	39 (19.3)
Aneurysm location		
Anterior communication artery	72 (35.7)	16 (7.9)
Middle cerebral artery aneurysm	56 (27.7)	11 (5.4)
Posterior communication artery	48 (23.7)	11 (5.4)
Anterior cerebral artery aneurysm	11 (5.4)	1 (0.4)
Internal carotid artery	15 (7.5)	0 (0.0)
Shape of aneurysm on preoperative MCTA		
Simple	104 (51.4)	16 (7.9)
Complex	98 (48.6)	23 (11.3)
Size (mm) of neck on preoperative MCTA		
< 6	154 (76.3)	26 (12.8)
6-10	38 (18.8)	9 (4.4)
> 10	10 (4.9)	4 (1.9)
Size (mm) of sac on preoperative MCTA		
< 7	174 (86.1)	31 (15.3)
7-12	24 (11.8)	6 (2.9)
13-24	4 (1.9)	2 (0.9)
> 25	0 (0.0)	0 (0.0)

MCTA : multi-slice computerized tomographic angiography

Table 2. Aneurysm remnants on 2D-DSA and 3D-DSA classified by type and size

	2D-DSA	3D-DSA
Type of aneurysm remnants		
N	18 (81.8%)	35 (89.8%)
N + S	4 (18.2%)	4 (10.2%)
Total	22 (100%)	39 (100%)
Size of aneurysm remnants		
2 mm ≥	Detected 5 case	19/39 (48.8%)
2 mm <	Detected 17 case	20/39 (51.2%)
Total		39 (100%)

2D-DSA : two-dimensional digital subtraction angiography, 3D-DSA : three-dimensional digital subtraction angiography, N : only neck remnant, N + S : neck plus sac remnant

remnants' small sizes, the presence of clip masses, and the overlapping with cerebral vessels (Table 2, 3). The mean size of the aneurysm remnants that had been missed by 2D-DSA was 1.67 ± 0.24 mm. Patients with ≤ 2 mm aneurysm remnants had an increased risk of having undetectable aneurysm remnants in 2D-DSA (70%, 14/20) compared with patients with > 2 mm aneurysm remnants (15%, 3/20) ($p = 0.035$) (Table 2).

Seventeen missed aneurysm remnants found in 3D-DSA were located in the anterior communicating artery (11 cases, 64.7%), posterior communicating artery (3 cases, 17.6%), and middle cerebral artery bifurcation (3 cases, 17.6%) (Table 3). In the Chi-square test, the statistically significant

variables that coincided with one another were the locations of the aneurysm, especially the anterior communicating artery ($p = 0.027$).

In the ROC analysis for postoperative 3D-DSA, the area under the ROC curve and with 95% CI for postoperative 2D-DSA were 0.843 and 0.630 to 1.056 ($p = 0.001$), respectively. In the Chi-square test, the coincidence for postoperative 2D-DSA and 3D-DSA was 69.3%. The statistically significant variable that coincided with remnants was the aneurysm neck size ($p = 0.006$). The dome size of the aneurysm and the long diameter of the aneurysm sac were not statistically significant ($p = 0.371$, $p = 0.068$). In terms of surgical factors, the main cause of aneurysm remnants was no full visualization (14/39, 35.9%), followed by clip design problems (8/39, 20.5%), broad-necked aneurysm (7/39, 17.9%), parent artery protection (7/39, 17.9%), and perforator artery protection (3/39, 7.7%).

DISCUSSION

In existing related literature, the incidences of residual aneurysm range from 3.5% to 13%^{7,8,13,15-17}. These reports, however, were obtained from 2D-DSA. Recently, as 3D-DSA provides more information for the evaluation of cerebral aneurysms compared with the standard 2D and rotational

DSA^{10,20}, the use of 3D-DSA has become increasingly popular in the neurosurgical field, especially before and after embolization^{1,11}. These authors wanted to detect aneurysm remnants more accurately via 3D-DSA after surgical clip placement to obtain baseline data for long-term follow-up as a partially treated aneurysm may lead to regrowth⁴ and re-bleeding and thus requires close attention^{21,23}. Moreover, to compare the results of clip placement with those of endovascular treatment performed via 3D-DSA^{1,18} and with the standard assessment of the degree of aneurysm occlusion, it was thought that the proven rate of occlusion after surgical clip placement via 3D-DSA should be determined.

Table 3. The aneurysm remnants which were missed on 2D-DSA and confirmed on 3D-DSA

NO.	Age/ Sex	Location	No. of Clip	Remnant Size	Result of 3D-DSA	Undetected cause by 2D-DSA	Cause of incomplete clipping	Surgical point of view	Treatment
1	52/M	ACoA	1	1.9 × 0.5	N	Small size	Perforator	Unavoidable	F/U
2	58/F	ACoA	2	1.9 × 0.9	N	Hidden by clip	Perforator	Unavoidable	F/U
3	57/F	PCoA	3	1.7 × 1.8	N	Overlapped with vessel	Clip design	Avoidable	F/U
4	45/F	ACoA	2	1.8 × 1.3	N	Hidden by clip	No full visualization	Avoidable	F/U
5	59/M	MCA	1	1.6 × 0.8	N	Overlapped with vessel	Broad neck	Unavoidable	F/U
6	48/M	MCA	3	2.5 × 1.3	N	Hidden by clip	Parent a. stenosis	Unavoidable	F/U
7	39/F	ACoA	2	1.7 × 1.0	N	Hidden by clip	Broad neck	Unavoidable	F/U
8	57/M	ACoA	2	1.8 × 1.1	N	Overlapped with vessel	Clip design	Avoidable	F/U
9	64/M	ACoA	2	2.3 × 1.0	N + S	Hidden by clip	No full visualization	Avoidable	Re-clip
10	58/M	ACoA	1	1.2 × 0.5	N	Small size	Parent a. stenosis	Unavoidable	F/U
11	50/M	ACoA	1	1.8 × 1.9	N	Hidden by clip	Parent a. stenosis	Unavoidable	F/U
12	68/F	MCA	1	1.5 × 0.7	N	Overlapped with vessel	Parent a. stenosis	Unavoidable	F/U
13	47/M	ACoA	1	1.4 × 1.8	N	Overlapped with vessel	No full visualization	Avoidable	F/U
14	48/M	PCoA	1	2.4 × 0.9	N	Hidden by clip	Clip design	Avoidable	F/U
15	50/F	ACoA	4	1.5 × 0.5	N	Small size	Broad neck	Unavoidable	F/U
16	72/F	ACoA	1	1.7 × 1.8	N	Hidden by clip	Clip design	Avoidable	F/U
17	41/F	PCoA	1	1.7 × 0.5	N	Small size	No full visualization	Avoidable	F/U

ACoA : anterior communicating artery, PCoA : posterior communicating artery, MCA : middle cerebral artery, F/U : follow up, N: neck, N + S : neck plus sac

It is very important to define what aneurysm remnant is because its definition can affect the rate of aneurysm remnants to be obtained. In this study, aneurysm remnant is defined as a filling with contrast medium of its portion greater than 1 mm in size^{14,16}. The detected aneurysm remnants were classified according to Sindou's classification of aneurysm remnants¹⁹. Such aneurysm remnant classification enabled the authors of this study to come up with a treatment plan : the N-group usually needs only follow-up studies as in their case, the clip is completely across the base of the aneurysm, and there is a residual neck between the clip and the arterial lumen; the N + S group, however, needs immediate further treatment. The obtained post-clipping aneurysm remnant rate was 39/202 (19.3%) in 3D-DSA and 22/202 (10.9%) in 2D-DSA. The results of 2D-DSA are in keeping with the 3.5-13%^{7,8,13,15-17} rates documented in the literature as shown in a recent meta-analysis. Kang et al.¹⁰ reported an aneurysm remnant rate of 42% obtained through 3D-DSA. Both results obtained by these authors and by Kang et al. are far higher than the incidences reported in the existing literature^{7,8,13,15-17}. Further, it can be said that the

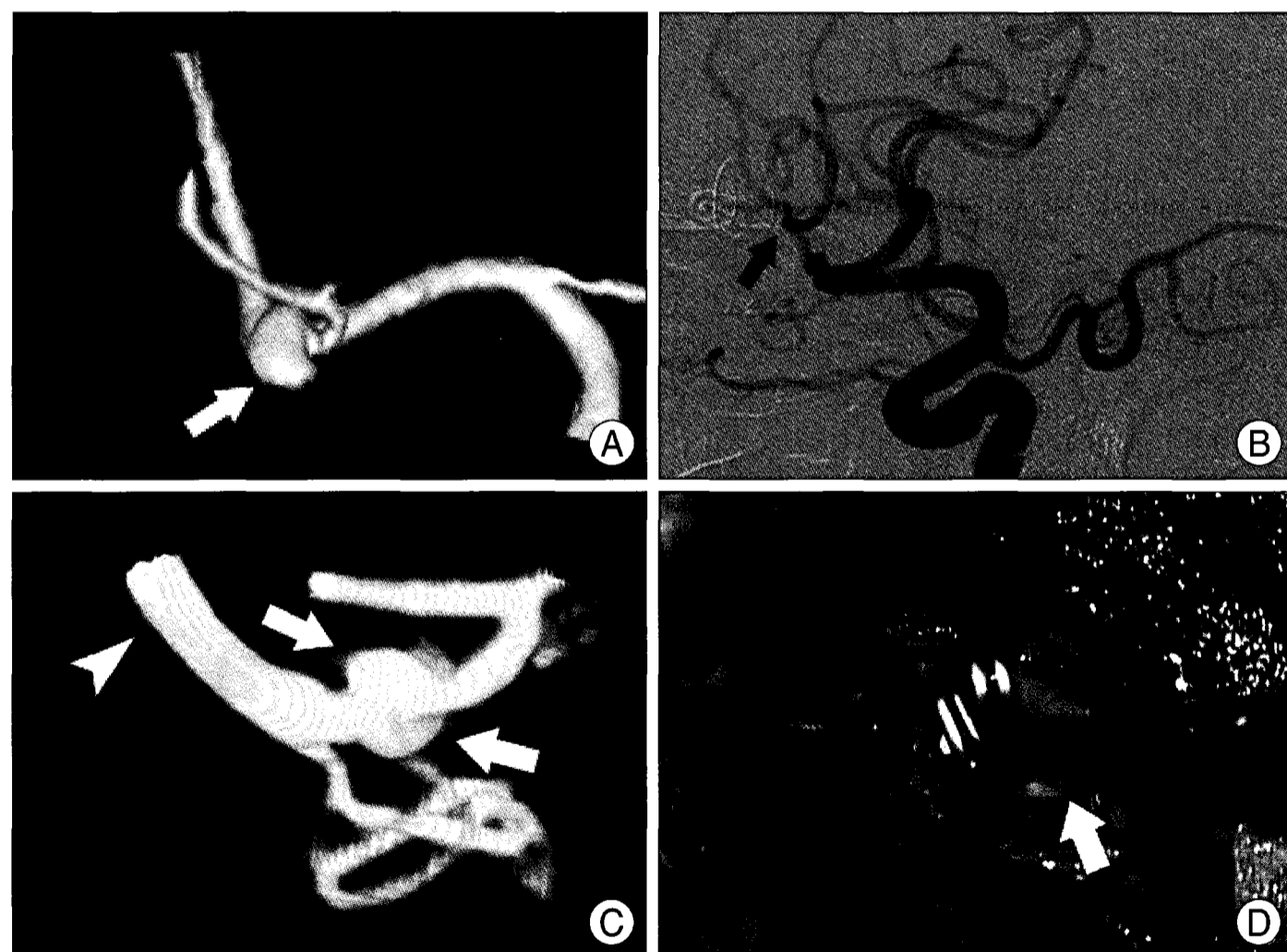


Fig. 1. A 59-year-old man harbored an aneurysm on the right middle cerebral artery bifurcation, which has been clipped and reinforced with cottonoid wrapping. A : Preoperative multi-slice computerized tomographic angiography shows a broad-necked saccular aneurysm (arrow). B : Postoperative 2D-DSA is performed 78 days after surgical clipping. 2D-DSA shows no remnant (arrow). C : Postoperative 3D-DSA is performed on the same day, and it shows remnant (arrows) (arrowhead: right M1). D : On the operative field, bulging portion below clip is shown but lumen stenosis and wide neck held complete clipping. The bulging portion is wrapped with cottonoid after clipping. The remnants size was 1.8 × 1.1 mm².

so-called small dog-ear aneurysm remnants were classified as aneurysm remnants because of the excellent image quality and the various viewing angles of 3D-DSA. Moreover, 3D-DSA proved to be better at detecting small aneurysm remnants (≤ 2 mm) and anterior communicating artery aneurysms (sandwiched between two A2 arteries and hidden)

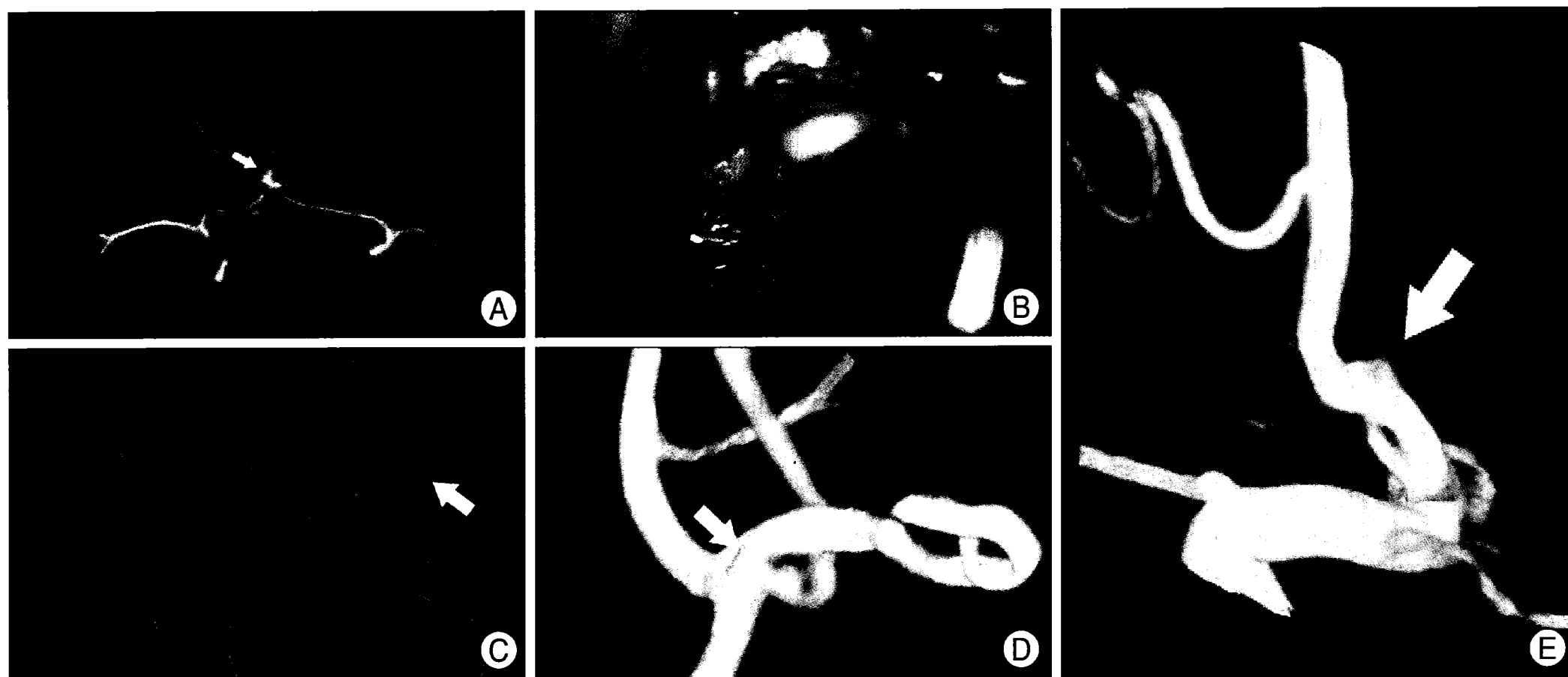


Fig. 2. A 52-year-old man with a residual neck after clipping of an anterior communicating artery (ACoA) aneurysm due to perforating artery arising from the aneurysm sac. A : Preoperative multi-slice computerized tomographic angiography shows a saccular aneurysm (arrow) on ACoA. B : Perforating arteries (arrows) arising from the aneurysm sac (arrowhead) are demonstrated in the operative photograph. C : Postoperative 2D-DSA is performed 20 days after surgical clipping. The remnant is not visible. D and E : Unlike 2D-DSA, 3D-DSA shows a small and residual remnant (arrow). The remnant size is $1.9 \times 0.5 \text{ mm}^2$.

than 2D-DSA. The clip mass and overlapping cerebral vessels in 3D-DSA did not serve as obstacles to the evaluation of the aneurysm remnants; as such, 3D-DSA was useful in evaluating aneurysm remnants with multiple-clip application and complex surrounding cerebral vessels.

Some of the causes of aneurysm remnants are unavoidable because of the incidence of a broad neck, parent artery protection, and perforator artery, but some of the causes of aneurysm remnants, such as no full visualization and clip design problems, are avoidable if one pays more attention to them. For such reason, surgeons should be more concerned about the sufficient exposure of aneurysm necks and must use an endoscope to confirm clip placement and design.

In terms of immediate follow-up on aneurysm remnants, authors were greatly helped by the use of 3D-DSA in treating one patient with aneurysm remnants that had not been seen in the 2D-DSA due to the presence of clip masses and the surrounding A2 vessels. The other three aneurysm remnants of the N + S group were detected in the 2D-DSA and were given further surgical or endovascular treatment. Immediate follow-up angiography for aneurysm remnants is important not only for the detection of aneurysm remnants requiring further treatment, but also for the collection of basic data for long-term follow-up. The complete exclusion of aneurysms from blood circulation is very important, especially when the patient is young^{9,24}. If an aneurysm remnant is found, the imaging follow-up must be planned in relation to the sizes of the rest of the aneurysm remnants^{4,12,20}. Clearly, the most dangerous type of evolution is the growth of an aneurysm remnant, as it may even-

tually lead to rupture. Authors have published the role of MCTA after clip placement in aneurysm patients, based on a comparison with 3D-DSA. In that study, it was concluded that patients with aneurysm remnants clipped with a single titanium clip can be evaluated via MCTA. MCTA is not useful, however, when multiple clips have been applied and when the aneurysm remnant is very small ($\leq 2 \text{ mm}$)⁵. In this study, 2D-DSA had missed 17 aneurysm remnants that were detected in 3D-DSA for various reasons. Among these was the fact that 11 of the patients were under 55 years old. Follow-up should be performed on them using 3D-DSA because they were relatively young, although the risk of bleeding from their aneurysm remnants is believed to be only 1-2%^{2-4,6,8,22}.

CONCLUSION

Postoperative 3D-DSA showed a higher incidence of aneurysm remnants than those cited in existing literatures, which had used 2D-DSA. Although the aneurysm remnants confirmed using 3D-DSA, which had been missed by 2D-DSA simultaneously, were small and the bleeding risk was low, the results of this study may be important as baseline data for long-term follow-up after clip placement.

References

1. Abe T, Hirohata M, Tanaka N, Uchiyama Y, Kojima K, Fujimoto K, et al. : Clinical benefits of rotational 3D angiography in endovascular treatment of ruptured cerebral aneurysm. *AJNR Am J Neuroradiol* 23 : 686-688, 2002
2. Akyüz M, Tuncer R, Yilmaz S, Sindel T : Angiographic follow-up after surgical treatment of intracranial aneurysms. *Acta Neurochir*

- (Wien) 146 : 245-250; discussion 250, 2004
3. CARAT Investigators : Rates of delayed rebleeding from intracranial aneurysms are low after surgical and endovascular treatment. *Stroke* 37 : 1437-1442, 2006
 4. David CA, Vishteh AG, Spetzler RF, Lemole M, Lawton MT, Partovi S : Late angiographic follow-up review of surgically treated aneurysms. *J Neurosurg* 91 : 396-401, 1999
 5. Dehdashti AR, Binaghi S, Uske A, Regli L : Comparison of multislice computerized tomography angiography and digital subtraction angiography in the postoperative evaluation of patients with clipped aneurysms. *J Neurosurg* 104 : 395-403, 2006
 6. Deshmukh VR, Kakarla UK, Figueiredo EG, Zabramski JM, Spetzler RF : Long-term clinical and angiographic follow-up of unclip-pable wrapped intracranial aneurysms. *Neurosurgery* 58 : 434-442; discussion 434-442, 2006
 7. Drake CG, Allcock JM : Postoperative angiography and the "slipped" clip. *J Neurosurg* 39 : 683-689, 1973
 8. Feuerberg I, Lindqvist C, Lindqvist M, Steiner L : Natural history of postoperative aneurysm rests. *J Neurosurg* 66 : 30-34, 1987
 9. Johnston SC, Dowd CF, Higashida RT, Lawton MT, Duckwiler GR, Gress DR; CARAT Investigators : Predictors of rehemorrhage after treatment of ruptured intracranial aneurysms : the Cerebral Aneurysm Rerupture After Treatment (CARAT) study. *Stroke* 39 : 120-125, 2008
 10. Kang HS, Han MH, Kwon BJ, Jung SI, Oh CW, Han DH, et al. : Postoperative 3D angiography in intracranial aneurysms. *AJNR Am J Neuroradiol* 25 : 1463-1469, 2004
 11. Kiyosue H, Tanoue S, Okahara M, Hori Y, Nakamura T, Nagatomi H, et al. : Anatomic features predictive of complete aneurysm occlusion can be determined with three-dimensional digital subtraction angiography. *AJNR Am J Neuroradiol* 23 : 1206-1213, 2002
 12. Lee JH, Kim SJ, Cha J, Kim HJ, Lee DH, Choi CG, et al. : Postoperative multidetector computed tomography angiography after aneurysm clipping : comparison with digital subtraction angiography. *J Comput Assist Tomogr* 29 : 20-25, 2005
 13. Lin T, Fox AJ, Drake CG : Regrowth of aneurysm sacs from residual neck following aneurysm clipping. *J Neurosurg* 70 : 556-560, 1989
 14. Macdonald RL, Wallace MC, Kestle JR : Role of angiography following aneurysm surgery. *J Neurosurg* 79 : 826-832, 1993
 15. Martin NA, Bentson J, Viñuela F, Hieshima G, Reicher M, Black K, et al. : Intraoperative digital subtraction angiography and the surgical treatment of intracranial aneurysms and vascular malformations. *J Neurosurg* 73 : 526-533, 1990
 16. Rauzzino MJ, Quinn CM, Fisher WS 3rd : Angiography after aneurysm surgery : indications for "selective" angiography. *Surg Neurol* 49 : 32-40; discussion 40-41, 1998
 17. Sato S, Suzuki J : Prognosis in cases of intracranial aneurysm after incomplete direct operations. *Acta Neurochir (Wien)* 24 : 245-252, 1971
 18. Schaafsma JD, Sprengers ME, van Rooij WJ, Sluzewski M, Majoie CB, Wermer MJ, et al. : Long-term recurrent subarachnoid hemorrhage after adequate coiling versus clipping of ruptured intracranial aneurysms. *Stroke* 40 : 1758-1763, 2009
 19. Sindou M, Acevedo JC, Turjman F : Aneurysmal remnants after microsurgical clipping : classification and results from a prospective angiographic study (in a consecutive series of 305 operated intracranial aneurysms). *Acta Neurochir (Wien)* 140 : 1153-1159, 1998
 20. Sugahara T, Korogi Y, Nakashima K, Hamatake S, Honda S, Takahashi M : Comparison of 2D and 3D digital subtraction angiography in evaluation of intracranial aneurysms. *AJNR Am J Neuroradiol* 23 : 1545-1552, 2002
 21. Thornton J, Bashir Q, Aletich VA, Debrun GM, Ausman JI, Charbel FT : What percentage of surgically clipped intracranial aneurysms have residual necks? *Neurosurgery* 46 : 1294-1298; discussion 1298-1300, 2000
 22. Tsutsumi K, Ueki K, Morita A, Usui M, Kirino T : Risk of aneurysm recurrence in patients with clipped cerebral aneurysms : results of long-term follow-up angiography. *Stroke* 32 : 1191-1194, 2001
 23. Wermer MJ, Rinkel GJ, Greebe P, Albrecht KW, Dirven CM, Tulleken CA : Late recurrence of subarachnoid hemorrhage after treatment for ruptured aneurysms : patient characteristics and outcomes. *Neurosurgery* 56 : 197-204; discussion 197-204, 2005
 24. Wermer MJ, van der Schaaf IC, Velthuis BK, Algra A, Buskens E, Rinkel GJ; ASTRA Study Group : Follow-up screening after subarachnoid haemorrhage : frequency and determinants of new aneurysms and enlargement of existing aneurysms. *Brain* 128 : 2421-2429, 2005