

PDS 퀴팅봉합술을 이용한 안면거상술

김석권 · 김명훈 · 권용석 · 이근철

동아대학교 의과대학 성형외과학교실

Limited Dissection Face Lift with PDS Quilting Suture

Seok Kwun Kim, M.D., Ph.D., Myung Hoon Kim, M.D.,
Yong Seok Kwon, M.D., Ph.D., Keun Cheol Lee, M.D., Ph.D.

Department of Plastic & Reconstructive Surgery, Dong-A
University School of Medicine, Busan, Korea

Purpose: Facial rejuvenating surgery has become a challenge to most plastic surgeons. Patients are demanding fewer complications, a prompt recovery, and more natural results. Current trend of the face lift surgery has been developed into less invasive procedures. Every aging patient in Asia wants to look younger without obvious evidence of surgical correction.

Methods: The authors performed the limited dissection face lift with PDS quilting suture on twenty five patients. These five quilting sutures consist of sutures at 1~2 cm posterior to the prominent point of zygoma to the periosteum of the zygomatic arch, at the lateral border of Bichat's fat pad area to the zygomatic arch, at the lateral border of the orbicularis oculi muscle to the deep temporal fascia, at the upper lateral border of the platysma to the periosteum of the mastoid, and at the anterior lower margin of the earlobe to the deep temporal fascia by quilting suture technique to achieve rejuvenation.

Results: These procedures could produce a balanced volumetric rejuvenation. This method gave considerable benefit of stable and satisfactory results. It provides reduced operative time, well corrected nasolabial fold and neck wrinkle, and swift recovery with minimal complications.

Conclusion: Although it could not replace the classic facelift, this technique can be recommended as an option for patients who do not present with advanced facial aging or not want a more extensive procedure.

Key Words: Facial rejuvenation, Limited dissection face lift, Quilting suture

Received March 4, 2010
Revised August 30, 2010
Accepted September 1, 2010

Address Correspondence: Seok Kwun Kim, M.D., Ph.D., Department of Plastic & Reconstructive Surgery, Dong-A University, College of Medicine, 1 3-ga, Dongdaesin-dong, Seo-gu, Busan 602-715, Korea. Tel: 051) 240-2807/Fax: 051) 243-5416/E-mail: sgkim1@dau.ac.kr

* This article was supported by the Dong-A University research fund.

I. INTRODUCTION

Most plastic surgeons refer to the words "facial rejuvenation" for face lift. The word "lifting" only implies pulling up what has fallen or tightening up what has loosened. If face lifting includes only these procedures, it will usually give an unnaturally tightened appearance. A pulled, tight look is not aesthetically pleasing and does not give satisfactory appearance.

Every patient wants to look younger without any obvious evidence of the surgical correction, therefore, some patients refuse to have the plastic surgeon operate on their eyebrows or eyelids. To meet the patients' requests, in the past 20 years the techniques utilized mainly involve pulling the superficial musculoaponeurotic system (SMAS) using Hamra's¹ deep plane composite face lifting, the most recent Saylan's² S-lift (a modified facelift), or Tonard's³ MACS lift. The face is a three-dimensional structure and two dimensional lifting in the vertical and horizontal directions will result in a flat, pulled, and aesthetically unnatural look. However, these techniques require invasive procedure in dissection. The emphasis in facial rejuvenation has shifted from improving specific areas, such as the nasolabial fold, to restoring the entire facial contour and reestablishing the graceful curves of youth. For the face to resume this smooth three-dimensional contour, all areas should be rejuvenated together.

For facial rejuvenation to be ideal, procedure should be quick and safe with a short or no hospital stay, swift recovery, inconspicuous scars on face, natural and stable rejuvenation. We designed our own technique to fulfill these criteria. Limited dissection face lift with PDS quilting suture on the SMAS could achieve a stable volumetric rejuvenation with low complication rates and swift recovery. Simple suspension suture will often induce the bowstring and skin notching, but quilting suture in the fashion of a narrow U-shaped loop can decrease the visible bowstring effect and skin notching.

Quilting effects redistribute the loose SMAS layer into 3-4 SMAS folds, adhering to each other, and provide fibrotic 3-dimensional SMAS. Therefore, quilting sutures can give a longer, permanent volumetric rejuvenating effect. The authors' method can obtain an additional volumetric effect in facial rejuvenation other than SMASectomy. Therefore, we report the concept and the technique of PDS quilting suture procedure for the face lift with limited access.

II. MATERIALS AND METHODS

The authors have performed the limited dissection face lift with PDS quilting suture. During the period from March 2006 to August 2009, these procedures were performed in 25 patients with mean age of 49 years (range, 46 to 58 years).

This technique is undertaken under only local anesthesia. Two point five milligram of midazolam is given intravenously before local anesthetic infiltration for comfortable relaxation and reduced local infiltrating pain. Local infiltration solution is prepared with diluted solution of 0.5% Lidocaine, 1:200,000 epinephrine and 2 mg of sodium bicarbonate.

A vertical temporal and preauricular, caudal end of the ear lobular incision is made, and then directed upward along the sulcus of posterior auricle. Posterior auricular transverse incision is made and extended to the 2.5~3 cm along the occipital hairline (Fig. 1). Limited skin flap is undermined beneath the subcutaneous fat tissue and above the SMAS layer, to about 1~2 cm posterior to the prominent area of zygomatic body and to the mandibular angle in oval shape. Lateral border of the orbicularis oculi muscle is exposed and the skin of

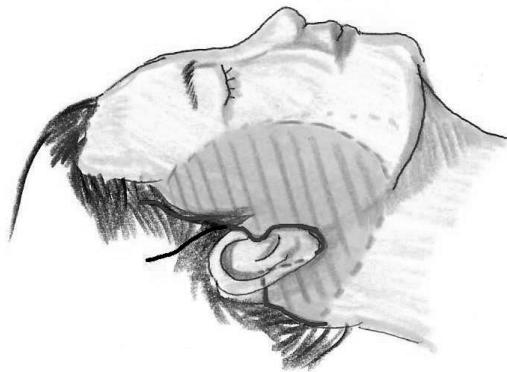

Fig. 1. Schematic view of incision line and limited dissection area.

mastoid area is also dissected (Fig. 2). Before putting quilting suture, meticulous hemostasis on the SMAS layer is needed. The ultimate goal of the technique is a pure anti-gravitational facial rejuvenation which can be achieved by the quilting suture acting on the deep facial soft tissue and the skin in the oblique and vertical direction.

The quilting suture is made in the fashion of a narrow U-shaped loop. The first 3-0 PDS quilting suture is taken from SMAS layer of 1~2 cm posterior to the prominent point of zygomatic body to the periosteum of the zygomatic arch to gain a tightening effect of the midface. The second quilting suture is taken from SMAS layer above the lateral border of Bichat's fat pad area to the same periosteum of the zygomatic arch. This suture produces suspension of Bichat's fat pad, inflation of the cheek area, and correction of the nasolabial fold. This suture can also correct the downward slanting of the corners of the mouth and the jowls. The third quilting suture is taken from the lateral border of the orbicularis oculi muscle to the deep temporal fascia and it serves tightening of the lateral orbit. The fourth quilting suture is taken from the upper lateral border of the platysma to the periosteum of the mastoid to correct the jowls and the marionette groove. This fourth suture is better to tie with stronger tension for an oblique and vertical pulling on the lateral part of the platysma muscle that it tightens the cervicomental area and improves the jowls. The additional fifth suture is taken from the anterior lower margin of the earlobe to the deep temporal fascia for the pure vertical vector. This additional fifth suture may not be needed in patients under fifty years, but essential in

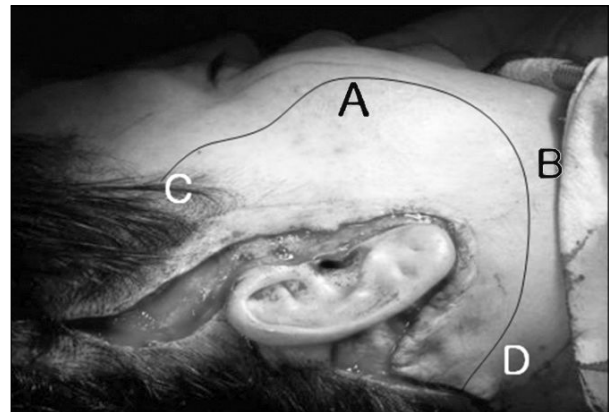


Fig. 2. Dissection points and extent. A. About 1~2 cm posterior to the prominent point of zygomatic body. B. The mandibular angle. C. Upper lateral border of the orbicularis oculi muscle. D. Mastoid area

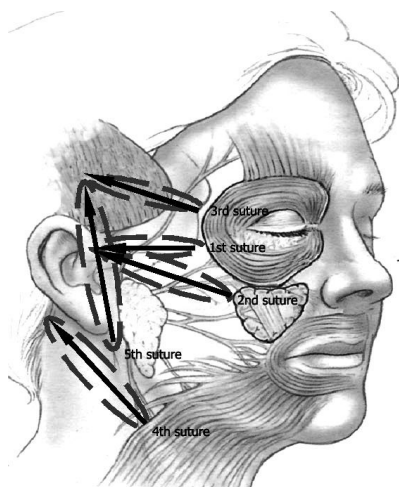


Fig. 3. Schematic view of anchoring sutures. The first anchoring suture is taken at the prominent area of the zygomatic body to the periosteum of zygomatic arch. The second anchoring suture is taken at the Bichat's fat pad to the periosteum of zygomatic arch. The third anchoring suture is taken at the upper lateral border of the orbicularis oculi muscle to the deep temporal fascia. The fourth suture is taken at the periosteum of mastoid to the upper lateral border of platysma. The fifth suture is taken at the anterior lower margin of the ear lobe to the deep temporal fascia for pure vertical vector.

the elderly patients (Fig. 3).

Skin redraping is performed in an oblique vector of a 45-degree angle. Any oblique vector can be divided into a horizontal and a vertical component. The horizontal vector produces only flattening of the face, whereas the vertical vector raises the gravitational descent tissue, thus enhancing the rejuvenation. The excess skin is excised and the skin flap is approximated with 4-0 PDS subcutaneous sutures by 3 key point sutures. A small silicone penrose drain is inserted in the lower part of the incision at the occipital hair line, and a further closure of the subcutaneous layer is performed with 5-0 PDS sutures and skin is closed with 5-0 and 6-0 nylon continuous or interrupted sutures. Ice cooling pack is applied for several hours after the procedure. The patients are usually admitted for 2 or 3 days but can leave the clinic 2 hours after surgery in case they don't want admission. The dressing is changed the next day. For the first 24 hours after surgery, patients are allowed to take limited amounts of soft diet. Oral antibiotics and pain killers are administrated for 3 days. All patients are recommended daily massage for facial lymphatic drainage starting from the fourth postoperative day for one week. All stitches are removed on day 7.

III. RESULTS

All the procedures were performed under local anesthesia with minimal sedation. For the first 3 days, most patients experienced mild pain in the temporal, cheek, and retroauricular region. Hematoma developed in two cases, which was evacuated on postoperative day 2. A temporary swelling of malar area, and cervicomandibular region were observed in all patients, which disappeared completely within 2 weeks. Most patients were able to return to their normal activities 1 week after surgery with the help of some camouflaging makeup. On postoperative day 14, all patients were able to go out without any makeup. Patients' satisfaction was relatively high. In all patients, the desired correction for the aging facial features was obtained and remained stable for the long time follow-up.

The limited dissection of this procedure provided reduction of the operative time (less than 2 hours), no skin necrosis and nerve damage, less hematoma formation. Good tightening on midface, nasolabial fold, periorbit, jowls and neck was obtained by this procedure. There were no skin notching, suture reaction and postauricular pleating. Most of all, we could achieve the stable balanced volumetric rejuvenation (Fig. 4, 5).

IV. DISCUSSION

When a face ages, solar damage, wrinkles, gravitational descent, and volume loss will occur. Traditionally, the Asian face is markedly different from the Caucasian in many respects that involve the skeletal and soft-tissue nature of the face. The resistance to aging in the Asian patient was credited to the thicker dermis of skin that contains greater collagen and the darker pigment that protects against photoaging and wrinkles. Asian face is subjected to a greater amount of gravitational force due to weaker skeletal support, heavier soft tissue, larger amount of malar fat, thicker skin, and a weaker chin. In most Asian patients, the skin is thicker and more fibrous than in the typical white patient. The Asian face tends to be wider and flatter than the Caucasian, similar to a toddler's broad face. Based on an understanding of the unique properties of the Asian face and of Asian aesthetics, the surgeons should embark upon a treatment strategy that is tailored to these considerations.⁵ Due to the anatomic differences between the Asian and Caucasian face outlined, facial aging processes are dissimilar. Because

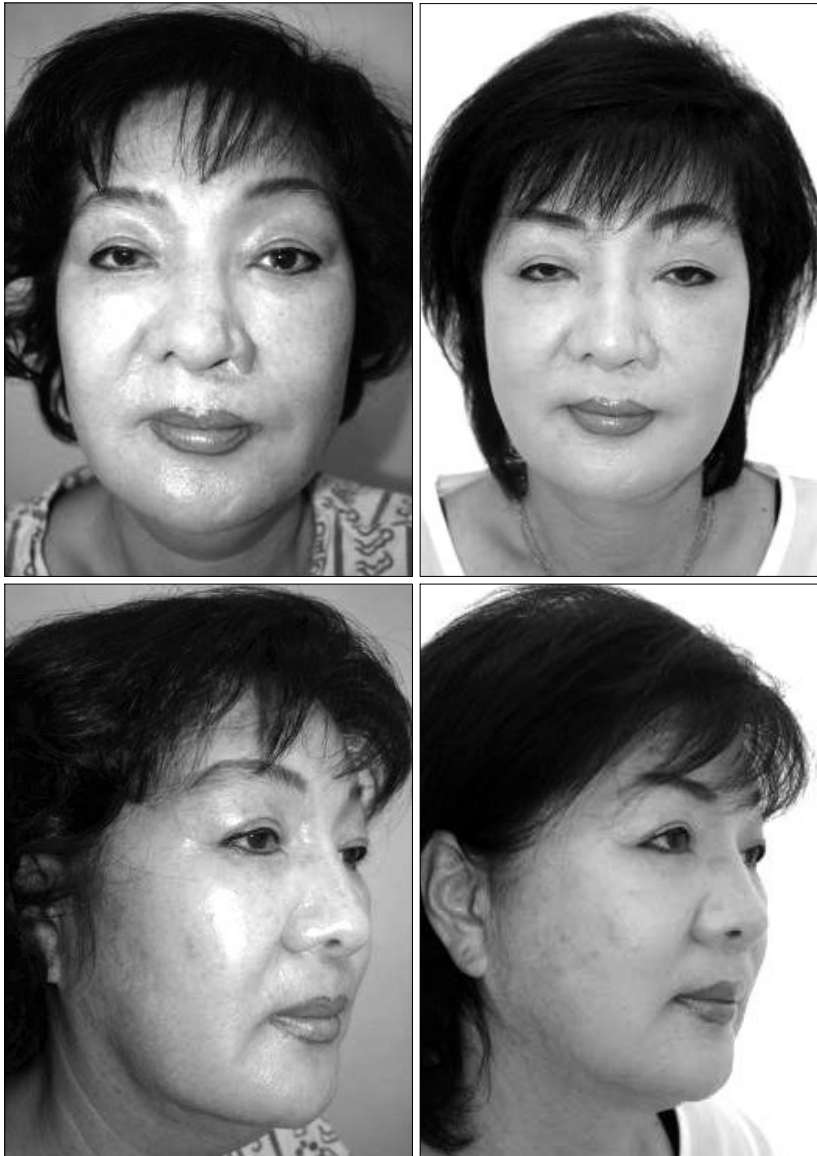

Fig. 4. Preoperative view of 56-year-old woman with moderate jowls and double chin with moderate anterior neck skin laxity (Above, Below, Left). Postoperative 1 year, appearance looks good lasting results after limited dissection face lift with 5 point PDS anchoring procedure (Above, Below, Right).

of the greater elastic nature and solar protection that the Asian skin affords, fewer rhytids arise than in Caucasians. Instead, the Asian face tends to age principally due to gravitational descent. The thicker skin, Bichad's fat pad contribute to considerable facial sagging.

Unfortunately, the history of rhytidectomy in Asia is considerably shorter than in the West. However, advanced techniques and a more open cultural environment have promoted a burgeoning growth in facial rejuvenative surgery. Therefore, following changes must be addressed, especially in Asian facelift procedures: (1) Volumetric deflation of the facial fat pad (fat atrophy) and its repositioning. This is particularly noticeable in the buccal area, which results in repositioning of the

upper lips. (2) The gravitational looseness of the facial ligaments, which results in sagging jowl and deepened nasolabial folds.⁵ Author's facial rejuvenation addresses all these concerns. This procedure results in a natural and youthful look. Most importantly, it is safe and gives quick postoperative recovery.

Several face lift techniques have been described through the years.^{3,5-9} They present different principles and ensure excellent effects. Tonnard MACS lift^{3,12} is fundamentally a pure antigravitational lifting procedure that will suspend the sagging soft tissues of the face and neck, together with the adhering skin, in a vertical direction into the place where they previously belonged. And this is a permanent purse-string suture to anchoring

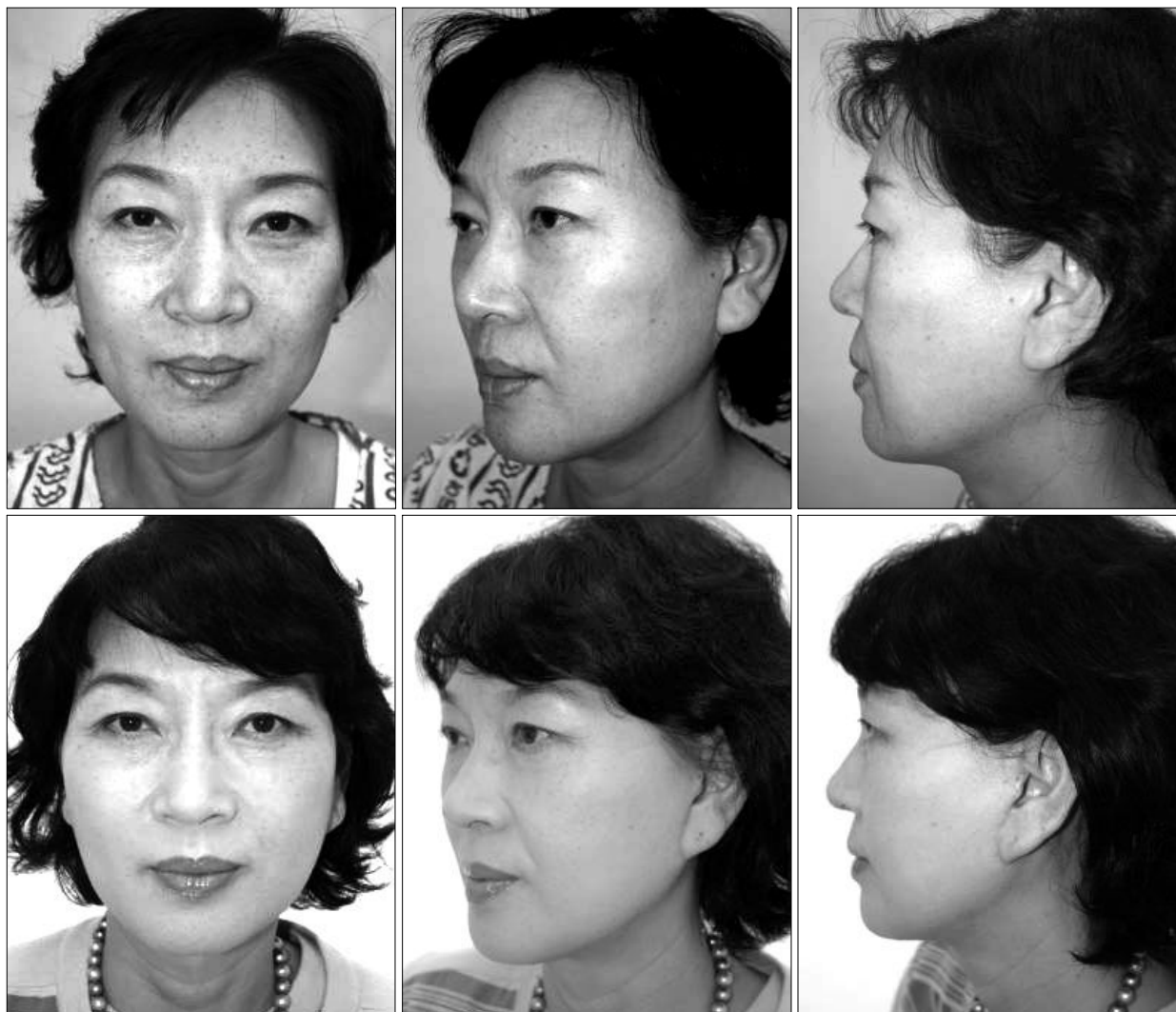

Fig. 5. Preoperative view of 56-year-old woman with skin laxity, moderate jowl, and mild dimple on cheek (Above). One year postoperative result: well corrected nasolabial fold, much improved cervicomandibular contour line. There are no visible scars on incision sites and pleating on postauricular area after limited dissection face lift with 5 point PDS anchoring suture procedure (Below).

sites. After tying this suture under maximum tension, a very effective elevation of the jowls is resulted.

Our technique intended to reinforce the suspension method. The laxity of the face does not occur in a single plane, nor does it occur only downward. Assuming this point of view, it is not ideal to handle the aging face using only one vector. To overcome this problem, our method is to stretch the subcutaneous tissue of face and anchor it to the strong tissues such as deep temporal fascia, periosteum of zygomatic arch, and mastoid. Using this procedure, a stable suture will be firmly attached to a strong region, thereby promoting face rejuvenation. Moreover, the undermined area will be limited, which

will allow relatively minor complications. The main difference between this technique and other suspension techniques is that sutures used to treat facial rhytids usually are made by anchoring on individualized vectors.

Five quilting sutures are used for correction of the lateral orbit, the middle third of face, the jowls and the neck. The first 3-0 PDS quilting suture is taken from the 1~2 cm posterior to the prominent area of the zygomatic body to the periosteum of zygomatic arch in the fashion of a narrow U-shaped loop. Tying of this suture under the proper tension produces a strong tightening effect of the midface. It also provides enhancement of the malar region. The second quilting suture is

taken from the Bichat's fat pad to the periosteum of the zygomatic arch, which produces suspension of Bichat's fat pad, inflation of cheek area, and correction of nasolabial fold. The third quilting suture is taken from the lateral border of the orbicularis oculi muscle to the deep temporalis fascia and it serves tightening of the lateral orbit. The fourth quilting suture is taken from upper lateral border of platysma to the periosteum of mastoid in the fashion of a narrow U-shaped loop. This fourth suture is better to tie with stronger tension for an oblique and vertical pulling on the lateral part of the platysma muscle, which tightens the cervicomental area and improves the jowls. The fifth suture is taken from anterior lower portion of the ear lobe to the deep temporal fascia for pure vertical vector. This fifth suture may not be needed in the patients under fifty years, but essential in elderly patients. The fifth quilting is useful for elevation of the sagging cheek tissue acting as a vertical vector. Careful attention to the tension and position of the quilting suture enhances the improvement of the infraorbital flattening as well as correction of the nasolabial fold and the jowls.

The trend in facial rejuvenation during the last decade has clearly been towards volume displacement¹⁰ or replacement⁴ instead of producing excessive tension in the face. For replacement of facial tissues, multiple dissection planes can be chosen. The ideal intervention should deliver the maximal efficiency with minimal risk. Limited subcutaneous dissection and direct suspension of the SMAS layer with such suture techniques as in this technique can allow a quick simple procedure and more safe result, which will guarantee predictable and stable rejuvenation with very swift recovery.

The use of quilting sutures provides many advantages. Weaving into the SMAS tissue with several firm quilting sutures, the pulling forces are distributed along the grabbed tissue of the quilting. The quilting sutures work as a facial resculpturing technique by imbrications of SMAS. And making them in the fashion of a narrow U-shaped loop can decrease the visible bowstring effect and skin notching. Quilting effects redistribute the loose SMAS layer into 3-4 SMAS folds, adhering to each other, and provide fibrotic 3-dimensional SMAS. This forms effective and stable traction on the SMAS tissue, which transmits its effect to each region of the face, such as the midface, the nasolabial fold, the Bichat's fat pad, lateral orbit, the jowl and neck. Thus, this procedure could promise a longer, permanent volumetric rejuvenating effect.

nating effect.

Our method can obtain an additional volumetric gain in the facial rejuvenation¹⁰ other than SMASectomy. The skin resection and redraping in the oblique and vertical vector act as a lock on the subcutaneous sculpturing. Finally the technique effectively redistributes the volume excess of labiomandibular region, jowl and the nasolabial fold. In the fatty lower face and neck or double chin, we could perform the recontouring with liposuction simultaneously. This could improve the cervicomandibular contour.

In quilting sutures, excessive tight tie must be avoided. Excessively tightened facial skin looks not natural. The suturing on the SMAS should be carefully performed in order to avoid injuries to the facial nerve branches. And it should be made only in SMAS layer superficially in order to prevent direct injury or compression of facial nerve branches. Under local anesthesia, It is possible to recognize the motor paralysis caused by impinging the nerve in the quilting suture site. The authors have not

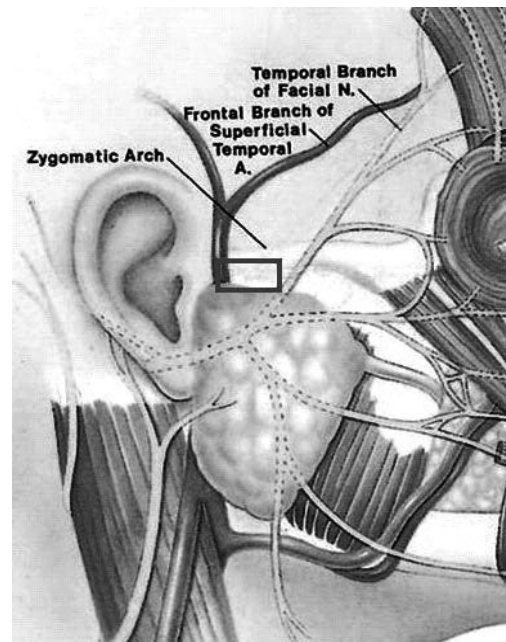


Fig. 6. Frontotemporal nerve triangle. Temporal branch of facial nerve divides into 2-4 branches at 2.2 ± 0.5 cm from the anterior rim of the bony external acoustic meatus, at 0.7 ± 0.2 cm from the lower aspect of the zygomatic arch. To prevent facial nerve injury, anchoring suture must be taken on this area (box area). The place of fixation for the sutures is the periosteum of the zygoma arch, which is free from vessels and nerves. (Lei T et al: The frontal-temporal nerve triangle; A new concept of locating the motor and sensory nerves in upper third of the face rhytidectomy. *Plast Reconstr Surg* 117: 385, 2006)

experienced a major motor or sensory nerve injury. Masterful knowledge of facial nerve and auricular nerve anatomy will prevent injury of their nerve branches. In one case, during the operation, the author recognized partial paralysis due to impinging of the marginal mandibular branch of the facial nerve after tightening, which we removed immediately and made another anchoring suture. Focusing on the prevention of these nerve injuries in rhytidectomy, the knowledge that there are no vessels and nerve branches in the frontotemporal nerve triangle¹¹ will help (Fig. 6). Accordingly, there will be no risk of facial nerve injury resulting from tightening of the SMAS quilting.

The advantages of the limited dissection face lift with PDS quilting suture include; achievement with local anesthesia, a quick procedure, no or short hospital stay and a swift recovery. Facial nerve injury and skin sloughing are unlikely to occur, and hematoma formation and postoperative numbness are significantly reduced because of limited dissection.

V. CONCLUSION

We recognized that limited dissection face lift with PDS quilting suture provided many advantages such as achievement under local anesthesia, a quick procedure, no or shorter hospital stay and a swift recovery period. Facial nerve injury and skin sloughing are unlikely to occur, and the incidence of hematoma formation and postoperative numbness are significantly reduced because of limited dissection.

The key elements in our procedure is performing strong quilting sutures on non-undermined SMAS layer and anchoring it to a fixed and rigid periosteum and temporal fascia. This produces effective and stable traction on the SMAS tissue, which transmits its effect to each region of the face, such as the midface, the nasolabial fold, the Bichat's fat pad, lateral orbit, the jaw and neck. Thus,

this procedure could promise a longer, permanent volumetric rejuvenating effect.

Our procedure may not replace the classic face lift, but be recommended as an option for patients who do not present with advanced facial aging or not want a more extensive procedure.

REFERENCES

1. Hamra ST: The tri-plane face lift dissection. *Ann Plast Surg* 12: 268, 1984
2. Saylan Z: Purse string-formed plication of the SMAS with fixation to the zygomatic bone. *Plast Reconstr Surg* 110: 667, 2002
3. Tonnard PL, Verpaele A, Gaia S: Optimising results from minimal access cranial suspension lifting (MACSLift). *Aesthetic Plast Surg* 29: 213, 2005
4. Coleman SR: Facial recontouring with lipostructure. *Clin Plast Surg* 24: 347, 1997
5. Sykes JM: Management of the aging face in the Asian patient. *Facial Plast Surg Clin North Am* 15: 353, 2007
6. Guerrerosantos J: Neck lift. simplified surgical techniques, refinements, and clinical classification. *Clin Plast Surg* 10: 379, 1983
7. Fulton JE, Saylan Z, Helton P, Rahimi AD, Golshani M: The S-lift facelift featuring the U-suture and O-suture combined with skin resurfacing. *Dermatol Surg* 27: 18, 2001
8. Stocchero IN: The RoundBlock SMAS Treatment. *Plast Reconstr Surg* 107: 1921, 2001
9. Tonnard P, Verpaele A, Monstrey S, Van Landuyt K, Blondeel P, Hamdi M, Matton G: Minimal access cranial suspension lift: A modified S-lift. *Plast Reconstr Surg* 109: 2074, 2002
10. Little JW: Three-dimensional rejuvenation of the midface: volumetric resculpture by malar imbrication. *Plast Reconstr Surg* 105: 267, 2000
11. Lei T, Gao JH, Xu DC, Zhong SZ, Li XJ, Chen B, Yang DY, Wang XH: The frontal-temporal nerve triangle; A new concept of locating the motor and sensory nerves in upper third of the face rhytidectomy. *Plast Reconstr Surg* 117: 385, 2006
12. Verpaele A, Tonnard P, Gaia S, Guerao FP, Pirayesh A: The third suture in MACS-lifting: making midface-lifting simple and safe. *J Plast Reconstr Aesthet Surg* 60: 1287, 2007