



Feeding Effect of an Anabolic Steroid, Nandrolone, on the Male Rat Testis*

Dong-Mok Lee^a, Taesun Min^{1,a}, Inho Choi, Yong-Pil Cheon², Taehoon Chun³,
Chang Sik Park⁴ and Ki-Ho Lee^{5,**}

School of Biotechnology, Yeungnam University, Gyeongsan 712-749, Korea

ABSTRACT : Nandrolone, 19-nortestosterone, is a synthetic androgenic-anabolic steroid promoting muscle growth. Nandrolone is also present in pig meat and sera at non-negligible levels. A number of scientific reports have suggested a positive relationship between incidence of infertility and increased meat consumption in humans. The present study was designed to determine out the effect of feeding nandrolone on the testis of the male reproductive tract. Mixtures of food and nandrolone at different concentrations (0.005 ppm and 0.5 ppm) were supplied to pubertal male rats for 6 weeks. Body weight was recorded every week during the entire experimental period. At the end of the treatment, the testis, epididymis, and epididymal fat were collected and weighted. Sperm numbers in the caudal epididymis were counted. Differential gene or protein expression of steroidogenic enzymes in the testes among experimental groups was determined by semi-quantitative real-time PCR or western blotting analysis, respectively. Histological changes of the testis induced by nandrolone treatment were examined by hematoxylin and eosin staining. Immunohistochemical analysis was employed to detect changes in the localization of steroidogenic enzymes in the testes among experimental animals. There were no significant changes on body, testis, epididymis, and epididymal fat weights among experimental groups. A significant increase of caudal sperm number was found in the 0.5 ppm nandrolone-treated group. Histological examination of the testes noted a high frequency of germ cell sloughing in seminiferous tubules of 0.5 ppm nandrolone-treated rats. Even though transcript levels of 3 β -hydroxysteroid dehydrogenase (HSD) I, 17 β -HSD4, and 17 α -hydroxylase were influenced by nandrolone treatments, protein levels of all molecules examined in the present study were not significantly affected. Immunohistochemical analysis showed no visible changes in the localization of steroidogenic enzymes in the testes among experimental groups. The current study showed that oral intake of nandrolone in male rats for 6 weeks did not cause significant damage to the testis. It is considered that a feeding effect of nandrolone on male fertility would not be remarkable. (**Key Words :** Nandrolone, Testis, Steroidogenic Enzymes, Testosterone, Fertility)

* This work was supported by ARPC (Agricultural R&D Promotion Center), Ministry for Agriculture, Forestry and Fisheries, Republic of Korea (108089-03-1-SB010) and the National Research Foundation of Korea (NRF) grants funded by the Korean Government (MEST) (20100001356 and 201000 16939).

** Corresponding Author : Ki-Ho Lee. Tel: +82-42-259-1643, Fax: +82-42-259-1649, E-mail: kiholee@eulji.ac.kr

¹ National Research Foundation of Korea (NRF), Daejeon 305-350, Korea.

² School of Biosciences and Chemistry, Center for NanoBio Applied Technology, Institute for Basic Sciences, Sungshin Women's University, Seoul 136-742, Korea.

³ School of Life Sciences and Biotechnology, Korea University, Seoul 136-701, Korea.

⁴ Division of Animal Science and Resources, Research Center for Transgenic Cloned Pig, Chungnam National University, Daejeon 305-764, Korea.

⁵ Department of Biochemistry and Molecular Biology and Medical Sciences Research Institute, College of Medicine, Eulji University, Daejeon 301-746, Korea.

^a These authors are equally contributed to this work.

Received August 3, 2010; Accepted September 6, 2010

INTRODUCTION

Anabolic-androgenic steroids (AAS) are synthetic analogs of testosterone. Thus, the AAS have structural and functional similarities with testosterone (Salas-Ramirez et al., 2008). The AAS promote muscle growth (anabolic effect) and have masculinizing effects through androgen receptor and androgen-response element in the target cells, similarly with testosterone (van Der, 1965). Of AAS, nandrolone, a.k.a. 19-nortestosterone (C₁₈H₂₆O₂), has a stronger anabolic capacity (about 5 times higher) than testosterone (Chrousos, 2006). Nandrolone is either chemically synthesized or naturally found in some mammals, including human and farm animals (Meyer et al., 1992; Schwarzenberger et al., 1993; Le Bizec et al., 1999). Especially, it is well documented that the edible parts of pig contain significant amount of anabolic steroids, including nandrolone (van Ginkel et al., 1989; Scarth et al., 2009). Several researches have reported the presence of

nandrolone-metabolites in human urine after ingestion of non-castrated boar meat (Pokrywka et al., 2009). These findings suggest that the intake of pork meat would result in non-intentional ingestion of exogenous nandrolone.

Nandrolone is frequently used to handle many clinical symptoms and diseases, such as osteoporosis in men (Hamdy et al., 1998), HIV-associated muscle wasting (Cuerda et al., 2005), growth deficiency (Ranke and Bierich, 1986), and anemia associated with chronic kidney failure (Basaria et al., 2001). In addition, nandrolone is utilized for testosterone-replacement therapy to treat prostate cancer and benign prostate hyperplasia (BPH), well known androgen-dependent diseases, because nandrolone could not be converted into dihydrotestosterone (DHT), most potent androgen (Kuhn, 2002). However, despite such therapeutic beneficial potentials, chronic and unregulated use of nandrolone result in undesirable outcomes, including hepatic toxicity (Yu-Yahiro et al., 1989), alternation of thyroid function (Fortunato et al., 2006), cardiovascular toxicities (Tseng et al., 1994). Prominent side effects of nandrolone misuse are also found in the reproduction of male and female. For examples, prolonged treatment of nandrolone in the male leads to altered testicular morphology (Takahashi et al., 2004), a decrease of testosterone secretion (Bijlsma et al., 1982), and reduction of sperm quality (Torres-Calleja et al., 2001). In female, administration of nandrolone causes disruption of estrus cycle, destruction of follicles in the ovary, morphological alteration of the uterus, and reduction of reproductive capacity (Gerez et al., 2005; Mobini Far et al., 2007). It is suggested that such deleterious effects of nandrolone on the reproductive tract would be due to a disruption of feedback regulation on hypothalamic-pituitary-gonadal axis by the exogenous agent (Karbalay-Doust et al., 2007). Koeva et al. (2003) have demonstrated that nandrolone treatment results in a decrease of 3β -hydroxysteroid dehydrogenase (HSD3B) activity in the testis, leading into a reduction of testosterone synthesis. However, a detailed mechanism about how nandrolone affects steroidogenesis in the testis is largely unknown.

Testosterone is a steroid hormone which plays the most important role in establishment of male phenotype and regulation of male reproduction during the development. Testosterone is mainly synthesized in the Leydig cells and influences spermatogenesis in the Sertoli cells of the testis. A number of steroidogenic enzymes are involved in the production of testosterone, including cytochrome P450 side chain cleavage (CYP11A1), cytochrome P450 17α -hydroxylase (CYP17), HSD3B, and 17β -HSD (HSD17B). Testosterone is metabolized into dihydrotestosterone (DHT) or 17β -estradiol (E_2) by the action of 5α -reductase or cytochrome P450 aromatase (CYP19), respectively. Thus, any effect on expression and/or function of these enzymes

could affect the production of testosterone and its metabolites in the testis. As described earlier, nandrolone could be chemically synthesized and naturally present in edible parts of pork. Most of published scientific data demonstrating on the effect of nandrolone on the testis have been obtained from intramuscular and/or subcutaneous treatment of nandrolone. However, none of researches has attempted to evaluate the effect of nandrolone on the testis via oral ingestion. Interestingly, an increasing number of recent researches have reported the presence of a closed correlation between consumption of meat and decreases of male fertility and semen quality (Swan et al., 2007; Mendiola et al., 2009).

Thus, the present research was designed to determine if treatment of nandrolone mixed with food gave an influence on the male reproduction. The feeding effect of nandrolone on the testis was evaluated by comparison of mRNA and protein levels of steroidogenic enzymes using semi-quantitative real-time PCR and western blotting analysis, respectively. In addition, immunohistochemical analysis was utilized to find out alteration of localization of these enzymes in the testis by feeding treatment of nandrolone. Moreover, measurement of sperm numbers in the caudal epididymis was made to assess the ingestional effect of nandrolone on spermatogenesis.

MATERIALS AND METHODS

Animals and nandrolone treatment

A total of 30 male Sprague Dawley rats at 5 weeks of age were purchased from Samtako (OSan, Korea). The rats were randomly divided into three experimental groups, control (n = 10), low dose nandrolone treatment (0.005 ppm) (n = 10), and high dose nandrolone treatment (0.5 ppm) (n = 10). Rats were individually housed under controlled conditions during the entire experimental period. To prepare nandrolone-containing food, the powdered rodent diet was purchased from Central Laboratory Animal Inc. (Seoul, Korea), and nandrolone was obtained from Tokyo Kasei Kogyo Co., Ltd. (Tokyo, Japan). A proper amount of nandrolone was thoroughly mixed with the powdered diet, and 100 g of the diet was supplied to each experimental animal every two days for 6 weeks. Before changing to a new food, amount of food left was recorded, and body weights of experimental animals were measured every week. Experimental animals were free to access to food and water for the entire experimental duration.

Tissue collection and total RNA and protein isolation

At the end of the experiment, animals were weighted and then anesthetized by CO₂ stunning. The male reproductive tract was collected, and wet weights of the testis, epididymis, and epididymal fat were measured and

recorded. A testis of a rat was fixed in Bouin's fixative for histological and immunohistochemical examination. The other testis of the rat was rapidly frozen in liquid nitrogen and kept in -80°C until used for total RNA and protein isolation. A caudal epididymis from each rat was separately collected, weighted, and stored in -20°C until used for sperm counting later.

Total RNAs from the testes were isolated by using Easy-Blue total RNA extraction solution (iNtRON Biotech., Sungnam, Korea). The isolated RNA pellets were dissolved and kept in RNA storage buffer (Ambion, Austin, USA) at -80°C until used for reverse transcription (RT) reaction. The quality and quantities of the total RNAs were determined by gel electrophoresis and an UV spectrophotometer (Eppendorf, New York, USA), respectively. To isolate proteins from the testes, the tissues were homogenized in ProPrep protein extraction solution (iNtRON Biotech., Sungnam, Korea). After ultracentrifugation at $16,609\times g$ (4°C) for 10 min, the supernatant was collected and stored in -80°C until used for western blotting analysis. The quantities of the proteins were measured by Bradford method (BioRad, Hercules, USA), with bovine serum albumin (BSA) as a standard. Protein samples were stored at -80°C until used for Western blot analysis.

Sperm counting in the caudal epididymis

The caudal epididymis was dissected out and cut into small pieces with a sharp knife in phosphate buffered saline (PBS) solution. Residual sperms remaining in the tissue pieces were drawn out by repeated pipetting. The PBS solution was collected in an eppendorf tube and centrifugated at 2,000 rpm for 10 min. A sperm pellet was suspended with 1 ml of PBS solution. A total number of sperm in the caudal epididymis was calculated by Makler counting chamber (Sefi-Medical Instruments Ltd., Santa Ana, USA). We repeated this procedure for 5 times to obtain a mean of total sperm number in a caudal epididymis.

Semi-quantitative real-time PCR analysis

The RT reaction was carried out according to the instruction in ImProm-IITM reverse transcription system (Promega, Madison, USA). Two micrograms of a total RNA were utilized for RT reaction in a total volume of 20 μl having oligo-dT primer. The RT reaction was performed at 25°C for 5 min, 42°C for 1 h, and 72°C for 15 min. The semi-quantitative real-time PCR was performed according to the instruction in GoTaq DNA polymerase (Promega, Madison, USA). Briefly, 1 μl of cDNA generated from the RT reaction was mixed with 0.75U of GoTaq DNA polymerase, 5 μl of $5\times$ buffer, 0.2 mM of dNTPs (Promega, Madison, USA), 2.5 μl of 3000X SYBR Green (BMA, Rockland, USA), 10 pmols of forward and reverse primers,

and dH_2O to make a total volume of 25 μl . The PCR was accomplished an initial pre-denaturation step at 95°C for 5 min, followed by denaturation at 94°C for 30 s, annealing at T_m for 30 s, and extension at 72°C for 30 s of cycles. The final extension step was performed at 72°C for 10 min at the end of each PCR using the PTC-200 Chromo 4 real-time system (Bio-Rad Laboratories, Hercules, USA). Oligonucleotide primers for PCR were obtained by using Primer 3 software (Whitehead Institute/MIT Center for Genomes Research, Cambridge, USA; <http://www.bioneer.co.kr/cgi-bin/primer/primer3.cgi>). The information of primers and T_m is summarized in Table 1. The sizes of PCR products were checked by fractionation on 1.0% agarose gel. In this analysis, we used Glyceraldehyde 3-phosphate dehydrogenase (*Gapdh*) as an internal PCR control. Quantifications of the PCR results were determined by the relative standard curve method to obtain quantitative values.

Western blot analysis

Forty micrograms of protein for each experimental animal were used for western blot analysis. The protein was fractionated on 12% SDS-PAGE polyacrylamide gel (Invitrogen, Carlsbad, USA) and transferred to a nitrocellulose membrane (Invitrogen). To block nonspecific binding of the primary antibody, the membrane was incubated in TBST (0.2 M Tris, 1.37 M NaCl, 0.05% Tween-20) with 1% BSA (Sigma, St. Louis, USA) at room temperature for 1 h. The membrane was immersed in primary antibody diluted in TBST at 4°C for overnight. The primary antibodies used for the present study were 1: 2,000 of polyclonal rabbit anti-CYP19 (a kind gift from Dr. Nobuhiro Harada, Fujita Health University, Japan), 1:4,000 of polyclonal rabbit anti-CYP11A1 (AB1244; Chemicon International, Inc., Temecula, USA), 1:5,000 of monoclonal mouse anti-HSD17B4 (a generous gift from Dr. Gabriele Möller, GSF-Research Center for Environment and Health, Neuherberg, Germany), 1:1,000 of polyclonal goat anti-CBR1 (ab4148; Abcam Ltd., Cambridge, United Kingdom), 1:1,000 of polyclonal rabbit anti-CYP17A (a great gift from Dr. Anita Payne, Stanford University, Stanford, USA), 1:500 of polyclonal rabbit anti-AKR1B1 (a precious gift from Dr. Motoko Takahashi, Saga University, Saga, Japan), and 1:1,000 of polyclonal rabbit anti-HSD3B (a benevolent gift from Dr. Ian Mason, University of Edinburgh, Edinburgh, United Kingdom). After washing with TBST for 3 times to remove residual primary antibodies, the membranes were incubated with a goat anti-rabbit or anti-mouse HRP-conjugated IgG or rabbit anti-goat HRP-conjugated IgG antibody (Santa Cruz Biotechnology, Inc., Santa Cruz, USA) diluted at 1:2,000 in TBST at room temperature for 1 h. Then, the membranes were washed with TBST for 4 times, and blotting results were detected

Table 1. Primer information for real-time PCR

Molecule	Forward primer (5'→3')	Reverse primer (5'→3')	T _m (°C)	Expected PCR size (bps)
<i>Cyp19</i> (M33986)	GCTTTCATCGCAGAGTATCCGG (1555-1577)	CAAGGGTAAATTCATTGGGCTTGG (1821-1844)	62	290
<i>Cyp11a1</i> (J05156)	AGGTGTAGCTCAGGACTT (530-547)	AGGAGGCTATAAAGGACACC (909-928)	52	399
<i>Cbr1</i> (BC105893)	GGAGAGGAGAGAGGACAAGAT (740-760)	TTCACCAAGTCAGGATAGAAGG (953-974)	52	235
<i>Hsd17b4</i> (NM_024392)	GCAAAGGTTCTTCATGGGG (1250-1268)	GTCCGTTTTCCACCAAAG (1450-1467)	55	218
<i>Hsd3b1</i> (M38178)	CCCATACAGCAAAAGGATGG (636-655)	GCCGCAAGTATCATGACAGA (766-785)	55	150
<i>Akr1b1</i> (BC062034)	CACGCAGAAGTCTGAAGCTG (960-979)	AGAAAGGCCGAAGAACTCC (1140-1159)	55	200
<i>Cyp17</i> (M31681)	AGATTGACCAGTACGTAGGCTTC AGCCGAA (1031-1060)	CACATCCAAGTCAAACCTCT GCAGTAGC (1413-1440)	67	410
<i>Gapdh</i> (X02231)	CCCCTGGCCAAGGTCATCCATG ACAACCTT (540-569)	GGCCATGAGGTCCACCACC CTGTTGCTGTA (1023-1052)	60	513

Cyp19: cytochrome P450 Aromatase, *Cyp11a1*: cytochrome P450 side chain cleavage, *Cbr1*: carbonyl reductase 1, *Hsd17b4*: 17 β -hydroxysteroid dehydrogenase type 4, *Hsd3b1*: 3-beta-hydroxysteroid dehydrogenase/delta-5-delta-4 isomerase type 1, *Akr1b1*: aldo-keto reductase family 1, member B1 (aldose reductase), *Cyp17*: cytochrome P450 17 α -hydroxylase, *Gapdh*: Glyceraldehyde 3-phosphate dehydrogenase.

with the enhanced chemiluminescence detection system (Amersham Biosciences, Pittsburgh, USA). We used GAPDH (SC-25778; Santa Cruz Biotechnology), as an internal control for the analysis. The results were analyzed using Image J, released from the National Institutes of Health (Bethesda, USA; <http://rsb.info.nih.gov/ij/download.html>).

H&E staining and immunohistochemical analysis

The testes were fixed in Bouin's solution for 22-24 h at room temperature and transferred into 70% ethanol. The testes were dehydrated in a series of ethanol (80, 90, 95, and 100% ethanol) and cleared with xylene. Then, the testes were infiltrated with paraffin at 60°C for 3 h and embedded in paraffin blocks. Tissue sections were made in 5 μ m thickness. For H&E staining to examine histological and morphological changes in the testes of nandrolone-treated animals, tissue sections were deparaffinized in xylene and then rehydrated in a series of ethanol and water. Tissue sections were stained with hematoxylin, followed by counter-staining with eosin. Sections were dehydrated in a series of ethanol, cleared with xylene, and mounted with cover glasses. The tissue sections were examined under light microscopy. Expression and localization of steroidogenic enzymes and steroid hormone metabolism-related molecules in the testis were determined by immunohistochemistry. Antigen retrieval of deparaffinized and rehydrated tissue sections was performed with simmering in 0.01 M citrate buffer for 10 min. After cooling down at room temperature, the sections were immersed in

0.3% H₂O₂/methanol for 15 min. Ten percentages of normal serum, goat (Chemicon International, Temecula, USA) or rabbit serum (Jackson ImmunoResearch Laboratories Inc., West Grove, USA), was applied to sections for 30 min at room temperature to block non-specific binding of the primary antibody. The sections were incubated in the primary antibody in humidified chamber at 4°C for overnight. We used same antibodies utilized for Western blot analysis, but at different concentrations; 1:100 for CYP19, 1:1,000 for CYP11A1, 1:200 for HSD17B4, 1:500 for CBR1, 1:500 for CYP17A, 1:200 for AKRIB1, and 1:500 of HSD3B. The same dilution of normal rabbit, mouse (Chemicon), or goat serum, in the place of primary antibody, was applied to negative control sections. Excess primary antibodies were removed by washing with PBS for 3 times, biotin-conjugated secondary antibody was applied to the sections at room temperature for 1 h. Unbound excess secondary antibodies were rinsed in PBS for 3 times, and elite avidin-biotin peroxidase (Vector Laboratories, Burlingame, USA) was put on the sections for 30 min. After washing in PBS for a couple of times, the sections were treated with a mixture of 3,3'-diaminobenzidine (Sigma), 0.05 M Tris-HCl buffer, and 5% H₂O₂ to detect color reaction of the peroxidase. Then the tissue sections were counterstained with hematoxylin, dehydrated in a series of ethanol, and mounted with cover glasses. Representative H&E and immunohistochemistry digital pictures were captured with Olympus-CoolSNAP cf color/OL camera (Olympus America, Melville, USA) using RSIimage version 1.1 software (Roper Scientific, Duluth, USA) and processes

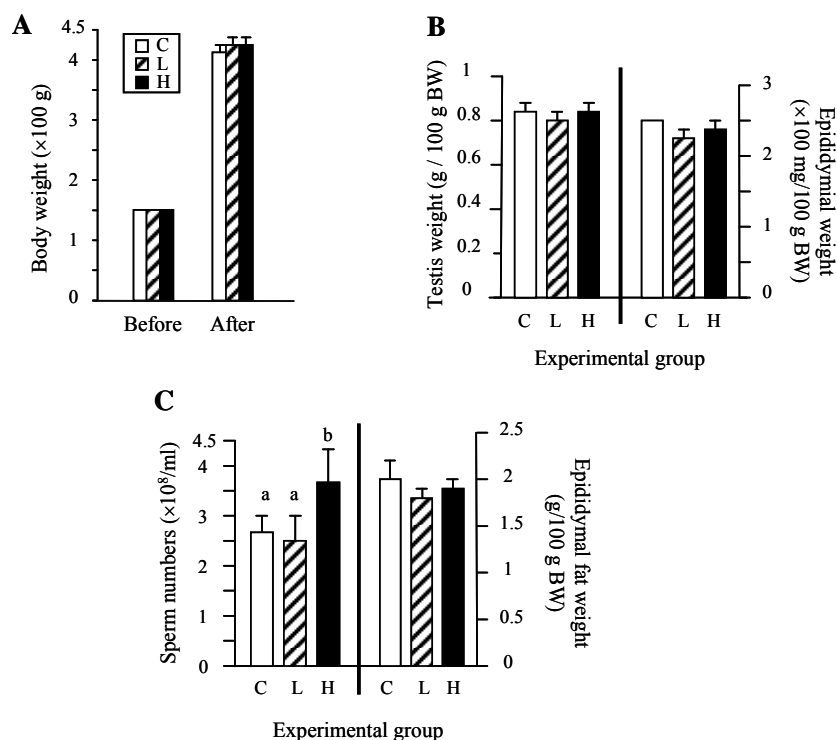


Figure 1. Feeding effects of nandrolone on body, testis, epididymis, and epididymal fat weight and sperm numbers in caudal epididymis. A) change of body weight, B) changes of the testis and epididymis weights, and C) changes of sperm numbers in the caudal epididymis and epididymal fat weight. C: Control group, L: Low dose nandrolone feeding group, and H: High dose nandrolone feeding group. Different letters in graphs indicate significant difference at $p < 0.05$ level.

in PhotoShop software (Adobe Systems, San Jose, USA).

Data analysis and presentation

For semi-quantitative real-time PCR analysis, each sample was repeated the RT and PCR reactions for 3-4 times to obtain a mean and standard error of an experimental group. The normalized mean value to *Gapdh* mRNA was used for comparison of mRNA expression level of the molecule. For western blot analysis, we repeated each sample for 3 times, and a mean value normalized to GAPDH was used for the final comparison. Data for mRNA expression levels were expressed relative to *Gapdh* as arbitrary units. Abundance of protein was expressed relative to normalized value of control group as arbitrary units. Statistical comparison of mean differences among experimental groups was conducted by 2-way analysis of variance, followed by Tukey's test, using SPSS software (SPSS Inc., Chicago, USA). In all cases, results were considered significant if $p < 0.05$.

RESULTS

Effects of nandrolone on body, testis, epididymis, and epididymal fat weights and caudal sperm number

There was no significant change on body weight among experimental groups after feeding treatment of nandrolone

for 6 weeks, regardless doses of nandrolone treated (Figure 1A). In the male reproductive tract, wet weights of the testis and epididymis of nandrolone treated groups were not significantly different with those of control group (Figure 1B). Interestingly, however, caudal sperm number was significantly increased in a high dose nandrolone treated group, while no change on the epididymal fat weight among experimental groups was found (Figure 1C).

Effect of nandrolone on histological change of the testis and expression of cytochrome P450 side chain cleavage (CYP11A1)

Feeding treatment of nandrolone at a low concentration (0.005 ppm) for 6 weeks did not cause visible histological change in the testis (Figure 2A). Light microscopic examination revealed that appearance and morphology of the testis of the low dose nandrolone treated animal were similar with those in the control animal (Figure 2A). In the testis of high dose nandrolone treated animal, the Leydig cell was appeared to be histologically normal (Figure 2A). However, a high frequency of germ cell sloughing (detachment of germ cells from the Sertoli cells) in the seminiferous tubules of the testis was found in nandrolone treated group at high dose (Figure 2A).

Examination of *Cyp11a1* gene expression showed no significant change among experimental groups (Figure 2B).

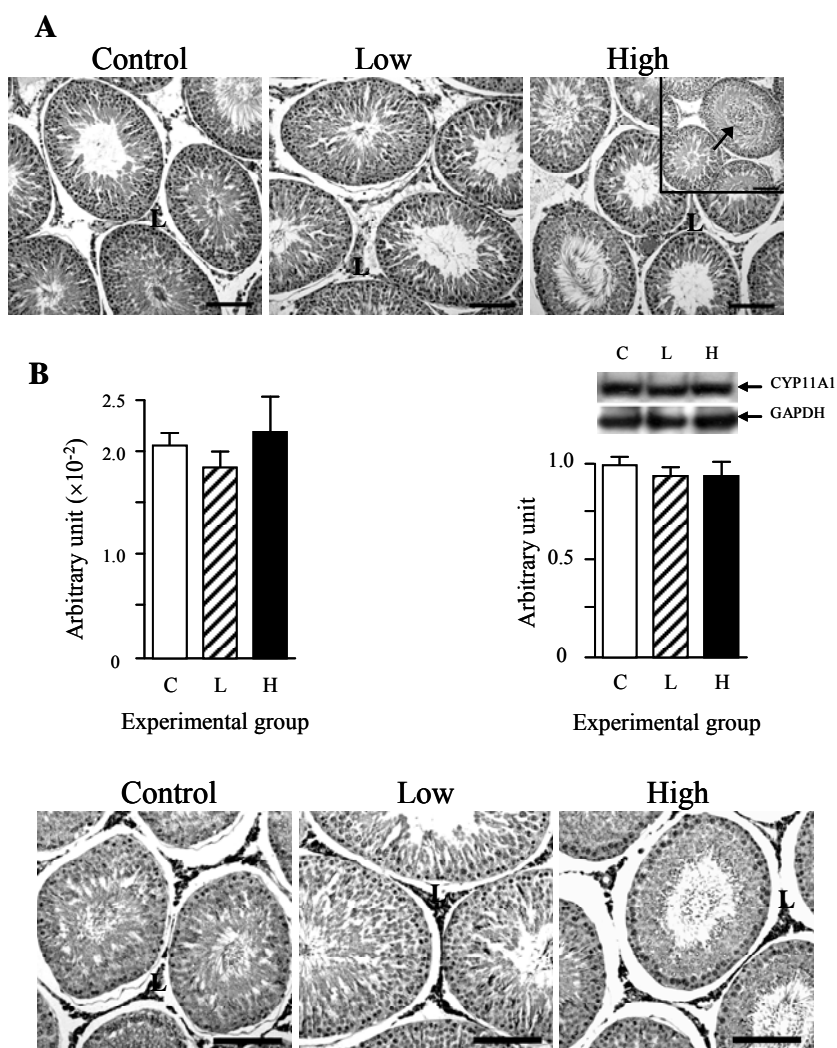


Figure 2. Histological examination of the testes and expressional change of cytochrome P450 side chain cleavage in the testis. A) H&E pictures of the testes and B) comparison of mRNA and protein levels and immunohistochemical localization of CYP11A1 in the testes. C: Control group, L: Low dose nandrolone feeding group, and H: High dose nandrolone feeding group. An arrow indicates sloughing of epithelial and germ cells in the seminiferous tubules. L: Leydig cell. Bars indicate 100 μ m.

Also, western blot analysis revealed that CYP11A1 protein abundance was not significantly different among experimental groups (Figure 2B). Immunohistochemical analysis exhibited an exclusive localization of CYP11A1 in the Leydig cells, while no immuno-reactivity was detected in the seminiferous tubules of the testis (Figure 2B and

Table 2. Summary of immunohistochemical analysis

Molecule	Leydig cells	Sertoli cells	Germ cells
CYP19	+	+/- ^b	+/- ^a
CYP11A1	+	-	-
CBR1	+	-	-
HSD17B4	+ ^b	-	+/- ^a
HSD3B1	+	-	-
AKR1B1	+/-	+	-
CYP17	+	-	+/- ^a

CYP19: cytochrome P450 Aromatase, CYP11A1: cytochrome P450 side chain cleavage, CBR1: carbonyl reductase 1, HSD17B4: 17 β -hydroxysteroid dehydrogenase type 4, HSD3B1: 3-beta-hydroxysteroid dehydrogenase/delta-5-delta-4 isomerase type 1, AKR1B1: aldo-keto reductase family 1, member B1 (aldose reductase), CYP17: cytochrome P450 17 α -hydroxylase.

^a Indicates germ cells at specific spermatogenic stage. ^b Indicates that all cells are not evenly immuno-positive.

+: positive, +/-: weakly positive, -: negative.

Table 2). In addition, there was no visible difference on the intensity of positive staining of CYP11A1 among experimental groups (Figure 2B).

Effect of nandrolone on expression of cytochrome 17 α -hydroxylase (CYP17) and 3 β -hydroxysteroid dehydrogenase 1 (HSD3B1)

Expression of *Cyp17* gene was significantly decreased with nandrolone feeding at low dose, while expressional

level of *Cyp17* mRNA was not affected by high nandrolone feeding treatment, compared with that of control group (Figure 3A). However, protein levels of CYP17 among experimental groups were not significantly different (Figure 3A). Immunohistochemical examination showed a strong positive staining of CYP17 in the Leydig cells of the testis (Figure 3A and Table 2). Interestingly, germ cells, but not Sertoli cells, in the seminiferous tubules were weakly positive for CYP17 (Figure 3A and Table 2).

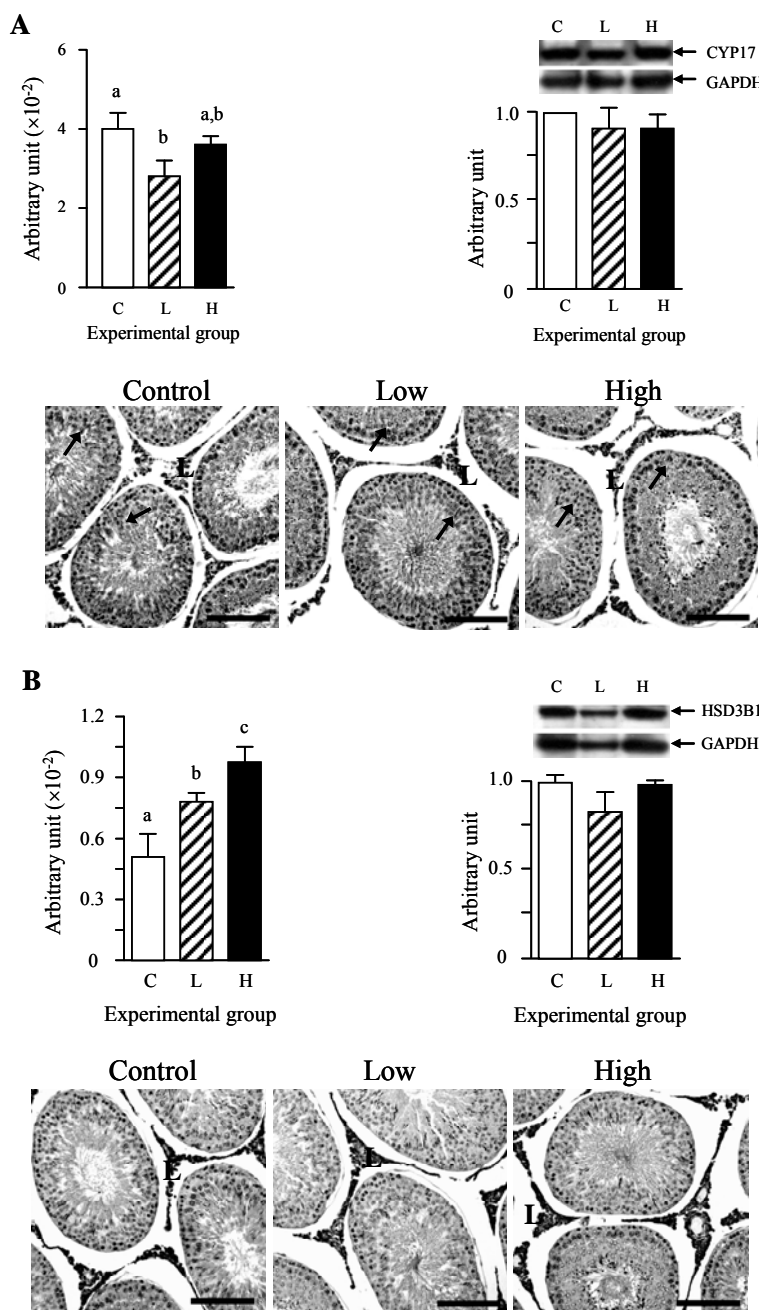


Figure 3. Effect of nandrolone feeding on 17 α -hydroxylase and 3 β -HSD 1 expression in the testis. A) comparison of mRNA and protein levels and immunohistochemical localization of CYP17 in the testes and B) comparison of mRNA and protein levels and immunohistochemical localization of HSD3B1 in the testes. C: Control group, L: Low dose nandrolone feeding group, and H: High dose nandrolone feeding group. L: Leydig cell. Bars indicate 100 μ m. Arrows indicate positive immuno-reaction in germ cells.

Abundance of *Hsd3b1* mRNA was significantly increased in low nandrolone treated group, compared with that of control group (Figure 3B). A further significant increase of *Hsd3b1* mRNA level was observed in the testis of high nandrolone treated group (Figure 3B). However, no significant change of HSD3B1 protein levels was found among experimental groups (Figure 3B). A strong immuno-reaction of HSD3B1 in the testis was exclusively shown in the Leydig cells, and there was no visible difference in an intensity of positive-staining of HSD3B1 among experimental groups (Figure 3B and Table 2). Other cell types in the testis were immuno-negative for HSD3B1 (Figure 3B and Table 2).

Effect of nandrolone on expression of 17 β -hydroxysteroid dehydrogenase 4 (HSD17B4) and cytochrome P450 aromatase (CYP19)

The level of *Hsd17b4* mRNA in a low nandrolone treated group was not significantly different with that in control group, while a feeding treatment with nandrolone at a high dose resulted in a significant increase of *Hsd17b4* transcript level (Figure 4A). Like other steroidogenic enzymes mentioned above, there was no significant change in protein levels among experimental groups (Figure 4A). Immunohistochemical analysis of HSD17B4 revealed a weak positive staining in the Leydig and germ cells, but immuno-negative in the Sertoli cells of the testis (Figure 4A and Table 2). Especially, the presence of HSD17 protein in the seminiferous tubules was restricted in specific types of germ cells (Figure 4A).

Semi-quantitative real-time PCR analysis showed that there was no significant expressional change of *Cyp19* gene among experimental groups (Figure 4B). A similar finding was detected on protein level of CYP19 (Figure 4B). The localization of CYP19 in the testis was observed in the Leydig cells, as well as in the Sertoli and certain germ cells (Figure 4B and Table 2). However, an intensity of immuno-reactivity of CYP19 was stronger in the Leydig cells than the Sertoli and germ cells (Figure 4B). There was no notable difference in immuno-staining quantity among experimental groups (Figure 4B).

Effect of nandrolone on expression of aldose reductase (AKB1B1) and carbonyl reductase 1 (CBR1)

Like *Cyp19* gene, the feeding treatment of nandrolone didn't have an influence on gene expression of *Akb1b1* in the testis (Figure 5A). Similarly, the protein levels of AKB1B1 were not affected by nandrolone treatment, compared with that in control group (Figure 5A). However, unlike other molecules tested in the present study, a strong immuno-positive reaction of AKB1B1 in the testis was observed in the Sertoli cells, while the Leydig cells were weakly positive and germ cells were clearly immuno-

negative (Figure 5A and Table 2). However, there was no observable difference on immuno-reactivity of AKB1B1 among experimental groups (Figure 5A).

Expression of *Cbr1* gene was not affected by nandrolone treatment (Figure 5B). Also, the levels of CBR1 protein of nandrolone treated groups were not significantly different with that of control (Figure 5B). However, localization of CBR1 in the testis was different with AKB1B1. A strong immuno-reactivity was exclusively detected in the Leydig cells of the testis (Figure 5B and Table 2). Neither the Sertoli cells nor the germ cells in the seminiferous tubules were negative for immuno-staining of CBR1 (Figure 5B and Table 2).

DISCUSSION

Nandrolone is an anabolic steroid which is present in the edible parts of pork at non-negligible amounts. The present study was attempted to determine if nandrolone ingested orally with food for 6 weeks affects the male reproductive capacity, especially focused on steroidogenesis and sperm production in the testis. Results obtained from the current research are summarized as following; i) no influence on body, testis, epididymis, and epididymal fat weights, ii) a significant increase of sperm number in the caudal epididymis and histological abnormality in the testis with 0.5 ppm treatment, iii) no significant changes on mRNA and protein levels of most steroidogenic enzymes, except *Cyp17*, *Hsd3b1*, and *Hsd17b4* mRNAs, iv) no visible changes on localization of steroidogenic enzymes in the testis, and v) no impact on male and female fertilizing capacities.

Nandrolone is intramuscularly administrated to treat various medical symptoms. For example, nandrolone is used to compensate HIV-associated wasting by increasing muscle and lean body mass (Corcoran and Grinspoon, 1999). Nandrolone treatment usually causes a significant decrease of total body weight (Yu-Yahiro et al., 1989; Takahashi et al., 2004). However, Karbalay-Doust and Noorafshan (2006) have reported no change on body weight with nandrolone treatment. These dissimilar observations would be due to different duration (long or short) and/or doses (high or low) of nandrolone treatment. In the present study, feeding treatment of nandrolone didn't affect on a change of body weight during postnatal development. Consumption of pork tissues results in increased levels of weak nandrolone metabolites, such as 19-norandrosterone and/or 19-noretiocholanolone, in urine (Le Bizec et al., 1999). Thus, it is speculated that most of nandrolone ingested orally would be converted into these metabolites in the liver and excreted in urine, in prior to giving an influence to body weight. In addition, we can't rule out a possibility that a length of oral nandrolone treatment would

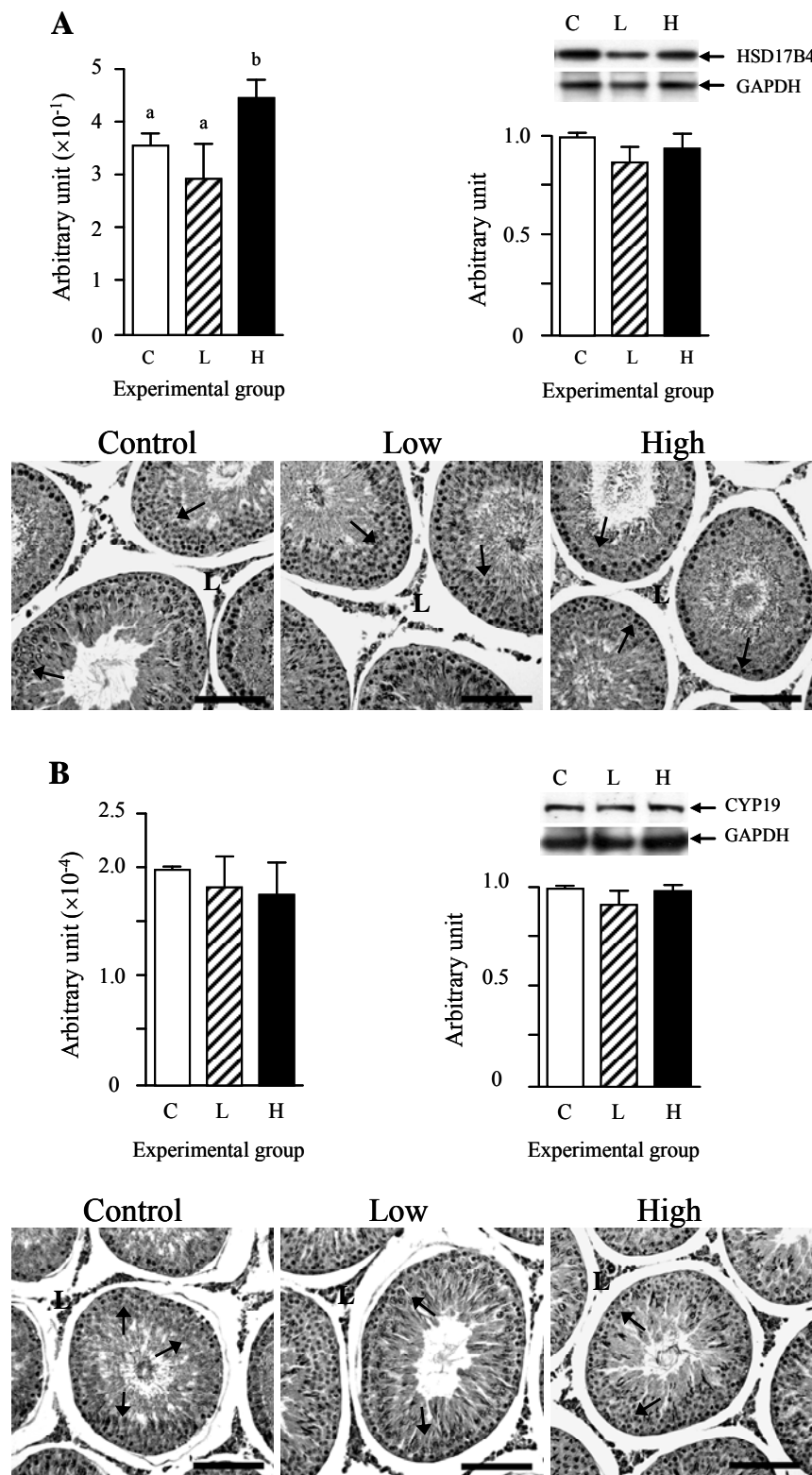


Figure 4. Expressional changes of 17 β -HSD 4 and cytochrome P450 aromatase in the testis. A) comparison of mRNA and protein levels and immunohistochemical localization of HSD17B4 in the testes and B) comparison of mRNA and protein levels and immunohistochemical localization of CYP19 in the testes. C: Control group, L: Low dose nandrolone feeding group, and H: High dose nandrolone feeding group. L: Leydig cell. Bars indicate 100 μ m. Different letters in graph indicate significant difference at $p < 0.05$ level.

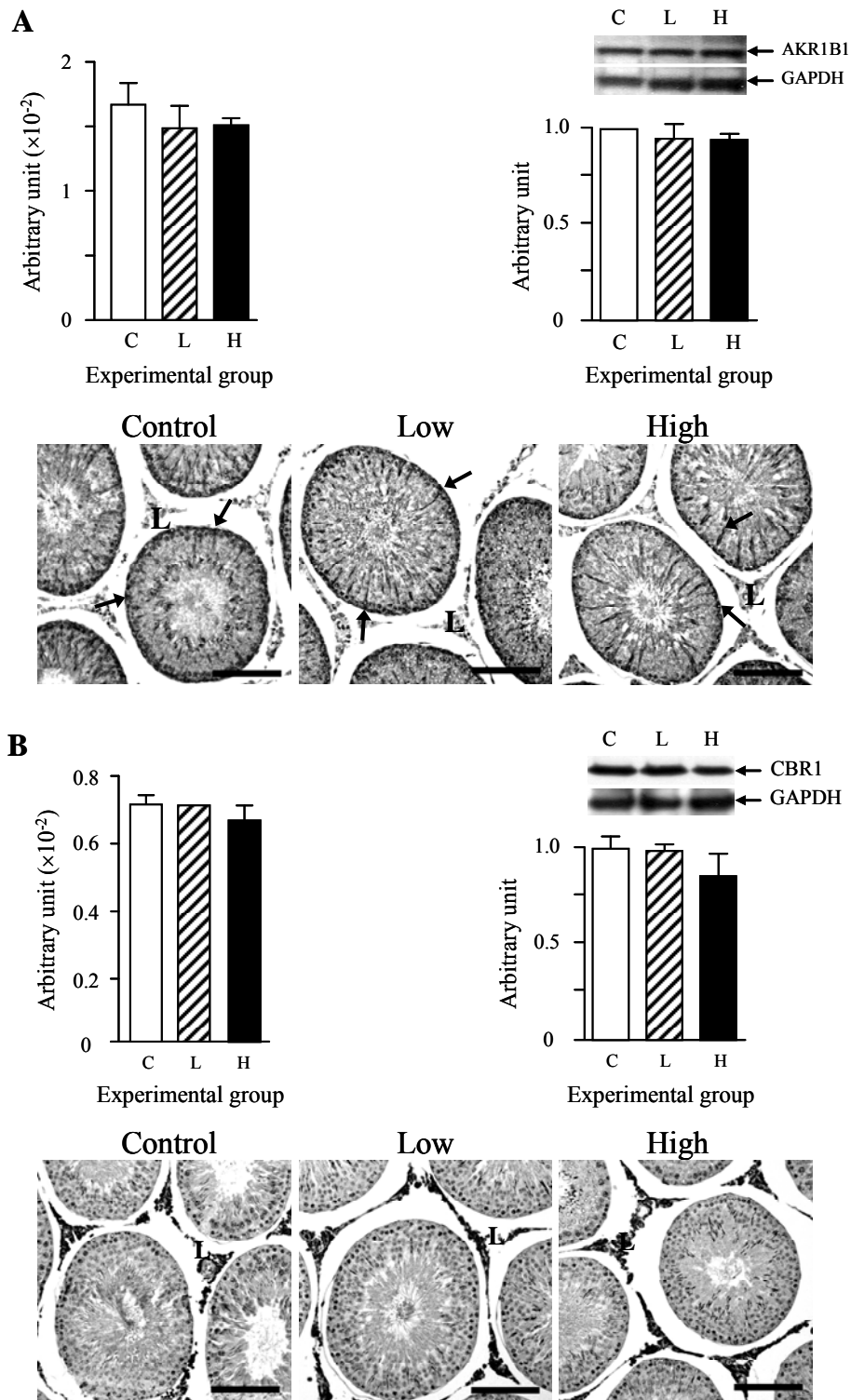


Figure 5. Expressional changes of aldose reductase and carbonyl reductase 1 in the testis after feeding treatment of nandrolone. A) comparison of mRNA and protein levels and immunohistochemical localization of AKR1B1 in the testes and B) comparison of mRNA and protein levels and immunohistochemical localization of CBR1 in the testes. C: Control group, L: Low dose nandrolone feeding group, and H: High dose nandrolone feeding group. L: Leydig cell. Bars indicate 100 μ m. Arrows indicate positive immuno-reaction in the Sertoli cells.

not be sufficient to affect body weight. An effect of nandrolone ingested orally on change of body weight is remained to be investigated in a future study.

The adverse effects of nandrolone on the testis have been demonstrated from a number of researches. Prolonged and uncontrolled use of nandrolone cause various histological and morphological abnormalities in the testis, including reduction of testicular volume and seminiferous tubule length (Noorafshan et al., 2005), germ and Sertoli cells' sloughing (Takahashi et al., 2004), and severe depletion of Leydig cells in the interstitial compartment (Nagata et al., 1999). Also, it is well recognized that a long-term use of nandrolone frequently results in male infertility, as a predominant side effect (Lombardo et al., 2005). Moreover, treatment with relatively high doses of nandrolone leads into decreases of testis and epididymal weights, sperm number, and sperm motility (Takahashi et al., 2004; Noorafshan et al., 2005; Karbalay-Doust et al., 2007). In the present study, we found no change on testis and epididymal weights and fertilizing capacity in male. However, feeding treatment of a high dose of nandrolone resulted in a significant increase of sperm number. This result is opposite to those shown by other studies (Karbalay-Doust et al., 2007). There is no clear explanation to justify the different results at this point. One of significant differences between the present and other studies could be the sources of sperms utilized to count the number. In the present study, sperm number in the caudal epididymis was counted, while others measured sperm numbers in the testis. But, this experimental difference could not give an apparent reason to acquire opposite results in change of sperm number by nandrolone treatment. This question would be determined by further detailed examination in the future. In the testis, even though clear morphological change on Leydig cells was not observed, sloughing of Sertoli and germ cells was frequently found with the high dose treatment of nandrolone. Similar phenomenon is commonly observed in the testis by nandrolone treatment (Takahashi et al., 2004). These findings imply that oral ingestion of nandrolone at high dose could affect histology of the testis, so thus possibly male fertility if the testis is exposure to oral-intake nandrolone at high amount for prolonged period.

Intramuscular administration of nandrolone alters gene expression and protein levels of various steroidogenic enzymes in the testis. Nagata et al. (1999) have demonstrated that nandrolone treatment in the stallion results in obvious decreases of immune-reactivity of CYP19 and HSD3B in the interstitial compartment of the testis. Chronic treatment of nandrolone causes a significant decrease of *Hsd17b3* mRNA level, while expression of other steroidogenic enzymes, *Cyp17*, *Hsd3b*, *Cyp11a1*, and *Cyp19*, has not been affected (Alsiö et al., 2009). In the present study, we found that mRNA levels of *Cyp17*,

Hsd3b1, and *Hsd17b4* were changed by feeding treatment of nandrolone. In the other hand, gene expression of *Cyp11a1*, *Cyp19*, *Akr1b1*, and *Cbr1* was not affected in the present research. Especially, an expressional pattern of *Hsd3b1* in the present study was different to that found from Alsiö et al. (2009). It is speculated that methodological difference of nandrolone treatment would produce such different experimental results. In the current research, there was no change at protein levels of all molecules tested. However, visible decreases of HSD3B and CYP19 protein levels have been detected by intramuscular treatment of nandrolone (Nagata et al., 1999). Such disagreement in the change of HSD3B protein level with nandrolone treatment is most likely due to different treatment methods. It is supposed that nandrolone ingested with food would be quickly absorbed and delivered to the liver, at which nandrolone is metabolized into weak anabolic androgenic steroids, while intramuscularly administrated nandrolone would directly go to the testis via the bloodstream and affect gene expression in the testis before nandrolone is converted into weak metabolites. However, we cannot rule out a possibility that ingestion of high amounts of nandrolone could influence protein levels of steroidogenic enzymes in the testis, so thus male fertility. An additional research is suggested to examine the feeding effect of higher nandrolone doses on the testis.

The caviar of the present study is the first attempt to determine the feeding effect of nandrolone on the testis of the male reproductive tract. An increasing attention has been focusing into the relationship between meat consumption and semen quality (Swan et al., 2007; Mendiola et al., 2009). These researches reach a common conclusion, which is that an increasing meat intake may alter male's testicular development and function and so thus male fertility (Swan et al., 2007; Mendiola et al., 2009). As stated in the introduction, most edible parts of pigs, including muscle and liver, contain non-negligible amount of nandrolone, ranged 1.1 to 200 mg/kg (Van Ginkel et al., 1989). There is no doubt that consumption of pork by people has been increasing every year. Thus, human being has more chance to be exposed to higher exogenous anabolic androgenic steroids present in pork. Even though the present study has not clearly demonstrated a harmful effect of oral ingestion of nandrolone on the testis, results from the current researches would suggest that large consumption of pork meat could give an influence on the testis, so thus male fertilizing capacity, in part.

In conclusion, from the present study, it is not conclusive if oral feeding of nandrolone directly affects the male fertility at the current point. However, morphological abnormality and aberrant gene expression in the tests at a high dose of nandrolone ingested orally may imply a negative relationship between pork consumption and male fertility.

REFERENCES

- Alsio, J., B. Carolina, L. Björkblom, P. Isaksson, L. Bergström, H. B. Schiöth and J. Lindblom. 2009. Impact of nandrolone decanoate on gene expression in endocrine systems related to the adverse effects of anabolic androgenic steroids. *Basic Clin. Pharmacol. Toxicol.* 105:307-314.
- Basaria, S., J. T. Wahlstrom and A. S. Dobs. 2001. Clinical review 138: Anabolic-androgenic steroid therapy in the treatment of chronic diseases. *J. Clin. Endocrinol. Metab.* 86:5108-5117.
- Bijlsma, J. W., S. A. Duurmsma, J. H. Thijssen and O. Huber. 1982. Influence of nandrolone decanoate on the pituitary-gonadal axis in males. *Acta Endocrinol. (Copenh.)* 101:108-112.
- Chrousos, G. P. 2006. The gonadal hormones and inhibitors. In: *Basic and Clinical Pharmacology* (Ed. B. G. Katzung). McGraw-Hill Professional, New York, USA. pp. 674-676.
- Corcoran, C. and S. Grinspoon. 1999. The use of testosterone in the AIDS wasting syndrome. *AIDS Clin. Care* 11:25-26.
- Cuerda, C., A. Zugasti, I. Bretón, M. Camblor, P. Miralles and P. Garcia. 2005. Treatment with nandrolone decanoate and megestrol acetate in HIV-infected men. *Nutr. Clin. Pract.* 20:93-97.
- Hamdy, R. C., S. W. Moore, K. E. Whalen, C. Landy and J. H. Quillen. 1998. Nandrolone decanoate for men with osteoporosis. *Am. J. Ther.* 5:89-95.
- Fortunato, R. S., M. P. Marassi, E. A. Chaves, J. H. M. Nascimento, D. Rosenthal and D. P. Carvalho. 2006. Chronic administration of anabolic androgenic steroid alters murine thyroid function. *Med. Sci. Sports Exerc.* 38:256-261.
- Gerez, J. R., F. Frei and I. C. C. Camargo. 2005. Histological assessment of ovaries and uterus of rats subjected to nandrolone decanoate treatment. *Contraception* 72:77-80.
- Karbalay-Doust, S. and A. Noorafshan. 2006. Stereological study of the effects of nandrolone decanoate on the rat prostate. *Micron* 37:617-623.
- Karbalay-Doust, S., A. Noorafshan, F. M. Ardekani and H. Mirkhani. 2007. The reversibility of sperm quality after discontinuing nandrolone decanoate in adult male rats. *Asian J. Androl.* 9:235-239.
- Koeva, Y. A., K. N. Georgieva, P. K. Atanassova and S. D. Delchev. 2003. Effects of submaximal training and anabolic androgenic steroids administration on steroidogenic enzyme activity in rat Leydig cells. *Folia Med. (Plovdiv)*. 45:37-40.
- Kuhn, C. M. 2002. Anabolic steroids. *Recent Prog. Horm. Res.* 57:411-434.
- Le Bizec, B., F. Monteau, I. Gaudin and F. André. 1999. Evidence for the presence of endogenous 19-norandrosterone in human urine. *J. Chromatogr. B. Biomed. Sci. Appl.* 723:157-172.
- Lombardo, F., P. Sgrò, P. Salacone, B. Gilio, L. Gandini, F. Dondero, E. A. Jannini and A. Lenzi. 2005. Androgens and fertility. *J. Endocrinol. Invest.* 28:51-55.
- Mendiola, J., A. M. Torres-Cantero, J. M. Moreno-Grau, J. Ten, M. Roca, S. Moreno-Grau and R. Bernabeu. 2009. Food intake and its relationship with semen quality: a case-control study. *Fertil. Steril.* 91:812-818.
- Meyer, H. H., D. Falckenberg, T. Janowski, M. Rapp, E. F. Rösel, L. van Look and H. Karg. 1992. Evidence for the presence of endogenous 19-nortestosterone in the cow peripartum and in the neonatal calf. *Acta Endocrinol. (Copenh.)* 126:369-373.
- Mobini Far, H. R., G. Agren, A. S. Lindqvist, M. Marmendal, C. Fahlke and I. Thiblin. 2007. Administration of the anabolic androgenic steroid nandrolone decanoate to female rats causes alterations in the morphology of their uterus and a reduction in reproductive capacity. *Eur. J. Obstet. Gynecol. Reprod. Biol.* 131:189-197.
- Nagata, S., M. Kurosawa, K. Mima, Y. Nambo, Y. Fujii, G. Watanabe and K. Taya. 1999. Effects of anabolic steroid (19-nortestosterone) on the secretion of testicular hormones in the stallion. *J. Reprod. Fertil.* 115:373-379.
- Noorafshan, A., S. Karbalay-Doust and F. M. Ardekani. 2005. High doses of nandrolone decanoate reduce volume of testis and length of seminiferous tubules in rats. *APMIS.* 113:122-125.
- Pokrywka, A., D. Kwiatkowska and D. Gorczyca. 2009. Possible reasons for the presence of nandrolone metabolites in urine. *Arch. Med. Sadowej. Kryminol.* 59:1550158.
- Ranke, M. B. and J. R. Bierich. 1986. Treatment of growth hormone deficiency. *Clin. Endocrinol. Metab.* 15:495-510.
- Salas-Ramirez, K. Y., P. R. Montalto and C. L. Sisk. 2008. Anabolic androgenic steroids differentially affect social behaviors in adolescent and adult male Syrian hamsters. *Horm. Behav.* 53:378-385.
- Scarth, J., C. Akre, L. van Ginkel, B. Le Bizec, H. De Brabander, W. Korth, J. Points, P. Teale and J. Kay. 2009. Presence and metabolism of endogenous androgenic-anabolic steroid hormones in meat-producing animals: a review. *Food Addit. Contam. Part A Chem. Anal. Control Expo. Risk Assess.* 26:640-671.
- Schwarzenberger, F., G. S. Toole, H. L. Christie and J. I. Raeside. 1993. Plasma levels of several androgens and estrogens from birth to puberty in male domestic pigs. *Acta Endocrinol.* 128:173-177.
- Swan, S. H., F. Liu, J. W. Overstreet, C. Brazil and N. E. Skakkebaek. 2007. Semen quality of fertile US males in relation to their mothers' beef consumption during pregnancy. *Hum. Reprod.* 22:1497-1502.
- Takahashi, M., Y. Tatsugi and T. Kohno. 2004. Endocrinological and pathological effects of anabolic-androgenic steroid in male rats. *Endocr. J.* 51:425-434.
- Torres-Calleja, J., M. Gonzalez-Unzaga, R. DeCelis-Carrillo, L. Calzada-Sanchez and N. Pedron. 2001. Effects of androgenic anabolic steroids on sperm quality and serum hormone levels in adult male bodybuilders. *Life Sci.* 68:1769-1774.
- Tseng, Y. T., R. W. Rockhold, B. Hoskins and I. K. Ho. 1994. Cardiovascular toxicities of nandrolone and cocaine in spontaneously hypertensive rats. *Fundam. Appl. Toxicol.* 22:113-121.
- van Der, V. J. 1965. On the mechanism of action of nandrolone phenylpropionate and nandrolone decanoate in rats. *Acta Endocrinol. (Copenh.)* 49:271-282.
- van Ginkel, L. A., R. W. Stephany, P. W. Zoontjes, H. J. van Rossum, H. van Blitterswijk and J. Zuijendorp. 1989. The presence of nortestosterone in edible parts from non-castrated male pigs. *Tijdschr. Diergeneesk.* 114:311-314.
- Yu-Yahiro, J., R. H. Michael, D. V. Nasrallah and B. Schofield. 1989. Morphologic and histologic abnormalities in female and male rats treated with anabolic steroids. *Am. J. Sports Med.* 17:686-689.