

## Organized Hematoma in the Maxillary Sinus

Jae-Jin Kim

Department of Dentistry/Oral & Maxillofacial Surgery, School of Medicine, Chungnam National University, Daejeon, Korea

### Abstract

Organized hematoma of the maxillary sinus is a rare, nonneoplastic benign lesion with locally destructive behavior that may mimic a malignancy. Clinically, symptoms do not usually occur while the lesion remains localized to the maxillary sinus. Because there is gradual enlargement of the lesion causing erosion and displacement of the adjacent bony structures, symptoms such as epistaxis, cheek swelling, nasal obstruction, headache, and exophthalmos become manifest. Radiologically, unilateral cases are much more frequent than bilateral, and Waters' view shows complete opacity of the expanded maxillary sinus and some masses. CT scan shows a large heterogeneous enhancing mass causing considerable expansion of the maxillary sinus with bony erosion. On MR imaging, the mass usually has a variable signal intensity on T1- and T2- weighted images, ranging from low to high. After contrast administration, discrete areas of enhancement are present within the mass. Although the disease is essentially benign and nonneoplastic, differential diagnosis from neoplastic disease including malignancy both clinically and radiologically has been always problematic. Accurate preoperative diagnosis of organized hematoma of the maxillary sinus is important to avoid unnecessary extensive surgery, because this condition is curative with a simple, conservative surgical approach and rarely recur. Organized hematoma of the maxillary sinus should be included in the differential diagnosis when patients have recurrent epistaxis, slow-growing mass of the cheek, nasal obstruction, and expansile mass in the maxillary sinus. A 33-year-old man was referred to the department of oral and maxillofacial surgery with a three-month history of slowly growing painful swelling of the left cheek. The mass of the maxillary sinus was resected by a Caldwell-Luc approach. Histopathology showed only a fibrous encapsulated organized hematoma. To our knowledge, organized hematoma of the maxillary sinus has not been previously described in the Korean literature of the oral and maxillofacial surgery. We report a case of organized hematoma of the maxillary sinus presenting with an enlarging maxillary sinus mass.

**Key words:** Organized hematoma, Maxillary sinus mass

### Introduction

A diverse disease entities causes an enlarging paranasal sinus mass that results in bony erosion and local expansion. Malignant tumors of the maxillary sinus and benign conditions including mucocele, hemangioma, and pseudotumor secondary to inflammation or bleeding disorder may present with expansion of the maxillary sinus.<sup>1-5)</sup>

Organized hematoma of the maxillary sinus is an

uncommon, nonneoplastic benign condition that can be locally destructive behavior. It most commonly affects the maxillary sinus. Less frequently, such a lesion may arise from the pericardium, cerebrum, adrenal gland, cerebellopontine angle, etc.<sup>6,7)</sup>

Clinical symptoms and radiologic appearance of the mass mimicked tumor during the provisional diagnosis of the disease. Correct preoperative diagnosis of organized hematoma is important to avoid unnecessary extensive surgery, because this condition is

\*This study was financially supported by clinical research fund of chungnam national university hospital in 2010.

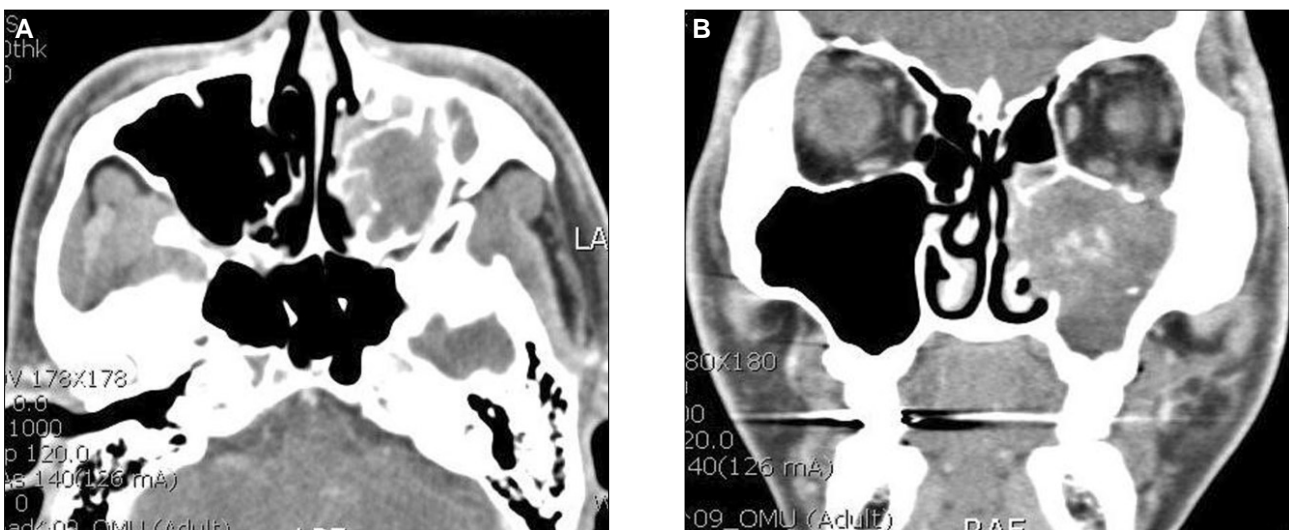
curative with a simple, conservative surgical approach and rarely recurs.

Since the first report by Ozhan *et al* in a patient with von Willebrand's disease, only fewer than 40 cases have been reported in the English literature. The aim of this article is to describe a rare case of organized hematoma of the maxillary sinus mimicking tumor.

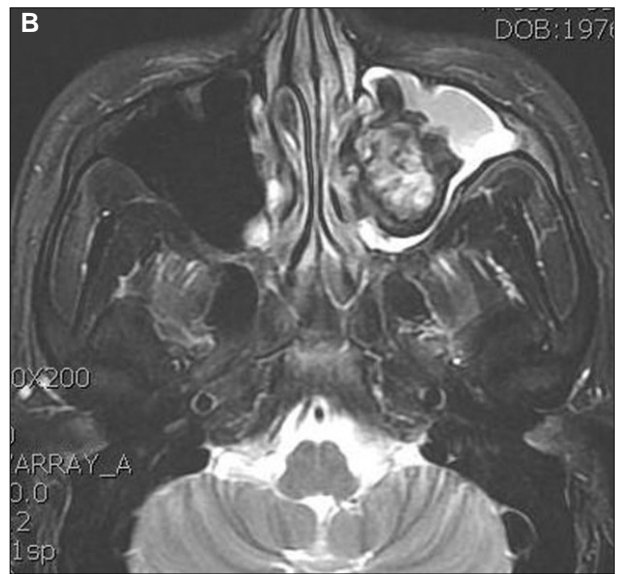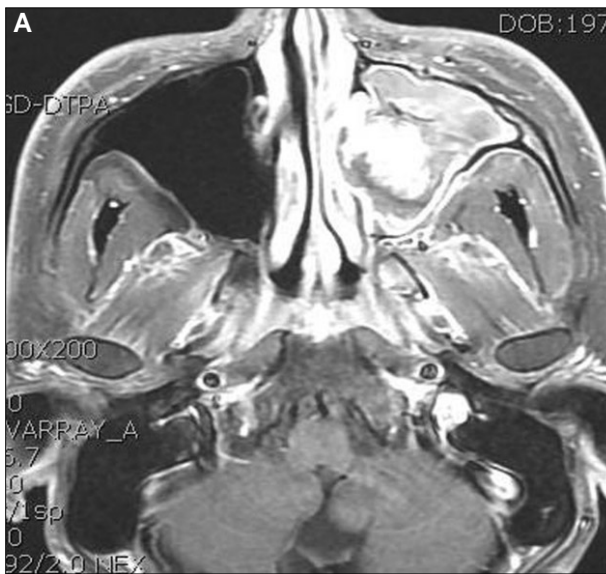
### Case Report

A 33-year-old man was referred to the department of oral and maxillofacial surgery with a three-month history of slowly growing painful swelling of the left cheek. He also complained of recurrent epistaxis with a partial left-sided nasal obstruction. When he was examined in our hospital, no epistaxis or neurologic deficit was noticed. There were no abnormalities in the nasopharynx, ears and throat. General examination and biochemical tests were normal. There was no history of hematopoietic disorder. Also, he denied history of trauma, previous surgery such as endoscopic sinus surgery. Anterior rhinoscopic examination revealed a reddish mass that bled easily occupying the left nasal cavity. We did not observe any tumoral mass or bleeding areas. General examination and hematological and biochemical tests were normal. Preoperatively taken CT scans of the paranasal

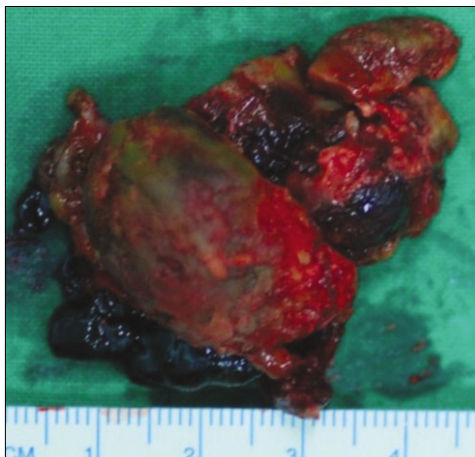sinuses revealed a 4 × 5 cm expansile heterogenous enhancing mass in the left maxillary sinus with internal calcific density and destruction of the medial wall of the orbit and medial wall of the maxillary sinus (Fig. 1). MR imaging shows the marked heterogeneity of the lesion with a mix of hypointense, isointense, and hyperintense signals (Fig. 2). Preoperative biopsy was performed through the anterior wall of the maxillary sinus. The pathologic evaluation of the specimen demonstrated inflammatory polyp showing hemorrhage with hemosiderin pigmentation and mild chronic inflammation, but the pathologist has not been able to confirm the exact pathologic diagnosis. Since the clinical and radiological findings raised the index of suspicion for a potentially neoplastic lesion and the risk of profuse bleeding, we chose performed Caldwell-Luc approach as treatment modality. A thin bony anterior wall of the maxillary sinus was observed. Caldwell-Luc approach allowed removal of the mass. A dark reddish soft tissue mass filling the entire maxillary sinus was seen. The mass was too difficult to remove en bloc from the maxillary sinus because it was friable and easily broken. But bleeding was not serious during or after surgery. The mass was completely removed. After removal of the tumor, the sinus mucosa was found intact and with a normal appearance. Grossly the mass included both a friable dark red portion and a



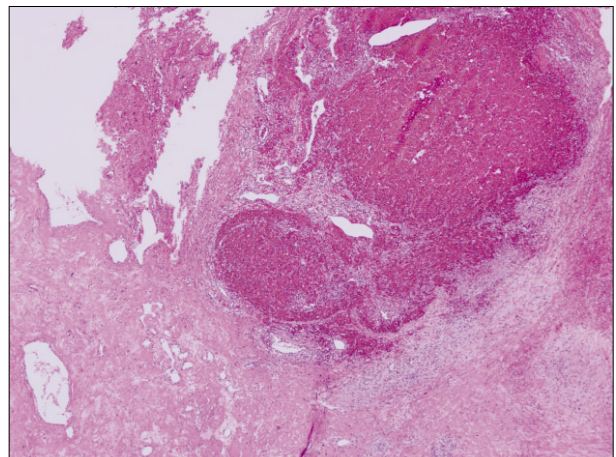
**Fig. 1.** A, Axial CT scan shows areas of patchy heterogeneous high density scattered in left maxillary sinus; B, Coronal CT scan shows expansile lesion of left maxillary sinus with erosion of medial and superior walls.



**Fig. 2.** The lesion shows intermingled low/intermediate/high signal intensity on both T1-A and T2-B weighted MR imaging.



**Fig. 3.** The removed mass. The mass measured 4 x 4 cm in size. Gross specimen of organized hematoma removed from maxillary sinus showing yellow, dark red and black areas.



**Fig. 4.** Histopathologic examination of the lesion showing hemorrhage and blood clots coexisting with neovascularization and fibrosis without evidence of neoplasm (H & E, x 40).

thick fibrous portion (Fig. 3). There were no postoperative complications with the exception of temporary swelling of the cheek and postoperative course of the patient was uneventful. Microscopically, the lesion comprised old hematoma with hemosiderin pigment, fibrous tissue with fibrin material and some fibroblast proliferation, and vascular proliferation without evidence of neoplasm (Fig. 4). These findings were compatible to the organized hematoma. From surgery until the present time, symptoms were completely relieved without any complication and recurrence.

## Discussion

Organized hematoma in the maxillary sinus is a rare nonneoplastic benign lesion that can be locally aggressive. Also, organized hematoma involving the intracranium, spinal cord, cervix or thigh has been reported occasionally.<sup>6,7)</sup>

A case report by Ozhan in 1996 is the first English document about organized hematoma of the maxillary sinus, which was associated with von Willebrand's disease.<sup>1)</sup> At a later time, organized

hematoma of the maxillary sinus was reported in patients without bleeding diathesis.<sup>3)</sup> This disease has been otherwise referred to as hemophilic pseudotumor or a hematoma-like mass, but the term "organized hematoma" is most commonly accepted.<sup>1,5,8-10)</sup>

The etiology of development of organized hematoma in the maxillary sinus has not been elucidated. However, Lee suggest a possible mechanism for the formation of an organized hematoma as follows.<sup>11)</sup> First, repeated hemorrhage in the maxillary sinus (semiclosed lumen) forms a hematoma encapsulated by fibrosis because of poor ventilation and drainage conditions. Second, the encapsulation prevents the absorption of the hematoma and induces vascularization. This hematoma transforms into an organized hematoma by means of neovascularization and fibrosis. Obstruction of the maxillary sinus ostium leads to negative intraluminal pressure, which causes rupture of the fragile vessels that line the sinus mucosa. This process causes rebleeding and increasing pressure with the hematoma. Third, the progressive expansion of a hematoma causes the demineralization of adjacent structures. The maxillary sinus is the one antrum in which organized hematoma occurs because it is the largest paranasal sinus that allows conditions of negative pressure and decreased ventilation. The occurrence of organized hematoma in other sinuses has been reported.<sup>5,9)</sup>

The cause and/or origin of bleeding for development of hematoma has not been elucidated, but possible mechanism proposed are as follows; (1) blood leakage from the nasal cavity through maxillary sinus ostium into the maxillary sinus, (2) simultaneously submucosal bleeding with epistaxis due to rupture or tear of the wall of arterial branches that supply the maxillary sinus, (3) rupture of unrecognized aneurysm of the arterial branches in the maxillary sinus.<sup>5)</sup> The mass usually originates in a single sinus and is generally located in the medial wall near the sinus ostium.

Patients range in age between 11 and 78 years, with the male-to-female ratio of 2-3 : 1.<sup>1,5,8)</sup> But, Kim reported that there was prediction for men, with the male-to-female ratio of 3 : 1.<sup>12)</sup> It occurs in patients with and without bleeding diathesis. A typical organized hematoma presents symptoms of recurrent

nasal bleeding, unilateral nasal obstruction, headache, and progressive cheek swelling along with the physical findings of medial displacement of the lateral nasal wall toward the nasal septum even with a deviation of the nasal septum to the opposite site.

Common CT findings of organized hematoma are expansion of one maxillary sinus, occasional extension into the ipsilateral ethmoid sinus, frequent bone erosion of the medial wall of the maxillary sinus, heterogeneous high density on unenhanced CT scans, and mucoperiosteal thickening.<sup>13)</sup> The other important finding is heterogeneous enhancement in a patchy distribution after administration of contrast medium.<sup>13)</sup> On MR imaging, the mass usually has a variable signal intensity on T1- and T2-weighted images, discrete areas of enhancement are present within the mass. The surrounding inflamed sinus mucosa, despite the bony changes, suggest a benign process on imaging.<sup>14)</sup>

Corrective preoperative diagnosis is important for determining the therapeutic plans, because organized hematoma of the maxillary sinus is usually curative with complete surgical resection simple by using endoscopic sinus surgery or Caldwell-Luc operation considering the benign and nonneoplastic nature of organized hematoma.

There is a long list of the differential diagnoses of a unilateral mass in the maxillary sinus detected on CT and MR images, including mucocele, fungus ball, inflammatory polyp, cholesterol granuloma, hemangioma, and carcinoma.<sup>5,13)</sup> Administration of contrast material is extremely useful, because mucocel, fungus ball, inflammatory polyp, and cholesterol granuloma do not usually enhance. Although hemangioma is seen as a smooth, freely mobile, purple looking, fleshy, polypoidal mass, standard radiological examinations (CT, MR image, angiography) are frequently limited help in the definitive preoperative diagnosis.<sup>2)</sup> Hemangioma of the maxillary sinus, especially the cavernous type, is probably the most difficult lesion to differentiate from organized hematoma both clinically and radiologically. Frank bony destruction, rather than smooth expansion of the sinus wall, associated with adjacent tissue invasion is a hallmark of carcinoma.

Recommended treatment of organized hematoma is

the Caldwell-Luc operation or endoscopic sinus surgery. Regardless of the approach, complete resection of the lesion is curative. But Suzuki *et al* reported that although small remaining tissue was left behind in the sinus after endoscopic sinus surgery, the diseases eventually cured in all the cases. Suzuki's report indicated that combination with other approaches such as inferior meatal and transcanine antrostomy is basically unnecessary.<sup>15)</sup>

Although rare, organized hematoma may be mistaken for a malignancy or locally aggressive neoplasm by presenting as an expansile soft tissue mass with erosion of the adjacent sinus walls. If a patient complains of recurrent nasal bleeding, nasal obstruction, and slow-growing mass of the cheek, organized hematoma must be included in the differential diagnosis to avoid inappropriate surgical treatment.

## References

- Ozhan S, Arac M, Isik S *et al* : Pseudotumor of the maxillary sinus in a patient with von Willebrand's disease. *Am J Roentgenol* 166 : 950, 1996.
- Raboso E, Rosell A, Plaza G *et al* : Hemangioma of the maxillary sinus. *J Laryngol Otol* 111 : 638, 1997.
- Salam MA, Whitehead E : Large maxillary sinus mucocele presenting with facial asymmetry. *J Laryngol Otol* 107 : 451, 1993.
- Som PM, Brandwein MS, Maldjian O *et al* : Inflammatory pseudotumor of the maxillary sinus : CT and MR findings in six cases. *Am J Roentgenol* 163 : 689, 1994.
- Unlu HH, Mutlu C, Ayhan S *et al* : Organized hematoma of the maxillary sinus mimicking tumor. *Auris Nasus Larynx* 28 : 253, 2001.
- Ito M, Tajima A, Sato K *et al* : Calcified cerebellopontine angle hematoma mimicking recurrent acoustic neuroma. *Clin Neurol Neurosurg* 90 : 65, 1988.
- Lee YY, Moser R, Bruner JM *et al* : Organized intracerebral hematoma with acute hemorrhage : CT patterns and pathologic correlations. *AJR Am J Roentgenol* 147 : 111, 1986.
- Yagisawa M, Ishitoya J, Tsukuda M : Hematoma-like mass of the maxillary sinus. *Acta Otolaryngol* 126 : 277, 2006.
- Lee BJ, Park HJ, Heo SC : Organized hematoma of the maxillary sinus. *Acta Otolaryngol* 123 : 869, 2003.
- Yoon TM, Kim JH, Cho YB : Three cases of organized hematoma of the maxillary sinus. *Eur Arch Otorhinolaryngol* 263 : 823, 2006.
- Lee PK, Wu JK, Ludemann JP : Hemorrhagic pseudotumor of the maxillary sinus. *J Otolaryngol* 33 : 206, 2004.
- Kim EY, Kim HJ, Chung SK *et al* : Sinonasal organized hematoma : CT and MR imaging findings. *Am J Neuroradiol* 28 : 1462, 2007.
- Lee HK, Smoker WR, Lee BJ *et al* : Organized hematoma of the maxillary sinus : CT findings. *Am J Roentgenol* 188 : W370, 2007.
- Nishiguchi T, Nakamura A, Mochizuki K *et al* : Expansile organized maxillary sinus hematoma : MR and CT findings and review of literature. *Am J Neuroradiol* 28 : 1375, 2007.
- Suzuki H, Inaba T, Hiraki N : Endoscopic sinus surgery for the treatment of organized hematoma of the maxillary sinus. *Kurume Med J* 55 : 37, 2008.

## 저자 연락처

우편번호 301-721  
대전광역시 중구 대사동 640  
충남대학교병원 치과/구강악안면외과  
김재진

원고 접수일 2010년 06월 15일  
게재 확정일 2010년 08월 03일

## Reprint Requests

### Jae-Jin Kim

Department of Dentistry/Oral & Maxillofacial Surgery,  
School of Medicine, Chungnam National University  
640, Daesa-dong, Jung-gu, Daejeon, 301-721, Korea  
Tel: +82-42-280-7820 Fax: +82-42-280-7824  
E-mail: kjjomfs@cnu.ac.kr

Paper received 15 June 2010  
Paper accepted 3 August 2010