

Case Report

Anterior Cranial Fossa Dural Arteriovenous Fistulae Presenting as Subdural Hematoma

Hyuk Jin Choi, M.D., Chang Won Cho, M.D., Ph.D.

Department of Neurosurgery, Maryknoll Medical Center, Busan Catholic Health System, Busan, Korea

Anterior cranial fossa dural arteriovenous fistulae (DAVFs) are very rare and the bleeding rate is very high, especially in the presence of leptomeningeal draining vein and aneurysmal varix formation. A 85-year-old male patient presented with subdural hematoma (SDH). Magnetic resonance image (MRI) and transfemoral carotid angiography (TFCA) disclosed DAVF at the anterior cranial fossa with bilateral arterial feeders and leptomeningeal draining vein with varix formation. The lesion was treated by simple ligation of pial connecting vein using low frontal craniotomy. In comparison with DAVFs of the other sites, the anterior cranial fossa DAVF is difficult to manage by endovascular treatment due to not only the difficulty of transvenous access but the risk of visual impairment when using transarterial route. Surgical ligation of pial connecting vein is feasible and effective treatment.

KEY WORDS : Anterior cranial fossa · Dural arteriovenous fistulae · Leptomeningeal draining vein · Craniotomy.

INTRODUCTION

Dural arteriovenous fistulae (DAVFs) are defined as abnormal connections between an arterial feeder and a dural venous sinus or leptomeningeal vein with the nidus located within the dural leaflets¹³. Most DAVFs are idiopathic. Others are associated with antecedent craniotomy, trauma, or dural sinus thrombosis and may result from aberrant dural angiogenesis².

Anterior cranial fossa DAVFs are rare (5.8%)^{1,5,9}, but they have an usually high incidence of sudden massive intracranial hemorrhage (62-91%)¹⁴.

Treatment of DAVF with cortical venous drainage is aimed at occlusion of the venous drainage or occlusion of all arterial supply, and can be surgical, endovascular, or a combination of both^{6,12,15}.

Although endovascular treatment of anterior cranial fossa DAVFs has become technically feasible, but its relative risks and benefits have not justified its use. We present a patients

with anterior cranial fossa DAVFs treated with surgery. The surgical management by simple ligation of leptomeningeal draining vein would be a better option in this type of DAVF.

CASE REPORT

A 85-year-old male patient had a sudden onset of headache and consciousness loss. Brain computed tomography (CT) and magnetic resonance imaging (MRI) revealed subdural hematoma (SDH), left side and intracerebral hematoma (ICH) at the left frontal pole with multiple signal voids suspecting blood vessels at the left side cranial base near the cribriform plate (Fig. 1). He had craniectomy

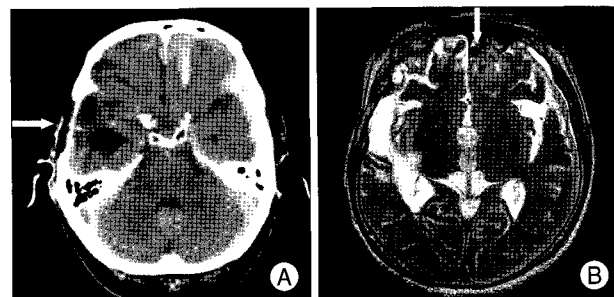


Fig. 1. Axial computed tomography scan showing previous craniectomy site on the right temporal area (arrow), recent intracerebral hemorrhage on the left frontal lobe, and subdural hematoma on the left frontotemporoparietal area (A). T2-weighted magnetic resonance image showing multiple signal voids at the left frontal pole near the cranial base (arrow) (B).

• Received : April 21, 2009 • Revised : July 21, 2009
 • Accepted : December 27, 2009
 • Address for reprints : Chang Won Cho, M.D., Ph.D.
 Department of Neurosurgery, Maryknoll Medical Center,
 Busan Catholic Health System, 12 Daecheong-dong 4-ga, Jung-gu,
 Busan 600-730, Korea
 Tel : +82-51-461-2458, Fax : +82-51-466-6164
 E-mail : braincwc@hotmail.com

and ventriculo-peritoneal shunt operation due to a trauma 20 years ago. Transfemoral carotid angiography (TFCA) disclosed a DAVF of the anterior cranial fossa. The arterial feeders were the ethmoidal arteries through collateral channels with the internal maxillary arteries, ophthalmic arteries, meningeal arteries, and a transosseous collateral by way of the superficial temporal artery, and which drained to the superior sagittal sinus by way of pial venous connections from the anterior cranial fossa near the crista gali through a cortical variceal vein (Fig. 2).

We chose surgical management rather than endovascular management and disconnected the pial venous connection due to the difficulty of transvenous access and the risk of visual deficit by transarterial embolization.

The patient was placed in a supine position with the head slightly elevated. Low frontal craniotomy was done along the both medial orbit and frontonasal suture. Frontal air sinus was cranialized, which enhanced low profile visual axis. To avoid injury to the frontal lobe, brain retraction was limited. The site of the fistula was easily identified on the level of chribriform plate, besides the crista gali where an arterialized and dilated draining vein arose from the dura. This vein was connected to the pial veins on the frontal cortical surface. Intraoperative doppler sonography was helpful to identify the arterialized vein. The vascular connection between the dura and the cortical draining vein was obliterated by bipolar coagulation and then clipped. The

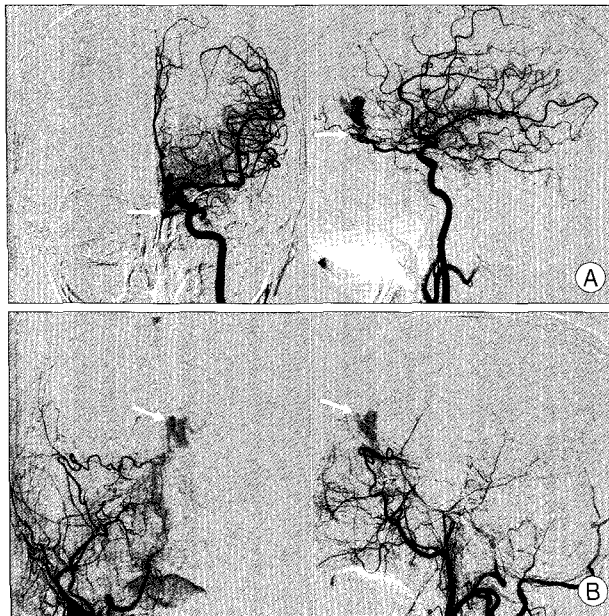


Fig. 2. A : Left internal carotid artery angiography, anteroposterior and lateral view revealing a dural arteriovenous fistulae (DAVF) supplied from the left ophthalmic and both ethmoidal arteries (arrow). B : Right external carotid artery angiography, anteroposterior and lateral view showing a DAVF supplied from the right internal maxillary artery, middle meningeal artery and sphenopalatine artery (arrow indicating varix).

arterialized draining vein and the cortical venous varix collapsed down (Fig. 3).

Postoperative angiography revealed the total obliteration of intracranial variceal vein and fistulae (Fig. 4). No postoperative complications were recorded.

DISCUSSION

The pathogenesis of anterior cranial fossa DAVF is unclear, and there have been some cases of anterior cranial fossa DAVF secondary to a head trauma⁷. The DAVF of the base of the anterior cranial fossa are known to carry a high risk of intracranial hemorrhage (62-91%)¹¹. Intracerebral hematomas and, less frequently, subarachnoid and subdural hemorrhages have been described^{1,9}. Lasjaunias et al.⁹ reviewed 191 previous reported cases of dural arteriovenous malformation (AVM). Nineteen of these DAVFs (9.9%) were located in the anterior cranial fossa, of which sixteen (84%) presented with intradural bleeding, and 4 (21%) presented with subdural hematoma. Awad et al.¹¹ performed meta-analysis on a total of 377 cases DAVM. Fifteen (68%) of the 22 DAVF located in the anterior cranial fossa showed aggressive neurological behaviors. It has been demonstrated that the occurrence of intradural bleeding in

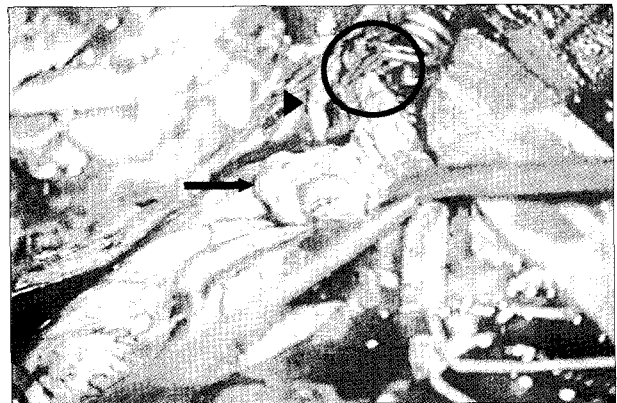


Fig. 3. Intraoperative photograph. Surgical microscopic view shows the clipped pial draining vein (circle), collapsed varix (arrow), and the olfactory nerve (arrowhead).

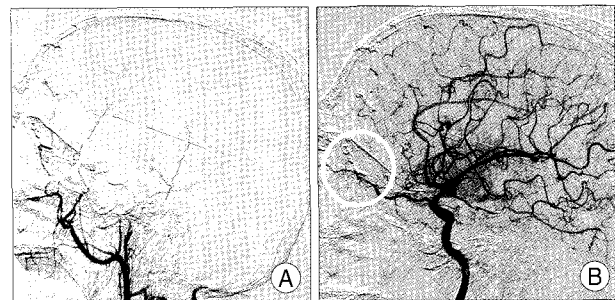


Fig. 4. Right External carotid artery angiogram (A) and left internal carotid artery angiogram (B) demonstrating the obliteration of the dural arteriovenous fistulae by clip (circle).

DAVFs in general and those of the anterior cranial fossa in particular is related to the pattern of venous drainage and not of arterial supply. Leptomeningeal venous drainage and variceal dilatation of intradural draining veins are associated with a high frequency of bleeding events^{1,3-5,13}. The pathogenesis of hemorrhage is considered as venous hypertension,⁷ venous varix is associated with bleeding in 72%¹⁴. Although in the absence of venous outflow stenosis and venous ectasia, DAVF of the anterior cranial fossa may bleed³.

Because the anterior cranial fossa DAVFs have an extraordinary high risk of hemorrhage, conservative management would rarely be indicated. The indications for the surgical management of DAVF in the anterior cranial fossa are patients with hemorrhage, symptomatic DAVF, and pial drainage vessel with varix¹⁴. The management of anterior cranial fossa DAVF aims at interruption of the fistula to prevent intradural bleeding events. To occlude the fistula, different treatment modalities such as surgery, embolization, irradiation, and combination therapy must be considered. Most reported cases were managed surgically. Because the main supply of these fistulae comes from multiple ethmoidal branches arising from one or both ophthalmic arteries, occlusion of the fistulae by embolization through the ophthalmic artery is considered more dangerous by most authors^{5,6,10}. Obliteration of the fistulae with embolic material is possible but not easy because of not only the difficulty of catheterizing small tortuous vessel and a high risk of visual impairment due to occlusion or spasm of the central retinal artery⁶ but the difficulty of transvenous access due to fragile bridging vein. Embolization could be considered to patients who are not suitable for surgical management. Therefore, at present microsurgical obliteration of the fistulae is considered preferred treatment for anterior cranial fossa DAVF⁸.

Surgery is considered as more straightforward than embolization. We exposed the fistulae by low frontal craniotomy until the frontonasal suture and cranialization of the frontal air sinus. With this technique, the frontal lobe retraction was kept to minimum and injury to the olfactory nerve and premature rupture of the fistula due to retraction was effectively prevented.

Typically, the fistulae make up of an epidural network supplying a single intradural draining vein via intradural arteriovenous microshunt. The draining vein may anastomize with pial vein to form an arterialized venous plexus. To occlude the arteriovenous shunt, simple surgical ligation of vascular connection from the dura to the pial leptomeningeal cortical vein is sufficient, and excision of the nidus are not mandatory.

CONCLUSION

In conclusion, DAVFs of the anterior cranial fossa frequently present with hemorrhage and have an aggressive clinical course. In compared to DAVFs of the other sites, anterior cranial fossa DAVFs would be better managed by simple surgical ligation of pial connecting draining vein.

References

1. Awad IA, Little JR, Akarawi WP, Ahl J : Intracranial dural arteriovenous malformations : factors predisposing to an aggressive neurological course. *J Neurosurg* 72 : 839-850, 1990
2. Chung SJ, Kim JS, Kim JC, Lee SK, Kwon SU, Lee MC, et al. : Intracranial dural arteriovenous fistulas : analysis of 60 patients. *Cerebrovasc Dis* 13 : 79-88, 2002
3. Defreyne L, Vanlangenhove P, Vandekerckhove T, Deschrijver I, Sieben G, Klaes R, et al. : Transvenous embolization of a dural arteriovenous fistula of the anterior cranial fossa : preliminary results. *AJNR Am J Neuroradiol* 21 : 761-765, 2000
4. Deshmukh VR, Chang S, Albuquerque FC, McDougall CG, Spetzler RF : Bilateral ethmoidal dural arteriovenous fistulae : a previous unreported entity : case report. *Neurosurgery* 57 : E809, 2005
5. Halbach VV, Higashida RT, Hieshima GB, Wilson CB, Barnwell SL, Dowd CF : Dural arteriovenous fistulas supplied by ethmoidal arteries. *Neurosurgery* 26 : 816-823, 1990
6. Hoh BL, Choudhri TF, Connolly ES Jr, Solomon RA : Surgical management of high-grade intracranial dural arteriovenous fistulas : leptomeningeal venous disruption without nidus excision. *Neurosurgery* 42 : 796-804; discussion 804-805, 1998
7. Im SH, Oh CW, Han DH : Surgical management of an unruptured dural arteriovenous fistula of the anterior cranial fossa : natural history for 7 years. *Surg Neurol* 62 : 72-75; discussion 75, 2004
8. Kim JH, Kwon OK, Lee KJ, Koh SB, Yoo H, Koh YC, et al. : Surgical management of dural arteriovenous fistula of the anterior cranial fossa after failure of embolization therapy : case report. *J Korean Neurosurg Soc* 31 : 271-273, 2002
9. Lasjaunias P, Chiu M, ter Brugge K, Tolia A, Hurth M, Bernstein M : Neurological manifestations of intracranial dural arteriovenous malformations. *J Neurosurg* 64 : 724-730, 1986
10. Lawton MT, Chun J, Wilson CB, Halbach VV : Ethmoidal dural arteriovenous fistulae : an assessment of surgical and endovascular management. *Neurosurgery* 45 : 805-810; discussion 810-811, 1999
11. Lv X, Li Y, Liu A, Lv M, Jiang C, Wu Z : Endovascular embolization of dural arteriovenous fistulas of the anterior cranial fossa : three case reports. *Neurol Res* 30 : 852-859, 2008
12. Mullan S : Reflections upon the nature and management of intracranial intraspinal vascular malformation and fistulae. *J Neurosurg* 80 : 606-616, 1994
13. Newton TH, Cronqvist S : Involvement of dural arteries in intracranial arteriovenous malformations. *Radiology* 93 : 1071-1078, 1969
14. Tanei T, Fukui K, Wakabayashi K, Mitsui Y, Inoue N, Watanabe M : Dural arteriovenous fistula in the anterior cranial fossa : four case reports. *Neurol Med Chir (Tokyo)* 48 : 560-563, 2008
15. van Dijk JM, TerBrugge KG, Willinsky RA, Wallace MC : Selective disconnection of cortical venous reflex as treatment for cranial dural arteriovenous fistulas. *J Neurosurg* 101 : 31-35, 2004