

## Case Report

# Bow Hunter's Stroke Caused by a Severe Facet Hypertrophy of C1-2

Chung Kee Chough, M.D.,<sup>1</sup> Boyle C. Cheng, Ph.D.,<sup>2</sup> William C. Welch, M.D.,<sup>3</sup> Chun Kun Park, M.D.<sup>4</sup>

Department of Neurosurgery,<sup>1</sup> The Catholic University of Korea College of Medicine, St. Mary's Hospital, Seoul, Korea

Department of Neurological Surgery,<sup>2</sup> University of Pittsburgh, Pittsburgh, USA

Department of Neurological Surgery,<sup>3</sup> University of Pennsylvania, Philadelphia, USA

Department of Neurosurgery,<sup>4</sup> The Catholic University of Korea College of Medicine, Seoul St. Mary's Hospital, Seoul, Korea

Bow hunter's stroke is a rare symptomatic vertebrobasilar insufficiency in which vertebral artery (VA) is mechanically occluded during head rotation. Various pathologic conditions have been reported as causes of bow hunter's stroke. However, bow hunter's stroke caused by facet hypertrophy of C1-2 has not been reported. A 71-year-old woman presented with symptoms of vertebrobasilar insufficiency. Spine computed tomography showed massive facet hypertrophy on the left side of C1-2 level. A VA angiogram with her head rotated to the right revealed significant stenosis of left VA. C1-2 posterior fixation and fusion was performed to prevent serious neurologic deficit from vertebrobasilar stroke.

**KEY WORDS :** Bow hunter's stroke · Facet joint · Hypertrophy · C1-2 fusion.

## INTRODUCTION

Head and neck rotation can cause mechanical stenosis or obstruction of vertebral artery (VA). This rare and unique symptomatic vertebrobasilar insufficiency or infarction is named "bow hunter's stroke" after the first description by Sorensen<sup>15</sup>. Various pathologic conditions have been reported as causes of bow hunter's stroke<sup>3,5-7,11,14</sup>. We report a 71-year-old woman with rotatory occlusion of VA from rare massive facet hypertrophy at the C1-2 level treated by C1-2 posterior fixation and fusion.

## CASE REPORT

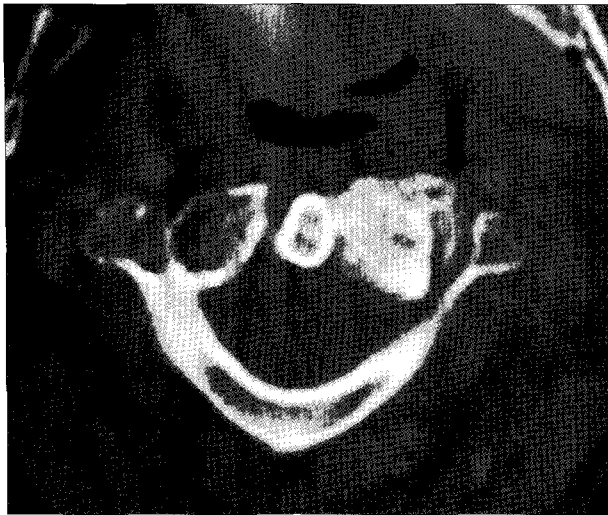
A 71-year-old woman presented with a 3-year history of vertigo, hypoesthesia of left toes and occasional memory loss, with rotation of head to the right side. These symp-

toms were reversed by returning her head to a neutral position. A physical and neurological examination was normal. Plain X-rays and magnetic resonant imaging studies demonstrated cervical spondylosis. Contrast-enhanced computed tomography showed massive facet arthropathy and resultant narrowing of the VA more so on the left than the right at the C1-2 level (Fig. 1). A left vertebral angiogram with the head in neutral position demonstrated a normal left VA with reflux down the right VA. With her head rotated 45 degrees to the right, there was a significant stenosis at C1-2, greater than 80% of the left VA and a questionable stenosis of the right VA as well (Fig. 2).

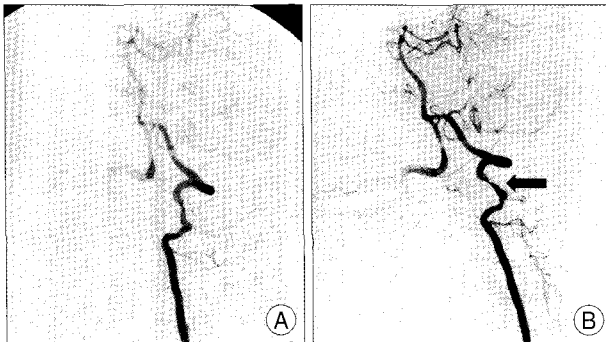
Posterior fixation and fusion of C1-2 was recommended to reduce the potential serious neurologic deficit from the vertebrobasilar stroke.

The patient was placed in prone position while the head was secured in a Mayfield holder and maintained in a neutral position. A linear skin incision was made from the occipital protuberance to the spinous process of C3. A bilateral subperiosteal dissection of the paraspinal musculature was performed to expose the lateral margins of the facet joints at the C2-3. Dissection was continued laterally over the posterior arch of C-1, exposing the VA in the vertebral groove on the C-1 arch. The C-2 pars screw entry point

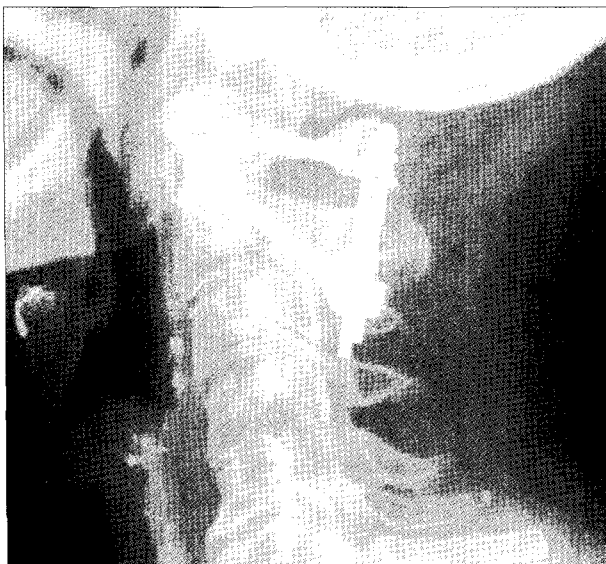• Received : July 29, 2009 • Revised : October 21, 2009  
 • Accepted : December 27, 2009  
 • Address for reprints : Chung Kee Chough, M.D.  
 Department of Neurosurgery, The Catholic University of Korea College of Medicine, St. Mary's Hospital, 62 Yeouido-dong, Yeongdeungpo-gu, Seoul 150-713, Korea  
 Tel : +82-10-3696-6186, Fax : +82-2786-5809  
 E-mail : chough@catholic.ac.kr



**Fig. 1.** Spinal computed tomography. Post-contrast computed tomography shows massive facet hypertrophy and result on narrowing of the vertebral artery (black arrow) more extensive on the left than the right at the C1-2 level.



**Fig. 2.** Left vertebral angiography A : With head rotation to the left, left vertebral artery shows no stenosis. B : With her head rotated 45 degrees to the right, the left vertebral artery showing severe stenosis at C2 level (black arrow).



**Fig. 3.** Postoperative lateral cervical spine shows posterior C1-2 fixation with good alignment.

and trajectory was oriented using anatomical landmarks, as described by Harms and Melcher<sup>7</sup>. A contoured horse-shoe shaped rod was secured to the C-1 arch using sublaminar cables. The rod was placed into the polyaxial screw heads and secured in position. Lateral arthrodesis was performed by decorticating the exposed surfaces of the C1-2 joints with a high-speed drill and then packing cancellous iliac crest autograft over these joints (Fig. 3). The postoperative course was uneventful. The patient was neurologically completely asymptomatic in follow-up. Head rotation was reduced by approximately 30% compared to her preoperative status.

## DISCUSSION

Bow hunter's stroke is a symptomatic vertebrobasilar insufficiency caused by stenosis or occlusion of the VA with head rotation<sup>12</sup>. It is a common finding on angiography that head rotation produces stenosis or occlusion of a contralateral VA. However, temporary positional occlusion of one VA during daily activities rarely produces major effects on posterior circulation blood flow. In most reported cases, patients with ischemic attacks induced by rotational occlusion of one VA had an opposite VA that was hypoplastic, stenotic, or occluded. The VAs at the atlantoaxial level are particularly prone to mechanical compression during head and neck rotation because of its unique relationship to the surrounding transverse foramina, paravertebral muscles, and fibrous ligaments<sup>1,5,6</sup>. Axial rotation at the C1-2 level may cause VA occlusion within normal range of motion due to the relatively fixed position of the artery within the posterior arch of the atlas<sup>5,14</sup>. Head rotation to the right results in fixation of the right atlantoaxial joint, while the atlas moves forward on the axis on the left side. The segment of vertebral artery between C-1 and C-2 can be narrowed or occluded in the process<sup>2</sup>. Atlantoaxial instability, ossification or hypertrophy of the atlantooccipital membrane, tightness of the paravertebral musculature, or severe changes of spondylosis may also contribute to vertebral artery compression<sup>3,5,6,8,13,14</sup>. The second most site of VA compromise is its entrance into the C6 transverse foramen<sup>8</sup>. This is attributed to the VA being anchored by fibrous band just before its entrance into the transverse foramen and head rotation leads to stenosis of the VA at the tethered C6 level<sup>10</sup>. Rotational stenosis of the VA at its second cervical segment (from C3 to C6) is very rare and osteophyte formation seems to play major role in these cases<sup>10</sup>.

Treatment alternatives for rotational compression of the atlantoaxial portion of the VA have included verbal warn-

ings or braces to restrict head and neck rotation, surgical fusions to prevent atlantoaxial rotation, and decompression of the VA at the C1-2 level. Decompression of the VA at the C1-2 level by either anterior or posterior approach has been used for affected patients<sup>4,9,12,14</sup>. Matsuyama et al.<sup>9</sup> reported results for nine patients of bow hunter's stroke treated with posterior decompression of VA. However, in three of these patients, reocclusion of the operated VA was recognized after surgery and two of them had more severe neurologic symptoms than preoperatively. Fox et al.<sup>4</sup> reported spinal accessory nerve palsy as a complication of the anterolateral decompressive approach<sup>4</sup>. The risks of direct surgical decompression of VA in the face of structural abnormalities such as massive facet hypertrophy in the present case are significant. Inadvertent vertebral artery injury during direct decompression could also have caused new neurological deficit or posterior fossa stroke. Posterior fixation of C1-2 to eliminate vertebral artery rotatory occlusion is a reasonable option in these patients.

## CONCLUSION

We report the rare case of a bow hunter's stroke from facet hypertrophy at the C1-2 level. C1-2 posterior fusion is a reasonable option considering significant risks of direct surgical decompression of VA in this case.

## References

1. Barton JW, Margolis MT : Rotational obstruction of the vertebral artery at the atlantoaxial joint. *Neuroradiology* 9 : 117-120, 1975
2. Bauer R, Sheehan S, Meyer JS : Arteriographic study of cerebro-

- vascular disease. II. Cerebral symptoms due to kinking, tortuosity, and compression of carotid and vertebral arteries in the neck. *Arch Neurol* 4 : 119-131, 1961
3. Easton JD, Sherman DG : Cervical manipulation and stroke. *Stroke* 8 : 594-597, 1977
4. Fox MW, Piepgras DG, Bartleson JD : Anterolateral decompression of the atlantoaxial vertebral artery for symptomatic positional occlusion of the vertebral artery. Case report. *J Neurosurg* 83 : 737-740, 1995
5. Frisoni GB, Anzola GP : Vertebrobasilar ischemia after neck motion. *Stroke* 22 : 1452-1460, 1991
6. Hardin CA, Poser CM : Rotational obstruction of the vertebral artery due to redundancy and extraluminal cervical fascial bands. *Ann Surg* 158 : 133-137, 1963
7. Harms J, Melcher RP : Posterior C1-C2 fusion with polyaxial screw and rod fixation. *Spine (Phila Pa 1976)* 26 : 2467-2471, 2001
8. Mapstone T, Spetzler RF : Vertebrobasilar insufficiency secondary to vertebral artery occlusion from a fibrous band. Case report. *J Neurosurg* 56 : 581-583, 1982
9. Matsuyama T, Morimoto T, Sakaki T : Comparison of C1-2 posterior fusion and decompression of the vertebral artery in the treatment of Bow hunter's stroke. *J Neurosurg* 86 : 619-623, 1997
10. Miele VJ, France JC, Rosen CL : Subaxial positional vertebral artery occlusion corrected by decompression and fusion. *Spine (Phila Pa 1976)* 33 : E366-E370, 2008
11. Pásztor E : Decompression of vertebral artery in cases of cervical spondylosis. *Surg Neurol* 9 : 371-377, 1978
12. Seki T, Hida K, Akino M, Iwasaki Y : Anterior Decompression of the atlantoaxial vertebral artery to treat bow hunter's stroke : technical case report. *Neurosurgery* 49 : 1474-1476, 2001
13. Sheehan S, Bauer RB, Meyer JS : Vertebral artery compression in cervical spondylosis. Arteriographic demonstration during life of vertebral artery insufficiency due to rotation and extension of the neck. *Neurology* 10 : 968-986, 1960
14. Shimizu T, Shiro W, Kojima T, Niwa S : Decompression of the vertebral artery for bow hunter's stroke. Case report. *J Neurosurg* 69 : 127-131, 1988
15. Sorenson BF : Bow hunter's stroke. *Neurosurgery* 2 : 259-261, 1978