

Clinical Article

Neonatal Intracranial Ischemia and Hemorrhage : Role of Cranial Sonography and CT Scanning

Imran Ahmad Khan, M.D.,¹ Shagufta Wahab, M.D.,¹ Rizwan Ahmad Khan, M.S., M.Ch.,² Ekram Ullah, M.D.,¹ Manazir Ali, M.D.³

Department of Radiodiagnosis,¹ Division of Pediatric Surgery,² Department of Pediatrics,³ JNMCH, AMU, Aligarh, India

Objective : To evaluate the role of cranial sonography and computed tomography in the diagnosis of neonatal intracranial hemorrhage and hypoxic-ischemic injury in an Indian set-up.

Methods : The study included 100 neonates who underwent cranial sonography and computed tomography (CT) in the first month of life for suspected intracranial ischemia and hemorrhage. Two observers rated the images for possible intracranial lesions and a kappa statistic for interobserver agreement was calculated.

Results : There was no significant difference in the kappa values of CT and ultrasonography (USG) for the diagnosis of germinal matrix hemorrhage/intraventricular hemorrhage (GMH/IVH) and periventricular leucomalacia (PVL) and both showed good interobserver agreement. USG, however detected more cases of GMH/IVH (24 cases) and PVL (19) cases than CT (22 cases and 16 cases of IVH and PVL, respectively). CT had significantly better interobserver agreement for the diagnosis of hypoxic ischemic injury (HII) in term infants and also detected more cases (33) as compared to USG (18). CT also detected 6 cases of extraaxial hemorrhages as compared to 1 detected by USG.

Conclusion : USG is better modality for imaging preterm neonates with suspected IVH or PVL. However, USG is unreliable in the imaging of term newborns with suspected HII where CT or magnetic resonance image scan is a better modality.

KEY WORDS : Hypoxic ischemic injury · Ultrasonography · CT-scan.

INTRODUCTION

Neonatal intracranial hemorrhagic and hypoxic lesions can be divided as those occurring in the preterm and in the term infants. In the preterm, the major lesions are germinal matrix hemorrhage (GMH)/intraventricular hemorrhage (IVH) and periventricular leucomalacia (PVL)^{13,18}. In the term infants the major problems are hypoxic-ischemic encephalopathy/injury (HIE) and intracranial hemorrhage^{1,11}. Intracranial hemorrhage is uncommon in term infants and when it occurs is generally unrelated to the germinal matrix²¹. Ultrasonography (USG), computed tomography (CT) and magnetic resonance image (MRI) are being routinely used to screen the neonate for probable intracra-

nial problems^{15,17,19,24}. Yet, only few studies have attempted to compare the role of various imaging modalities in the setting of specific neuroimaging findings viz. hemorrhagic and ischemic lesions in preterm and term infants. The purpose of our study was to compare the relative role of cranial sonography and CT in the diagnosis of hemorrhagic and ischemic events in preterm and term infants; and thereby attempt to determine which modality is better suited for detection of a particular lesion. We did not include MRI in our comparative study as MRI is not available in most of the Indian setup, especially at the periphery. Also, most of the neonates are too sick to be investigated by MRI. Furthermore, cost concerns preclude the use of MRI in many cases.

The advantages of USG are that it is easily available, cheap, quick and easy to perform and can be done at the bedside. Also, it does not use ionizing radiation. However, sonography does not differentiate subarachnoid from subdural hemorrhages and it is also unlikely that a small cortical hemorrhage will be detected¹². It is relatively insensitive to alteration in brain tissue perfusion and to acute HIE^{3,22}.

- Received : March 25, 2009 • Revised : November 14, 2009
- Accepted : December 29, 2009
- Address for reprints : Rizwan Ahmad Khan, M.S., M.Ch.
Division of Pediatric Surgery, Department of Pediatrics, JNMCH, AMU,
4/817-F, S. S. Nagar, Nagla Road, Aligarh, U.P., India
Tel : +91-9410210281, Fax : +0571-2721127
E-mail : arrizwanahmadkhan@yahoo.co.in

The advantages of CT include its easy availability and high spatial resolution. CT provides excellent anatomic resolution of the entire brain parenchyma. Also, it is not operator dependent, relatively cheaper and can be more rapidly performed as compared to MRI. CT can reliably distinguish between subdural and subarachnoid bleed, which is difficult on sonography¹². However in premature infants the role of CT for the documentation of acute hypoxic-ischemic brain injury is limited. High water content of the premature brain precludes the use of decreased attenuation as an index of cerebral edema. CT contributes significantly to total radiation dose derived from medical imaging in children. At present, the best radiologic modality to evaluate the brain in infants and children is MRI. There are no known biological hazards and no ionizing radiation, and it produces exquisite anatomic detail of the central nervous system (CNS). MRI has greater sensitivity and specificity for the detection of perinatal HII than either ultrasound or CT. Thus, early T2 prolongation on standard MRI within 12 to 18 hours after injury appears to correlate with edema, whereas T1 shortening after 3 days and T2 shortening after 6-7 days correlates with permanent brain damage^{10,24}.

MATERIALS AND METHODS

Our study was conducted from January 2005 to December 2006, in the Department of Radiodiagnosis, J.N. Medical College and Hospital, AMU on 130 neonates referred from the Neonatal Unit of our hospital with clinical suspicion of intracranial ischemia or hemorrhage. Informed consent was obtained from the parents of the patients included in the study. Cranial sonography and CT were then performed within 48 hours of each other. Of these CT could not be performed in 15 patients and in 14 patients the interval between CT and USG was more than 48 hours due to various reasons and so they were excluded. Of the remaining 101 infants we chose 100 as the study size, for the ease of calculations. The study included 54 preterm and 46 term infants. There were 56 males and 44 females. Imaging was performed at 10-14 days of age, as recommended by Boal et al.⁴ A detailed clinical evaluation was done including general physical examination and neuro-logical examination. Clinical data included estimated gestational age (Ballard's), birth weight, 1 and 5 minute Apgar scores, mode of delivery, age at imaging and time between sonography and CT. The relevant laboratory investigations like serum electrolytes, arterial blood pH and pO₂, and serum bilirubin were carried out whenever required.

The following exclusion criteria were taken into account :

1) Patients with known congenital CNS malformations.

2) Patients with meningitis.

3) Patients in whom sonography and CT could not be performed within 48 hours of each other.

Imaging

Cranial sonography was performed with a Toshiba Famio 8 Smart Ultrasound machine using multifrequency 4 MHz and 6 MHz electronic curvilinear array probes. Eight MHz and 12 MHz linear high frequency probes were also used to detect any possible extraaxial fluid collections. Standard images in sagittal and coronal planes were obtained through the anterior fontanelle. Posterior sagittal and coronal views were obtained via the posterior fontanelle, whenever required. Non-contrast CT was done using Siemens Somatom Balance single slice helical scanner using the sequence mode at 120 keV, 120 mAs, and 1.5 second scan time per acquisition; 5 × 5 mm contiguous axial scans were obtained. Reduced tube current settings were used²⁰ to reduce mean radiation dose to the patient.

Image analysis

All sonograms and CT images were separately and independently reviewed by two senior radiologists who were blinded to patient history and previous radiology reports. The images were assessed for the following abnormalities : germinal matrix hemorrhages (GMH)-Grades I through IV, including intraventricular hemorrhages (IVH) and parenchymal extension (PE) (Burstein Papile et al.⁷ classification was used); non-matrix related hemorrhages including intraparenchymal hemorrhage (IPH) and extraaxial (subdural/subarachnoid/epidural) hemorrhage; HII of the cortex, basal ganglia, brainstem, thalamus or cerebellum; and early and late (cystic) PVL¹⁸. Each abnormality was scored on a scale of 1-5 (1 = definitely not present, 2 = probably not present, 3 = indeterminate, 4 = probably present, 5 = definitely present). An abnormality was considered present if the collective score of the two observers was at least 8.

Statistical analysis

For each technique, possible findings from the examinations of the participants were rated as one of five categories 1 to 5 by the two observers. The kappa statistic for multiple ratings per participant was used to measure interobserver agreement^{8,23}. Kappa with linear weighting was used instead of unweighted kappa as used erroneously by previous observers^{5,6}. Hypothesis tests were evaluated as statistically significant when *p* values were less than 0.05. Comparison of kappa statistics between imaging techniques was conducted using the z test. When two techniques were compared, the technique with statistically higher kappa value was consi-

dered to be more accurate for the detection of a specific imaging finding.

RESULTS

Twenty-four cases of germinal matrix/intraventricular hemorrhages, 10 cases of non-matrix related intracranial hemorrhages, 33 cases of HII in term infants and 19 cases of HII in preterm infants (PVL) were observed as per Table 1.

Preterm infants

Out of the 54 preterm infants, 24 suffered from germinal matrix/intraventricular hemorrhages (Fig. 1), 19 suffered from PVL and 6 patients had extra-axial hemorrhages, 2 patients of PVL also suffered from intraparenchymal hemorrhages which were not related to germinal matrix. Twenty of the 24 cases of IVH (83%) and 13 of the 19 cases of PVL (68%) were seen in preterm infants of < 32 weeks of gestational age. USG detected 24 cases of GMH/IVH while CT detected 22 cases; 2 cases of grade I IVH being missed on CT (Table 2). Although the kappa values of CT (0.8544) were found to be higher than USG (0.7874), the difference was not statistically significant. There were 13 cases of early PVL and 6 cases of cystic PVL (Fig. 2-5). USG detected 19 cases of PVL while CT detected only 16. Both CT and USG however detected all the cases of cystic PVL. The kappa values of USG were found to be higher than CT particularly for early PVL. The difference was however, not significant. Thus the sensitivity of CT relative to USG for the diagnosis of IVH and PVL were 91.7 and 82.75% respectively. USG was unable to detect only 1 of the 6 cases of extra-axial hemorrhages which were revealed by CT, indicating that sonography has poor sensitivity in the detection of extra-axial hemorrhages (6.2%). Furthermore, two small intra-parenchymal hemorrhages of the size about 1 cm were missed on USG and were detected only on CT.

Term infants

USG revealed 18 cases of HII as compared to 33 detected by CT (Table 3). Additionally, USG diagnosed seven false positive cases which were reported as definitely negative on CT, thus the sensitivity and specificity of USG relative to CT were only 55.5% and 72% respectively. Moreover, kappa values of CT (0.772) were significantly higher than the corresponding values of USG (0.5394) for the diagnosis of HII ($p < 0.01$). Two cases of intracranial bleed were seen in term infants in our study, which were reliably diagnosed by both CT and USG.

Table 1. Spectrum of findings

S. no.	Findings	Number of cases detected on	
		Cranial sonography	NCCT head
1	GMH/IVH	24	22
2	Non-matrix hemorrhages	3	10
3	Periventricular leucomalacia	19	16
4	Hypoxic-ischemic injury	18	33

GMH/IVH : germinal matrix hemorrhage/intraventricular hemorrhage

Table 2. CT and USG of intracranial bleed in preterm infants

Finding of GMH/IVH	No. of patients detected by	
	Sonography	NCCT
Grade I	03	01
Grade II	09	09
Grade III	09	09
Grade IV	03	03

GMH/IVH : germinal matrix hemorrhage/intraventricular hemorrhage

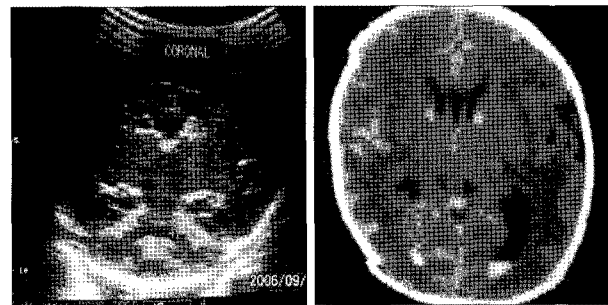


Fig. 1. Ultrasonography and computed tomography of a neonate showing B/L grade III germinal matrix and intraventricular hemorrhage with hydrocephalus.

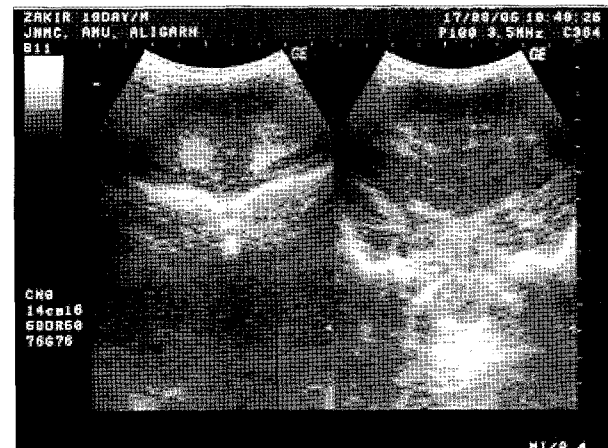


Fig. 2. Early periventricular leucomalacia : ultrasonography shows increased echogenicity in B/L frontal and left parietal region.

DISCUSSION

Blakenberg et al.⁹ had previously compared the efficacy of USG relative to CT and MRI for the diagnosis of ischemia and hemorrhages. However, their study was small (n = 47) and there was no adequate representation of preterm

infants in their study. We had 54 preterm and 46 term infants in our study and we wanted to compare the efficacy of USG relative to CT in each subgroup. In preterm neonates, out of the 34 cases of intracranial hemorrhages, 24 were germinal matrix related. Majority of the cases of IVH

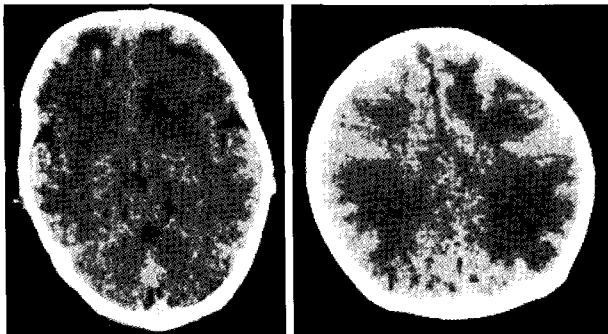


Fig. 3. Early periventricular leucomalacia: computed tomography of the above patient shows low attenuation of white matter in B/L frontal and parietal regions. A small focus of bleed is seen in right frontal region.

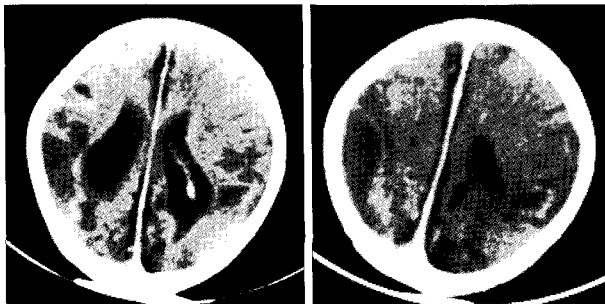

Fig. 4. Computed tomography of a patient showing cystic periventricular leucomalacia.

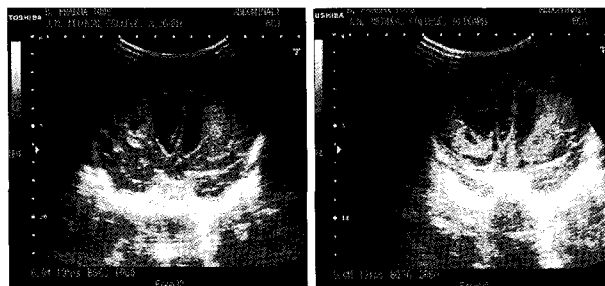


Fig. 5. Ultrasonography of same patient showing cystic periventricular leucomalacia.

Table 3. USG and CT findings in cases of hypoxic ischemic injury in term infants

S. no.	Findings	USG	CT
1	Focal/Multifocal cerebral infarcts	9	15
2	Global ischemic changes	1	4
3	Cystic encephalomalacia	4	4
4	Cerebellar infarcts	0	2
5	Basal ganglia infarcts	3	4
6	Thalamic infarcts	1	2
7	Brainstem infarcts	0	2

USG : ultrasonography

(83%) were seen in the preterm neonates of less than 32 weeks gestational age. USG fared well in the diagnosis of GMH/IVH and detected more cases than CT (24 as against 22 detected by CT). This finding was also seen by previous observers^{5,6}. The two cases that were missed by CT were of unilateral grade I GMH. Also, both CT and USG showed excellent interobserver agreement in the diagnosis of grade I to IV IVH, with kappa values of CT ($k = 0.8544$) being slightly greater than USG ($k = 0.7874$). The difference, however, was not statistically significant. Thus, USG should be the preferred modality for the screening of IVH owing to its better and excellent interobserver agreement.

CT was found to be more sensitive in detecting extraaxial hemorrhages, and detected 6 cases of subdural bleed as compared to only 1 detected by USG. This finding was also noted by previous observers^{2,5,6,14}. CT was also better in detecting non-matrix related intraparenchymal hemorrhages and detected 4 of them. USG showed poor sensitivity and was unable to detect 2 of these cases where hemorrhage was less than 1 cm in size. Thus, our study shows that USG is not reliable in the detection of non-matrix related hemorrhages.

In preterm neonates, 19 cases of periventricular leucomalacia were observed in our study, 6 cases were of cystic PVL and 13 of early PVL (B/L periventricular echogenicity on USG). We found it difficult on CT to differentiate low attenuation due to PVL from normal low attenuation seen in premature brain. As a result, CT had lesser (though not statistically significant) kappa values than USG for the diagnosis of PVL, particularly early PVL (Table 2). There were three such cases where the diagnosis was missed on CT-scan (early PVL). Sonography on the other hand showed good sensitivity and interobserver agreement for the diagnosis of early PVL. All the 6 cases of cystic PVL were, however diagnosed reliably by both modalities. Hence, sonography should be the imaging modality of choice for the detection of early PVL. However, once cystic changes develop after 1-3 weeks, both modalities can diagnose PVL with equal precision.

In term neonates, cranial sonography detected only 18 cases of hypoxic ischemic injury out of 33 detected by CT. Focal ischemic lesions appeared on USG as localized areas of variably increased echogenicity. However, interpretation of this increased echogenicity was relatively subjective and a number of cases (7 cases) were reported as having suspicious areas of increased echogenicity which were termed as definitely negative by CT (false positive). It was particularly difficult to diagnose on USG cases where there was a generalized increase in echogenicity of bilateral cerebral hemispheres (global ischemia). Also USG was not able to detect

any of the cases of brainstem and cerebellar infarcts (Table 3). The interobserver agreement of USG ($k = 0.5394$) was significantly lower than CT ($k = 0.772$) ($p < 0.01$) in diagnosis of HII in term neonates. The difference between ultrasound and CT for the detection of cortical HII could not be explained by progressive evolution of ischemic injury because there was a narrow window of time between the performance of each examination (we performed cranial sonography and CT within 48 hours of each other). Thus, USG fared poorly in the diagnosis of HII in term neonates. The superiority of CT for the detection of HII has been suggested by several investigators^{2,14}. The study with USG-pathology correlation has demonstrated low sensitivity (28%) in the detection of pathologically proven HII-associated lesions in neonates. However, 9 infants with strong clinical evidence of HIE (low 1 and 5 min Apgar scores) turned out to be normal at the time of CT scan, implying that presence of normal scan at CT and sonography does not entirely rule out neurological insult in the affected neonate. Other imaging techniques such as functional and diffusion-weighted MR imaging, positron emission tomography, single photon emission computed tomography and MR spectroscopy may prove to be more useful in the detection of regional cerebral blood flow/perfusion or metabolic disturbances to precisely define the extent of injury and thus predict future neurodevelopment outcome.

Our study did not address the issue whether serial US examinations could provide the same diagnostic information as CT. The changes associated with the evolution of GMH/IVH and HII that have been observed at serial USG examinations can be useful diagnostically. However, this aspect ignores the additive costs of multiple USG examinations and possible delay in diagnosis. Further studies need to be conducted to compare both conventional and newer neuroimaging techniques with respect to cost benefit issues.

CONCLUSION

Cranial USG examination provides a relatively sensitive and highly specific means of detecting IVH and should be employed in screening preterm neonates for IVH and the interobserver agreement of CT is higher than USG for the detection of IVH, and can detect extra-axial hemorrhages which are likely to be missed on USG. Moreover, cranial sonography has greater sensitivity and interobserver agreement than CT in the diagnosis of PVL (HII of premature brain) and therefore should be the preferred modality for imaging PVL. In term neonates, USG fared poorly in the detection of HII i.e., it has poor sensitivity, specificity and interobserver agreement as compared to CT. Furthermore,

CT is fairly precise modality for detecting HII of term neonates and should be the mainstay in the imaging of term neonates, where cost concerns or non-availability precludes the use of MRI.

References

1. Alan H, Volpe JJ : Hypoxic ischemic cerebral Injury in the Newborn in Kenneth FS, Stephan A (eds) : *Pediatr Neurol*, ed 3. Mosby, 1999, Vol 1, pp191-204
2. Ayyapan C, Rajeswasri PA, Edwin N : Clinical and computerized tomography evaluation of term neonates with perinatal asphyxia. *Indian Pediatr* 36 : 174-177, 1999
3. Babcock DS, Ball W Jr : Postasphyxial encephalopathy in full-term infants; ultrasound diagnosis. *Radiology* 148 : 417-423, 1983
4. Boal DK, Watterberg KL, Miles S, Gifford KL : Optimal cost-effective timing of cranial ultrasound screening in low-birth weight infants. *Pediatr Radiol* 25 : 425-428, 1995
5. Blankenberg FG, Loh NN, Bracci P, D'Arceuil HE, Rhine WD, Norbash AM, et al. : Sonography, CT and MR imaging : a prospective comparison of neonates with suspected intracranial ischemia and hemorrhage. *AJNR Am J Neuroradiol* 21 : 213-218, 2000
6. Blankenberg FG, Norbash AM, Lane B, Stevenson DK, Bracci PM, Enzmann DR : Neonatal intracranial ischemia and hemorrhage : diagnosis with US, CT and MR imaging. *Radiology* 199 : 253-259, 1996
7. Burstein J, Papile LA, Burstein R : Intraventricular hemorrhage and hydrocephalus in premature newborn : a prospective study with CT. *AJR Am J Roentgenol* 132 : 631-635, 1979
8. Donker DK, Hasman A, van Geijn HP : Interpretation of low kappa values. *Int J Biomed Comput* 33 : 55-64, 1993
9. Fawer CL, Calame A : *Ultrasound In imaging Techniques of the CNS of neonates*. Verlag, 1994, pp79-106
10. Fitz CR, Byrd SE, Vezina G : Imaging Modalities in Kuhn JP, Slovis TL, Haller JD (eds) : *Caffey's Pediatric Diagnostic imaging*, ed 10. Mosby, 2004, pp482-505
11. Gupta AK : Hypoxic-Ischemic Encephalopathy in Berry M, Suri S, and Chowdhury V, JP Brothers (eds) : *Diagnostic Radiology : Pediatric Radiology*. 1997, pp260-273
12. Kazam E, Rudelli R, Monte W, Rubenstein WA, Ramirez de Arellano E, Kairam R, et al. : Sonographic diagnosis of cisternal subarachnoid hemorrhage in the premature infant. *AJNR Am J Neuroradiol* 15 : 1009-1020, 1994
13. Laura RM, Keller SM : Intraventricular Hemorrhage of preterm neonate in Kenneth FS, Stephan A : *Pediatric Neurology*, ed 3. Mosby, 1999, Vol 1, pp205-219
14. Mack LA, Wright K, Hirsh JH, Alvord EC, Guthrie RD, Shuman WP, et al. : Intracranial hemorrhage in premature infants : accuracy in sonographic evaluation. *AJR Am J Roentgenol* 137 : 245-250, 1981
15. Ment LR, Bada HS, Barnes P, Grant PE, Hirtz D, Papile LA, et al. : Practice parameter : neuroimaging of the neonate : report of the Quality Standards Subcommittee of the American Academy of Neurology and the Practice Committee of the Child Neurology Society. *Neurology* 58 : 1726-1738, 2002
16. O'shea TM, Volberg F, Dillard RG : Reliability of interpretation of cranial ultrasound diagnosis of pathologically verified lesions in the brain of very preterm infants. *Dev Med Child Neurol* 35 : 457-471, 1993
17. Perlman JM, Rollins N : Surveillance protocol for the detection of intracranial abnormalities in premature neonates. *Arch Pediatr Adolesc Med* 154 : 822-826, 2000
18. Patrizia V, Anna L, Valentina D, Francesca A, Giuseppe P, John CP, et al. : Intraventricular hemorrhage and periventricular leucomalacia

- in preterm infants. *Obstet Gynecol* 104 : 225-231, 2004
19. Rumack C, Wilson S, Charboneau W : Neonatal and Infant Brain Imaging in Rumack C, Wilson S, Chaboneau W : **Diagnostic Ultrasound**, ed 2. Mosby, 1997, Vol 2, Chapter 53, pp1443-1502
20. Shah R, Gupta AK, Rehani MM, Pandey AK, Mukhopadhyay S : Effect of tube reduction on reader confidence in pediatric computed tomography. *Clin Radiol* 60 : 224-231, 2005
21. Siu SLY, Kwong NS, So K : A 10-year review of intracranial haemorrhage in term neonates. *HK J Pediatr* 11 : 140-146, 2006
22. Stark JE, Seibert JJ : Cerebral artery Doppler ultrasonography for the prediction of outcome after perinatal asphyxia. *J Ultrasound Med* 13 : 595-600, 1994
23. Viera AJ, Garrett JM : Understanding interobserver agreement : the kappa statistic. *Fam Med* 37 : 360-363, 2005
24. Wycliffe ND, Thomson JR, Mcleary M, Holshouser B, Ashwal S : Pediatric Neuroimaging in Kenneth FS, Stephan A : **Pediatric Neurology**, ed3. Mosby, 1999, Vol 1, pp122-141