

Case Report

Herniated Lumbar Disc Combined with Spinal Intradural Extramedullary Cysticercosis

Kyeong Bo Choi, M.D.,¹ Byeong-Wook Hwang, M.D., Ph.D.,¹ Won Gyu Choi, M.D., Ph.D.,² Sang-Ho Lee, M.D., Ph.D.²

Department of Neurosurgery,¹ Busan Wooridul Spine Hospital, Busan, Korea

Department of Neurosurgery,² Wooridul Spine Hospital, Seoul, Korea

Spinal cysticercosis is a very uncommon manifestation of neurocysticercosis which is caused by the larvae of *Taenia solium*. However, it can develop as a primary infection through blood stream or direct larval migration. It can result in high recurrence and severe neurologic morbidity if not treated appropriately. We report the case of a 43-year-old woman who presented with severe lower back pain and left leg radiating pain in recent 2 weeks. Magnetic resonance image (MRI) of lumbar spine demonstrated extruded disc at the L5-S1 level combined with intradural extramedullary cystic lesion. We performed the open lumbar microdiscectomy (OLM) at L5-S1 on the left with total excision of cystic mass. After surgery, the patient showed an improvement of previous symptoms. Diagnosis was confirmed by histopathological examination as intradural extramedullary cysticercosis. We discuss clinical features, diagnostic screening, and treatment options of spinal cysticercosis.

KEY WORDS : Cysticercosis · Neurocysticercosis · Spinal cysticercosis · Intradural cysticercosis · *Taenia solium*.

INTRODUCTION

Cysticercosis is the most common parasitic disease of the central nervous system and is caused by *Cysticercus cellulosae*, the metacestode state of *Taenia solium*¹⁻³⁾. However, spinal involvement of cysticercosis is very rare and the incidence reported previously is approximately 1 to 3%^{1,3,12)}. It is an endemic condition to Brazil, Peru, Mexico, Korea, India, South America, Tropical African, and Southeast Asian countries⁶⁻⁸⁾. In this report, we present a rare case of extruded disc at the L5-S1 level with spinal intradural extramedullary cystic lesion which was treated with both surgical excision and medical treatment at our hospital.

CASE REPORT

A 43-year-old female suffered from severe lower back pain and paresthesia in left lower extremity for 2 weeks. She also complained of the progressive weakness and diminished sen-

sation in her both lower extremities during past 20 years. Neurologic examination showed the motor power of grade 3/5 in left ankle dorsiflexion and grade 4/5 in the right. Magnetic resonance imaging (MRI) of the lumbar spine revealed the downward extruded disc at L5-S1 combined with well-defined intradural extramedullary cystic lesion, which was isointense on T1- and hypointense on T2-weighted images (Fig. 1). MRI of the brain to differentiate the space occupying lesion was normal and there was no evidence of cystic lesion elsewhere.

We performed the open lumbar microdiscectomy (OLM) at left L5-S1 to remove both extruded disc material and cystic mass. After OLM, we observed that there was no epidural lesion except extruded disc, but the dural sac was tough and tense. We performed longitudinal durotomy to identify the intradural extramedullary lesion. At first, we detected moderate severe adhesion of cauda equina and did not expect anything such as hematoma or cystic lesion. After a laborious more dissection of the cauda equina, a well-capsulated cyst adherent to sacral roots and adjacent dura was noted. After the careful incision of the cystic wall under the microsurgical techniques, clear cystic fluid was gushed out, and it was sucked out by the suction. The grape-like, multiple whitish small masses within the cyst were found and removed in piecemeal fashion (Fig. 2). Finally, the wound was profusely irrigated

• Received : August 6, 2010 • Revised : October 18, 2010

• Accepted : December 21, 2010

• Address for reprints : Byeong-Wook Hwang, M.D., Ph.D.

Department of Neurosurgery, Busan Wooridul Spine Hospital, Hubsky

WIAA 10F, 153-8 Oncheon 1-dong, Dongrae-gu, Busan 607-831, Korea

Tel : +82-51-559-2262, Fax : +82-51-559-2295

E-mail : busan@wooridul.co.kr

with hypertonic saline to decrease inflammatory reaction caused by parasite infection during the operation.

Histopathologic examination revealed cysticercosis with fibrous capsule containing parasites (Fig. 3). Subsequently, she was treated with albendazole (15 mg/kg per day) for 2 weeks to prevent recurrence. Corticosteroid treatment was also added to reduce the inflammatory reaction during the

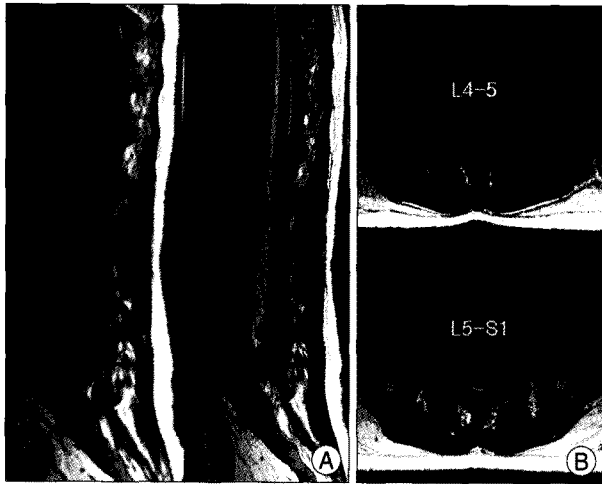


Fig. 1. A : Preoperative sagittal T1- and T2-weighted images show the downward extruded disc at L5-S1 combined with cystic lesion (arrow), which is isointense on T1- and hypointense on T2-weighted images. B : Pre-operative axial T2-weighted images show a cystic lesion at the spinal intradural extramedullary location.

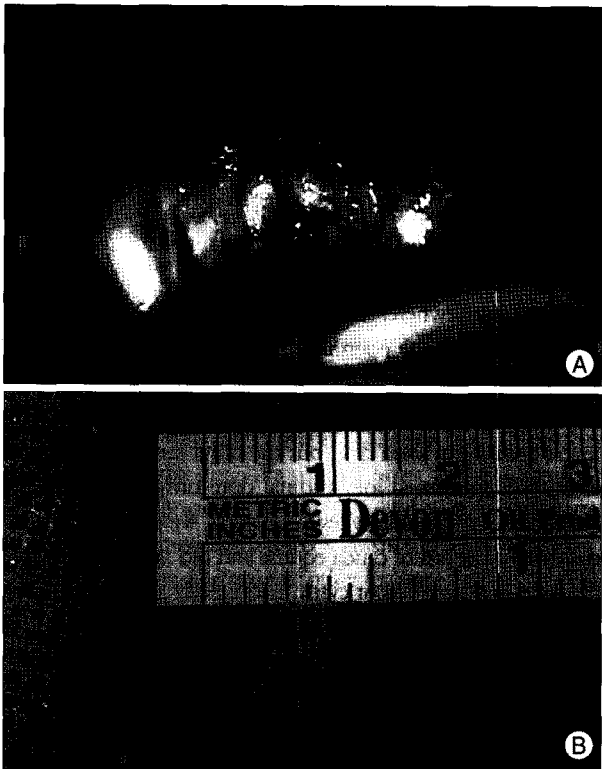


Fig. 2. Surgical excision of the extramedullary cyst. A : Intraoperative finding of grape-like, multiple whitish small masses within the cyst. B : Photograph of the operative specimen at the operating room.

early postoperative period. Immediately after the operation, the patient showed much improvement of her lower back and left leg pain. Follow-up MRI one week later after surgery showed well-decompressed herniated disc and total excision of cystic mass (Fig. 4). She was discharged 2 weeks after surgery without any sequelae.

Unfortunately, three months after the surgery, the patient readmitted due to recurrent intolerable lower back pain and paresthesia on both legs. Follow-up MRI images showed adhesion of the cauda equina to ventral dura at L5 body level

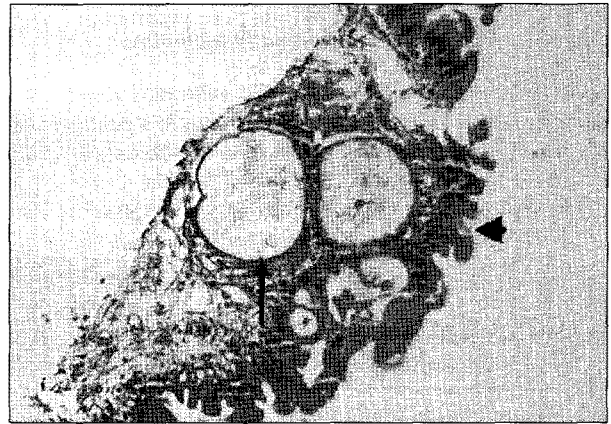


Fig. 3. Photomicrograph of the histopathological specimen revealing the scolex (arrow) and a portion of the cyst wall (arrow head) (H&E, original magnification $\times 40$).

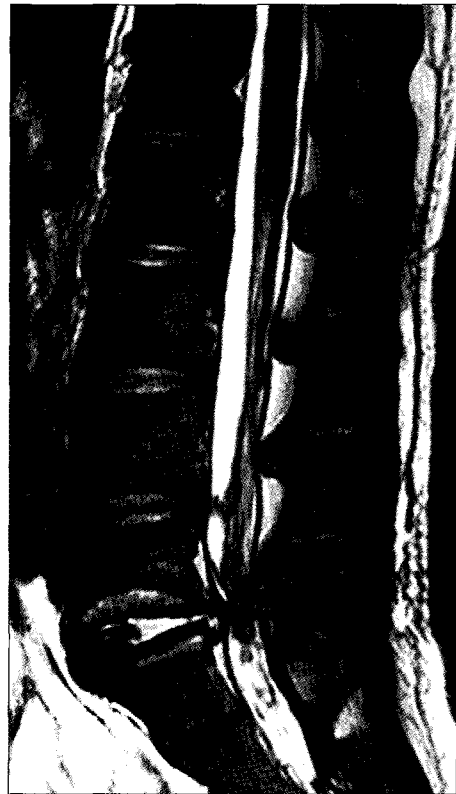

Fig. 4. T2-weighted MRI 1 week later after surgery shows well-decompressed herniated disc and total excision of cystic mass.

with chronic arachnoidal scarring. Although the symptomatic treatments with pain control and physical treatment were effective for her symptoms, recurrent symptoms have remained during 1 year follow-up.

DISCUSSION

Cysticercosis is the most common parasitic infection of the central nervous system and results from direct ingestion of cysticercal eggs contaminated by human or porcine feces. However, spinal involvement of cysticercosis is exceedingly rare. According to the previous literature, the incidence of spinal cysticercosis ranges from 1 to 3% compared to intracranial cysticercosis^{3,15}. Colli et al. suggested the hypothesis of "sieve effect" at the transition level between intracranial and intraspinal subarachnoid space to account for the relatively lower incidence of spinal cysticercosis⁵.

Spinal cysticercosis can occur in either the subarachnoid space or the spinal cord. Subarachnoid location of spinal cysticercosis occurs most frequently in approximately 80% of cases^{1,10}. There are several routes for disseminating parasite to spinal subarachnoid space. The most reliable route is the cerebrospinal fluid (CSF). It is thought to result from larval migration through the ventricular system into the spinal subarachnoid space⁵. Intramedullary cysticercosis is considered as a result from the hematogenous spread, but Paterakis et al. suggested that, as well as CSF dissemination, hematogenous migration is also possible in cases of extramedullary cysticercosis^{1,5,12}.

More detailed evaluations for the spinal cysticercosis are usually necessary before treatment for the following patients: 1) the patient with a history of the intermittent neurologic symptoms including, typical back pain, radicular leg pain with progressive motor weakness; 2) the patients showing inflammatory reaction such as diffuse leptomeningeal enhancement with cystic lesion on MRI; 3) those who came from endemic areas. In our patient, it is supposed that the patient's recent symptoms of lower back pain and radicular leg pain occurred due to extruded disc, but the occasional neurologic symptoms such as intermittent paresthesia and weakness of the low extremities during the past 20 years might have originated from spinal cysticercosis. Therefore, it is probably explainable that relatively late and insidious onset of symptoms was not caused by the direct mass effect, but by the inflammatory reaction.

According to some authors, nearly 50% of patients who underwent spinal surgery for spinal cysticercosis have experienced continued or recurrent symptoms attributed to arachnoidal inflammation^{5,11,13}. Moreover, several series described that the patients with chronic arachnoidal scarring

or spinal cord inflammation have reported poorer outcomes. Although previous symptoms of our patient were improved immediately after surgery, the symptoms recurred and aggravated 3 months later. Unfortunately, after the readmission, the adhesion of the cauda equina to ventral dura at the operated level was observed on follow-up MRI. The durotomy allowed us to observe the severe adhesion of the cauda equina. Therefore, massive irrigation of surgical site with hypertonic saline or diluted Betadine solution after removal of cyst is necessary to decrease these distresses during the operation and perioperative steroid injections are crucial⁴. In the case of recurrent symptoms associated with inflammatory reaction induced by the dying larvae after index surgery, adhesiolysis of rootlets alone, or combined with duroplasty can be performed, but the effects of such surgery have not been clearly reported.

MRI scan is the diagnostic study of choice for evaluating spinal cysticercosis because it provides non-invasive images of a large area of the spinal cord, cauda equina and any potential intraspinal pathological entity⁸. However, it is difficult to make accurate diagnosis of spinal cysticercosis only by the MRI study and clinical features especially in patient with herniated lumbar disc combined with cystic mass as in our case. Because MRI scan can demonstrate the various pathological stages of spinal cysticercosis, there are no unique radiological feature^{6,7,13}. Also, other pathologies, such as arachnoid cysts, dermoid cysts, hydatid cysts, tuberculosis, sarcoidosis and forms of subarachnoid neoplasia, have similar radiologic findings^{2,3}. Furthermore, the complete assessments of entire neuraxis are mandatory in cases of spinal cysticercosis, because solitary lesion is extremely rare.

Serology with the enzyme-linked immunosorbent assay (ELISA) in the serum and CSF provide relatively reliable result in the endemic area, even though they have high false positive and false negative^{8,14}. However, lumbar puncture may cause unexpected neurological worsening in patients with spinal subdural block and careful caution is essential.

There have been some controversies in the literature regarding surgical excision versus medical treatment for spinal cysticercosis^{2,4,11,12,15}. The patients with severe neurologic symptoms caused by spinal cysticercosis are the best candidates for surgery. As surgical excision can give definite diagnosis and alleviate compressive symptoms, it is favored by the majority of authors as treatment of choice³⁻⁵. Hamed et al.⁹ suggest that surgical treatment of spinal cysticercosis is appropriate for the exact diagnosis and efficient treatment due to non-availability of immunologic tests and short mean period of medical observation in the developing country that is endemic area.

Surgical treatment, nevertheless, is not always a guarantee

for good prognosis. Severe adhesions between nervous tissue and cystic mass may make total resection of cyst difficult in some cases. Additionally, as surgery related high mortality and morbidity rate (15 and 85%, respectively) have been reported, medical treatment with cysticidal drugs may be tried^{2,15}. Albendazole and praziquantel are still the most commonly used cysticidal drugs that are able to destroy most of the spinal and intracranial parasites. However, very high doses of albendazole for viable cyst may increase the inflammatory reaction around the cysticerci during its degeneration, and could result in neurological worsening⁵. Simultaneous administration of steroid is necessary for prevention of neurological deterioration due to inflammatory reaction.

CONCLUSION

Spinal cysticercosis is extremely rare compared with intracranial cysticercosis and it is very difficult to make accurate diagnosis only by observing the neurologic symptoms, radiologic findings or immunodiagnostic tools, respectively. Spinal cysticercosis should be considered for the differential diagnosis in patients with neurological deterioration due to herniated disc combined with spinal cystic lesion in endemic area.

• Acknowledgements

This study was supported by a grant from the Wooridul Spine Foundation.

References

1. Alsina GA, Johnson JP, McBride DQ, Rhoten PR, Mehringer CM, Stokes JK : Spinal neurocysticercosis. *Neurosurg Focus* 12 : e8, 2002
2. Chang KH, Han MH : MRI of CNS parasitic diseases. *J Magn Reson Imaging* 8 : 297-307, 1998
3. Ciftçi E, Diaz-Marchan PJ, Hayman LA : Intradural-extramedullary spinal cysticercosis : MR imaging findings. *Comput Med Imaging Graph* 23 : 161-164, 1999
4. Colli BO, Martelli N, Assirati JA Jr, Machado HR, de Verguero Forjaz S : Results of surgical treatment of neurocysticercosis in 69 cases. *J Neurosurg* 65 : 309-315, 1986
5. Colli BO, Valença MM, Carlotti CG Jr, Machado HR, Assirati JA Jr : Spinal cord cysticercosis : neurosurgical aspects. *Neurosurg Focus* 12 : e9, 2002
6. do Amaral LL, Ferreira RM, da Rocha AJ, Ferreira NP : Neurocysticercosis : evaluation with advanced magnetic resonance techniques and atypical forms. *Top Magn Reson Imaging* 16 : 127-144, 2005
7. García HH, Del Brutto OH : Imaging findings in neurocysticercosis. *Acta trop* 87 : 71-78, 2003
8. Garcia E, Sotelo J : A new complement fixation test for the diagnosis of neurocysticercosis in cerebrospinal fluid. *J Neurol* 238 : 379-382, 1991
9. Hamed SA, El-Metaal HE : Unusual presentations of neurocysticercosis. *Acta Neurol Scand* 115 : 192-198, 2007
10. Leite CC, Jinkins JR, Escobar BE, Magalhães AC, Gomes GC, Dib G, et al. : MR imaging of intramedullary and intradural-extramedullary spinal cysticercosis. *AJR Am J Roentgenol* 169 : 1713-1717, 1997
11. Mohanty A, Venkatrama SK, Das S, Das BS, Rao BR, Vasudev MK : Spinal intramedullary cysticercosis. *Neurosurgery* 40 : 82-87, 1997
12. Paterakis KN, Kapsalaki E, Hadjigeorgiou GM, Barbanis S, Fezoulidis I, Kourtopoulos H : Primary spinal intradural extramedullary cysticercosis. *Surg Neurol* 68 : 309-311, 2007
13. Rahalkar MD, Shetty DD, Kelkar AB, Kelkar AA, Kinare AS, Ambardekar ST : The many faces of neurocysticercosis. *Clin Radiol* 55 : 668-674, 2000
14. Rosas N, Sotelo J, Nieto D : ELISA in the diagnosis of neurocysticercosis. *Arch Neurol* 43 : 353-356, 1986
15. Torabi AM, Quiceno M, Mendelsohn DB, Powell CM : Multilevel intramedullary spinal neurocysticercosis with eosinophilic meningitis. *Arch Neurol* 61 : 770-772, 2004