

Case Report

Transient Global Aphasia with Hemiparesis Following Cerebral Angiography : Relationship to Blood Brain Barrier Disruption

Dong Ha Kim, M.D., Chang Hwa Choi, M.D., Ph.D., Jung Hwan Lee, M.D., Jae Il Lee, M.D.

Department of Neurosurgery, Pusan Cancer Center, School of Medicine, Pusan National University, Busan, Korea

Temporary disruption of the blood-brain barrier (BBB) after cerebral angiography is presumably caused by nonionic radiographic contrast medium (CM). We hereby report a case of 58-year-old woman who developed decreased mentality, global aphasia and aggravated right hemiparesis after cerebral angiography. Brain CT examination demonstrated gyriform enhancement throughout the left cerebral cortex and thalamus. MR diffusion did not reveal acute infarction. MR angiography did not show any stenosis, spasm or occlusion at the major cerebral vessels. Follow-up CT scan after 1 day did not show any gyriform enhancement. Worsened neurologic signs and symptoms were improved completely after 7 days. In the present study, disruption of the BBB with contrast medium after angiography seems to be the causative factor of transient neurologic deterioration.

KEY WORDS : Blood brain barrier (BBB) disruption · Contrast medium · Transient global aphasia · Transient hemiparesis · Cerebral angiography.

INTRODUCTION

Historically, cerebral angiography has been a key method in the diagnosis and planning the treatment of many intracranial lesions. However, it is an invasive procedure with potentially severe complications, but its incidence is low and most of the neurologic complications are transient or reversible⁶. The incidence of neurologic complications after cerebral angiography are related to subarachnoid hemorrhages (SAHs), atherosclerotic cerebrovascular diseases, arteriovenous malformations (AVMs), or episodes of recurrent transient ischemic attack (TIA)⁶.

Transient neurologic deficits such as transient cortical blindness, seizure attack, hemiparesis and aphasia following conventional angiography have been reported in the past^{1-3,9,13}. However, many patients who experienced transient neurologic deficit did not have such risk factors that can increase the incidence of neurologic complications. Some cases have been reported to be associated with disruption of the blood brain

barrier (BBB) after conventional angiography^{9,10,14,15}.

We report a case of transient global aphasia with hemiparesis associated with disruption of BBB and review of related literatures.

CASE REPORT

A 58-year-old woman with history of hypertension and intracerebral hemorrhage in thalamus that occurred two months prior to admission was referred to our institute with a diagnosis of unruptured intracranial aneurysms on magnetic resonance (MR) angiography (Fig. 1). On neurologic examination, there was no neurologic deficit except right sided mild hemiparesis. Routine transfemoral cerebral angiography was performed with contrast medium (Optiray®, Mallinckodt Medical, St. Louis, USA). During angiography, the patient was not given any medications except oxygen through nasal cannula. We confirmed the presence of two small aneurysms at the proximal portion of right anterior choroidal artery and left ophthalmic artery (Fig. 2). There were no stenotic lesions on cerebral angiography and no embolic events during the procedure. Following angiography, the patient showed drowsy mentality and global aphasia while right sided hemiparesis was aggravated. Brain computed tomography (CT) scans were immediately obtained, which showed marked high

• Received : December 27, 2009 • Revised : March 12, 2010
• Accepted : December 21, 2010
• Address for reprints : Chang Hwa Choi, M.D., Ph.D.
Department of Neurosurgery, Pusan National University Hospital,
305 Gudeok-ro, Seo-gu, Busan 602-739, Korea
Tel : +82-51-240-7257, Fax : +82-51-244-0282
E-mail : chwachoi@pusan.ac.kr

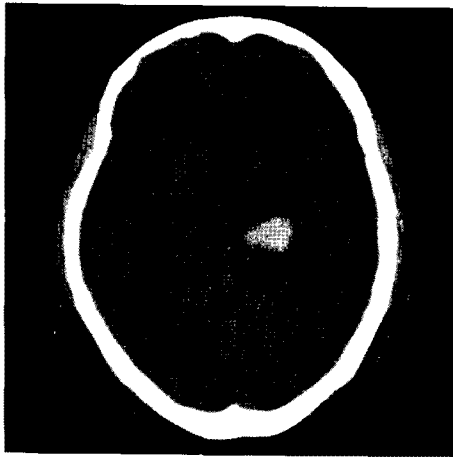


Fig. 1. Brain CT scan 2 months before shows intracerebral hematoma at thalamus.

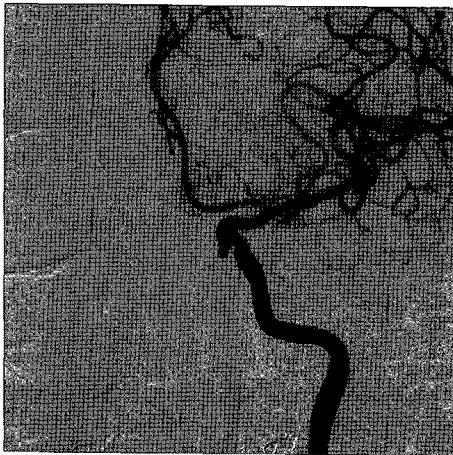

Fig. 2. Cerebral angiography demonstrates normal finding except left ophthalmic artery aneurysm.

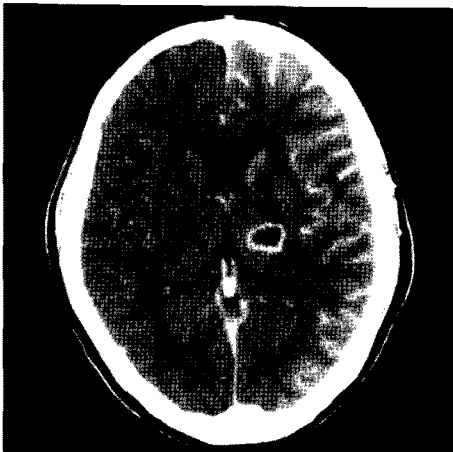


Fig. 3. Postangiographic brain CT scan shows gyriform enhancement of the left cerebral cortex and thalamus.

attenuation throughout the left cerebral cortex and thalamus (Fig. 3). Brain MR with diffusion image revealed no acute infarction (Fig. 4A). MR angiography demonstrated no stenosis or occlusion at the major cerebral vessels (Fig. 4B). The patient was treated with hydration and steroids. Twenty-

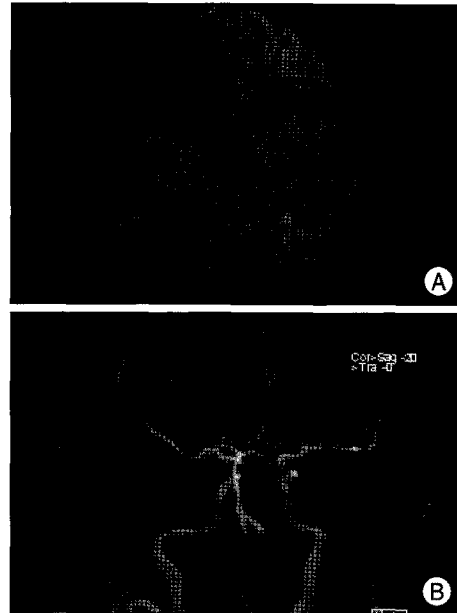


Fig. 4. Postangiographic brain MR diffusion-weighted image and angiography. A : There is no evidence of acute infarction on MR diffusion-weighted image. B : Brain MR angiography demonstrates no definite vasospasm.

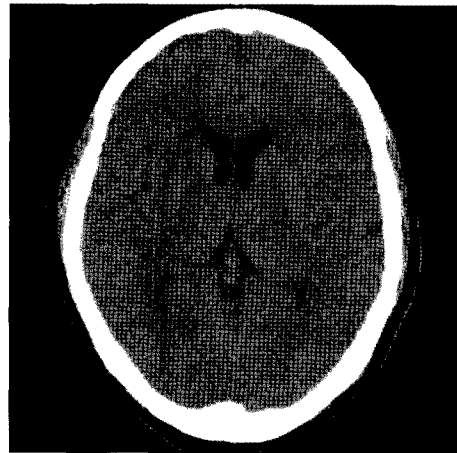


Fig. 5. Follow up CT scan after 22 hours. Note that the gyriform enhancement has disappeared.

four hours later, the neurologic symptoms and signs had recovered slowly. Repeat brain CT scan at that time demonstrated no enhancement on cerebral cortex and thalamus (Fig. 5). After 3 days, the mentality had completely recovered and aphasia also showed improvement. Global aphasia with hemiparesis had recovered completely after a week and the patient was discharged.

DISCUSSION

Cerebral angiography is associated with relatively low rates of complications⁶⁾. The rates of neurologic complications after cerebral angiography have been reported from 0.9% to 4%⁵⁾. The risk factors of neurologic complications following

angiography are SAHs, atherosclerotic cerebrovascular disease, AVMs and frequent histories of TIA⁶.

The mechanism of cerebral dysfunction causing transient neurologic deterioration after cerebral angiography still remains speculative. Transient neurologic deficits following cerebral angiography were previously assumed to result from embolism or factors that impair cortical perfusion, such as SAH or atherosclerotic disease during angiography¹³. However, contrast medium (CM)-induced disruption of the BBB and a direct neurotoxicities by CM have also been proposed as possible mechanisms of cerebral dysfunction¹³.

Following cerebral angiography, there have been rare reports of brain CT finding of abnormal high density in the cerebral cortex, in addition to temporary neurologic deficits resulting from disruption of the BBB related CM¹⁴. They are reported not only in cases of cerebral angiography but also in coronary, abdominal angiography or contrast-enhance CT^{1,7,9,10,13}. Some authors have reported transient cortical blindness after conventional angiography with occipital lobe enhancement^{1,3,13}. Others reported seizure attacks and transient hemiparesis or aphasia with diffuse unilateral cortex enhancement on non-contrast brain CT following conventional angiography^{9,14}.

The BBB has a complex physiological mechanism for maintaining the homeostasis of the neuronal environment¹⁰. In spite of the BBB being not permeable to CM1), transient breakdown of the BBB by radiographic CM is well described¹⁶. According to the previous literature, the transient breakdown of the BBB by the CM has been explained by hyperosmolality and chemotoxicity of the CM^{11,12}. Hypertonic solutions draw water out of the endothelial cells of cerebral vessels, as the cells shrink and the tight junctions separate out¹¹. The severity of the barrier disturbance is questionably related to the ionic and chemical contents of the medium (chemotoxic action)¹². Uchiyama et al reported that high iodine concentration, low temperature of the solutions (higher viscosity) and brief injection interval times may be relative factors contributing the BBB disruption through animal study¹⁵. Alternatively, some authors reported that possible mechanisms of the BBB breakdown could be due to microvascular sludging or arterial vasospasms⁸.

The finding of CT after disruption of the BBB following angiography is a diffuse high density in the cerebral cortex⁹. There were no signs of cerebral ischemia on diffusion-weighted MR images¹⁴. MR enhancement with gadolinium diethylenetriaminepentaacetic acid (Gd-DTPA) has recently proved to be capable of detecting the BBB disruption more sensitively and precisely than either MR without enhancement or CT¹⁵.

In this case study, the patient's neurologic deficits were right

sided hemiparesis and aphasia. Brain CT findings after angiography revealed diffuse high attenuation on the left cerebral cortex. No acute infarction or vasospasms were observed on brain MR image. The patient had no risk factors that could impair cerebral perfusion and also no embolic event had occurred during angiography. Thus, transient neurologic deteriorations could result from BBB disruption with contrast induced direct neurotoxicity to the left cerebral cortex.

We treated this phenomenon with hydration to increase the clearance rate of CM. Also, we used steroids. Corticosteroids were effective when the BBB was disrupted¹⁴. However, this phenomenon was known to transient¹⁻³. So, excessive treatment must be avoided.

CONCLUSION

This is a report of a rare case of transient global aphasia with hemiparesis after cerebral angiography, associated with the disruption of BBB. This phenomenon is clinically significant and could be attributed to hyperosmolality and chemotoxicity of CM. However, definite mechanism of transient BBB breakdown is still elusive. Thus, further experimental studies are required to provide substantial explanation for the variable contributors in the BBB breakdown.

References

- Alp BN, Bozbuga N, Tuncer MA, Yakut C : Transient cortical blindness after coronary angiography. *J Int Med Res* 37 : 1246-1251, 2009
- Alsarraf R, Carey J, Sires BS, Pinczower E : Angiography contrast-induced transient cortical blindness. *Am J Otolaryngol* 20 : 130-132, 1999
- Borowik H, Kulakowska A, Drozdowski W, Dubicki A, Krasnicki P : [Transient cortical blindness-a complication after coronary angiography--case report]. *Pol Merkur Lekarski* 24 : 430-432, 2008
- Greenberg MS: *Handbook of Neurosurgery*, ed 6th. New York : Greenberg Graphics, 2006, pp84-85
- Heiserman JE, Dean BL, Hodak JA, Flom RA, Bird CR, Drayer BP, et al. : Neurologic complications of cerebral angiography. *AJNR Am J Neuroradiol* 15 : 1401-1407; discussion 1408-1411, 1994
- Kaufmann TJ, Huston J, 3rd, Mandrekar JN, Schleck CD, Thielen KR, Kallmes DF : Complications of diagnostic cerebral angiography : evaluation of 19,826 consecutive patients. *Radiology* 243 : 812-819, 2007
- Mentzel HJ, Blume J, Malich A, Fitzek C, Reichenbach JR, Kaiser WA : Cortical blindness after contrast-enhanced CT : complication in a patient with diabetes insipidus. *AJNR Am J Neuroradiol* 24 : 1114-1116, 2003
- Nakai Y, Hyodo A, Okazaki M, Shibata Y, Matsumaru Y, Nose T : [Transient cortical blindness and convulsion mimicking a hemorrhagic complication during embolization of the cerebellar AVM]. *No Shinkei Geka* 27 : 249-253, 1999
- Numaguchi Y, Fleming MS, Hasuo K, Puyau FA, Nice CM Jr : Blood-brain barrier disruption due to cerebral arteriography : CT findings. *J Comput Assist Tomogr* 8 : 936-939, 1984
- Okazaki H, Tanaka K, Shishido T, Nagase H, Hoshino M, Takebayashi S, et al. : Disruption of the blood-brain barrier caused by nonionic contrast medium used for abdominal angiography : CT demonstration.

- J Comput Assist Tomogr 13 : 893-895, 1989
11. Rapoport SI, Thompson HK, Bidinger JM : Equi-osmolal opening of the blood-brain barrier in the rabbit by different contrast media. *Acta Radiol Diagn (Stockh)* 15 : 21-32, 1974
 12. Salvesen S, Nilsen PL, Holtermann H : Effects of calcium and magnesium ions on the systemic and local toxicities of the N-methyl-glucamine (Meglumine) salt of metrizoic acid (Isopaque). *Acta Radiol Diagn (Stockh) Suppl* 270 : 180+, 1967
 13. Shyn PB, Bell KA : Transient cortical blindness following cerebral angiography. *J La State Med Soc* 141 : 35-37, 1989
 14. Uchiyama Y, Abe T, Hirohata M, Tanaka N, Kojima K, Nishimura H, et al. : Blood brain-barrier disruption of nonionic iodinated contrast medium following coil embolization of a ruptured intracerebral aneurysm. *AJNR Am J Neuroradiol* 25 : 1783-1786, 2004
 15. Uchiyama Y, Abe T, Tanaka N, Kojima K, Uchida M, Hirohata M, et al. : Factors contributing to blood-brain barrier disruption following intracarotid injection of nonionic iodinated contrast medium for cerebral angiography: experimental study in rabbits. *Radiat Med* 24 : 321-326, 2006
 16. Wilson AJ, Evill CA, Sage MR : Effects of nonionic contrast media on the blood-brain barrier. Osmolality versus chemotoxicity. *Invest Radiol* 26 : 1091-1094, 1991