

Case Report

Successful Treatment of a Case with Rhino-Orbital-Cerebral Mucormycosis by the Combination of Neurosurgical Intervention and the Sequential Use of Amphotericin B and Posaconazole

Young Kyung Yoon, M.D.,¹ Min Ja Kim, M.D.,¹ Yong Gu Chung, M.D.,² Il Young Shin, M.D., Ph.D.²

Division of Infectious Diseases,¹ Departments of Internal Medicine, Neurosurgery,² College of Medicine, Korea University, Korea

Rhino-orbital-cerebral (ROC) mucormycosis is an uncommon, acute and aggressive fungal infection. It remains a challenging problem to clinicians despite aggressive debridement surgery and antifungal therapy. The authors describe a case of ROC mucormycosis with pericranial abscess occurring in a female patient with uncontrolled diabetes mellitus. The infection initially developed in the right-sided nasal sinus and later progressed through the paranasal sinuses with the invasion of the peri-orbital and frontotemporal region, due to the delayed diagnosis and treatment. Numerous non-septate hyphae of the zygomycetes were identified by a punch biopsy from the nasal cavity and by an open biopsy of the involved dura. The patient was treated successfully with extensive debridement of her necrotic skull and surrounding tissues, drainage of her pericranial abscess and antifungal therapy, including intravenous amphotericin B for 61 days and oral posaconazole for the following 26 days. She returned to a normal life and has had no recurrence since the end of her treatment 15 months ago.

KEY WORDS : Mucormycosis · Neurosurgery · Amphotericin B · Posaconazole.

INTRODUCTION

Mucormycosis is uncommon but has become more prevalent due to the growing number of patients with metabolic or immunologic imbalances¹⁶. It remains as a potentially lethal fungal infection, even though antifungal therapy and aggressive surgical intervention are currently available³. Rhinocerebral mucormycosis is the most common clinical form, accounting for about 50% of the reported cases, and the most fatal clinical category, compared to pulmonary, cutaneous, gastrointestinal and disseminated mucormycosis¹⁹. It is further divided into three subtypes : rhinomaxillary, rhinoorbital and rhino-orbital-cerebral (ROC)¹⁹. Approximately 70% of rhinocerebral cases were found in diabetic patients with ketoacidosis¹².

The survival rate is 82% for patients with isolated rhinomaxillary mucormycosis, whereas the prognosis is markedly poor in cases of cerebral involvement, with a survival rate of 38-50%, despite aggressive surgery, antifungal therapy and reversal of underlying predisposing factors^{16,19,23}. Surgical intervention has been relegated to an adjunctive role in the treatment of these patients because of deformed function and disfigurement of appearance from radical surgery. Importantly, angioinvasion, thrombosis and tissue necrosis of the disease might result in the poor penetration of antifungal agents to the site of the infection. In addition, amphotericin B penetrates poorly into the blood-brain barrier, making it difficult to achieve effective fungicidal levels in cerebral lesions. Therefore, surgical intervention should be considered in the treatment of mucormycosis with necrotic tissues and cerebral lesions.

Here, we describe a patient with ROC mucormycosis who was successfully treated by the strict control of blood sugar levels, sequential antifungal therapy of amphotericin B and posaconazole, as well as aggressive neurosurgical intervention.

• Received : July 9, 2009 • Revised : October 21, 2009

• Accepted : December 21, 2009

• Address for reprints : Il Young Shin, M.D., Ph.D.
Department of Neurosurgery, College of Medicine, Korea University,
126-1 Anam-dong 5-ga, Seongbuk-gu, Seoul 136-705, Korea
Tel : +82-2-920-5729, Fax : +82-2-929-5629
E-mail : kosaken@lycos.co.kr

CASE REPORT

A 46-year-old female presented with progressive peri-orbital swelling and headache for a week. She had received endoscopic sinus surgery and antibiotic treatment due to the right-sided sinusitis at a local ENT clinic 2 months prior to admission. An ophthalmologic examination on admission showed tenderness and erythema of the right upper eyelid and lacrimal sac, but no proptosis was visible. Her visual acuity was 20/20 OD and a fundoscopic examination revealed normal results. An endoscopic examination of her nasal cavities revealed necrotic materials with thick purulent discharge in the right side. Other physical and neurological findings did not reveal any out of the ordinary results. The laboratory values included a white blood cell count of 3,020 cells/microliter, with 66.5% neutrophils, hemoglobin of 9.8 g/dL, hematocrit of 28.6%, platelet count of 94,000 cells/microliter, a blood urea nitrogen concentration of 15.7 mg/dL, a serum creatinine of 0.9 mg/dL and C-reactive protein of 3.0 mg/L. Her random and fasting blood glucose levels were 213 and 138 mg/dL, respectively. HbA1c was 6.4%. She had no known history of diabetes before she presented with ROC mucormycosis.

We retrospectively reviewed the findings of a prior nasal biopsy from the local ENT clinic, which revealed copious fungal hyphae, suggestive of mucormycosis. Treatment with amphotericin B was immediately started. Magnetic resonance imaging (MRI) demonstrated high signals on the soft tissues of the right-sided maxillary and ethmoid sinuses, on the periorbital fat with local bony erosions in the infratemporal fossa and pericranial abscess in the frontotemporal region (Fig. 1A).

Because the patient refused to have aggressive debridement of her facial and peri-orbital lesions, she was medically treated with amphotericin B, up to 4,525 mg for the initial 30 days, along with the strict control of her blood glucose levels. When the follow-up MRI revealed pericranial abscess and osteomyelitis in the frontotemporal region, in spite of moderate improvement of her facial and peri-orbital lesions, she then agreed with the doctor's decision to undergo neurosurgical intervention. A frontal craniectomy showed osteomyelitis with extensive bone invasion and pericranial abscess in the frontotemporal region. Extensive bony debridement, removal of the involved dura and surrounding necrotic tissues and drainage of the pericranial abscess were performed. We used lyophilized dura (Lyodura, B. Braun Melsungen, Germany) and artificial bone grafts (Biobone, Johnson & Johnson, Tokyo, Japan) for the cranioplasty. A pathologic examination of her necrotic tissues revealed inflammation with neutrophils, lymphocytes,

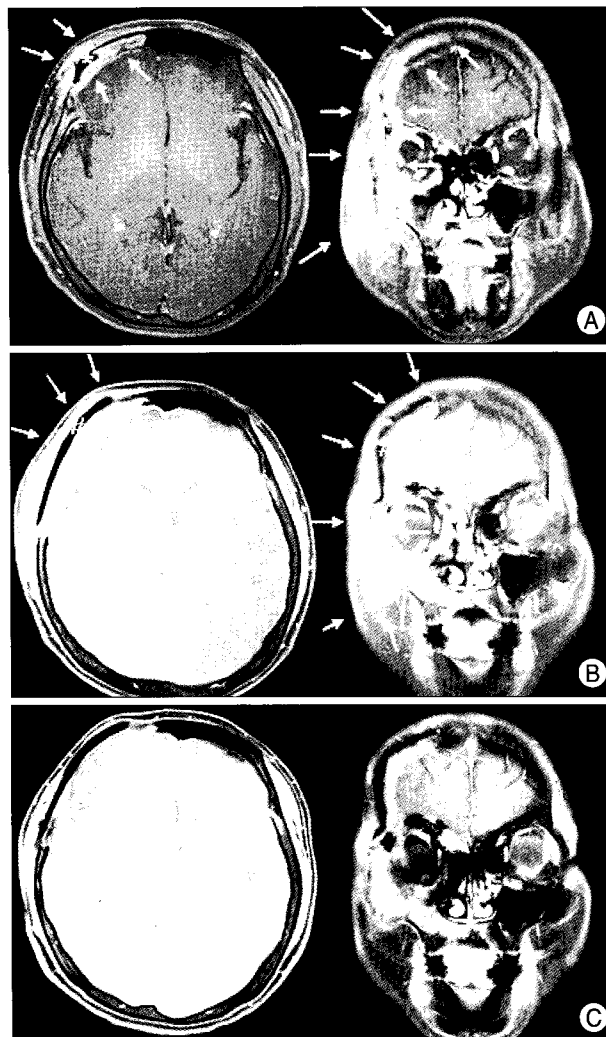


Fig. 1. Magnetic resonance images (MRI) of the lesion on admission (arrows). Postgadolinium T1-weighted axial magnetic resonance image shows pericranial abscess appearing as ring-enhancing lesion in the right frontotemporal region and extensive soft tissue infiltrating lesion with destruction of the skull vault (*). The coronal section shows the overall lesions before treatment (A). MRI before change of antifungal agent from amphotericin B to posaconazole shows markedly improved pericranial abscess and periorbital soft tissue lesion in the right frontotemporal region after surgical intervention (B; metallic artifact (#)). Magnetic resonance images of the lesion after treatment completion (C).

scattered multinucleated giant cells, and wide, nonseptate, right-angled branched hyphae on Hematoxylin and Eosin stain and the Gomori methenamine silver stain (Fig. 2). Hyphae were invading the cortical bone and skin of the frontal area. Fungal cultures of the removed tissue were negative. Amphotericin B was administered, up to a total of 5,225 mg, used for 31 days after the neurosurgery. She had no adverse effects related to amphotericin B. The follow-up MRI revealed the disappearance of the pericranial abscess by surgical removal and a decrease in the enhanced periorbital lesions, but residual lesions were present (Fig. 1B). Laboratory findings on the follow-up were normal except

for C-reactive protein of 3.5 mg/L. She was discharged from the hospital with a prescription of posaconazole (400mg twice daily) as an oral step-down therapy. The posaconazole was prescribed for a total of 26 days, when her symptoms and signs no longer existed and the C-reactive protein decreased to 0.32 mg/L. At the time of completion of her treatment, MRI showed more improvement (Fig. 1C). The patient has been disease free until the time of a 15 month follow-up from the completion of the treatment.

DISCUSSION

Rhinocerebral mucormycosis is easy to mistake for common bacterial sinusitis on initial diagnosis. A delay in diagnosis and appropriate therapy might be associated with high mortality. A multiplicity of underlying diseases can predispose to mucormycosis⁹. As diabetes mellitus is the most common risk factor, mucormycosis should be suspected in the patients with diabetes mellitus who are diagnosed with sinusitis. In our case, fungal sinusitis progressed to the ROC mucormycosis due to delayed diagnosis and

treatment. Similarly, previous reported cases in the Korean literature mostly involved patients having diabetes^{4,8,9} and were initially mis-diagnosed as having acute sinusitis¹⁰.

In the past decade, the aggressive surgical debridement of the lesions was considered as the treatment of choice for the ROC mucormycosis. Moreover, orbital exenteration was often indicated due to rapid extension into the orbits. With the advent of new therapeutic regimens, however, the treatment strategy now should include rapid diagnosis, reversal of underlying medical conditions, systemic use of antifungal agents and appropriate surgical debridement only as needed^{13,20}.

In the beginning of the treatment, our patient refused to have surgical debridement of her extensive facial and forehead lesions, because of the potential cosmetic problems and possible deformed functions of the face. But, her cerebral lesions showed no improvement with the medical therapy of amphotericin B and strict glucose control. Without the neurosurgical intervention, we think, it would have been far less likely for her to recover from the ROC mucormycosis.

Amphotericin B has been the first-line antifungal agent for rhinocerebral mucormycosis¹⁸. The majority of the cases reported in the Korean literature were treated with amphotericin B^{4,8-10}. In the meanwhile, it must be taken in account that amphotericin B does not readily penetrate the blood-brain barrier and might be ineffective in cerebral mucormycosis^{18,20}. Because there are no reliable anti-fungal agents, surgical debridement combined with antifungal therapy is inevitable in the treatment of cerebral mucormycosis^{1,2,7,16}. Although the extent and timing of surgical debridement necessary to maximize the outcomes of mucormycosis has never been defined, a recent study supports the concept of an "aggressive-conservative" approach, that uninvolved tissues spared from debridement when possible¹⁴.

Amphotericin B is limited in use by its renal and systemic toxic effects. New antifungal agents and a combination of existing agents in the treatment of mucormycosis have been reviewed recently^{6,11,17,20}. Posaconazole is a reasonable salvage option for patients with mucormycosis refractory to or intolerant to polyene therapy²². The available data are insufficient to support a significant role of primary treatment for mucormycosis^{15,21}, however, posaconazole is an option for the oral step-down therapy for patients who have responded to amphotericin B. The drug is also beneficial in treatment and prevention of any relapse of central nervous system mucormycosis²¹. Therefore, posaconazole might promise effective treatment to the ROC mucormycosis, even though more clinical experiences and clinical trial studies are needed.

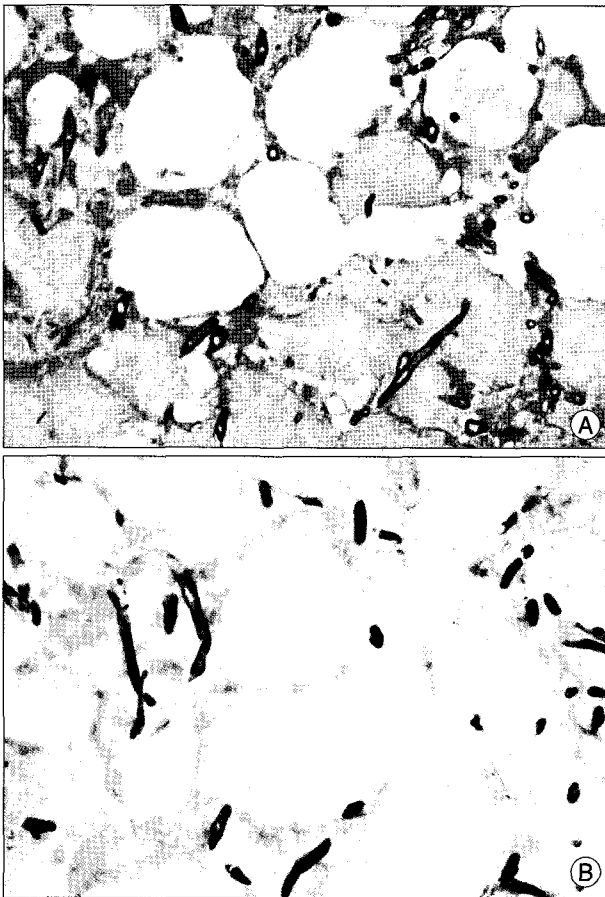


Fig. 2. Microscopic finding. Wide unseptate hyphae with obtuse or right angle branching (H & E stain, original magnification $\times 400$) (A), (Gomori-methanamine silver stain, $\times 400$) (B).

CONCLUSION

The authors report a case of cured rhino-orbital-cerebral mucormycosis complicated with osteomyelitis and pericranial abscess. This study gives support to the essential role that neurosurgical intervention as well as the potential advantage of posaconazole as an oral step-down therapy should play in the treatment of rhino-orbital-cerebral mucormycosis.

• Acknowledgements

The authors wish to thank Prof. Nam Joon Lee, the Department of Radiology, Korea Univ. Hospital for his valuable assistance during this work. Also, we would like to thank Prof. Chul Hwan Kim and Dr. Jeong Hyeon Lee, the Department of Pathology, Korea Univ. Hospital for their helpful pathological review.

References

- Bhansali A, Bhadada S, Sharma A, Suresh V, Gupta A, Singh P, et al. : Presentation and outcome of rhino-orbital-cerebral mucormycosis in patients with diabetes. *Postgrad Med J* 80 : 670-674, 2004
- Chakrabarti A, Das A, Mandal J, Shivaprakash MR, George VK, Tarai B, et al. : The rising trend of invasive zygomycosis in patients with uncontrolled diabetes mellitus. *Med Mycol* 44 : 335-342, 2006
- Chakrabarti A, Das A, Sharma A, Panda N, Das S, Gupta KL, et al. : Ten years' experience in zygomycosis at a tertiary care centre in India. *J Infect* 42 : 261-266, 2001
- Choi HY, Lew JM : Rhinocerebral mucormycosis combined with brain abscess. *J Korean Soc Plast Reconstr Surg* 16 : 363-371, 1989
- deShazo RD, Chapin K, Swain RE : Fungal sinusitis. *N Engl J Med* 337 : 254-259, 1997
- Diekema DJ, Messer SA, Hollis RJ, Jones RN, Pfaller MA : Activities of caspofungin, itraconazole, posaconazole, ravuconazole, voriconazole, and amphotericin B against 448 recent clinical isolates of filamentous fungi. *J Clin Microbiol* 41 : 3623-3626, 2003
- Han SR, Choi CY, Joo M, Whang CJ : Isolated cerebral mucormycosis. *J Korean Neurosurg Soc* 42 : 400-402, 2007
- Jeong H, Kang PJ, Lee JY, Cha KS, Lee ID, Son DH, et al. : A case of rhinocerebral mucormycosis associated with diabetes mellitus. *Korean J Med* 39 : 715-720, 1990
- Kim HJ, Choung YH, Cho MJ, Baik SS : Clinical analysis of eight cases of mucormycosis. *J Clin Otolaryngol* 15 : 134-138, 2004
- Lee CH, Jinn TH, Choi HY, Kim JY : Two cases of rhinocerebral mucormycosis. *Korean J Otorhinolaryngol-Head Neck Surg* 32 : 139-144, 1989
- Marom T, Watad W, Dan M, Roth Y : Posaconazole for bone-involving rhinomaxillary mucormycosis. *Otolaryngol Head Neck Surg* 140 : 610-611, 2009
- McNulty JS : Rhinocerebral mucormycosis : predisposing factors. *Laryngoscope* 92 : 1140-1143, 1982
- Peterson KL, Wang M, Canalis RF, Abemayor E : Rhinocerebral mucormycosis : evolution of the disease and treatment options. *Laryngoscope* 107 : 855-862, 1997
- Reed C, Bryant R, Ibrahim AS, Edwards J Jr, Filler SG, Goldberg R, et al. : Combination polyene-caspofungin treatment of rhino-orbital-cerebral mucormycosis. *Clin Infect Dis* 47 : 364-371, 2008
- Rickerts V, Atta J, Herrmann S, Jacobi V, Lambrecht E, Bialek R, et al. : Successful treatment of disseminated mucormycosis with a combination of liposomal amphotericin B and posaconazole in a patient with acute myeloid leukaemia. *Mycoses* 49 Suppl 1 : 27-30, 2006
- Roden MM, Zaoutis TE, Buchanan WL, Knudsen TA, Sarkisova TA, Schaufele RL, et al. : Epidemiology and outcome of zygomycosis : a review of 929 reported cases. *Clin Infect Dis* 41 : 634-653, 2005
- Rogers TR : Treatment of zygomycosis: current and new options. *J Antimicrob Chemother* 61 Suppl 1 : i35-i40, 2008
- Scully EP, Baden LR, Katz JT : Fungal brain infections. *Curr Opin Neurol* 21 : 347-352, 2008
- Spellberg B, Edwards J Jr, Ibrahim A : Novel perspectives on mucormycosis : pathophysiology, presentation, and management. *Clin Microbiol Rev* 18 : 556-569, 2005
- Spellberg B, Walsh TJ, Kontoyiannis DP, Edwards J Jr, Ibrahim AS : Recent advances in the management of mucormycosis: from bench to bedside. *Clin Infect Dis* 48 : 1743-1751, 2009
- Tarani L, Costantino F, Notheis G, Wintergerst U, Venditti M, Di Biasi C, et al. : Long-term posaconazole treatment and follow-up of rhino-orbital-cerebral mucormycosis in a diabetic girl. *Pediatr Diabetes* 10 : 289-293, 2009
- van Burik JA, Hare RS, Solomon HF, Corrado ML, Kontoyiannis DP : Posaconazole is effective as salvage therapy in zygomycosis : a retrospective summary of 91 cases. *Clin Infect Dis* 42 : e61-e65, 2006
- Yohai RA, Bullock JD, Aziz AA, Markert RJ : Survival factors in rhino-orbital-cerebral mucormycosis. *Surv Ophthalmol* 39 : 3-22, 1994