

Laboratory Investigation

Morphometric Study of the Korean Adult Pituitary Glands and the Diaphragma Sellae

Kyo-Sung Ju, M.D.,¹ Hack-Gun Bae, M.D.,¹ Hyung-Ki Park, M.D.,¹ Jae-Chil Chang, M.D.,¹ Soon-Kwan Choi, M.D.,¹ Ki-Bum Sim, M.D.²

Department of Neurosurgery,¹ Soonchunhyang University Cheonan Hospital, Cheonan, Korea

Department of Neurosurgery,² Jeju National University, Jeju, Korea

Objective : To investigate the morphometric characteristics of the pituitary gland and diaphragma sellae in Korean adults.

Methods : Using the 33 formaline fixed adult cadavers (23 male, 10 female), the measurements were taken at the diaphragma sellae and pituitary gland. The authors investigated the relationship between dura and structures surrounding pituitary gland, morphometric aspects of pituitary gland and stalk, and morphometric aspect of central opening of diaphragma sellae.

Results : The boundary between the lateral surface of pituitary gland and the medial wall of cavernous sinus was formed by the thin dural layer and pituitary capsule. The pituitary capsule adherent tightly to the pituitary gland was observed to continue from the diaphragma sellae. Mean width, length, and height of the pituitary gland were 14.3 ± 2.1 , 7.9 ± 1.3 , and 6.0 ± 0.9 mm in anterior lobes, and 8.7 ± 1.7 , 2.9 ± 1.1 , and 5.8 ± 1.0 mm in posterior lobes, respectively. Although all dimensions of anterior lobe in female were slightly larger than those in male, statistical significance was noted in only longitudinal dimension. The ratio of posterior lobe to the whole length of pituitary gland was about 27%. The mean thickness of pituitary stalk was 2 mm. The diaphragmal opening was 5 mm or more in 26 (78.8%) of 33 specimen. The opening was round in 60.6% of the specimen, and elliptical oriented in an anterior-posterior or transverse direction in 39.4%.

Conclusion : These results provide the safe anatomical knowledge during the transsphenoidal surgery and may be helpful to access the possibility of the development of empty sella syndrome.

KEY WORDS : Pituitary gland · Diaphragma sellae · Cadaver.

INTRODUCTION

The pituitary gland is situated within the hypophyseal fossa which is limited anteriorly, posteriorly, and inferiorly by bony constituents of the sella turcica¹⁾. Both lateral and superior aspects of the pituitary gland are covered by the thin layer of dura composing the medial wall of cavernous sinus and the diaphragma sellae¹⁵⁾. However, the border between the medial wall of cavernous sinus and the lateral portion of pituitary gland remain poorly understood.

Even though magnetic resonance imaging (MRI) allows accurate estimation of the size and shape of the pituitary gland, 22% of pituitary glands studied autopsy are com-

pressed to some degree by the carotid artery^{3,8)}. In addition, the transverse dimension of the gland cannot be ascertained simply by determining the width of the dorsum sellae or the floor of the sella turcica⁸⁾. The adult hypophysis has been known to be approximately 10 mm in length, 10 to 15 mm in width, and about 5 mm in height⁸⁾. However, to our knowledge, there has not been a report with regards to separate measurement of size of the anterior and posterior lobes in Koreans. Diabetes insipidus is the most common complication resulting from the injury of pituitary posterior lobe at the surgery of pituitary adenoma. Thus, it is very important to know the demarcation and the size of the pituitary anterior and posterior lobes to reduce the complications at the surgery through the transsphenoidal approach for the removal of pituitary tumor.

The central aperture of the diaphragm is of variable size, ranging from small foramen to a large hole and transmits the pituitary stalk and its blood supply. The size of the aperture is important in protecting the gland from trans-

• Received : December 4, 2008 • Revised : November 12, 2009
• Accepted : November 30, 2009
• Address for reprints : Hack-Gun Bae, M.D.
Department of Neurosurgery, Soonchunhyang University Cheonan Hospital, 23-20 Bongmyeong-dong, Cheonan 330-721, Korea
Tel : +82-41-570-3648, Fax : +82-41-572-9297
E-mail : hgbaeb@schca.ac.kr

mitted pulsations of the choroids plexus or in defending the visual fibers against suprasellar extension of an expanding pituitary tumor⁸). In some instances, the arachnoid membrane herniates extensively through an incompetent diaphragma sellae, resulting in the lesion known as the empty sella syndrome²). Thus, morphometric study for the central aperture of the diaphragm sellae may help to prevent the cerebrospinal fluid leak, optic nerve injury, or other brain tissue injury. The variability in the diameter of the opening of the diaphragma sellae could explain the growth of pituitary tumors toward the cavernous sinus or toward the suprasella region⁴). The purpose of this study was to provide the anatomical knowledge more safe at the transsphenoidal approach for the pituitary tumor through the morphometric study of the pituitary gland and diaphragma sellae.

MATERIALS AND METHODS

A total of 33 formaline fixed adult cadavers (23 male, 10 female) were used in this study. The mean age was 55.3 ± 15.4 years (range 23-87 years) in male and 62.8 ± 19.1 years (range 28-76 years) in female. The brain and its skull covering were removed, exposing the skull base. The types of the central opening of the diaphragma sellae and the relationship between the dural structures surrounding pituitary gland and the dura of diaphragma sellae were investigated. The central opening of the diaphragma sellae was divided into open and closed types. The longest diameter of the central opening of the diaphragma sellae was 5 mm or more in open type and less than 5 mm in closed type (Fig. 1). When the dorsum sellae was pushed down by cut of its base, the posterior lobe of pituitary gland was placed in the concave cavity of dorsum sellae and easily separated from the dura of dorsum sellae without adhesion (Fig. 2). After en-bloc removal of the pituitary gland, the relationship between dura and structures surrounding pituitary gland, morphometric aspects of pituitary gland and stalk, and morphometric aspect of central opening of diaphragma sellae were studied. The morphometric results of pituitary gland according to sex difference were compared using t-test. A probability value lower than 0.05 was considered statistically significance.

RESULTS

Relationship between dura and structures surrounding pituitary gland

Diaphragma sellae was continuous with the dura mater covering tuberculum sellae, anterior clinoid process, superior

aspect of dorsum sellae and posterior clinoid process (Fig. 1). The undersurface of pituitary gland was easily separated from the endosteal layer of sellar floor. The capsule encircling the pituitary gland was very thin and semitransparent

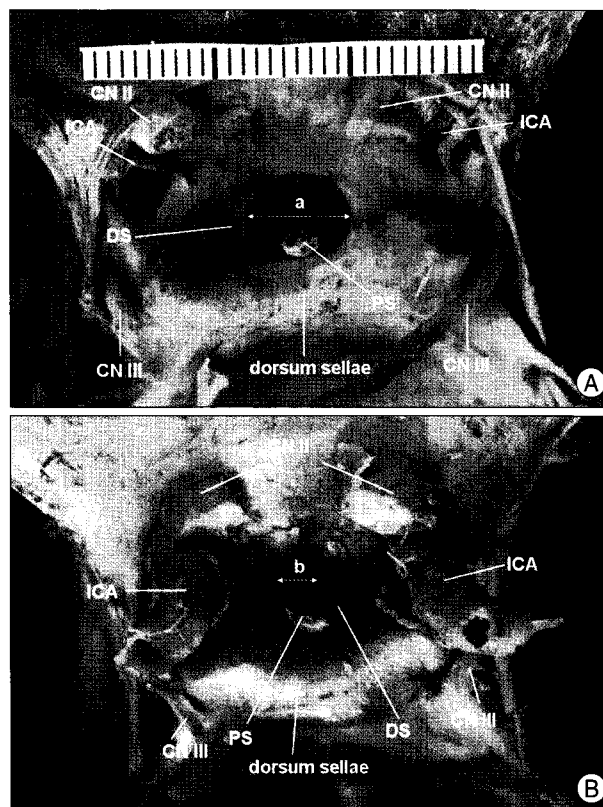


Fig. 1. Photographs showing the dural relationship between the diaphragm and its surrounding structures. Diaphragma sellae is continuous with the dura mater covering tuberculum sellae, anterior clinoid process, superior aspect of dorsum sellae and posterior clinoid process. The largest diameter of central opening of diaphragm (a and b) is more than 5 mm in open type (A) and less than 5 mm in closed type (B). CN : cranial nerve, DS : dorsum sellae, ICA : internal carotid artery, PS : pituitary stalk.

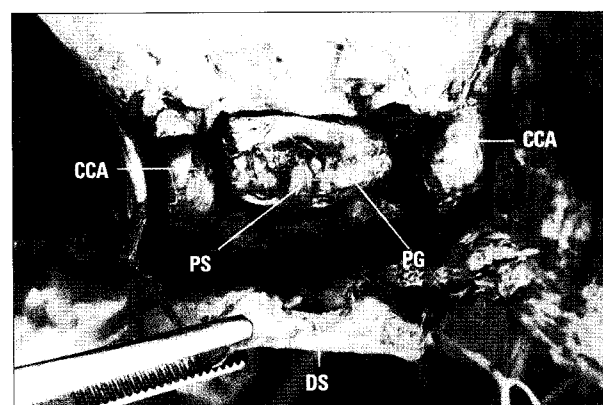


Fig. 2. Photograph showing the relation between pituitary gland and surrounding structures. Pituitary gland has been completely divided from the cavernous carotid artery (CCA) and dorsum sellae. The thin dural layer forming the medial wall of CCA could not be separated into an inner and an outer layer, as could the lateral of CCA. DS : dorsum sellae, PG : pituitary gland, PS : pituitary stalk.

membrane and tightly adhesive to the pituitary gland. The lateral surface of pituitary gland was bordered upon the medial wall of cavernous sinus by a thin dural layer, so called meningeal dural layer, which could not be separated into an inner and outer layer as could the lateral of cavernous sinus.

This layer seemed to be continuous with the the endosteal layer of sellar floor and the dural fold of diaphragma sellae (Fig. 3). Thus, sella floor and undersurface of pituitary gland were composed of two layers of dura, one was continuous with sphenoid bone and the other

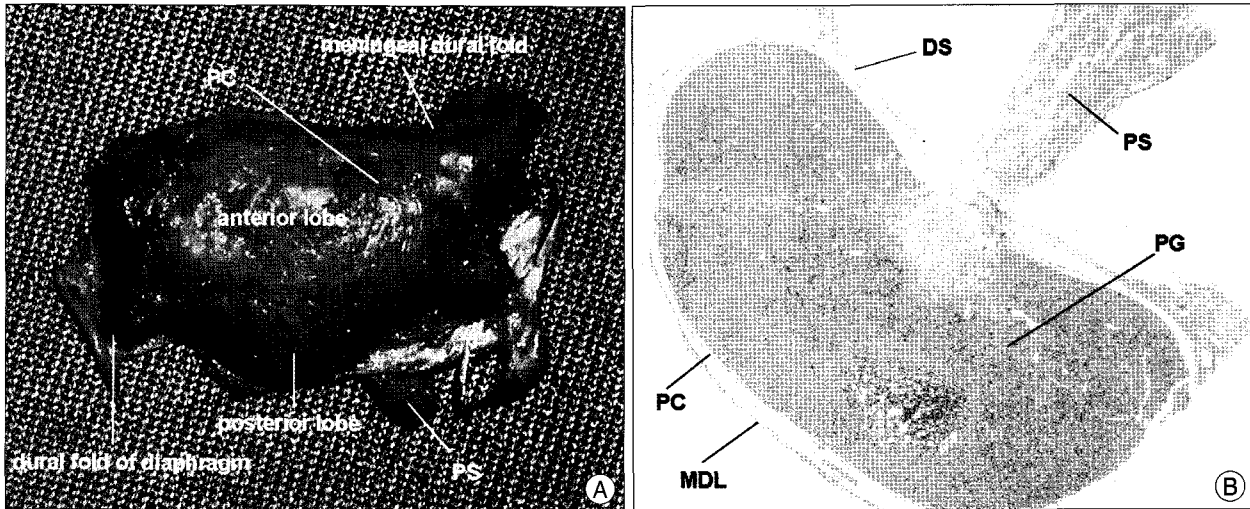


Fig. 3. Photograph showing the inferior view of the pituitary gland (A). Dural fold of diaphragm is visible. The single layer representing the meningeal dural layer comes from the diaphragm and wraps around the pituitary gland. Photomicrograph showing the coronal section of the pituitary gland and stalk (B). Pituitary capsule which is composed of thin fibrotic capsule, encircles and tightly adhesive to the pituitary gland. It is continuous with the superior lateral margin of pituitary gland. The lateral surface of pituitary capsule is bordered by a thin dural layer, so called meningeal dural layer, which is continuous with the dural fold of diaphragma sellae superiorly and encircles undersurface of the pituitary gland inferiorly. DS : diaphragma sellae, MDL : meningeal dural layer, PC : pituitary capsule, PG : pituitary gland, PS : pituitary stalk.

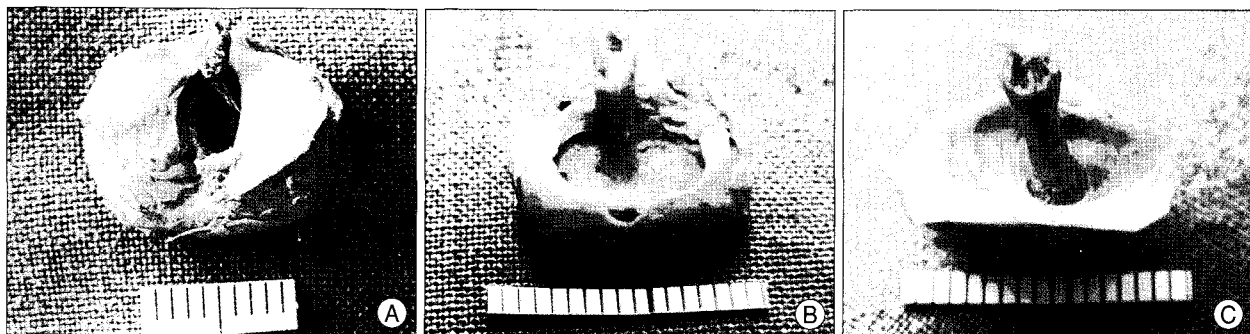


Fig. 4. Photograph showing the variable size and shapes of the central aperture of the diaphragm. Elliptical shape of open type (A), round shape of open type (B), and close type (C) are visible.




Fig. 5. Photographs showing the measurements of pituitary gland and stalk on antero-superior (A) and postero-superior (B) and lateral views (C). A : transverse dimension of anterior lobe, B : transverse dimension of pituitary stalk, C : transverse dimension of posterior lobe, D : height of anterior lobe, E : height of posterior lobe, F : longitudinal dimension of anterior lobe, G : longitudinal dimension of posterior lobe, H : longitudinal dimension of pituitary stalk.

composing the medial wall of cavernous carotid artery encircled the pituitary gland. The pituitary capsule was continuous with the superior lateral margin of pituitary gland.

Morphometric aspect of pituitary gland and pituitary stalk

Pituitary gland showed ovoid or round configuration (Fig. 4). The gland was generally wider than it was longer. The lateral border between anterior and posterior lobes of pituitary gland was slightly depressed by lobulated configuration of each lobe, which made a clear distinction between anterior and posterior lobes (Fig. 5). The mean width of pituitary gland was 14.3 ± 2.1 mm in anterior lobe and 8.7 ± 1.7 mm in posterior lobe. Sagittal dimension of pituitary gland was the mean 10.7 ± 1.6 mm, 7.9 ± 1.3 mm in anterior lobe and 2.9 ± 1.1 mm in posterior lobe. The heights from the each floor of anterior and posterior lobes to the diaphragma sellae were 6.0 ± 0.9 mm and 5.8 ± 1.0 mm, respectively. Posterior lobe occupied approximately 27.1% to the whole sagittal length of pituitary gland and approximately 60.8% to the mean width of anterior lobe. Female had a tendency to be slightly greater in all dimensions of anterior pituitary lobe, whereas male had a tendency to be slightly greater in all dimensions of posterior lobe than those in female, but statistical significance was noted in only longitudinal dimension of anterior lobe ($p = 0.031$). The pituitary stalk was measured at the midportion of the stalk. The width of pituitary stalk was an average 1.9 ± 0.3 mm (range 1.4-2.8 mm) and was greater in female compared with that in male ($p < 0.041$). The sagittal dimension was an average 1.8 ± 0.4 mm (range 2.6-1.0 mm) and was also slightly longer in female, but there was not statistically significant (Table 1). The width of stalk was slightly greater than sagittal dimension. In consideration of the dehydration of specimen, these results are considered to be somewhat low.

Morphometric aspect of central opening of diaphragma sellae

In 20 (60.6%) of the total 33 specimen, central opening of diaphragma sellae showed round appearance slightly longer in width than sagittal dimension, whereas 13 (39.4%) showed elliptical shape longer in sagittal dimension than width. The mean diameter of the central opening of diaphragma sellae based on the largest dimension was 6.8 ± 1.7 mm. The open type more than 5 mm in the largest diameter of central opening of diaphragma sellae was noted in 26

Table 1. Comparison of mean dimensions of pituitary gland and stalk according to sex difference

Variables	Mean dimension \pm SD (mm)			p-value
	Male (n = 23)	Female (n = 10)	Total	
Anterior lobe				
Transverse	13.9 ± 1.8	15.4 ± 2.5	14.3 ± 2.1	0.144
Longitudinal	7.5 ± 1.1	8.8 ± 1.4	7.9 ± 1.3	0.031
Height	6.0 ± 1.0	6.2 ± 0.8	6.0 ± 0.9	0.741
Posterior lobe				
Transverse	8.8 ± 1.8	8.6 ± 1.3	8.7 ± 1.7	0.841
Longitudinal	3.0 ± 1.2	2.5 ± 0.9	2.9 ± 1.1	0.330
Height	5.8 ± 1.0	5.7 ± 1.1	5.8 ± 1.0	0.881
Pituitary stalk				
Transverse	1.8 ± 0.2	2.1 ± 0.4	1.9 ± 0.3	0.041
Longitudinal	1.8 ± 0.5	1.9 ± 0.3	1.8 ± 0.4	0.573

SD : standard deviation

Table 2. Morphometric aspect of diaphragma sellae

Types of central aperture*	Numbers (%)	Dimension (mm) †
Open	26 (78.8)	7.3 ± 1.3
Close	7 (21.2)	4.4 ± 0.4
Total	33 (100)	6.8 ± 1.7

*Open and close types mean 5 mm or more and less than 5 mm in the largest diameter of central opening of diaphragma sellae, respectively.

† Dimension is expressed as mean \pm standard deviation

specimen (78.8%) and closed type was noted in 7 specimen (21.2%). The diameter of the central opening of diaphragma sellae was the mean 7.3 ± 1.3 mm in open type and 4.4 ± 0.4 mm in close type (Table 2).

DISCUSSION

The dura covering the lateral wall and roof of the cavernous sinus consists of an endosteal layer lining the bone and a meningeal layer facing the brain¹⁵. However, the border between the medial wall of cavernous sinus and the lateral portion of pituitary gland remain poorly understood. Some reports suggest that there is no medial wall of the cavernous sinus and that the pituitary capsule separates the pituitary gland from the cavernous sinus^{5,16}. Recently, Yasuda et al.¹⁵ demonstrated that the cavernous sinus has a single dural layer that separates the cavernous sinus from the sella and capsule of the pituitary gland. The medial wall has two segments, sellar and sphenoidal, and the sellar part of medial wall is formed by a very thin meningeal layer, which is a continuation of the upper layer of diaphragm sellae. The sphenoidal part of the medial wall was observed to be formed by a single layer of endosteal dura mater¹⁵. In this study, very thin single layer suspending meningeal dura could be observed in the medial portion of the cavernous internal carotid artery and it continued from the diaphra-

gma sellae. The capsule adherent tightly to the pituitary gland was observed to continue from the diaphragma sellae. The pituitary capsule was a well-defined structure and was different from the medial wall. Thus, the boundary between the lateral surface of pituitary gland and the medial wall of cavernous sinus was formed by the thin dural layer and pituitary capsule.

Even though modern radiographic techniques like MRI allow accurate estimation of the size and shape of the pituitary gland and have supplanted earlier methods based on roentgenographic measurement, in previous autopsy study, 22% of pituitary gland were compressed to some degree by the carotid artery^{3,8)}, and 23% of gland had a superior-to-inferior dimension at least 2 mm less than the depth of the pituitary fossa, with the dimension of some glands being less than half this depth⁸⁾. Thus, the dimension of the gland cannot be ascertained simply by determining the width of the dorsum sellae or the floor of the sella turcica. The adult hypophysis measures approximately 10 mm in length, 10 to 15 mm in width, and about 5 mm in height⁸⁾. In this study, the mean size of the pituitary gland measured 8 mm in length, 14 mm in width, and 6 mm in height. On average of width, length and height of anterior pituitary lobe, the female has a tendency to be slightly longer than male gland, but the statistical significance was only noted in the length of anterior pituitary gland. There was not statistically significant according to the difference of sex in the size of posterior pituitary lobe. Posterior lobe occupied approximately 27.1% to the whole sagittal length of pituitary gland and approximately 60.8% to the mean width of anterior lobe. In view of the sellar floor, posterior lobe is considered to locate in the posterior 1/4 of pituitary fossa. Regarding with the height of pituitary gland, Tsunoda et al.¹⁴⁾ reported a difference of height of pituitary gland according to the sex and age based on the magnetic resonance imaging. By their results, the mean pituitary height was 5.1 mm and female was greater than that in male. The height peaked in the 20 to 29 age group and tended to decline with age. However, female had a tendency for pituitary height to increase again in the 50 to 59 age group¹⁴⁾. There has been a suggestion that this second increase in female may reflect high concentrations of gonadotropic hormones, apparently due to an age-related decline in circulating gonadal steroids and an increase in gonadotropin-releasing hormones^{6,13,14)}. The height of pituitary gland usually means that of anterior lobe because of higher in the height of anterior lobe compared with that of posterior lobe. In this study, the authors did not measure the pituitary gland according the specific age group because of the lack of specimen. The mean height of pituitary gland was 6.2 mm in female and 6 mm in male specimen. Even

though the height of pituitary gland was higher in female compared with male, there was not statistically significant.

Pituitary stalk enlargement can occur in infiltrative diseases such as hemochromatosis, sarcoidosis, Wilson's disease, infections, and intracranial and metastatic tumors^{7,9)}. In an adult, the diagnosis of pituitary stalk enlargement is entertained when the stalk diameter exceeds 4 mm⁹⁾. In pediatric group, pituitary stalk enlargement can be considered when a diameter greater than 2 mm measured in at least one portion of the pituitary stalk^{11,12)}. However, such results are based on the radiological findings. In this study, the mean diameter measured at the mid portion of stalk was 2 mm or less. The width of stalk was greater than sagittal dimension and was wider in female compared with male. In consideration of the dehydration of specimen, these results can be considered somewhat low.

The diaphragma sellae forms the roof of the sella turcica and covers the pituitary gland. The central aperture of the diaphragm transmits the pituitary stalk and its blood supply. The size of the aperture and the relative competence of the diaphragma are important factors in protecting the pituitary gland from transmitted pulsation of the choroid plexus or in defending the visual fibers against suprasellar extension of an expanding pituitary tumor⁸⁾. In some instances, the arachnoid membrane herniates extensively through an incompetent diaphragma sellae, resulting in the lesion known as the empty sella syndrome²⁾. This condition is found in 5% to 23% of autopsy cases²⁾. The central aperture of diaphragma is of variable size. About 10% of autopsy cases having the diaphragmal opening greater than 5 mm in size have been considered too thin to serve as reliable barriers against easy penetration during transsphenoidal procedures³⁾. In the autopsy studies, diaphragmal opening greater than 5 mm in size has been reported to be 39-56%^{3,10)}. In this study, the open type more than 5 mm in the largest diameter of central opening of diaphragma sellae was noted in 78.8%. The diameter of the central opening of diaphragma sellae was mean of 7.3 ± 1.3 mm in open type and 4.4 ± 0.4 mm in close type. The contour of opening was also variable. Round shape was found in 60.6% and elliptical in 39.4%. In other report, the opening was round in 54% of the autopsy cases, and elliptical in 46%¹⁰⁾.

CONCLUSION

The pituitary capsule is a well-defined structure and is different from the medial wall of cavernous sinus. The gland is generally wider than it is longer. The lateral and inferior borders between anterior and posterior lobes of pituitary gland can be clearly distinguished because of the slight

depression by lobulated configuration of each lobe. The posterior lobe of pituitary gland occupies the posterior 1/4 of whole longitudinal dimension of the pituitary gland. The mean diameter of pituitary stalk is less than 2 mm in cadaveric specimen. More than 78% is the open type and more than 5 mm in the largest diameter of central opening of diaphragma sellae and the contour of opening is also variable. These results may provide the safe anatomical knowledge during the transsphenoidal approach for the removal of the pituitary tumor and may be helpful to access the possibility of the development of empty sella syndrome.

References

1. Amar AP, Weiss MH : Pituitary anatomy and physiology. *Neurosurg Clin N Am* 14 : 11-23, 2003
2. Aron DC, Findling JW, Tyrell JB : Hypothalamus and pituitary in Greenspan FS, Strewler GJ (eds) : *Basic and clinical endocrinology*, ed 5. Stanford : Appleton & Lange, 1997, pp95-156
3. Bergland RM, Ray BS, Torack RM : Anatomical variations in the pituitary gland and adjacent structures in 225 human autopsy cases. *J Neurosurg* 28 : 93-99, 1968
4. Campero A, Martins C, Yasuda A, Rhoton AL Jr : Microsurgical anatomy of the diaphragma sellae and its role in directing the pattern of growth of pituitary adenomas. *Neurosurgery* 62 : 717-723; discussion 717-723, 2008
5. Dietemann JL, Kehrli P, Maillot C, Diniz R, Reis M Jr, Neugroschl C, et al. : Is there a dural wall between the cavernous sinus and the pituitary fossa? Anatomical and MRI findings. *Neuroradiology* 40 : 627-630, 1998
6. Elster AD, Chen MY, Williams DW 3rd, Key LL : Pituitary gland : MR imaging of physiologic hypertrophy in adolescence. *Radiology* 174 : 681-685, 1990
7. Kimmel DW, O'Neill BP : Systemic cancer presenting as diabetes insipidus. Clinical and radiological features of 11 patients with a review of metastatic-induced diabetes insipidus. *Cancer* 52 : 2355-2358, 1983
8. Kirgis HD, Locke W : Anatomy and embryology in Locke W, Schally AV (eds) : *The hypothalamus and pituitary in health and disease*. Charles C. Thomas : Spring-field, 1972, pp3-65
9. Puig ML, Webb SM, Del Pozo C, de Juan M, Serrano S, Vilardell E : Endocrine aspects of pituitary stalk enlargement. *Clin Endocrinol (Oxf)* 27 : 25-32, 1987
10. Rhoton AL Jr : The sellar region. *Neurosurgery* 51 : S335-S374, 2002
11. Seidel FG, Towbin R, Kaufman RA : Normal pituitary stalk size in children : CT study. *AJR Am J Roentgenol* 145 : 1297-1302, 1985
12. Simmons GE, Suchnicki JE, Rak KM, Damiano TR : MR imaging of the pituitary stalk : size, shape and enhancement pattern. *Am J Roentgenol* 159 : 375-377, 1992
13. Simpkins JW, Estes KS : Role of monoaminergic neurons in the age-related alterations in anterior pituitary secretion in Nemeroff CB, Duun AJ (eds) : *Peptides, Hormones and Behaviors*. New York : Spectrum Press, 1984, pp823-863
14. Tsunoda A, Okuda O, Sato K : MR height of the pituitary gland as a function of age and sex : especially physiological hypertrophy in adolescence and in climacterium. *AJNR Am J Neuroradiol* 18 : 551-554, 1997
15. Yasuda A, Campero A, Martins C, Rhoton AL, Ribas GC : The medial wall of the cavernous sinus : microsurgical anatomy. *Neurosurgery* 55 : 179-189; discussion 189-190, 2004
16. Yokoyama S, Hirano H, Moroki K, Goto M, Imamura S, Kuratsu JI : Are nonfunctioning pituitary adenomas extending into the cavernous sinus aggressive and/or invasive? *Neurosurgery* 49 : 857-862; discussion 862-863, 2001