

Laboratory Investigation

Different Expression of Extracellular Matrix Genes : Primary vs. Recurrent Disc Herniation

Sung-Uk Kuh, M.D., Young-Min Kwon, M.D., Dong-Kyu Chin, M.D., Keun-Su Kim, M.D., Byung-Ho Jin, M.D., Yong-Eun Cho, M.D.

Department of Neurosurgery, Spine and Spinal Cord Institute, Yonsei University College of Medicine, Seoul, Korea

Objective : Recurrent lumbar disc herniation has been reported to occur in 5% to 15% of surgically treated primary lumbar disc herniation cases. We investigated the molecular biologic characteristics of primary herniated discs and recurrent discs to see whether the recurrent discs has the similar biological features with primary herniated discs.

Methods : Primary herniated disc and recurrent disc cells were obtained by discectomy of lumbar disc patients and cells were isolated and then taken through monolayer cultures. We compared chondrogenic and osteogenic mRNA gene expression, and western blot between the two groups.

Results : The mRNA gene expression of recurrent disc cells were increased 1.47* times for aggrecan, 1.38 times for type I collagen, 2.04 times for type II collagen, 1.22 times for both Sox-9 and osteocalcin, and 1.31 times for alkaline phosphatase, respectively, compared with the primary herniated lumbar disc cells (*indicates $p < 0.05$). Western blot results for each aggrecan, type I collagen, type II collagen, Sox-9, osteocalcin, and alkaline phosphatase were similar between the primary herniated disc cells and recurrent disc cells.

Conclusion : These results indicate that the recurrent disc cells have similar chondrogenic and osteogenic gene expression compared to primary herniated disc cells. Therefore, we assumed that the regeneration of remaining discs could fill the previous discectomy space and also it could be one of the factors for disc recurrence especially in the molecular biologic field.

KEY WORDS : Recurrent disc · Aggrecan · Collagen · Sox-9 · Osteocalcin · Alkaline phosphatase.

INTRODUCTION

Recurrent lumbar disc herniation has been noted to occur in 5% to 15% of cases surgically treated for primary lumbar disc herniation^{18,19}. The exact reason for disc recurrence after discectomy has not been clearly understood, although disc recurrence after discectomy is often a result of the technical problems associated with surgery such as incomplete disc removal, biomechanical factors, or disc regeneration after discectomy.

As far as we are aware, there have been no reports of the molecular biologic studies on the human recurrent discs. It was reported that the disc cells are not only degenerated but also regenerated after degeneration^{4,5,7-10,12-14,17}. After a lum-

bar discectomy, repairing tissues substitute the part of the empty disc space or around the fenestrated annular defect¹¹.

Our hypothesis was that there might be a regeneration of disc tissues inside the disc space after a lumbar discectomy. Thus, we studied the molecular biologic characteristics of disc materials acquired from the revision surgery for recurrent lumbar disc herniation. All of the data were compared with the results from the primary disc herniation.

MATERIALS AND METHODS

Clinical materials

We classified the patients into two groups : primary disc herniation and recurrent disc herniation, not enhanced on the Gd-DTPA contrast MRI. Disc materials of the recurrent disc herniation group were obtained from 9 patients (6 from L4/5, 3 from L5/S1 segment). Their mean age was 47.3 (24-69) years old and the recurrent disc herniation group consisted of 4 men and 5 women. The average time interval from 1st operation and 2nd surgery for recurrent disc herniations was 5.4 years (range 5 months-11 years 11

• Received : July 16, 2009 • Revised : November 8, 2009
• Accepted : December 26, 2009
• Address for reprints : Keun-Su Kim MD, PhD.
Department of Neurosurgery, Spine and Spinal Cord Institute,
Yonsei University College of Medicine, 712 Eonju-ro, Gangnam-gu,
Seoul 135-720, Korea
Tel : +82-2-2019-3390, Fax : +82-2-3461-9229
E-mail : spinekks@yuhs.ac

months). Disc materials of the primary disc herniation group were obtained from a group of 9 patients (7 from L4/5, 2 from L5/S1 segments) with a mean age of 50.6 (39-67) years old and the primary disc herniation group consisted of 5 men and 4 women. Both groups showed no statistical difference in the general demographics including Pfirrmann's grading system of lumbar disc degeneration on MR images (Table 1).

Isolation of disc cells and culture

Unless otherwise stated, all reagents were purchased from GibcoBRL (Grand Island, NY, USA). During a lumbar discectomy, intervertebral disc materials were taken from the patients with primary and recurrent disc herniation. To make the samples homologous, disc materials were acquired from nucleus pulposus not annulus. Tissue from each disc was dissected into small pieces and incubated (5% CO₂, 95% room air at 37°C) in Dulbecco's Modified Eagle Medium and Ham's F-12 (DMEM/F-12) media. To isolate the cells, disc tissues were digested in DMEM/F-12 media with 0.2% protease (Sigma Chemical, St. Louis, MO, USA) for 1 hour, followed by 0.025% collagenase (Sigma Chemical, St. Louis, MO, USA) for 12 hours. Cells from less than 2 passages were used for each experiment.

Each disc cells (2 × 10⁵ cells/well) were grown as monolayer cultures for 6 days in DMEM/F-12 media with 10% fetal bovine serum (FBS) +10 U/mL penicillin + 10 g/mL streptomycin + 0.2 mmol/L L-glutamine. After 6 days, mRNA expression of aggrecan, type I collagen, type II collagen, Sox-9, osteocalcin, and alkaline phosphatase were measured with real-time PCR. And also, we compared the western blot between primary and recurrent disc herniation groups.

Real-time polymerase chain reaction assay

Total RNA was extracted from each disc cells and the mRNA levels of aggrecan, type I collagen, type II collagen, Sox-9, osteocalcin, and alkaline phosphatase were determined using real-time PCR. Total RNA was extracted with Trizol reagent (GIBCO BRL, Gaithersburg, MD, USA) and quantified by measuring absorbance

at 260 nm using a spectrophotometer (Nanodrop, Delaware, USA). Specific primers for aggrecan, type I collagen, type II collagen, Sox-9, osteocalcin, and alkaline phosphatase were constructed using the complete mRNA sequence from the National Center for Biotechnology Information. Forward and reverse primer sequences of aggrecan, type I collagen, type II collagen, Sox-9, osteocalcin, and alkaline phosphatase are summarized in Table 2.

We used an ABI Prism 7300 (Applied biosystems, California, USA) that detects SYBR Green fluorescent dye incorporated in double strand DNA. A 15 µL reaction volume included 25 ng of cDNA of RT-PCR and 5 pmole of each primer (aggrecan, type I collagen, type II collagen, Sox-9, osteocalcin, and alkaline phosphatase). Thirty-five real-time PCR cycles were performed for denaturation (95 °C for 30 seconds), annealing, and elongation (60°C for 60 seconds). To confirm amplification specificity, PCR products were subjected to a melting curve analysis. Threshold cycles (Ct) of aggrecan, type I collagen, type II collagen, Sox-9, osteocalcin, and alkaline phosphatase were standardized according to GAPDH. The mRNA expression of recurrent herniated disc cells were compared to primary herniated disc cells and reported as a ratio.

Table 1. Demographics of primary hemiated and recurrent hemiated lumbar disc patients

Level	Primary hemiated lumbar disc	Recurrent lumbar disc
Age	52.4 (39-67)	46.9 (24-69)
Sex ratio (M : F)	5 : 4	4 : 5
Disc level	L4/5 (7)	L4/5 (6)
	L5/S1 (2)	L5/S1 (3)
Pfirrmann's grading	Grade 3 (2)	Grade 3 (3)
	Grade 4 (5)	Grade 4 (4)
	Grade 5 (2)	Grade 5 (2)

Two groups have no statistical difference in the demographics

Table 2. Primer sequence for aggrecan, type I collagen, type II collagen, Sox-9, osteocalcin, and alkaline phosphatase

	Primer	Sequence
Aggrecan	Forward	CTGCTCCGAGGCCATTCAG
	Reverse	CTGGGTCACGATCCACTCC
Type I collagen	Forward	GTCGAGGGCCAAGACGAAG
	Reverse	CAGATCACGTCATGCACAAC
Type II collagen	Forward	GGTCTGGTGGAAACTTTGCT
	Reverse	GGTCCTTGCAITACTCCCAAC
Sox-9	Forward	AGCGAACGCACATCAAGAC
	Reverse	GCTGTAGTGTGGGAGGTTGAA
Osteocalcin	Forward	CACTCCTCGCCCTATTGGC
	Reverse	CCCTCCTGCTGGACACAAAAG
Alkaline phosphatase	Forward	ATGGGATGGGTGTCTCCACA
	Reverse	CCACGAAGGGGAACITGTC
GAPDH*	Forward	ATGGGGAAGGTGAAGGTCG
	Reverse	GGGGTCATTGATGCCAACAATA

*GAPDH (glyceraldehyde-3-phosphate dehydrogenase) was used as a house keeping gene

Statistical analysis

Student's t-test and Fischer's exact test were used for statistics. A *p*-value less than 0.05 was defined as statistical significance.

RESULTS

mRNA expression in the primary herniated and recurrent lumbar discs

The mRNA levels of aggrecan, type I collagen, type II collagen, and Sox-9 increased 1.47*, 1.38, 2.04, and 1.22 times, respectively, in recurrent lumbar discs. Also, the mRNA levels of osteocalcin and alkaline phosphatase were increased 1.22 and 1.31 times, respectively, in recurrent lumbar discs (Fig. 1) (* indicates *p* < 0.05).

Western blotting in the primary herniated and recurrent lumbar discs

There was no difference between primary herniated and recurrent lumbar discs (Fig. 2).

DISCUSSION

The main results of this experiment are that the human recurrent discs had similar molecular biologic features as the primary herniated discs on the chondrogenic and osteogenic gene expression including western blotting results.

The recurrence of back or sciatic pain after primary discectomy can be caused by a true recurrence of disc herniation, new disc herniation at a different disc, epidural fibrosis, local arachnoiditis, symptomatic arthritis of the small intervertebral joints, secondary spinal stenosis, instability, and spondylitis or spondylodiscitis¹⁹. The recurrent disc herniation might inevitably develop in some patients, who can be determined by examining the postoperative scar using Gd-DTPA contrast-enhanced MRI study^{1,11}. We used the primary disc herniation and confirmed recurrent disc herniation, not enhanced lesion on the Gd-DTPA contrast MRI to compare both discs.

It was reported that a large extruded lumbar disc resolved spontaneously without operation, and recent immunohistologic studies have created insights into the reabsorptive mechanisms that might account for this^{3,6,11,15}. On the other hand, there is another animal study which showed that the nucleus pulposus can regenerate. Three months after chymopapain injections into the intervertebral disc in the animal study, disc-space narrowing developed for 2 weeks due to the loss of proteoglycans and then the intervertebral disc showed an increase in height due to proteoglycans recovering and 6 months later, the intervertebral

disc height increased more, and normal histology restored².

The mRNA expressions of aggrecan and type 2 collagen in disc cells, chondrocytes, and bone marrow derived stem cells were increased after rhBMP-2 treatment in rabbits⁹. Also, LIM Mineralization Protein (LMP)-1 could induce the BMP-2 and BMP-7 gene expression and then finally increase the protein production in both AF cells and chondrocytes of rabbits¹⁰. But, so far, there have been no reports of the molecular biologic studies on the human recurrent discs.

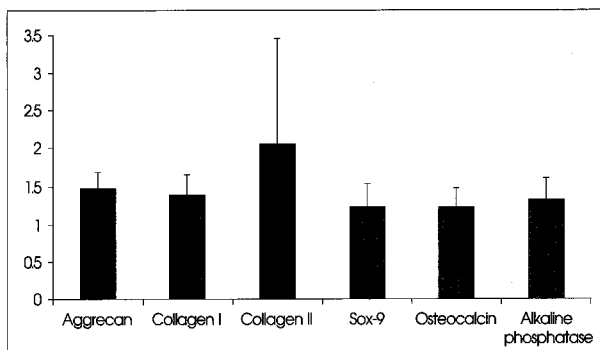


Fig. 1. mRNA expression of recurrent disc cells for aggrecan, type I collagen, type II collagen, Sox-9, osteocalcin, and alkaline phosphatase compared to primary herniated lumbar disc cells.

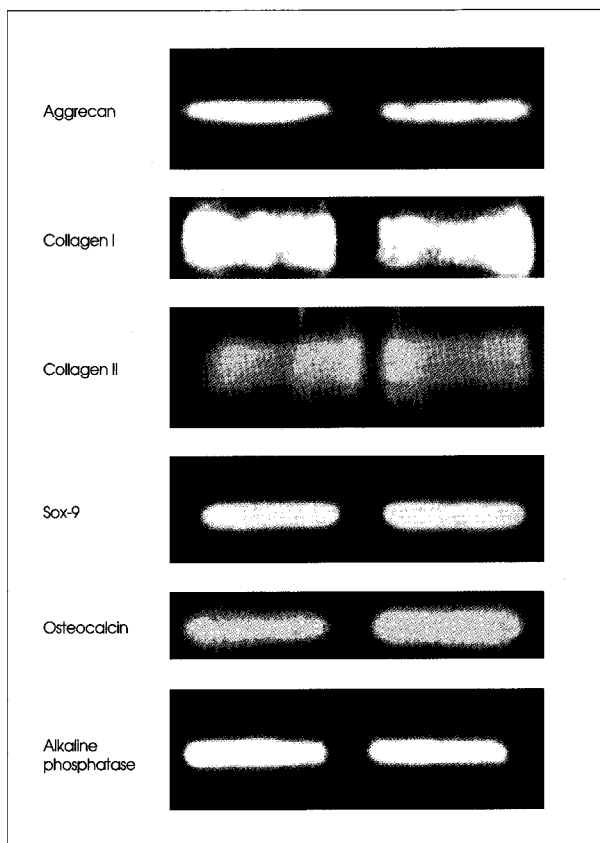


Fig. 2. Western blotting of recurrent disc cells for aggrecan, type I collagen, type II collagen, Sox-9, osteocalcin, and alkaline phosphatase compared to primary herniated lumbar disc cells.

Laus et al.¹¹⁾ reported that recurrent discs, which appeared within 1 year of surgery, were identical to that of primary herniation in morphological study and so the remaining discs after discectomy could regenerate and then fill the resected disc space. Risbud et al.¹⁶⁾ reported that the AF and NP derived cells also evidenced chondrogenic differentiation. Therefore, degenerated human discs contain skeletal progenitor cells, which suggests that these endogenous progenitors may be used to repair intervertebral discs.

There are many risk factors of recurrent lumbar disc herniation after conventional open discectomy such as young age, male gender, smoking, and traumatic events¹⁹⁾.

We assumed that remaining disc cells after discectomy could regenerate and proliferated during the healing process. For that reason, recurrent discs have similar chondrogenic and osteogenic gene expression. Therefore, we thought the excessive regeneration of remaining discs after discectomy could be one of the reasons for recurrent disc herniation.

CONCLUSION

These studies indicate that recurrent disc cells have similar chondrogenic and osteogenic gene expression compared to primary herniated disc cells. Therefore, we assume that regeneration of the remaining discs could fill the previous discectomy space and also it could be one of the factors for disc recurrence, especially in the molecular biologic field.

• Acknowledgements

This study was supported by a faculty research grant of Yonsei University College of Medicine for 2008 (No. 6-2008-0290).

References

- Bialecki J, Lukawski S, Milecki M, Lachowicz W : Differential diagnosis of post-surgery scars and recurrent lumbar disc herniation in MRI. *Ortop Traumatol Rehabil* 6 : 172-176, 2004
- Bradford DS, Cooper KM, Oegema TR Jr : Chymopapain, chemonucleolysis, and nucleus pulposus regeneration. *J Bone Joint Surg Am* 65 : 1220-1231, 1983
- Doita M, Kanatani T, Harada T, Mizuno K : Immunohistologic study of the ruptured intervertebral disc of the lumbar spine. *Spine* 21 : 235-241, 1996
- Guehring T, Omlor GW, Lorenz H, Engelleiter K, Richter W, Carstens C, et al. : Disc distraction shows evidence of regenerative potential in degenerated intervertebral discs as evaluated by protein expression, magnetic resonance imaging, and messenger ribonucleic acid expression analysis. *Spine* 31 : 1658-1665, 2006
- Inoue G, Ohtori S, Aoki Y, Ozawa T, Doya H, Saito T, et al. : Exposure of the nucleus pulposus to the outside of the anulus fibrosus induces nerve injury and regeneration of the afferent fibers innervating the lumbar intervertebral discs in rats. *Spine* 31 : 1433-1438, 2006
- Ito T, Yamada M, Ikuta F, Fukuda T, Hoshi SI, Kawaji Y, et al. : Histologic evidence of absorption of sequestration-type herniated disc. *Spine* 21 : 230-234, 1996
- Johnson WE, Sivan S, Wright KT, Eisenstein SM, Maroudas A, Roberts S : Human intervertebral disc cells promote nerve growth over substrata of human intervertebral disc aggrecan. *Spine* 31 : 1187-1193, 2006
- Kuh SU, Zhu Y, Li J, Tsai KJ, Fei Q, Hutton WC, et al. : A comparison of three cell types as potential candidates for intervertebral disc therapy : anulus fibrosus cells, chondrocytes, and bone marrow derived cells. *Joint Bone Spine* 76 : 70-74, 2009
- Kuh SU, Zhu Y, Li J, Tsai KJ, Fei Q, Hutton WC, et al. : Can TGF-beta1 and rhBMP-2 act in synergy to transform bone marrow stem cells to discogenic-type cells? *Acta Neurochir (Wien)* 150 : 1073-1079; discussion 1079, 2008
- Kuh SU, Zhu Y, Li J, Tsai KJ, Fei Q, Hutton WC, et al. : The AdLMP-1 transfection in two different cells; AF cells, chondrocytes as potential cell therapy candidates for disc degeneration. *Acta Neurochir (Wien)* 150 : 803-810, 2008
- Laus M, Bertoni F, Bacchini P, Alfonso C, Giunti A : [Recurrent lumbar disc herniation : what recurs? (A morphological study of recurrent disc herniation).] *Chir Organi Mov* 78 : 147-154, 1993
- Le Maitre CL, Richardson SM, Baird P, Freemont AJ, Hoyland JA : Expression of receptors for putative anabolic growth factors in human intervertebral disc : implications for repair and regeneration of the disc. *J Pathol* 207 : 445-452, 2005
- Lotz JC, Kim AJ : Disc regeneration : why, when, and how. *Neurosurg Clin N* 16 : 657-663, 2005
- Meisel HJ, Siodla V, Ganey T, Minkus Y, Hutton WC, Alasevic OJ : Clinical experience in cell-based therapeutics : Disc chondrocyte transplantation A treatment for degenerated or damaged intervertebral disc. *Biomol Eng* 24 : 5-21, 2007
- Reyentovich A, Abdu WA : Multiple independent, sequential, and spontaneously resolving lumbar intervertebral disc herniations : a case report. *Spine* 27 : 549-553, 2002
- Risbud MV, Guttapalli A, Tsai TT, Lee JY, Danielson KG, Vaccaro AR, et al. : Evidence for skeletal progenitor cells in the degenerate human intervertebral disc. *Spine* 32 : 2537-2544, 2007
- Schnake KJ, Putzier M, Haas NP, Kandziora F : Mechanical concepts for disc regeneration. *Eur Spine J* 15 Suppl 3 : S354-S360, 2006
- Swartz KR, Trost GR : Recurrent lumbar disc herniation. *Neurosurg Focus* 15 : E10, 2003
- Suk KS, Lee HM, Moon SH, Kim NH : Recurrent lumbar disc herniation : results of operative management. *Spine* 26 : 672-676, 2001