

Case Report

Pyogenic Spondylodiscitis after Percutaneous Endoscopic Lumbar Discectomy

Kyeong-Bo Choi, M.D.,¹ Choon-Dae Lee, M.D.,² Sang-Ho Lee, M.D., PH.D.²

Department of Neurosurgery,¹ Busan Wooridul Spine Hospital, Busan, Korea

Department of Neurosurgery,² Wooridul Spine Hospital, Seoul, Korea

We reviewed 9 cases of pyogenic spondylodiscitis following percutaneous endoscopic lumbar discectomy (PELD). Microbiologic cultures revealed 6 causative organisms. Five patients were managed conservatively and four were treated surgically. The mean follow-up period was 20.6 months and the average length of hospitalization was 24 days. Radiological evidence of spinal fusion was noted and infection was resolved in all patients. Although PELD is a safe and effective procedure, the possibility of pyogenic spondylodiscitis should always be considered.

KEY WORDS : Pyogenic spondylodiscitis · Percutaneous endoscopic lumbar discectomy.

INTRODUCTION

Pyogenic spondylodiscitis is an extremely rare but potentially devastating complication that leads to significant neurological deterioration^{2,3,8}. It is also one of the most disabling causes of failed back surgery syndrome⁹. These days, percutaneous endoscopic lumbar discectomy (PELD) is commonly performed as a safe and effective alternative for open lumbar microdiscectomy (OLM) for soft lumbar disc herniation^{4,15,23}. It is also known as a reliable procedure with a relatively low infectious complication rate due to minimal damage to normal tissue, less bleeding, continuous irrigation with saline solutions mixed with an antibiotic, and a short operation time¹². However, most previous studies have focused on spondylodiscitis after OLM (OLM-SD), and few authors have expressed their concerns about spondylodiscitis following PELD (PELD-SD). In this report, we describe 9 cases of PELD-SD and present distinctive clinical and radiological features.

CASE REPORT

Patient demographics

Among the 7,184 patients who underwent PELD in our hospital between March 2003 and June 2007, 9 patients treated for SD were retrospectively reviewed. The mean age for the 9 patients at the initial operation was 39.7 years (range : 21-61 years). The study included 7 males and 2 females. All patients had suffered from lower back pain with unilateral leg pain for several years and lumbar disc herniation was diagnosed using magnetic resonance imaging (MRI) before PELD. Herniated levels were L4-5 in seven cases and L5-S1 in two cases (Table 1). Chronic underlying disease was presented in two patients; hypertension and hypothyroidism, respectively.

Surgical Technique

PELD was performed under local anesthesia. The patient was placed in the prone position on a radiolucent table in a sterile operating room. The skin entry point was usually 10 to 14 cm from the midline, which had already been measured by evaluating preoperative computed tomography (CT) scan or MRI. After the operation site and the area surrounding it were washed with soap and water, the skin was prepared with an antiseptic solution. As a method of optimal needle placement previously described by Yeung and Tsou^{20,23}, an 18-gauge spinal needle was inserted into the posterior one-third

• Received : April 21, 2010 • Revised : July 15, 2010
• Accepted : November 22, 2010
• Address for reprints : Choon-Dae Lee, M.D.
Department of Neurosurgery, Wooridul Spine Hospital,
47-4 Cheongdam-dong, Gangnam-gu, Seoul 135-100, Korea
Tel : +82-2-513-8275, Fax : +82-2-513-8146
E-mail : nslcd@yahoo.co.kr

Table 1. Patients' demographic data and clinical outcomes

Patient No.	Age (years)	Sex	Level	Onset of Sx. (days)	Type of Infection	Culture	Treatment	Outcome
1	55	M	L4-L5	10	SD, PA	No growth	CTG-BD	Excellent
2	33	F	L5-S1	7	SD	Pseudomonas	PELD-BD, ALIF+PFF	Good
3	61	M	L4-L5	9	SD, EA	Acinetobacter	PELD-BD, ALIF+PFF	Excellent
4	40	M	L5-S1	7	SD	No culture	Conservative	Good
5	35	F	L4-L5	4	SD, PA	E. coli	OS-BD, ALIF+PFF	Excellent
6	37	M	L4-L5	4	SD, EA	CNS	CTG-BD, ALIF+PFF	Good
7	29	M	L4-L5	6	SD, PA	Enterobacter	CTG-BD, OS-BD	Good
8	21	M	L4-L5	3	SD	No culture	Conservative	Good
9	47	M	L4-L5	5	SD	Pseudomonas	PELD-BD	Excellent

SD : spondylodiscitis, PA : paravertebral abscess, EA : epidural abscess, CNS : coagulase-negative staphylococcus, CTG-BD : CT-guided aspiration biopsy with drainage, PELD-BD : percutaneous endoscopic lumbar discectomy with biopsy and debridement, OS-BD : open surgical biopsy with drainage, ALIF+PFF : anterior lumbar interbody fusion with posterior facet screw fixation

of the disc by means of Kambin's triangle under the guidance of C-arm fluoroscope. An intraoperative discography was performed with a mixture of contrast media and indigo carmine to stain selectively the degenerated herniated disc materials blue. After withdrawal of the needle, a 7-mm-long stab incision was made at the entry point of the guidewire. After the guidewire was withdrawn, a blunt-tapered obturator through the serial dilators, followed by a working cannula, and the endoscope were introduced in order. The annulus was windowed, and then the herniated disc material was removed using endoscopic forceps, a side-firing laser, and a radiofrequency probe. During the procedure, a normal saline solution mixed with antibiotics was used for continuous irrigation. Finally, the endoscope was withdrawn and a one-point skin suture was made with a sterile dressing. In our cases, the mean operation time was 54 minutes (range : 35-95 minutes) and intraoperative blood loss was not measured. Prophylactic antibiotics using 1 gram of Cefazolin were administered 30 minutes before the procedures and every 8 hours for the first 24 hours in all patients.

Results

Clinical presentation

All patients had severe lower back pain and unilateral buttock pain of varying severity. Four patients had fever (body temperature > 38.0°C). No patients had neurological deficits. The mean duration between the index operation and the onset of pain was 6 days (range : 3-10 days). The average length of hospitalization was 24 days (range : 14-53 days) and the mean follow-up period was 20.6 months (range : 4-51 months).

Microbiologic findings

A causative organism was identified in 6 of 7 cases; 3 by PELD biopsy, 2 by CT-guided aspiration biopsy, and 1 by

open surgical biopsy. However, blood cultures did not reveal any offending bacteria in the four patients with fever. A negative culture was found by PELD in one patient and no culture was conducted for two patients due to the refusal of biopsy.

Radiological findings

MRI findings revealed a preserved disc space without endplate erosions in seven cases or mild endplate erosions in two cases in the early phase of infection and loss of affected disc height in 7 patients at the last follow-up. The diagnosis of SD was confirmed in 6 patients by MRI and in 3 by CT scans. Both MRI and CT scans accurately identified paravertebral abscesses in 3 patients. Epidural abscess was found by using post-contrast enhanced MRI in 2 patients.

Treatment modalities

All patients had initially started a short-term broad-spectrum antibiotic therapy. The regimen was adjusted after identification of the causative organisms based on a microbial susceptibility test. An empiric regimen was administered in the negative culture case. Mean duration of intravenous antibiotic therapy was 6.4 weeks (range : 2-10 weeks) and mean duration of antibiotic therapy was 12.8 weeks (range : 7-28 weeks). The indications for interventional biopsies were immediate drainage of paravertebral abscesses in 4 patients and increasing lower back pain despite appropriate intravenous antibiotic therapy in 3 patients. The procedures were composed of a CT-guided aspiration biopsy with drainage in 3 cases, a PELD biopsy with debridement in 3 cases, and an open surgical biopsy with abscess drainage in 1 case.

However, 4 patients who had persistent infection and failed to respond to antibiotic therapy underwent additional anterior lumbar interbody fusion (ALIF) using iliac bone graft with posterior facet screw fixation. The mean duration between the onset of symptoms and interventional biopsy in 7 patients was 6 days (range : 3-10 days), and combined fusion

surgery was performed at a mean of 10.8 weeks (range : 3-17 weeks) after biopsy.

Clinical outcomes

Radiological evidence of fusion was noted and the infection has been resolved in all patients at the last follow-up. Four patients who underwent fusion surgery experienced immediate relief of back pain. One patient who underwent an open surgical biopsy with abscess drainage had gradually decreasing lower back pain during the first 3 months after surgery and became pain-free at 6 months follow-up. The mean VAS score for back and leg pain between the onset of infection and the last follow-up decreased from 6.89 to 5.67 ($p = 0.36$) and from 7.11 to 3.44 ($p = 0.004$), respectively. The mean ODI score improved from 63.5% to 33.1% ($p = 0.009$). None had a recurrence of SD nor required a supplemental spinal surgery thereafter. At the last follow-up, 7 patients had no pain and 2 patients reported substantial improvement of the previous symptoms six months later after fusion surgery.

DISCUSSION

The incidence of pyogenic SD has recently increased due to a steep rise in minimally invasive percutaneous procedures^{5,7}. Particularly, PELD has been growing its popularity as a safe and effective procedure because of its advantages includ-

ing less tissue trauma, diminished postoperative pain, shortened hospital stays, and early return to work^{4,12,15}. Therefore, the infectious complications of PELD and its incidence have been seldom reported in previous literature because the incidence itself was very rare. Until now, most previous studies have focused on OLM-SD and the incidence has varied from 1% to 5%, depending on the authors^{13,19}.

The pathogenesis of PELD-SD in our cases still remains unclear. Thus, several feasible hypotheses are suggested through our experience and previous studies^{4,14,23}.

First of all, the inadvertent direct puncture of the colon using a spinal needle or guidewire is a probable cause of infection (Patient 5, 7). A far lateral entry point from the midline and a needle insertion angle that is too steep may increase the risk of bowel injury (Fig. 1, 2). An inappropriate advancement of the guidewire further than the anterior margin of the disc is also closely related to the occurrence of infection. To avoid such complications, a precise preoperative evaluation of the subject level for optimal trajectory through an axial CT scan or MRI must be achieved. For a proper route aiming at the extruded fragment, the spinal needle should touch the superior facet of the affected level and then slide down the facet. Frequent fluoroscopic verification of the correct position of the spinal needle and instruments is also indispensable¹⁰. If bowel penetration by the spinal needle is suspected, immediate withdrawal of the contaminated needle followed by a

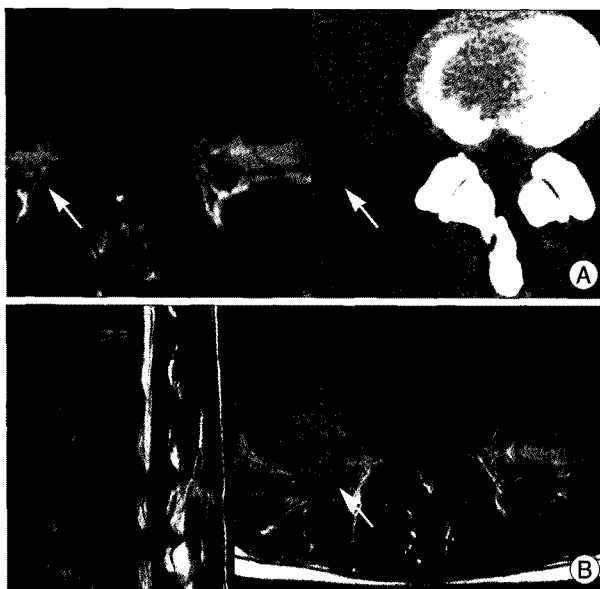


Fig. 1. A 35-year-old female patient (patient 5) presented with a one-year history of severe lower back pain and right leg pain. Preoperative axial T1-weighted magnetic resonance imaging (MRI) and computed tomography (CT) scan show an extruded disc herniation on the right side at the L4-5 level (A). Note the posterior extension of the ascending colon on the MRI and CT scan (arrow). T2-weighted MRI 9 days after PELD shows a large right psoas abscess (arrow) and secondary spondylodiscitis (SD) at the L4-5 level (B). *E. coli* was cultured from the psoas abscess.

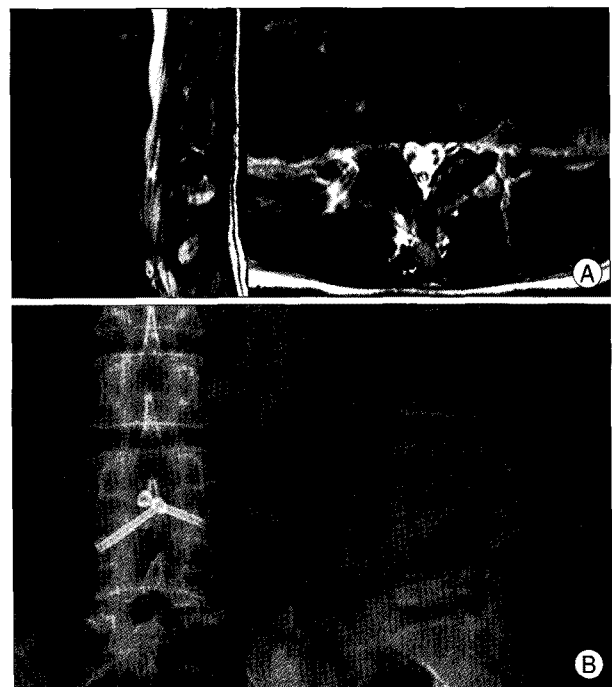


Fig. 2. T2-weighted MRI (A) and plain radiographs (B) 4 years after anterior lumbar interbody fusion (ALIF) with percutaneous facet screw fixation (PFF) demonstrate complete resolution of the infection and subsequent solid fusion of the L4-5 segment.

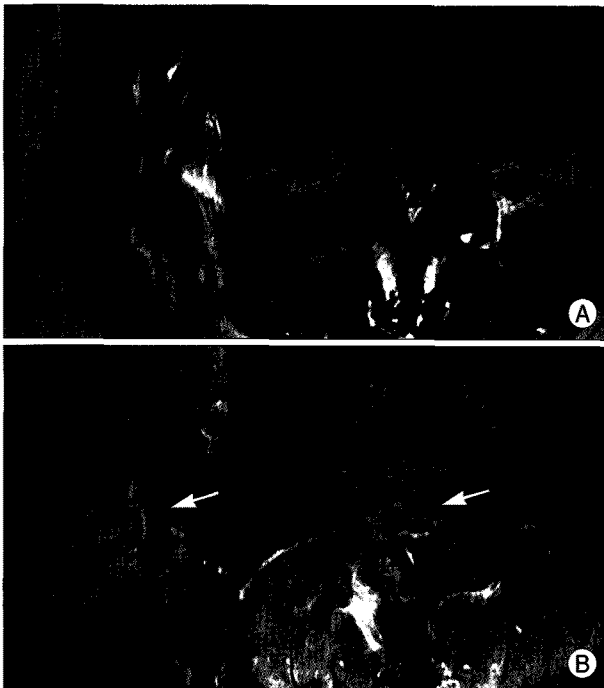


Fig. 3. A 37-year-old male patient (patient 6) had a 2-week history of severe right buttock and leg pain. T1- and T2-weighted MRI 7 days after PELD revealing a lesion with low signal intensity and mild endplate erosions at the L4-5 level (A). Gadolinium-enhanced MRI 2 months after CT-guided aspiration biopsy showing a large epidural abscess (arrow) and more aggravated vertebral body destruction with spondylodiscitis (B). Coagulase negative *Staphylococcus* was identified from the infected disc.

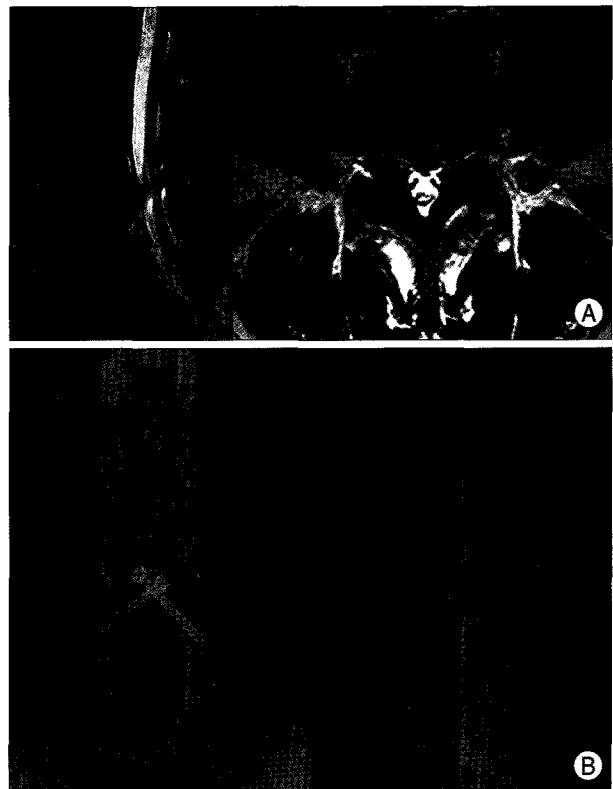


Fig. 4. T2-weighted MRI (A) and plain radiographs (B) 2 years after ALIF with PFF demonstrating the restoration of disc height and solid fusion of the L4-5 segment.

profuse saline irrigation mixed with an antibiotic should be performed to avoid the chance of subsequent infection from spreading. Then, intravenous antibiotic treatment for presumed gram-negative infections should be started at once.

Secondly, iatrogenic introduction of the causative organism into the disc space by a contaminated spinal needle may occur during the initial skin puncture (Patient 3, 6) (Fig. 3, 4)^{17,18}. In order to prevent from being pulled with skin tissue or a piece of surgical drape, initial enough skin incision using knife for the passage of the spinal needle and instruments should be carried out.

Thirdly, the surgical glove perforation often happens unconsciously because the glove is sometimes wedged either between the obturator and working cannula, or between the working cannula and the connector of the irrigation fluid inflow channel during the procedure. Accurate manipulation of instruments and double gloving of all members of the surgical team could help reduce the chance of infection.

Fourthly, infection transfer by endoscopic instruments due to their frequent in-and-out movements through the working channel combined with a long operation time is plausible. Thus, careful surgical techniques including a clean operative field, meticulous hemostasis, and minimal tissue necrosis are crucial.

Other possible factors for the sporadic occurrence of infection include exposure of surgical draping, blowing dust particles in the operating room due to frequent turnings of the C-arm fluoroscope, presence of many observers near the surgeon, or improperly disinfected small diameter serial dilators. In the case of an inflammatory skin lesion around the operation field, a double surgical draping technique, which consists of the surgical draping of the operation site after a small covering of the affected skin lesion, can be effective to protect the puncture wound from a potential infectious source^{11,14,22}.

Although the optimal treatment modalities for postoperative SD are still a matter of debate, the general principle is conservative treatment with antibiotics, which can also be applied to cases of PELD-SD. The routine schedule for efficient medical treatment consists of consistent administration of organism-specific intravenous antibiotics for 6 weeks, followed by an additional 6 weeks of oral antibiotics, depending on the clinical and laboratory findings²¹. In the case of a negative culture, an empiric regimen for presumed gram-positive infections should be prescribed because the most common pathogen is *Staphylococcus*¹³. Sequential follow-up of the ESR and CRP values is mandatory to evaluate the effectiveness of the antibiotic treatment. Discontinuance of the antibiotic treatment can be considered after verification of normal CRP

values, more than twice, at regular intervals of several days.

However, surgical treatment is usually necessary with the following : 1) the presence of a neurological deficit; 2) increased paravertebral or epidural abscess formation; 3) significant disc space narrowing with adjacent vertebral body destruction; 4) spinal instability with developing kyphosis; and 5) failure to respond to conservative therapy^{1,11)}. With the development of surgical techniques, the mainstay of surgical treatment for advanced SD is ALIF using autologous bone graft followed by posterior screw fixation, although several surgical modalities have been described for the treatment of spinal infections^{6,16)}. This combined anterior and posterior approach offer some advantages as follows; direct access to the infected vertebral bodies and intervertebral disc, radical debridement of the infected tissues, avoidance of extensive injury to back muscle and posterior ligament structure, low possibility of a neural injury during the surgery, and a high fusion rate^{16,18,21)}.

Recently, Ha et al.¹⁰⁾ performed a retrospective study of 24 patients to determine the efficacy of anterior radical debridement and fusion with posterior instrumentation in a single-stage procedure for patients in whom medical management of pyogenic discitis and vertebral osteomyelitis had failed. In their study, solid bone fusion was achieved in 23 (95.8%) patients and all patients experienced significant postoperative reduction in pain, and those with neurological deficits improved. In our cases, four patients underwent this combined approach and obtained satisfactory clinical results regarding pain, mobility, and spontaneous fusion of the involved disc space at the last follow-up.

Our experience of acute PELD-SD indicates that medical treatment alone may not produce satisfactory clinical results due to the long disabling period of the condition; surgical treatment in selected cases on an individual basis may be necessary for rapid pain relief, earlier mobilization, a shorter hospital stay, and early return to work.

CONCLUSION

Although PELD is undoubtedly a safe and effective procedure, the possibility of postoperative SD should always be considered because of its potential for devastating morbidity and subsequent great economic loss. Careful observation in all postoperative patients, prompt diagnosis, and an appropriate step-by-step management strategy are essential to avoid this complication.

• Acknowledgements

This study was supported by a grant from the Wooridul Spine Foundation.

References

1. Abramovitz JN, Batson RA, Yablon JS : Vertebral osteomyelitis. The surgical management of neurologic complications. *Spine (Phila Pa 1976)* 11 : 418-420, 1986
2. Bircher MD, Tasker T, Crashaw C, Mulholland RC : Discitis following lumbar surgery. *Spine (Phila Pa 1976)* 13 : 98-102, 1988
3. Blankstein A, Rubenstein E, Ezra E, Lokiec F, Caspi I, Horoszowski H : Disc space infection and vertebral osteomyelitis as a complication of percutaneous lateral discectomy. *Clin Orthop Relat Res* : 234-237, 1987
4. Choi G, Lee SH, Lokhande P, Kong BJ, Shim CS, Jung B, et al. : Percutaneous endoscopic approach for highly migrated intracanal disc herniations by foraminoplasty technique using rigid working channel endoscope. *Spine (Phila Pa 1976)* 33 : E508-E515, 2008
5. Cohen SP, Larkin T, Abdi S, Chang A, Stojanovic M : Risk factors for failure and complications of intradiscal electrothermal therapy : a pilot study. *Spine (Phila Pa 1976)* 28 : 1142-1147, 2003
6. Dimar JR, Carreon LY, Glassman SD, Campbell MJ, Hartman MJ, Johnson JR : Treatment of pyogenic vertebral osteomyelitis with anterior debridement and fusion followed by delayed posterior spinal fusion. *Spine (Phila Pa 1976)* 29 : 326-332; discussion 332, 2004
7. Dullerud R, Nakstad PH : Side effects and complications of automated percutaneous lumbar nucleotomy. *Neuroradiology* 39 : 282-285, 1997
8. Eismont FJ, Bohlman HH, Soni PL, Goldberg VM, Frechafer AA : Pyogenic and fungal vertebral osteomyelitis with paralysis. *J Bone Joint Surg Am* 65 : 19-29, 1983
9. Fouquet B, Goupille P, Jattiot F, Cotty P, Lapiere F, Valat JP, et al. : Discitis after lumbar disc surgery. Features of "aseptic" and "septic" forms. *Spine (Phila Pa 1976)* 17 : 356-358, 1992
10. Ha KY, Shin JH, Kim KW, Na KH : The fate of anterior autogenous bone graft after anterior radical surgery with or without posterior instrumentation in the treatment of pyogenic lumbar spondylodiscitis. *Spine (Phila Pa 1976)* 32 : 1856-1864, 2007
11. Hanaoka N, Kawasaki Y, Sakai T, Nakamura T, Nanamori K, Nakamura E, et al. : Percutaneous drainage and continuous irrigation in patients with severe pyogenic spondylitis, abscess formation, and marked bone destruction. *J Neurosurg Spine* 4 : 374-379, 2006
12. Jang JS, An SH, Lee SH : Transforaminal percutaneous endoscopic discectomy in the treatment of foraminal and extraforaminal lumbar disc herniations. *J Spinal Disord Tech* 19 : 338-343, 2006
13. Katonis P, Tzermiadianos M, Papagelopoulos P, Hadjipavolu A : Postoperative infections of the thoracic and lumbar spine : a review of 18 cases. *Clin Ortho Relat Res* 454 : 114-119, 2007
14. Kim WJ, Lim ST, Lee SH : Pyogenic psoas abscess and secondary spondylodiscitis as a rare complication of percutaneous endoscopic lumbar discectomy : a case report. *Joint Dis Rel Surg* 16 : 163-166, 2005
15. Lee S, Kim SK, Lee SH, Kim WJ, Choi WC, Choi G, et al. : Percutaneous endoscopic lumbar discectomy for migrated disc herniation : classification of disc migration and surgical approaches. *Eur Spine J* 16 : 431-437, 2007
16. Lim JK, Kim SM, Jo DJ, Lee TO : Anterior interbody grafting and instrumentation for advanced spondylodiscitis. *J Korean Neurosurg Soc* 43 : 5-10, 2008
17. Mastrorardi L, Rychlicki F, Tatta C, Morabito L, Agrillo U, Ducati A : Spondylodiscitis after lumbar microdiscectomy : effectiveness of two protocols of intraoperative antibiotic prophylaxis in 1167 cases. *Neurosurg Rev* 28 : 303-307, 2005
18. Quiñones-Hinojosa A, Jun P, Jacobs R, Rosenberg WS, Weinstein PR : General principles in the medical and surgical management of spinal infections : a multidisciplinary approach. *Neurosurg Focus* 17 : E1, 2004
19. Rohde V, Meyer B, Schaller C, Hassler WE : Spondylodiscitis after lumbar discectomy. Incidence and a proposal for prophylaxis. *Spine (Phila Pa 1976)* 23 : 615-620, 1998

20. Ruetten S, Komp M, Merk H, Godolias G : Use of newly developed instruments and endoscopes : full-endoscopic resection of lumbar disc herniations via the interlaminar and lateral transforminal approach. *J Neurosurg Spine* 6 : 521-530, 2007
21. Safran O, Rand N, Kaplan L, Sagiv S, Floman Y : Sequential or simultaneous, same-day anterior decompression and posterior stabilization in the management of vertebral osteomyelitis of the lumbar spine. *Spine (Phila Pa 1976)* 23 : 1885-1890, 1998
22. Silber JS, Anderson DG, Vaccaro AR, Anderson PA, McCormick P; NASS : Management of postprocedural discitis. *Spine J* 2 : 279-287, 2002
23. Yeung AT, Tsou PM : Posterolateral endoscopic excision for lumbar disc herniation : Surgical technique, outcome, and complications in 307 consecutive cases. *Spine (Phila Pa 1976)* 27 : 722-731, 2002