

## Case Report

# Traumatic Atlantoaxial Rotatory Fixation with Accompanying Odontoid and C2 Articular Facet Fracture

Jong Yang Oh, M.D.,<sup>1</sup> Chung Kee Chough, M.D.,<sup>1</sup> Chul Bum Cho, M.D.,<sup>2</sup> Hae Kwan Park, M.D.<sup>1</sup>

*Department of Neurosurgery,<sup>1</sup> Yeouido St. Mary's Hospital, The Catholic University of Korea, Seoul*

*Department of Neurosurgery,<sup>2</sup> Sacred Heart Hospital, College of Medicine, Hallym University, Anyang, Korea*

Traumatic atlantoaxial rotatory fixation (AARF) with accompanying odontoid and C2 articular facet fracture is a very rare injury, and only one such case has been reported in the medical literature. We present here a case of a traumatic AARF associated with an odontoid and comminuted C2 articular facet fracture, and this was treated with skull traction and halo-vest immobilization for 3 months. After removal of the halo-vest immobilization, his neck pain was improved and his neck motion was preserved without any neurologic deficits although mild torticollis was still observed in closer inspection.

**KEY WORDS :** Atlantoaxial rotatory fixation · Odontoid fracture.

## INTRODUCTION

Traumatic atlantoaxial rotatory fixation (AARF) with C2 fracture is a very rare injury, and few such cases have been reported in the literature. We present here a case of a traumatic AARF associated with an odontoid and comminuted C2 articular facet fracture. The patient was successfully treated with skull traction and halo-vest immobilization.

## CASE REPORT

A 37-year-old male patient was referred to our department after he had been hit on the posterior neck by a brick that had been dropped from a 2 meter height at a construction site. The chief complaint was posterior neck pain. The neurologic examination was normal. However, his head was fixed and rotated to the left side and it was tilted toward the right side with decreased neck motion on close inspection.

Radiographs in flexion and extension showed a 3 mm atlantodental interval. The C1-2 joint spaces and the odontoid-lateral mass relationship appeared asymmetrical on the open mouth view (Fig. 1A). The 3D reconstructions of the cervical CT scan revealed anterior dislocation of the left lateral mass of C1 and posterior dislocation of the right lateral mass of C1 (Fig. 2). In addition, fractures of the odontoid and right superior articular facet were noted. The odontoid fracture was type III. Transverse ligament was intact on the cervical spine MRI (Fig. 3). We applied continuous skull traction with 10 lb of force. The cervical open-mouth view radiographs were checked daily. Though the reduction of the fixed AARF was not complete, the asymmetrical odontoid-lateral mass relationship was improved after 2 days of continuous skull traction (Fig. 1B). Halo-vest immobilization was applied for 3 months. At 3 months after the halo-vest immobilization, the follow-up cervical open-mouth view radiography showed healing of the odontoid and articular facet fracture in an acceptable position (Fig. 1C). Yet, the follow-up 3D reconstructions of the cervical CT scan still revealed fixed AARF (Fig. 4). After removal of the halo-vest immobilization, although mild torticollis still observed in closer inspection, his neck pain was completely improved and his neck motion was preserved without neurologic deficits.

• Received : June 8, 2010 • Revised : June 10, 2010

• Accepted : November 22, 2010

• Address for reprints : Chung Kee Chough, M.D.

Department of Neurosurgery, Yeouido St. Mary's Hospital, The Catholic University of Korea, Yeouido-dong, Yeongdeungpo-gu, Seoul 150-713, Korea

Tel : +82-2-3779-1189, Fax : +82-2-786-5809

E-mail : chough@catholic.ac.kr

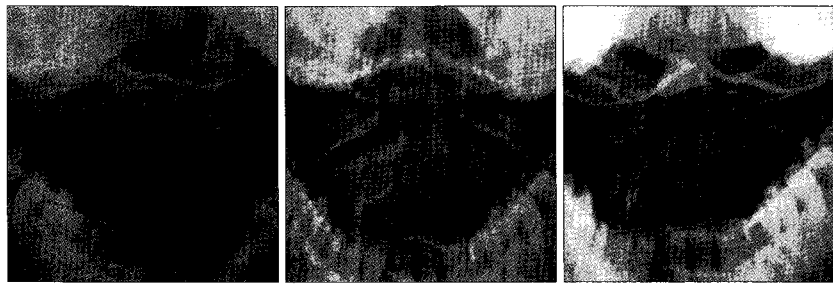
## DISCUSSION

AARF is also known as rotatory subluxation, rotatory displacement, rotary deformity, rotational subluxation, and spontaneous hyperemic dislocation, and this is characterized by incomplete dislocation of the inferior atlantal and superior axial articular facets. In the normal physiologic condition of the atlantoaxial joint complex, a reversible subluxation in the C1/2 joint (lateral mass) occurs during neck rotation. This complex movement is restricted with regard to extreme motions by the transverse ligament and the alar ligaments<sup>4</sup>. However, in fixed AARF, the physiologic reduction or return to the neutral position following a rotational movement is not achieved<sup>3</sup>. So, the patients typically present with painful torticollis and a characteristic 'cock robin' position.

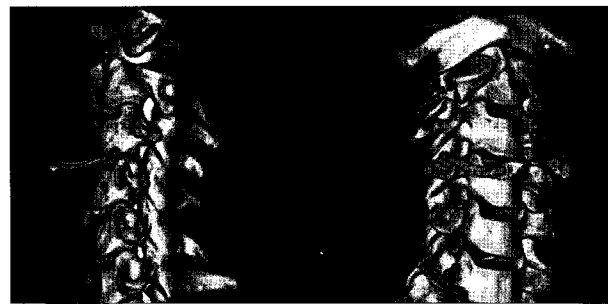
The cause of AARF is generally either an infection or a traumatic event<sup>2</sup>. There is a clear predilection for children and young adults regardless of the cause because of specific anatomical features such as a relatively large head, the underdeveloped neck musculature, the increased laxity of the joint capsule and the horizontal configuration of the C1-C2 articular facets. In children, this is usually seen after infection or inflammation of the surrounding tissues (Grisel's syndrome), and is thought to be secondary to synovial joint effusion and neck muscle spasm<sup>10</sup>. However, AARF in adults is rare and it is usually seen after trauma. The mechanisms of traumatic AARF include infolding of the synovial folds into the C1-C2 joints, muscle spasm, subsequent ligamentous contracture, articular cartilage damage or facet fracture<sup>4</sup>.

The goals of treatment are to restore the normal pain-free range of motion, prevent or reverse any neurologic compromise, and restore the spinal stability<sup>7</sup>. The treatment options include conservative care, immobilization, traction, manual reduction and surgery. Conservative treatment is the first step to treat fixed AARF if the transverse ligament is intact<sup>13</sup>. Surgical reduction and internal fixation are indicated in the following case : when conservative measures fail to reduce fixed AARD, in the case of re-dislocation and for highly unstable injuries<sup>8,12</sup>.

AARF in combination with a C2 fracture is an extremely rare injury, and only 6 such cases have been reported in the literature<sup>1,5,6,9,11</sup>. Moreover, only 1 case of a traumatic AARF with accompanying odontoid and C2 superior articular facet fracture has been reported in the literature<sup>11</sup>. Fuentes et al.<sup>5</sup> reported on a case of successful treatment of type II odontoid fracture combined AARF after surgical fixation and reduction



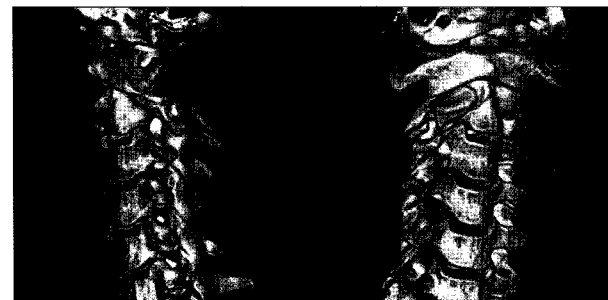
**Fig. 1.** The cervical open mouth view radiograms. A : The cervical open mouth view radiogram reveals an asymmetrical odontoid-lateral mass relationship and a type III odontoid fracture. B : The cervical open mouth view radiogram at 2 days during continuous skull traction shows an improved asymmetrical odontoid-lateral mass relationship. C : The cervical open mouth view radiogram at 3 months after halo-vest immobilization shows an improved asymmetrical odontoid-lateral mass relationship with healed fracture of the odontoid.



**Fig. 2.** 3D reconstruction image of the cervical CT scan showing posterior dislocation of the right lateral mass of C1 and anterior dislocation of the left lateral mass of C1 with C2 and the right superior articular facet of the C2 fractures.



**Fig. 3.** An intact transverse ligament is demonstrated by the axial T1-weighted magnetic resonance image.



**Fig. 4.** 3D reconstruction image of the cervical CT scan obtained at 3 months after halo immobilization still shows posterior dislocation of the right lateral mass of C1 and anterior dislocation of the left lateral mass of C1.

of the odontoid fracture with C1-C2 transarticular fixation. Seybold et al.<sup>9)</sup> reported on a case of failed reduction of C2 articular facet fracture combined with AARF after traction and halo immobilization, and they proposed that only a closed reduction under general anesthesia with muscle relaxation led to reduction. However, Andy et al.<sup>11)</sup> reported complete reduction of AARF and a type II odontoid fracture after only skull traction with a halo frame. These cases show that the definitive treatment of this injury is still controversy.

In our case, we performed skull traction as the initial treatment because of the intact transverse ligament, there was no C1/C2 instability seen on flexion and extension on the plain radiographs and no neurologic deficits. However, skull traction could not completely reduce the AARF. Although acute AARF is thought to be easily reduced, an AARF associated with a facet fracture is difficult to correct<sup>7)</sup>. If closed reduction is unsuccessful, then open reduction must be performed<sup>13)</sup>. However, we did not perform manual reduction under general anesthesia as well as open reduction. There were some reasons for this decision. Firstly, transoral manual reduction could have aggravated the odontoid and articular facet fractures, and promoted spinal instability or neurologic deficits. Secondly, considering patient's subjective well-being and quality of life, the limitation of neck motion after open reduction and C1/C2 arthrodesis would be disadvantageous for this patient, who had no spinal instability or neurologic deficits. Lastly, the torticollis was mild in closer inspection. Thus, we decided halo-vest immobilization without complete reduction. If the treatment with the halo-vest had resulted in non-union of the odontoid fracture or persistent C1/C2 instability, then delayed surgery would have been needed for internal fixation and fusion. Although AARF was still observed on the 3D reconstruction of the cervical CT scan after 3 months, the odontoid fracture showed union without C1/2 instability.

In summary, this case demonstrated that halo-vest immobilization as conservative treatment was effective even if complete reduction could not be achieved. But, if severe torticollis is observed, then open reduction and C1/C2 fusion

should be considered for correcting the deformity.

## CONCLUSION

To the best of our knowledge, this is the second case of a traumatic AARF with accompanying odontoid and C2 superior articular facet fracture. When considering the patient's neck motion and patient's subjective well-being, conservative treatment may be an effective treatment option if the transverse ligament is intact and there is no C1/C2 instability.

## References

1. Cheng SG, Blackmore CC, Mirza SK, Harris JH Jr : Rotatory subluxation and fracture at C1-C2. *AJR Am J Roentgenol* 175 : 540, 2000
2. Crook TB, Eynon CA : Traumatic atlantoaxial rotatory subluxation. *Emerg Med J* 22 : 671-672, 2005
3. El-Khoury GY, Clark CR, Gravett AW : Acute traumatic rotatory atlanto-axial dislocation in children. A report of three cases. *J Bone Joint Surg Am* 66 : 774-777, 1984
4. Fielding JW, Hawkins RJ : Atlanto-axial rotatory fixation. (Fixed rotatory subluxation of the atlanto-axial joint). *J Bone Joint Surg Am* 59 : 37-44, 1977
5. Fuentes S, Bouillot P, Palombi O, Ducolombier A, Desgeorges M : Traumatic atlantoaxial rotatory dislocation with odontoid fracture : case report and review. *Spine (Phila Pa 1976)* 26 : 830-834, 2001
6. Graziano G, Colon G, Hensinger R : Complete atlanto-axial dislocation associated with type II odontoid fracture : a report of two cases. *J Spinal Disord* 7 : 518-521, 1994
7. Kim YS, Lee JK, Moon SJ, Kim SH : Post-traumatic atlantoaxial rotatory fixation in an adult : a case report. *Spine* 32 : E682-E687, 2007
8. Moore KR, Frank EH : Traumatic atlantoaxial rotatory subluxation and dislocation. *Spine (Phila Pa 1976)* 20 : 1928-1930, 1995
9. Seybold D, Hopf F, Müller E, Muhr G, Kollig E : [Traumatic atlanto-axial rotatory fixation with lateral mass fracture of the axis]. *Unfallchirurg* 106 : 1040-1045, 2003
10. Singh VK, Singh PK, Balakrishnan SK, Leitao J : Traumatic bilateral atlantoaxial rotatory subluxation mimicking as torticollis in an adult female. *J Clin Neurosci* 16 : 721-722, 2009
11. Spoor AB, Diekerhof CH, Bonnet M, Oner FC : Traumatic complex dislocation of the atlanto-axial joint with odontoid and C2 superior articular facet fracture. *Spine (Phila Pa 1976)* 33 : E708-E711, 2008
12. Vinchon M, Assaker R, Leclerc X, Lejeune JP : Vertebrobasilar insufficiency resulting from traumatic atlantoaxial instability : case report. *Neurosurgery* 36 : 839-841, 1995
13. Weisskopf M, Naeve D, Ruf M, Harms J, Jeszenszky D : Therapeutic options and results following fixed atlantoaxial rotatory dislocations. *Eur Spine J* 14 : 61-68, 2005