

Case Report

Cerebral Aneurysm in the Long Fenestration at the Middle Portion of M1 Segment

Ki-Bum Sim, M.D., Ph.D., Chang Sub Lee, M.D., Ph.D., Jung Cheol Park, M.D., Ji Soon Huh, M.D.

Department of Neurosurgery, Jeju National University College of Medicine, Jeju, Korea

We report a unique case of bilateral mirror image M1 aneurysms, one of which was an unruptured aneurysm arising from the proximal end of right middle cerebral artery fenestration with long loop and the other ruptured aneurysm from the contralateral side. We clipped ruptured aneurysm first and unruptured one in three months after the first operation. The difficulties of identifying this unusual vascular anomaly and possible problems during the surgery of an aneurysm at the site of fenestration are discussed with a review of the literature.

KEY WORDS : Cerebral aneurysm · Fenestration · Middle cerebral artery.

INTRODUCTION

The fenestration of middle cerebral artery (MCA) is a rare anatomical variant. It is often asymptomatic. However, with the recent advances of neuroradiologic technique, the reported cases of MCA fenestration associated with cerebral aneurysms are increasing. To date, about 67 cases of MCA fenestration were reported and two thirds of these cases were reported in the later half from the first case report in 1962 to present. We report a rare case of bilateral MCA aneurysms, one of which was developed at the proximal end of right MCA fenestration with long convex loop on the middle portion of M1.

CASE REPORT

A 32-year-old man, previously healthy, presented with sudden onset of severe headache and vomiting. The patient had no history of trauma and his past medical history was unremarkable. He demonstrated meningeal irritation signs with no focal neurological deficit. A computed tomography

(CT) scan of the head showed slight subarachnoid hemorrhage in the left insular cistern (Fig. 1). A three-dimensional CT angiography showed bilateral mirror image MCA aneurysms located at the middle portion of M1 segment and a vascular loop enclosing the right MCA aneurysm was suspected (Fig. 2, 3A). Conventional cerebral angiography showed both aneurysms arose at the similar distance, about 1.5 cm, from the internal carotid artery (ICA) bifurcation and directed inferolaterally. The left one measured 4 mm in diameter and the right one measured 6 mm in diameter with

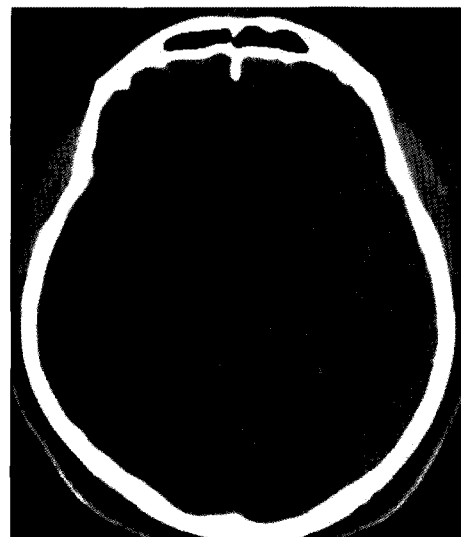


Fig. 1. Initial brain computed tomogram shows slight subarachnoid hemorrhage in left insular cistern.

• Received : January 25, 2010 • Revised : March 22, 2010
• Accepted : November 22, 2010
• Address for reprints : Ji Soon Huh, M.D.
Department of Neurosurgery, Jeju National University Hospital,
Jeju National University College of Medicine, 1753-3 Ara 1-dong,
Jeju 690-716, Korea
Tel : +82-64-717-1620, Fax : +82-64-717-1630
E-mail : nsdrhuh@jejunu.ac.kr

smooth surface. Despite of conventional angiography, we could not differentiate definitely the MCA fenestration from overlapping of vessels (Fig. 3B). We presumed the left one was ruptured and Guglielmi detachable coil embolization was tried but it was discontinued due to intimal damage to the left ICA. A left frontotemporal craniotomy was performed. The surgical exploration revealed that the left MCA aneurysm was ruptured and it was clipped in usual manner without difficulty. After three months, the second operation was performed. Three-dimensional rotational angiography at that time clearly defined the relationship of the fenestration and an aneurysm (Fig. 3C). The fenestration started from the middle portion of the M1 and a saccular aneurysm arose from the proximal end of the fenestration. The size of diagonal loop was measured about 1 cm from proximal to distal end of the fenestration. The aneurysm was also clipped successfully with right frontotemporal craniotomy. Most of characteristics observed in the previous study could be confirmed under the surgical microscope but some unexpected problems were encountered. The aneurysmal sac was directed toward behind the fenestrated branches. The fenestrated branches were densely adhered to the aneurysmal sac all the way. Furthermore, it was hard to distract or retract the branches because the distal end of fenestration was fused (Fig. 4). After dissection of aneurysmal neck, an obliquely angled aneurysmal clip was applied. The postoperative course was uneventful and he was discharged without neurologic deficit.

DISCUSSION

In 1962, Crompton reported the first case of MCA fenestration in 347 middle cerebral arteries examined in autopsy⁴. The incidence of MCA fenestration varies from 0.02% to 1% according to the methods of investigation (e.g., autopsy or angiographic studies). It was observed 0.17% to 1% in autopsy studies^{4,31-33} and 0.02% to 0.43% in angiographic studies^{9,10,25}. Although it shows similar incidences between anatomical and angiographic studies, the conventional angiography has some diagnostic difficulties. The MCA fenestration that is obscured by combined aneurysm or other arterial

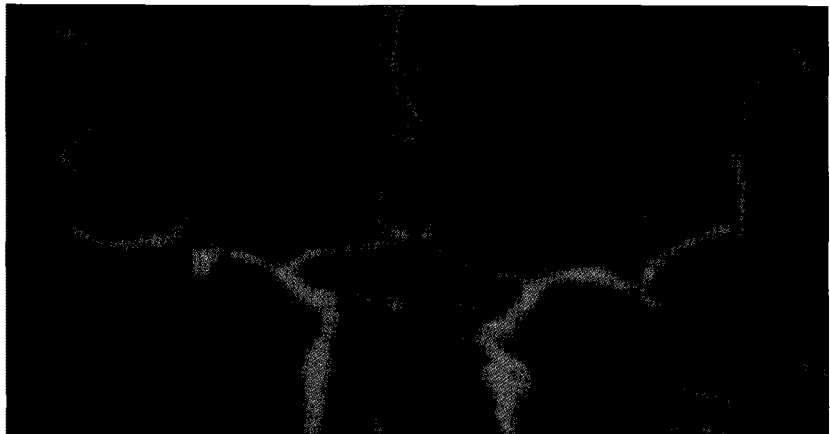


Fig. 2. The computed tomographic angiogram shows bilateral mirror image middle cerebral artery aneurysms.

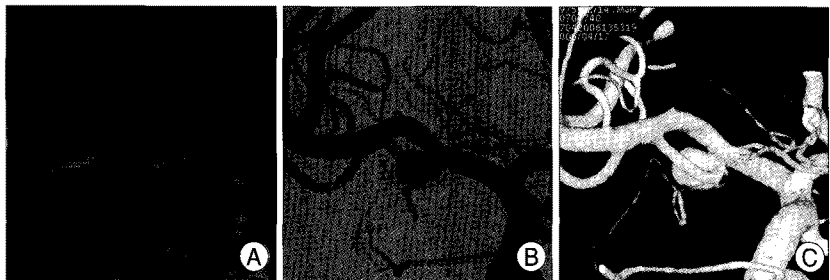


Fig. 3. Angiographic findings of M1 aneurysm in the long loop fenestration with various methods. Three dimensional computed tomographic angiogram (A) and right carotid angiogram (B), left anterior oblique view show a right middle cerebral artery (MCA) aneurysm arising from the proximal end of presumed MCA fenestration, but definite diagnosis of MCA fenestration was not made. Three-dimensional rotational cerebral angiography (C) shows the accurate relationship of right MCA aneurysm arising from the proximal end of fenestration.

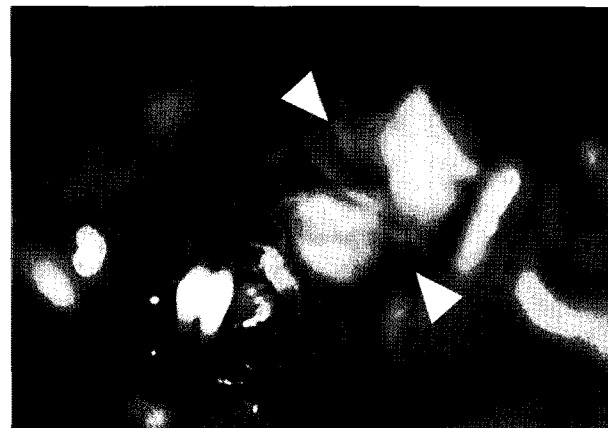


Fig. 4. Intraoperative photograph shows a middle cerebral artery aneurysm (black arrow) in the loop of fenestration (white arrowhead) and a temporary clip in the proximal M1 segment.

branches could be unrecognized. We also could not confirm the presumed MCA fenestration with conventional angiography but definite diagnosis was made with three-dimensional rotational angiography. The stereoscopic images from this study revealed clear relationship of the fenestrated vessels and the aneurysm at the proximal end of fenestration. It is believed that stereoscopic reconstruction technique such as

three-dimensional rotational angiography could be helpful to overcome the limitation of conventional angiography in detecting these hidden anomalies and identifying the relationship of fenestration loop and aneurysms.

To date, about 67 cases of MCA fenestration including our case were reported¹⁻³³. Most of previous articles on the MCA fenestration focused on the association of cerebral aneurysm located at the site of fenestration or distant site from it. In the review of previous reports, 19 cases were coincided with cerebral aneurysms^{1,5,7,12-19,24,29,30,33} and 6 cases of aneurysm developed at the proximal or distal end of fenestration^{5,12,18,19,24,30}. Other data indicated that the MCA fenestration was developed mainly at the M1 portion and there was no ethnic predilection between Asian and Western countries. Although these were sporadic cases, it is considered that arterial fenestration would be a spectrum of congenital anomaly that commonly accompany with cerebral aneurysms and fenestration site would be a preferred site of aneurysm development. Finlay measured stereological data from six segment of brain arteries, each including fenestration (five from vertebrobasilar junction and one from the MCA). He found media defect on the both edge of fenestration and difference of subendothelial layering between proximal and distal end of fenestration. He stated that the propensity of aneurysm development at the site of fenestration could be explained by structural abnormality and hemodynamic stress like the aneurysms arising from any bifurcation. Structural investigation by Finlay supports the assumption that proximal end of fenestration could be a preferred site of aneurysm development⁶.

The MCA fenestration is a rare vascular anomaly and an incidental finding in itself. But when saccular aneurysms develop in its proximal end of fenestration, neurosurgeons could be encountered the surgical problems that we had experienced. The closed loop of fenestration enclosing the aneurysmal sac is an unfamiliar surgical environment. It could disturb the dissection between the fenestrated branches and aneurysmal sac to make space for the clip placement. Although the difficulties in dissection and clip placement may be different to the size and relationship of fenestrated loop and aneurysmal sac, it is considerable that the surgical difficulties in the treatment of aneurysm adjacent to this unfamiliar vascular anomaly could be a new clinical significance of arterial fenestration.

CONCLUSION

We report a rare case of MCA aneurysm originated from proximal end of fenestration with long loop at the middle portion of M1 segment. Vascular neurosurgeons have to consider such hidden vascular anomaly in the review of

preoperative examination and prepare the possible surgical problems during operation.

• Acknowledgements

This paper was supported by a grant from the Jeju National University Hospital Research Fund in 2008.

References

1. Baba M, Shimizu T, Kagawa M, Kitamura K, Kobayashi N : [A case of multiple anomalies of cerebral vessels--fenestration of the middle cerebral artery aneurysm of the anterior communicating artery and arteriovenous malformation on the frontopolar region (author's transl).] *No Shinkei Geka* 5 : 59-64, 1977
2. Barbara H, Marek S, Stawomir B, Dabrowka S : Angiographic and CT-angiographic appearance of middle cerebral artery fenestration in a patient with spontaneous subarachnoid hemorrhage. *Pol J Radiol* 68 : 87-89, 2003
3. Ciszek B : On a rare form of fenestration of the middle cerebral artery. *Folia Morphol (Warsz)* 54 : 9-13, 1995
4. Crompton MR : The pathology of ruptured middle-cerebral aneurysms with special reference to the differences between the sexes. *Lancet* 280 : 421-425, 1962
5. Deruty R, Pelissou-Guyotat I, Mottolese C, Bogнар L, Laharotte JC, Turjman F : Fenestration of the middle cerebral artery and aneurysm at the site of the fenestration. *Neurol Res* 14 : 421-424, 1992
6. Finlay HM, Canham PB : The layered fabric of cerebral artery fenestrations. *Stroke* 25 : 1799-1806, 1994
7. Fujimoto M, Nakahara I, Tanaka M, Iwamuro Y, Watanabe Y, Harada K : [Multiple intracranial aneurysms and vascular abnormalities associated with neurofibromatosis type 1 : a case report.] *No Shinkei Geka* 32 : 355-359, 2004
8. Fuse T, Niwa Y, Harada S : Local intraarterial fibrinolytic therapy for embolic stroke associated with vascular anomalies--two case reports. *Neurol Med Chir (Tokyo)* 40 : 641-644, 2000
9. Gailloud P, Albayram S, Fasel JH, Beauchamp NJ, Murphy KJ : Angiographic and embryologic considerations in five cases of middle cerebral artery fenestration. *AJNR Am J Neuroradiol* 23 : 585-587, 2002
10. Ito J, Maeda H, Inoue K, Onishi Y : Fenestration of the middle cerebral artery. *Neuroradiology* 13 : 37-39, 1977
11. Jeong SK, Kwak HS, Cho YI : Middle cerebral artery fenestration in patients with cerebral ischemia. *J Neurol Sci* 275 : 181-184, 2008
12. Kalia KK, Ross DA, Gutin PH : Multiple arterial fenestrations, multiple aneurysms and an arteriovenous malformation in a patient with subarachnoid hemorrhage. *Surg Neurol* 35 : 45-48, 1991
13. Kim DW, Kang SD : Middle cerebral artery fenestration associated with an aneurysm. *Korean J Cerebrovasc Surg* 7 : 158-160, 2005
14. Kim MS, Hur JW, Lee JW, Lee HK : Middle cerebral artery anomalies detected by conventional angiography and magnetic resonance angiography. *J Korean Neurosurg Soc* 37 : 263-267, 2005
15. Kitami K, Kamiyama H, Yasui N : [Angiographic analysis of the middle cerebral artery in cerebral aneurysms--its branching pattern and so-called vascular anomalies.] *No Shinkei Geka* 13 : 283-290, 1985
16. Lazar ML, Bland JE, North RR, Bringewald PR : Middle cerebral artery fenestration. *Neurosurgery* 6 : 297-300, 1980
17. Lee SJ, Hong SK : M1 fenestration in a patient with multiple cerebral arterial aneurysm : case report. *J Korean Neurosurg Soc* 27 : 536-539, 1998
18. Nakamura H, Takada A, Hide T, Ushio Y : Fenestration of the middle cerebral artery associated with an aneurysm--case report. *Neurol Med Chir (Tokyo)* 34 : 555-557, 1994
19. Nussbaum ES, Defillo A, Janjua TM, Nussbaum LA : Fenestration of the middle cerebral artery with an associated ruptured aneurysm. *J Clin*

- Neurosci* 16 : 845-847, 2009
20. Okudera H, Koike J, Toba Y, Kuroyanagi T, Kyoshima K, Kobayashi S. [Fenestration of the middle cerebral artery associated with cerebral infarction. Report of two cases.] *Neurol Med Chir (Tokyo)* 27 : 559-563, 1987
 21. Osborn RE, Kirk G : Cerebral arterial fenestration. *Comput Radiol* 11 : 141-145, 1987
 22. Parmar H, Sitoh YY, Hui F : Normal variants of the intracranial circulation demonstrated by MR angiography at 3T. *Eur J Radiol* 56 : 220-228, 2005
 23. Sanders WP, Sorek PA, Mehta BA : Fenestration of intracranial arteries with special attention to associated aneurysms and other anomalies. *AJNR Am J Neuroradiol* 14 : 675-680, 1993
 24. Schmieder K, Hardenack M, Harders A : Proximal long fenestration associated with an internal carotid artery aneurysm. Case illustration. *J Neurosurg* 86 : 733, 1997
 25. Teal JS, Rumbaugh CL, Bergeron RT, Segall HD : Angiographic demonstration of fenestrations of the intradural intracranial arteries. *Radiology* 106 : 123-126, 1973
 26. Uchino A, Kato A, Abe M, Kudo S : Association of cerebral arteriovenous malformation with cerebral arterial fenestration. *Eur Radiol* 11 : 493-496, 2001
 27. Uchino A, Kato A, Takase Y, Kudo S : Middle cerebral artery variations detected by magnetic resonance angiography. *Eur Radiol* 10 : 560-563, 2000
 28. Uchino A, Takase Y, Nomiyama K, Egashira R, Kudo S : Fenestration of the middle cerebral artery detected by MR angiography. *Magn Reson Med Sci* 5 : 51-55, 2006
 29. Ueda T, Goya T, Kinoshita K : [Fenestration of the middle cerebral artery associated with an aneurysm.] *Neurol Med Chir (Tokyo)* 23 : 278-281, 1983
 30. Ueda T, Goya T, Kinoshita K, Wakuta Y, Mihara K : [Multiple anomalies of cerebral vessels. A case of multiple aneurysms associated with fenestration of the middle cerebral artery and persistent primitive trigeminal artery.] *No Shinkei Geka* 12 : 531-536, 1984
 31. Umansky F, Dujovny M, Ausman JJ, Diaz FG, Mirchandani HG : Anomalies and variations of the middle cerebral artery : a microanatomical study. *Neurosurgery* 22 : 1023-1027, 1988
 32. Wollschlaeger G, Wollschlaeger PB, Lucas FV, Lopez VF : Experience and result with postmortem cerebral angiography performed as routine procedure of the autopsy. *Am J Roentgenol Radium Ther Nucl Med* 101 : 68-87, 1967
 33. Yasargil MG : *Microneurosurgery*, New York : Thieme-Stratton Inc., 1984, pp72-91