

Clinical Article

Hypopharyngeal Wall Exposure within the Surgical Field : The Role of Axial Rotation of the Thyroid Cartilage during Anterior Cervical Surgery

Byung Kwan Choi, M.D.,¹ Won Ho Cho, M.D.,¹ Chang Hwa Choi, M.D.,¹ Geun Sung Song, M.D.,¹ Choongrak Kim, Ph.D.,³ Hak Jin Kim, M.D.²

Departments of Neurosurgery,¹ Radiology,² School of Medicine, Pusan National University, Busan, Korea

Department of Statistics,³ Pusan National University, Busan, Korea

Objective : Esophageal/hypopharyngeal injury can be a disastrous complication of anterior cervical surgery. The amount of hypopharyngeal wall exposure within the surgical field has not been studied. The objective of this study is to evaluate the chance of hypopharyngeal wall exposure by measuring the amount of axial rotation of the thyroid cartilage (ARTC) and posterior projection of the hypopharynx (PPH).

Methods : The study was prospectively designed using intraoperative ultrasonography. We measured the amount of ARTC in 27 cases. The amount of posterior projection of the hypopharynx (PPH) also was measured on pre-operative CT and compared at three different levels; the superior border of the thyroid cartilage (SBTC), cricoarytenoid joint and tip of inferior horn of the thyroid cartilage (TIHTC). The presence of air density was also checked on the same levels.

Results : The angle of ARTC ranged from -6.9° to 29.7° , with no statistical difference between the upper and lower cervical group. The amount of PPH was increased caudally. Air densities were observed in 26 cases at the SBTC, but none at the TIHTC.

Conclusion : Within the confines of the thyroid cartilage, surgeons are required to pay more attention to the status of hypopharynx/esophagus near the inferior horn of the thyroid cartilage. The hypopharynx/esophagus at the TIHTC is more likely to be exposed than at the upper and middle part of the thyroid cartilage, which may increase the risk of injury by pressure. Surgeons should be aware of the fact that the visceral component at C6-T1 surgeries also rotates as much as when the thyroid cartilage is engaged with a retractor. The esophagus at lower cervical levels warrants more careful retraction because it is not protected by the thyroid cartilage.

KEY WORDS : Anterior cervical surgery · Thyroid cartilage · Hypopharynx · Esophageal injury.

INTRODUCTION

Little attention has been given to how the hypopharynx and esophagus are exposed within the surgical field during anterior cervical surgeries. When the thyroid cartilage is engaged with a retractor, the amount of hypopharyngeal wall exposure within the surgical field is unknown. Since the thyroid cartilage lamina makes it difficult to expose the coronally-oriented posterior wall of the hypopharynx, it is uncertain whether the retractor blade makes contact with the hypopharynx. One of the keys to explain hypopharyngeal

wall exposure is to measure the axial rotation of the thyroid cartilage (ARTC). In the literature, the thyroid cartilage has been illustrated to rotate enough to expose hypopharyngeal wall within the surgical field¹⁾. If the amount of ARTC is large enough to allow hypopharyngeal wall to be exposed within the surgical field, the hypopharynx will be more prone to be injured (Fig. 1A). It is because sharp retractors, instruments and retraction pressure are potential causes of hypopharyngeal/esophageal injuries^{6,7,11,13)}. However, if there is no rotation of the thyroid cartilage intraoperatively, hypopharyngeal wall exposure within the surgical field would be minimal (Fig. 1B). Additionally, the degree of posterior projection of the hypopharynx (PPH) could be another indicator (Fig. 2A). Thus far, the ARTC in anterior cervical spine surgeries has received little attention from spine surgeons. It has never been measured and there is no confirmed data as to the amount of ARTC during anterior cervical surgery.

• Received : March 30, 2010 • Revised : July 6, 2010

• Accepted : November 26, 2010

• Address for reprints : Hak Jin Kim, M.D.

Department of Radiology, School of Medicine, Pusan National University,
305 Gudeok-ro, Seo-gu, Busan 602-739, Korea

Tel : +82-51-240-7257, Fax : +82-51-244-0282

E-mail : hakjink@pusan.ac.kr

The purpose of this study was to evaluate hypopharyngeal/esophageal wall exposure within the surgical field by measuring the amount of ARTC and PPH during anterior cervical surgery.

MATERIALS AND METHODS

The study was prospectively designed. Beginning in March 2006 one-level anterior cervical surgeries were consecutively assigned to the current study. These surgeries included anterior cervical discectomy and fusion (ACDF) and anterior cervical foraminotomy. We obtained informed consent for intra-operative ultrasonographic measurements from patients pre-operatively. Patients who declined the intra-operative measurements were not included. The degree of ARTC was measured using a surgical protractor when a Caspar retractor was applied (Fig. 2B, C). In these patients, pre-operative CT and MRI were obtained. Based on the pre-operative images, those patients with asymmetric thyroid cartilage laminae were excluded from the study. Twenty-seven patients were finally enrolled into the study. There were 20 males and 7 females. The age ranged from 38 to 77 years with an average of 53.8. There were 7 cases of anterior cervical foraminotomy and 20 cases of ACDF. The patient was placed in the supine position. A rolled-towel was placed under the patient's shoulders. The head and neck was extended. Before draping, the operating room table and the patient's shoulders were balanced to avoid angular bias. A transverse skin incision was made in the usual manner. The sternocleidomastoid muscle was retracted laterally and the visceral component was retracted medially. The deep cervical fascia was opened immediately medial to the carotid artery. Medial margins of longus colli muscles were displaced laterally with a dissector. The space under the longus colli muscles was created to

expose the uncovertebral joint. Serrated blades were placed under the longus colli muscles and distracted with the Caspar retractor. The blades were distracted to expose both uncovertebral joints. A surgical protractor was modified to measure ARTC when retraction was applied. This protractor has two holding grips which are attached to an ultrasono-

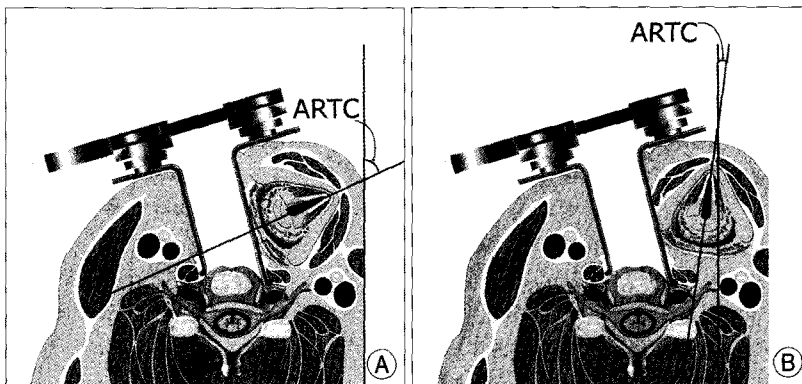


Fig. 1. The relationships between the hypopharyngeal wall exposure within the surgical field and the amount of axial rotation of the thyroid cartilage (ARTC). A : When the thyroid cartilage rotates enough to allow hypopharyngeal wall to be exposed within the surgical field, sharp retractors, instruments and retraction pressure are more likely to cause hypopharyngeal injuries. B : If the ARTC is minimal, the thyroid cartilage lamina primarily contacts the retractor blade and restricts hypopharyngeal wall exposure.

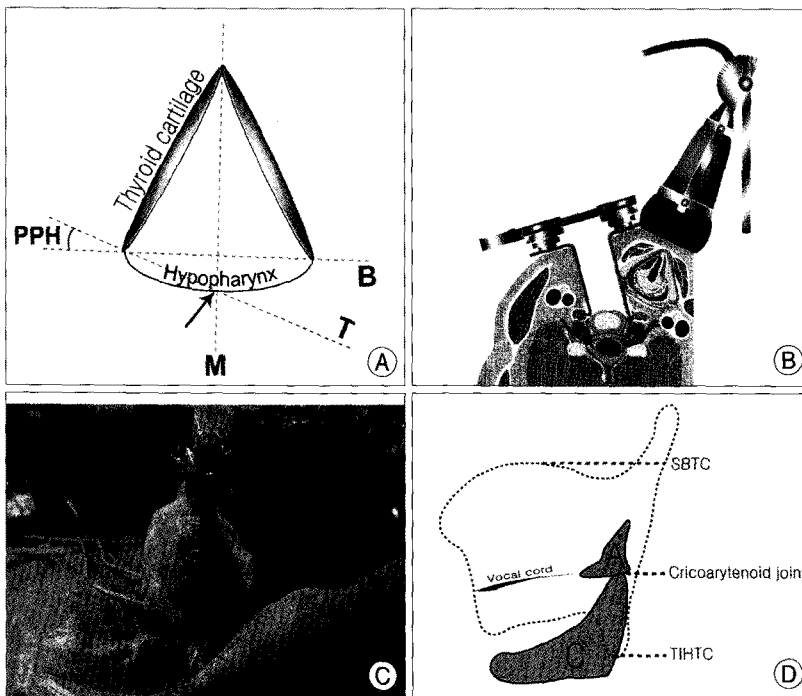


Fig. 2. Measurements of ARTC and posterior projection of the hypopharynx (PPH). A : The definition of PPH is an angle between two lines (B and T). B is the line that connects two posterior borders of the thyroid cartilage. T is the line connecting one posterior border of the thyroid cartilage and a point (arrow) where line M and the posterior boundary of the hypopharynx meet. M is a line that symmetrically bisects the thyroid cartilage. B : The relationship between the surgical protractor and the thyroid cartilage measuring the amount of ARTC. C : Intraoperative measurement of the ARTC using surgical protractor modified to be attached to an ultrasonographic probe. D : The thyroid, arytenoid (A) and cricoid (C) cartilages. The amount of PPH is measured at three different levels of the thyroid cartilage; superior border of the thyroid cartilage (SBTC), cricoarytenoid joint and tip of inferior horn of the thyroid cartilage (TIHTC). These levels are illustrated as dotted lines.

graphic probe (Fig. 2B, C). The operations were performed by two surgeons (BKC and GSS). A radiologist (HJK) examined the thyroid cartilage laminae to determine the orientation of the thyroid cartilage. While the thyroid cartilage laminae were shown to be balanced on the screen, the rotation angle of the thyroid cartilage was measured by the protractor. The direction of rotation was defined to have a positive value when the prominence of the thyroid cartilage was rotated to the opposite side of the surgical approach (Fig. 1). For analysis, patients were divided into the following two groups based on the level of surgery : C3-4, 4-5, and 5-6 were assigned to the upper cervical group (n = 14); and C6-7 and C7-T1 were assigned to the lower cervical group (n = 13). In these patients, pre-operative CT scans were reviewed. The amount of PPH was measured at three different levels (Fig. 2D) of the thyroid cartilage [the superior border of the thyroid cartilage (SBTC), the cricoarytenoid joint, and the tip of inferior horn of the thyroid cartilage (TIHTC)]. The degree of PPH was defined as an angle between two lines (the line that connects two posterior borders of the thyroid cartilage lamina and the line connecting the posterior border of the lamina and maximal hypopharyngeal projection) (Fig.

2A). The PPH was measured by a picture archiving communication system (m-view 3.5, Infinitt Healthcare, Seoul, Korea). The presence of air density in the hypopharyngeal cavity was also checked at the same levels.

RESULTS

Axial rotation of the thyroid cartilage

For the upper cervical group (C3-4, C4-5, and C5-6), average ARTC was 13.7° with a standard deviation of 12.28°. For the lower cervical group (C6-7 and C7-T1), the average ARTC was 10.2 ± 9.52° (Table 1). There was no statistical difference between the two groups (t-test, p = 0.425).

Posterior projection of the hypopharynx

The PPH at the SBTC was 8.3 ± 6.45° (Table 2). It showed an average of 15.5 ± 5.9° at the level of the cricoarytenoid joint. This angle at the TIHTC was 27.3 ± 5.10°. The TIHTC coincided with the level of the cricoid cartilage in all cases. The differences in the angles at three different levels were statistically significant (one way analysis of variance, p < 0.001).

Table 1. Axial rotation of the thyroid cartilage

Group	Case	Segment	Rotation	Approach	Average
The Upper Cervical Group	Case 1	C3-4	21.0°	Right	13.7 ± 12.28°
	Case 5	C3-4	26.0°	Right	
	Case 8	C3-4	29.7°	Right	
	Case 21	C3-4	26.1°	Left	
	Case 20	C4-5	14.1°	Left	
	Case 23	C4-5	1.3°	Right	
	Case 3	C5-6	-4.8°	Right	
	Case 6	C5-6	9.6°	Right	
	Case 7	C5-6	25.7°	Right	
	Case 10	C5-6	25.7°	Left	
	Case 15	C5-6	11.8°	Right	
	Case 18	C5-6	-6.9°	Left	
	Case 22	C5-6	7.5°	Right	
	Case 27	C5-6	4.8°	Right	
The Lower Cervical Group	Case 2	C6-7	0.0°	Right	10.2 ± 9.52°
	Case 4	C6-7	28.5°	Left	
	Case 12	C6-7	9.0°	Left	
	Case 13	C6-7	6.0°	Right	
	Case 14	C6-7	21.7°	Right	
	Case 16	C6-7	6.0°	Right	
	Case 19	C6-7	11.9°	Left	
	Case 24	C6-7	1.8°	Left	
	Case 25	C6-7	-3.1°	Left	
	Case 26	C6-7	24.7°	Left	
Case 9	C7-T1	11.8°	Left		
Case 11	C7-T1	7.8°	Left		
Case 17	C7-T1	7.0°	Left		

t-test, p = 0.425

The presence of air density in the hypopharyngeal cavity

In 26 cases (96.3%), air densities were observed in the hypopharyngeal cavity at the SBTC. Only six cases (22.2%) showed air densities at the level of the cricoarytenoid cartilage. None of the cases showed air densities in the hypopharynx at the level of the TIHTC. There was a statistical difference among the levels (multiple comparison test, p < 0.001).

DISCUSSION

Hypopharynx/esophageal injuries can be catastrophic complications of anterior cervical surgeries^{3,10,12}. Since the hypopharynx spans from the oropharynx to the esophagus inferiorly¹⁶, hypopharyngeal injury is often included in esophageal perforation^{8,9,15}.

The current results show that the thyroid cartilage rotates an average of 10-13°. When we apply these values in a geometrical model (Fig. 1B), this amount of rotation does not permit the retractor blade to make contact with the

hypopharyngeal wall. The observed range of motion suggests that the retractor would contact primarily with the thyroid cartilage thus restricting hypopharyngeal wall exposure during surgery. As far as sharp instruments and retraction pressure are concerned, the thyroid cartilage lamina plays a protective role against injuries. Between the upper and lower cervical groups, the difference in the degree of ARTC was not significant ($p = 0.45$). In the current study, two groups were divided by the possibility of retractor engagement with the thyroid cartilage lamina. C5-6 was assigned to the upper cervical group because C5-6 surgeries are more likely to accompany retractor engagement with the thyroid cartilage; the Caspar retractor blade spans more than one cervical level and the prominence of the thyroid cartilage approximates the level of C4-5^{1,2,5,17}. These results show the visceral component in the lower cervical group rotates as much as in the upper cervical group. It is noteworthy that the thyroid cartilage rotates with little or no retractor engagement in the lower cervical group. Since they are invested in the same visceral fascia with the thyroid cartilage², the esophagus and trachea in the lower cervical group are thought to rotate together with the thyroid cartilage. The demarcation of the visceral component is often visible on the post-operative CT (Fig. 3). Our results indicate that the possibility of esophageal/hypopharyngeal wall exposure is greater in lower cervical surgeries. Surgeons should pay more attention to the status of esophagus in lower cervical spine surgeries because it is not protected by the thyroid cartilage.

Geometrically, the possibility of hypopharyngeal wall exposure escalates as the amount of the PPH increases (Fig. 2A). By comparing the PPH at three different levels (Fig. 2D), we attempted to determine the change in hypopharyngeal wall exposure in the caudal direction. Roughly, each level represents uppermost, middle, and lowermost levels of the thyroid cartilage. Each landmark was chosen based on the feasibility of reading the landmark on the CT scan. The level of TIHTC coincides with the cricoid cartilage. As a surface landmark,

the cricoid cartilage coincides with C5-6¹, C6⁵, or C6-7^{14,17}.

The amount of the PPH was most prominent at the TIHTC, with an average of 27.3°; the amount of the PPH was least obvious at the SBTC. The trend was statistically significant ($p < 0.001$). When we reviewed the CT findings

Table 2. PPH at three different levels of the thyroid cartilage

	SBTC	Cricoaarytenoid joint	TIHTC
Case 1	7.0°	4.5°	25.3°
Case 2	12.0°	12.3°	29.6°
Case 3	13.9°	21.8°	27.4°
Case 4	10.7°	9.5°	25.2°
Case 5	-14.4°	6.6°	28.3°
Case 6	7.3°	12.4°	27.9°
Case 7	10.9°	19.6°	31.1°
Case 8	7.3°	16.2°	26.8°
Case 9	5.5°	13.1°	14.8°
Case 10	7.6°	9.7°	24.3°
Case 11	13.6°	17.3°	35.3°
Case 12	9.2°	14.7°	29.2°
Case 13	8.7°	18.6°	31.3°
Case 14	5.2°	17.8°	30.5°
Case 15	12.4°	16.0°	25.3°
Case 16	14.8°	32.0°	32.1°
Case 17	-0.6°	9.7°	30.6°
Case 18	18.5°	19.1°	31.8°
Case 19	13.1°	18.0°	29.8°
Case 20	9.2°	20.7°	27.4°
Case 21	4.7°	13.0°	21.0°
Case 22	14.8°	16.0°	31.0°
Case 23	13.6°	24.1°	31.1°
Case 24	9.2°	11.9°	24.8°
Case 25	0.7°	8.3°	16.4°
Case 26	6.8°	14.5°	17.2°
Case 27	1.3°	21.9°	32.7°
Average	8.3 ± 6.45°	15.5 ± 5.92°	27.3 ± 5.10°

One way analysis of variance, $p < 0.001$. SBTC : superior border of the thyroid cartilage, TIHTC : tip of inferior horn of the thyroid cartilage, PPH : posterior projection of the hypopharynx

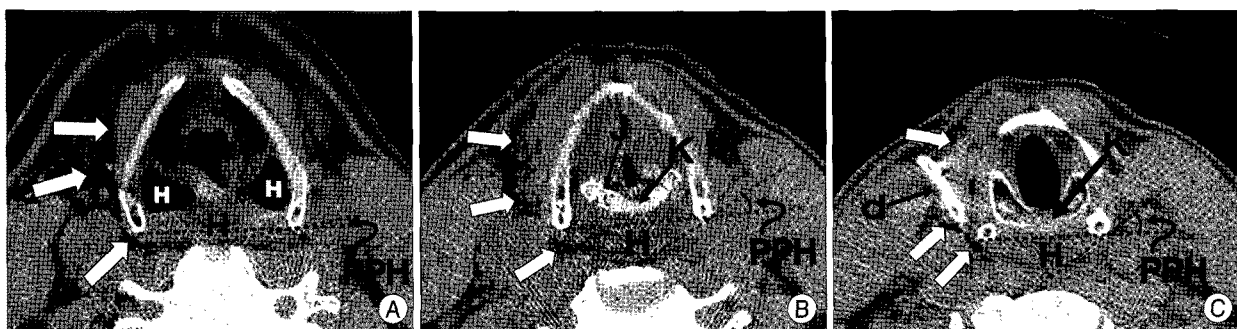


Fig. 3. The visceral component bordered by air densities (white arrows) and a drain tube (d) on post-operative neck CT images. The amount of PPH of the hypopharynx (H) increases in caudal direction. A : A scan at the level of SBTC. Air densities in the hypopharynx are observed. B : At the level of the cricoarytenoid joint (J), the amount of PPH is larger. The hypopharynx (H) is located behind the cricoid cartilage (K). C : At the TIHTC, the amount of PPH is largest. No air density is observed in the hypopharynx.

at each level, we could relate some anatomic features behind this trend. At the level of the SBTC, the only structure that fills the cavity is the epiglottis. We observed air densities in the hypopharynx in all cases except one; the air densities explain the least prominent PPH at this level. These air densities (or empty space) may play a role as reserve spaces and allow the hypopharyngeal wall to be less seriously affected when retraction pressure is applied. At the level of the cricoarytenoid joint, the space in the thyroid cartilage is occupied by voice-generating structures, such as the arytenoid cartilage, thyroarytenoid muscles, and cricoid cartilage. These contents within the thyroid cartilage push the hypopharyngeal wall posteriorly, leaving less space for the hypopharynx (Fig. 3B). We observed air densities in only 6 cases in the hypopharynx at the level of the cricoarytenoid joint. Inferior to this level, the space in the thyroid cartilage is primarily occupied by the cricoid cartilage. This brings the hypopharynx behind this ring-shaped cartilage (Fig. 3C). At the TIHTC, the hypopharynx projects further posteriorly. The hypopharynx is no longer protected by the thyroid cartilage lamina and no air density was observed. The influence of retraction pressure could be more serious when we considered the shape and hard consistency of the cricoid cartilage. When pressure is applied, it can compress the hypopharynx against the convex surface of the ring-shaped cartilage. The thin posterior mucosa is already noted as a possible cause of perforation⁴⁾. Considering the amount of PPH and number of air densities, the risk of the hypopharyngeal wall injury is the greatest at the level of the TIHTC within the confines of the thyroid cartilage.

There are several reports that support the findings of the current study. Newhouse et al.²⁾ reported 22 cases of hypopharyngoesophageal perforations. There was no perforation at C4-5 and only one case at the C3-4 level. This could be partially explained by the less chance of performing surgery at these levels. However, the presence of the thyroid cartilage and minimal rotation of the cartilage played a role in preventing hypopharyngeal perforation. At the level of C5-C7, frequent hypopharyngoesophageal injuries has been commented^{9,11)}. We suggest that this can be explained by the absence of the thyroid cartilage lamina and the greatest amount of PPH at the TIHTC.

Also, intraluminal pressure has shown to be greater at C5-6 when compared with C3-4 in a cadaveric study¹⁵⁾. However, clear explanation on the pressure difference was not given on the report¹⁵⁾. This can be related to the fact that the thyroid cartilage lamina or hyoid bone contacts retractor blades and direct pressure was not delivered to the cavity of the hypopharynx at the level of C3-4. The hypopharynx can accommodate more pressure because it has more space filled with air.

CONCLUSION

Within the confines of the thyroid cartilage during anterior cervical approach, surgeons should pay more attention to the status of hypopharynx/esophagus near the inferior horn of the thyroid cartilage. The hypopharynx/esophagus at the TIHTC is more likely to be exposed than at the upper and middle part of the thyroid cartilage, which may increase the risk of injury by pressure.

Surgeons should be aware of fact that the visceral component at C6-T1 surgeries also rotates as much as when the thyroid cartilage is engaged with a retractor. The esophagus at lower cervical levels warrants more careful retraction because it is not protected by the thyroid cartilage.

• Acknowledgements

This article was presented at Korean Spinal Neurosurgery Society 23th Annual meeting. Byung Kwan Choi was supported 2 years by Pusan National University Research Grant.

References

1. Baskin JJ, Vishteh AG, Dickman CA, Sonntag VKH : Anterior cervical instrumentation, in Winn HR (ed) : *Youmans Neurological Surgery*, ed 5. Philadelphia : Saunders, 2004, Vol 4, pp4621-4638
2. Biyani A, An HS: Anterior upper cervical spine approaches, in Herkowitz HN (ed) : *The cervical spine surgery atlas*, ed 2. Philadelphia : Lippincott Williams and Wilkins, 2004, pp69-89
3. Eleraky MA, Llanos C, Sonntag VK : Cervical corpectomy : report of 185 cases and review of the literature. *J Neurosurg* 90 : 35-41, 1999
4. Jones WG 2nd, Ginsberg RJ : Esophageal perforation : a continuing challenge. *Ann Thorac Surg* 53 : 534-543, 1992
5. Knaub MA, Herkowitz HN : Anterior Approach for Cervical Myelopathy, in Herkowitz HN, Garfin SR, Eismont FJ, Bell GR, Balderston RA (eds) : *Rothman-Simeone The Spine*, ed 5. Philadelphia : Saunders Elsevier, 2006, Vol 2, pp847-863
6. Konstantakos AK, Temes RT : Delayed esophageal perforation : a complication of anterior cervical spine fixation. *Ann Thorac Surg* 80 : 349, 2005
7. Leibrock LG, Berman BM : Modification of Cloward cervical retractor. Technical note. *J Neurosurg* 61 : 193-194, 1984
8. Newhouse KE, Lindsey RW, Clark CR, Lieponis J, Murphy MJ : Esophageal perforation following anterior cervical spine surgery. *Spine (Phila Pa)* 14 : 1051-1053, 1989
9. Nourbakhsh A, Garges KJ : Esophageal perforation with a locking screw : a case report and review of the literature. *Spine (Phila Pa)* 32 : E428-E435, 2007
10. Park JS, Kim YB, Hong HJ, Hwang SN : Esophageal injury following anterior cervical plate fixation. *J Korean Neurosurg Soc* 37 : 151-145, 2005
11. Patel NP, Wolcott WP, Johnson JP, Cambron H, Lewin M, McBride D, et al. : Esophageal injury associated with anterior cervical spine surgery. *Surg Neurol* 69 : 20-24; discussion 24, 2008
12. Reid RR, Dutra J, Conley DB, Ondra SL, Dumanian GA : Improved repair of cervical esophageal fistula complicating anterior spinal fusion : free omental flap compared with pectoralis major flap. Report of four cases. *J Neurosurg* 100 : 66-70, 2004
13. Tew JM Jr, Mayfield FH : Complications of surgery of the anterior cervical spine. *Clin Neurosurg* 23 : 424-434, 1976
14. Torrens M : Anterior cervical decompression and fusion technique, in

- Torrens M, Dickson RA (eds) : **Operative Spinal Surgery**. Philadelphia : W.B. Sanders, 1991, pp31-50
15. Tortolani PJ, Cunningham BW, Vigna F, Hu N, Zorn CM, McAfee PC : A comparison of retraction pressure during anterior cervical plate surgery and cervical disc replacement : a cadaveric study. **J Spinal Disord Tech** 19 : 312-317, 2006
16. Uppaluri R, Sunwoo JB : Neoplasms of the hypopharynx and cervical esophagus, in Cummings CW (ed) : **Otolaryngology Head & Neck Surgery**, ed 4. Philadelphia : Elsevier, 2005, Vol 2, pp 1899-1931
17. Young PH : Operative Anatomy and Basic Microsurgical Approaches to the Cervical Spine, in Young PH (ed) : **Microsurgery of the Cervical Spine**. New York : Raven Press, 1991, pp17-30