

## Effects of conventional and modified facemask therapies on dentofacial structures

Ahmet Yagci, DDS, PhD,<sup>a</sup> Tancan Uysal, DDS, PhD<sup>b</sup>

**Objective:** The purpose of this prospective study was to evaluate the dentofacial effects of conventional and modified facemask therapies with rapid maxillary expansion, in a group of Class III patients; and compared with an untreated control group. **Methods:** The conventional facemask group (Group 1) comprised of 24 patients, 13 girls and 11 boys (mean age,  $9.2 \pm 1.4$  years); the modified facemask treatment group (Group 2) comprised of 24 patients, 12 girls and 12 boys (mean age,  $9.3 \pm 1.6$  years); and the control group (Group 3) comprised of 21 subjects, 11 girls and 10 boys (mean age,  $9.8 \pm 1.9$  years). Treatment and control changes within the groups and the differences between the groups were analyzed statistically. Intra-group comparisons were evaluated using the non-parametric Wilcoxon's test and intergroup changes were analyzed using the Kruskal-Wallis test. The statistical significance of intergroup differences was further assessed with the Mann-Whitney test for independent samples and applying Bonferroni's correction ( $p < 0.016$ ). **Results:** In group 1, SNB changes were less than the control. There were increases in SNA, ANB, SN-MP, A to N perp and Upper lip to E plane. In group 2, SNB, U1-NA (mm) U1-NA ( $^{\circ}$ ) and Pog to N perp (mm) changes were less than the control. There were increases in SNA, ANB, SN-MP, A to N perp and Upper lip to E plane. **Conclusions:** Modified facemask appliance can be used effectively in Class III patients with a retrognathic maxilla. Facemask therapies with expansion resulted in an anterior advancement and translation of maxilla without rotation; and the mandible moved downward and backward in both treatment groups. (*Korean J Orthod* 2010;40(6):432-443)

**Key words:** Malocclusion, Angle Class III, Extraoral traction appliances, Palatal expansion technique, Cephalometry

### INTRODUCTION

The skeletal Class III malocclusion can be originated from mandibular prognathism, maxillary retro-

gnathism, or both.<sup>1,2</sup> In most cases, Class III malocclusions are characterized by an average of a 60% maxillary deficiency.<sup>2,3</sup> Protraction of the maxilla with a facemask is a common treatment procedure for Class III patients, with maxillary retrusion.

The use of the protraction facemask provides a directed, constant anterior force to the maxilla. With the application of constant protraction forces, several animal studies have shown significant anterior displacement of the maxillary structures, accompanied by histological changes in the circum-maxillary sutures.<sup>4,5</sup> In addition, clinical studies indicate that the orthopedic approach is practicable for craniofacial deformities.

Studies have documented that facemask treatment before adolescence produces an orthopedic effect to

<sup>a</sup>Research Assistant, Department of Orthodontics, Faculty of Dentistry, Erciyes University, Kayseri, Turkey.

<sup>b</sup>Associate Professor and Chair, Department of Orthodontics, Faculty of Dentistry, Erciyes University, Kayseri, Turkey and Visiting Professor, King Saud University, Riyadh, Saudi Arabia.

Corresponding author: **Ahmet Yagci**.

Department of Orthodontics, Faculty of Dentistry, Erciyes University, Kayseri, Turkey.

+903524374937; e-mail, dtahmetyagci@hotmail.com.

Received June 1, 2010; Last Revision August 24, 2010; Accepted August 27, 2010.

DOI:10.4041/kjod.2010.40.6.432 / pISSN 1225-5610

place the maxilla in a forward position, often accompanied by a clockwise rotation of the mandible and counter-clockwise rotation of the maxilla, together with dental changes.<sup>6</sup> Counter-clockwise rotation of the maxilla is beneficial in the treatment of low-angle, deep-bite Class III patients; but it has undesired effects in Class III cases with high-angle skeletal patterns and anterior open bites.<sup>6</sup> In order to eliminate these undesired side effects, some investigators have applied the protraction force at an angle of 20 - 30° downward from the occlusal plane<sup>7,8</sup> but others have applied the force buccally in the molar, premolar, canine, and lateral incisor regions.<sup>8-10</sup>

Hata et al.<sup>11</sup> found that applying the force from a point 5 mm above the palatal plane (PP) resulted in elimination of the counter-clockwise rotation effect on the maxilla. Nanda<sup>12</sup> had developed a modified protraction headgear design to deliver the protraction forces from a higher level. Alcan et al.<sup>13</sup> introduced the modified maxillary protraction facemask where they applied the point of force up to the level of the forehead. Keles et al.<sup>6</sup> examined the effect of varying force directions on maxillary protraction by modified facemask appliance and found that this method can be used effectively on patients who represent Class III malocclusion combined with anterior open bite. Göyenci and Ersoy<sup>14</sup> evaluated the effects of modified facemask therapy on dentofacial structures. They concluded that, applying the force with modified facemask by means of a facebow induced anterior movement of the maxilla without rotation of the jaws and upper and lower maxillary heights were unaffected.

To our knowledge there is no research in the literature that compared the effects of conventional and modified facemask appliances; and evaluated with a control group all in one study. The purpose of this prospective study was to evaluate the dentofacial effects of conventional and modified facemask therapies with rapid maxillary expansion, in Class III patients; and compared with an untreated control. For group 1, the protraction force was applied intraorally from the lateral region, in group 2 the protraction force was applied with a modified facebow extraorally from a higher level and group 3 consisted of control subjects.

## MATERIAL AND METHODS

This study was approved by the Regional Ethical Committee on Research of the Erciyes University, Faculty of Dentistry.

A power analysis established by G\*Power Ver. 3.0.10. (Franz Faul, Universität Kiel, Germany) software, based on a 1 : 1 ratio between groups, showed that a sample size of 21 patients would give more than 80% power to detect significant differences with 0.40 effect size and at  $\alpha = 0.05$  significance level.

The samples consisted of cephalometric records of 72 Class III patients with maxillary retrusion. Patients who fulfilled the following inclusion criteria were selected:

- Class III molar relationship
- Anterior crossbite or edge-to-edge incisal relationship
- ANB angle of 0° or less; and nasion perpendicular to A-point of 2 mm or less
- No congenitally missing or extracted teeth
- No deformity in the nasomaxillary complex
- Cephalometric radiographs of adequate quality available before and at the end of facemask-expansion therapy.

Patients with craniofacial abnormality, psychosocial impairment, craniofacial anomaly or skeletal openbite (at least a 1 mm opening when the incisal edges of the maxillary and mandibular incisors were projected perpendicularly onto the N-Me plane) were excluded from the study.

Sixty-nine (36 girls and 33 boys) out of the 72 subjects who met the inclusionary criteria were randomly selected, and 3 patients were discarded because of psychosocial impairment, craniofacial anomaly and insufficient cooperation. Conventional facemask treatment group (Group 1) comprised of 24 patients, 13 girls and 11 boys (mean age, 9.2 ± 1.4 years); modified facemask treatment group (Group 2) comprised of 24 patients, 12 girls and 12 boys (mean age, 9.3 ± 1.6 years); and control group (Group 3) comprised of 21 subjects, 11 girls and 10 boys (mean age, 9.8 ± 1.9 years).

Cephalometric records were obtained from all sub-

jects at pre- and post-treatment for the experimental group, and during the control period for the control group. Treatment time in Group 1 ranged between 0.5 and 1.7 years (mean  $1.09 \pm 0.28$  years); treatment time in Group 2 ranged between 0.7 and 1.8 years (mean  $1.2 \pm 0.3$  years); and the observation period ranged between 0.5 and 1.7 years (mean  $0.91 \pm 0.36$  years).

To constitute the control group, cephalometric records were taken with parental permissions by obtaining informed consent from subjects/parents; who did not accept treatment by an extraoral appliance, at that time. Then most of these subjects accepted the treatment protocol.

#### Appliance design in group 1

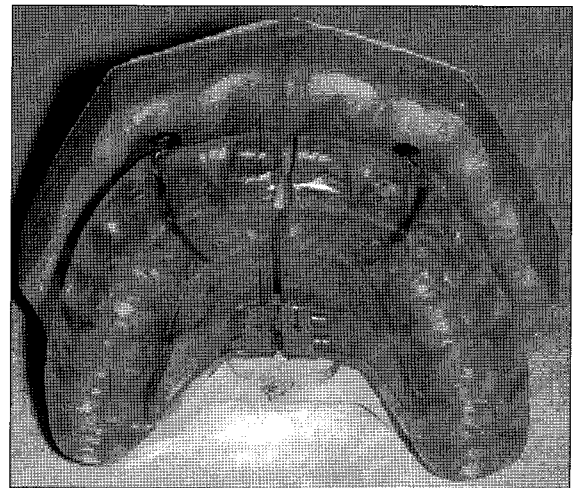
In this group, a facemask,<sup>15</sup> and a bonded full coverage maxillary acrylic splint expander with vestibular hooks, and heavy elastics (500 g, depends on the distance between the hooks of expansion appliance and the facemask) were used for orthopedic facemask therapy.<sup>8</sup>

Elastics were connected bilaterally to an adjustable midline crossbow on the Petit type facemask.<sup>15</sup> The protraction elastics were applied to the vestibular hooks attached between the lateral incisor and canine teeth 10 - 15 mm above the maxillary occlusal plane

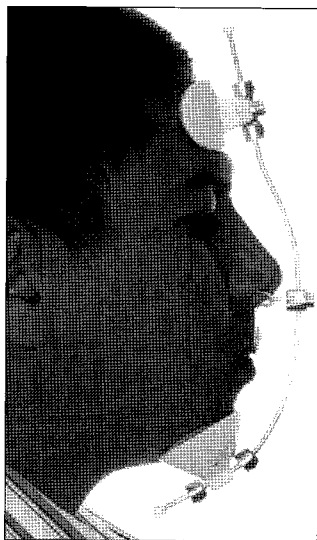(Fig 1); with a downward and forward pull of 20° to avoid bite opening during maxillary protraction (Fig 2).

#### Appliance design in group 2

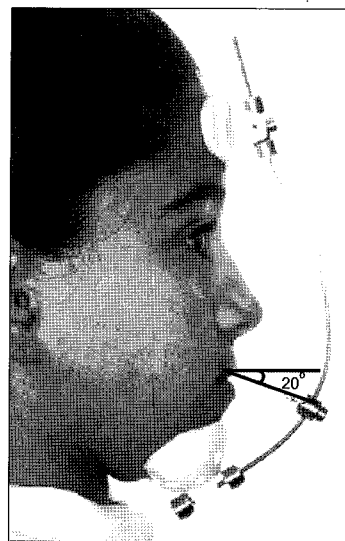
A modified bonded rapid maxillary expansion appliance with full occlusal coverage, a specially designed facebow, a facemask and heavy elastics (500 g, depends on the distance between the modified facebow



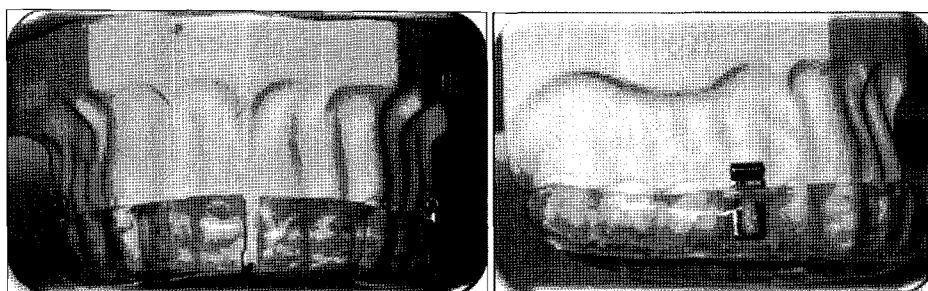
**Fig 2.** Conventional facemask appliance. Downward and forward pull of 20° from the occlusal plane was applied.



**Fig 1.** Force application unit of conventional facemask appliance.



**Fig 3.** Force application unit of modified facemask appliance.



**Fig 4.** Modified facemask appliance. The point of force was applied at the level of the dentomaxillary center of resistance.

**Table 1.** Cephalometric measurements used in the present study

*Skeletal angular and linear measurements*

- SNA angle (SNA): inward angle toward the cranium between the NA line and the sella-nasion (SN) plane
- SNB angle (SNB): inward angle toward the cranium between the NB line and the SN plane
- ANB angle (ANB): angle between the NA and NB lines, obtained by subtracting SNB from SNA
- SN plane to mandibular plane angle (SN-MP): angle between the SN plane and the mandibular plane (MP)
- SN plane to palatal plane angle (SN-PP): angle between the SN plane and the palatal plane (PP)
- A point to nasion perpendicular (A to N perp): distance between A point and N perpendicular line measured perpendicular to N perpendicular line
- Pogonion to N perpendicular (Pog to N perp): distance between pogonion and N perpendicular line measured from the perpendicular to N perpendicular line
- Me point to nasion (N-Me): Total anterior facial height
- ANS to nasion (N-ANS): Upper anterior facial height
- Me point to ANS (ANS-Me): Lower anterior facial height

*Dental angular and linear measurements*

- Maxillary central incisor to mandibular central incisor (U1-L1) (interincisal angle): angle is measured between the extension of the maxillary and mandibular incisor long axis line; the most posterior angle is measured
- Maxillary incisor to NA plane (U1-NA): distance between the tip of the upper incisor and a line from N to point A
- Maxillary incisor-NA angle (U1-NA): angle formed by the long axis of the upper incisor to a line from N to point A
- Maxillary incisor-PP angle (U1-PP): angle formed by the long axis of the upper incisor to palatal plane
- Mandibular incisor to NB (L1-NB): distance between the tip of the mandibular incisor and a line from nasion to point B
- Mandibular incisor-NB angle (L1-NB): angle formed by the long axis of the mandibular incisor to a line from N to Point B
- Mandibular incisor-MP angle (L1-MP): angle formed by the long axis of the mandibular incisor to mandibular plane

*Soft tissue angular and linear measurements*

- Nasolabial angle (Prn-Sn-Upper lip): angle formed by the labial surface of the upper lip to a line from Subnasale to tip of nose
- Upper lip to E plane: distance between the upper lip and a line from the tip of the nose to the end of the chin
- Lower lip to E plane: distance between the lower lip and a line from the tip of the nose to the end of the chin

hook parts and the facemask) were used for orthopedic facemask therapy.

The bonded expansion appliance was modified by adding two tubes (Activator Tubes, Dentaureum, Ispringen, Germany) on the buccal side of the acrylic in the premolar area (Fig 3). The purpose of these tubes was to accommodate the inner bows of the specially designed face bow. The facebow was constructed from an adjustable facebow (Std Ss Facebow, G&H Wire Company, Franklin, Indiana, USA). The inner bows of the facebow end in the mouth with a special U-shaped bend in order to enter the buccal tubes from the distal, and thus be able to retain it, when an anterior pull is applied. The outer bow was bent upwards at a 90 degree angle to provide a point of force application at the level of the dentomaxillary center of resistance, and also to apply the parallel forces on both sides (Fig 4).

In both treatment groups, the midline expansion screw of the bonded maxillary expander was activated two times a day for the first week and once a day until the desired change in the transverse dimension was achieved. Patients were instructed to wear the facemask full-time except during meals. We told patients to keep track of his/her wearing time on the scorecard and to bring his/her card to each visit. The appliance was used in both treatment groups until a positive overjet was accomplished.

#### Cephalometric analysis

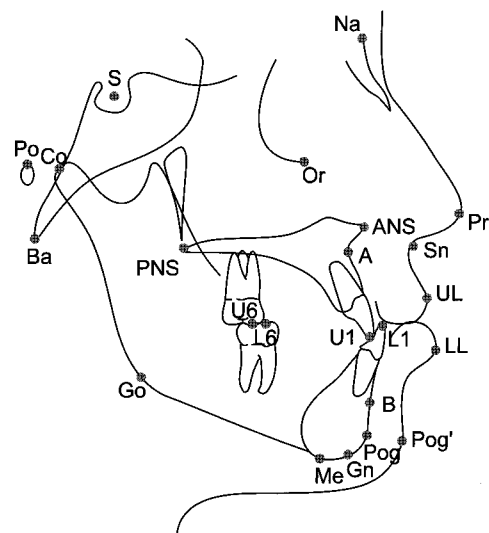
All of the cephalometric films used in this study were taken in the same cephalostat (Planmeca; Planmeca OY, Helsinki, Finland). All subjects were positioned in the cephalostat with the sagittal plane at a right angle to the path of the X-ray, the Frankfort plane was parallel to the horizontal, the teeth were in centric occlusion, and the lips were lightly closed.<sup>16</sup> All hard and soft tissue landmarks were digitized and measured with Dolphin Image Software, Version 11.0 (Dolphin Imaging and Management Solutions, Los Angeles, California, USA). Twenty measurements, (9 linear and 11 angular) were used to evaluate the changes in treatment and control groups. The landmarks were identified according to the definitions provided by Swlerenga et

al.<sup>17</sup> and presented in Table 1. Landmarks used in this study are shown in Fig 5.

#### Statistical analysis

All statistical analyses were performed using the Statistical Package for Social Sciences, version 13.0 for Windows (SPSS Inc., Chicago, IL, USA). Arithmetic mean and standard deviation values were calculated for all cephalometric measurements. The normality test of Shapiro-Wilks and Levene's variance homogeneity test were applied to the data. The data were found not normally distributed, and there was no homogeneity of variance between the groups. Intra- group comparisons were evaluated by using non-parametric Wilcoxon's test and intergroup changes were analyzed with Kruskal-Wallis test. The statistical significance of intergroup differences was further assessed with the Mann-Whitney test for independent samples with Bonferroni's correction ( $p < 0.016$ ).

To determine the errors associated with radiographic measurements, 10 radiographs were selected randomly. Their tracings were repeated 8 weeks after the first measurement. A Bland and Altman plot was applied to assess the repeatability. It was found that the difference between the first and second measurements were insignificant (Table 2).



**Fig 5.** Cephalometric landmarks used in the present study.

**Table 2.** Bland and Altman Plot to assess the repeatability

Measurements	Correlation	Bias	95% CI	SE	SD of differences
SNA (degree)	-0.23	0.30	-0.50 to 1.00	0.34	1.10
SNB (degree)	0.18	-0.10	-0.50 to 0.30	0.18	0.60
ANB (degree)	0.63	0.30	-0.20 to 0.90	0.25	0.80
SN-MP (degree)	-0.35	0.40	-0.50 to 1.30	0.40	1.30
SN-PP (degree)	-0.41	0.10	-0.60 to 0.90	0.33	1.00
A to N perp (mm)	-0.56	0.40	-0.30 to 1.10	0.30	0.90
Pg-Na Perp (mm)	-0.48	0.20	-0.10 to 0.50	0.13	0.40
N-Me (mm)	0.20	-0.80	-2.60 to 1.00	0.78	2.50
N-ANS (mm)	-0.22	0.12	-0.40 to 0.60	0.22	0.72
ANS-Me (mm)	0.10	0.33	0.40 to 1.00	0.32	1.01
Interincisal angle (degree)	-0.17	-1.40	-3.50 to 0.80	0.93	2.90
U1-NA (mm)	-0.52	-0.70	-1.80 to 0.50	0.53	1.70
U1-NA (degree)	-0.08	0.10	-1.00 to 1.30	0.52	1.70
U1-PP (degree)	0.06	0.50	-0.60 to 1.60	0.50	1.60
L1-NB (mm)	0.47	0.10	-0.30 to 0.50	0.19	0.60
L1-NB (degree)	-0.05	0.90	-0.90 to 2.60	0.77	2.40
L1-MP (degree)	0.41	0.70	-1.60 to 2.90	0.99	3.10
Nasolabial angle (degree)	0.30	1.50	0.30 to 2.70	0.51	1.60
Upper lip to E plane (mm)	0.40	1.26	-0.10 to 2.60	0.62	1.90
Lower lip to E plane (mm)	-0.14	0.45	-0.50 to 1.40	0.44	1.41

SE, Standard error; SD, standard deviation.

**RESULTS**

Pre-treatment/control values and standard deviations of measurements and statistical comparisons are presented in Table 3. Pre- and post-treatment/control descriptive statistical values and comparisons are presented in Table 4.

Pre- and post-treatment and pre- and post-control intra-group comparisons

In group 1, post-treatment measurements showed statistical changes in Pog to N perp ( $p < 0.05$ ); SN-MP ( $p < 0.01$ ); and SNA, ANB, A to N perp, N-Me, ANS-Me, and Upper lip to E plane ( $p < 0.001$ ).

In group 2, post-treatment measurements showed significant differences in U1-NA (mm), U1-NA ( $^{\circ}$ ) and

L1-MP ( $^{\circ}$ ) ( $p < 0.05$ ); A to N perp and Upper lip to E plane ( $p < 0.01$ ); and SNA, SNB, ANB, SN-MP, Pog to N perp, N-Me, ANS-Me, interincisal angle, L1-NB (mm), L1-NB ( $^{\circ}$ ), and Lower lip to E plane ( $p < 0.001$ ).

In group 3, post-control measurements showed increases in SNA, N-Me, N-ANS, U1-PP ( $p < 0.05$ ) and SNB measurements ( $p < 0.01$ ).

Treatment and control changes between group comparisons

In group 1, SNB changes were less than the control and this changes were statistically significant ( $p < 0.05$ ). There were increases in SNA, ANB, SN-MP, ( $p < 0.001$ ) and A to N perp and Upper lip to E plane ( $p < 0.01$ ).

In group 2, SNB, U1-NA ( $^{\circ}$ ) ( $p < 0.05$ ) and

**Table 3.** Pre-treatment/control values and standard deviations of measurements and statistical comparisons

Measurements	Group 1 Pre-treatment (T1)		Group 2 Pre-treatment (T1)		Group 3 Pre-control (T1)		p
	Mean	SD	Mean	SD	Mean	SD	
1 SNA (degree)	77.5	1.4	77.2	2	78.0	2.0	NS
2 SNB (degree)	79.6	2.4	80.3	2.5	79.8	2.4	NS
3 ANB (degree)	-2.1	1.4	-3.3	2.2	-1.9	1.7	NS
4 SN-MP (degree)	35.6	2.5	34.3	3.4	34.9	2.3	NS
5 SN-PP (degree)	9.7	3.7	8.9	3.3	9.4	3.3	NS
6 A to N perp (mm)	-2.7	1.5	-3.3	2.5	-1.9	1.9	*
7 Pg-Na Perp (mm)	-1.1	3.5	-0.8	4.4	-0.2	4.0	NS
8 N-Me (mm)	102.1	7.2	100.9	6.3	103.1	7.0	NS
9 N-ANS (mm)	45.9	3.5	44.9	3.6	46.1	3.7	NS
10 ANS-Me (mm)	57.3	5.2	55.4	4.0	57.8	4.7	NS
11 Interincisal angle	132.8	10.2	137.1	11.9	136.3	9.8	NS
12 U1-NA (mm)	3.3	1.8	4.0	2.3	2.9	2.5	NS
13 U1-NA (degree)	24.3	6.3	26.3	7.1	23.9	8.7	NS
14 U1-PP (degree)	111.2	7.0	112.3	7.3	111.3	9.1	NS
15 L1-NB (mm)	3.5	1.4	2.2	1.2	2.9	1.4	*
16 L1-NB (degree)	25.0	5.6	19.7	6.7	21.7	6.2	*
17 L1-MP (degree)	90.2	6.3	85.7	7.1	87.0	7.1	NS
18 Nasolabial angle	111.2	11.5	108.5	9.6	108.2	12.8	NS
19 UL to E plane	-3.5	1.8	-4.0	2.2	-4.1	2.3	NS
20 LL to E plane	0.6	2.1	0.0	2.1	-0.1	2.5	NS

SD, Standard deviation; NS, not significant. \* $p < 0.05$ .

U1-NA (mm) and Pog to N perp (mm) ( $p < 0.01$ ) changes were less than the control. There were increases in SNA, SN-MP ( $p < 0.01$ ) and ANB, A to N perp and Upper lip to E plane ( $p < 0.001$ ).

When both treatment groups were compared, no statistically significant differences were found in any of the measurements.

## DISCUSSION

To our knowledge, the present study is the first to evaluate and demonstrate the effects of a modified facemask (protraction force applied with a modified facebow extraorally); and to compare it with the conventional facemask and an untreated control group, all in one study. In this study, both treatment groups

showed that the SN-PP angle did not change and the maxilla showed no rotation while moving forward.

The average age of patients that were selected for the study group was 9.43 years. A review of the literature reveals that greater skeletal changes with the use of the maxillary protraction appliance are possible in young patients.<sup>18,19</sup> Treatment in the deciduous dentition produces greater skeletal changes than those produced in the mixed dentition stage;<sup>20</sup> moreover, when therapy begins in the early mixed dentition, it seems to induce more favorable changes in the craniofacial skeleton, compared with the same treatment started in the late mixed dentition.<sup>21</sup> However, Baik<sup>22</sup> reported that comparison of the measurements of the treatment effect according to age showed no statistically significant difference. Similarly, Yüksel et al.<sup>23</sup> compared the

treatment outcomes in two different chronological age groups and found no significant difference in the orthodontic and orthopedic effects. According to, Merwin et al.<sup>24</sup> there was no difference between the age groups 5 to 8 and 8 to 12 years from the point of protraction of the maxilla.

Proffit and Fields<sup>25</sup> claimed that rapid maxillary expansion (RME) had to be carried out, before protraction of the maxilla. There are other studies<sup>12,26</sup> in the literature that support the concept that, RME treatment releases maxilla's sutures with the surrounding bones and enhances the protraction procedure. In the present concept, treatment was started in the seventh day of RME in both treatment groups after mobilizing

the sutures surrounding the maxilla.

During the protraction procedure, rigid appliances are needed to withstand the heavy forces.<sup>13</sup> For this purpose some investigators have used rigid wires,<sup>27</sup> whereas others used an acrylic cap splint.<sup>26</sup> Previous investigations<sup>8</sup> showed that the application of cap splint type maxillary expansion appliances would increase the skeletal effect of the protraction headgear. In the current study, a full coverage maxillary acrylic splint expander appliance was used in both treatment groups, in order to increase the rigidity of the appliance, to prevent the occlusal interferences, to apply homogeneous force, and to maximize the skeletal effect of the protraction headgear.

**Table 4.** Pre- and post-treatment, pre- and post-control values and standard deviations of measurements and statistical comparisons

Measurements	Group 1				Wilcoxon <i>p</i> value	Group 2				Wilcoxon <i>p</i> value
	Pre-treatment (T1)		Post-treatment (T2)			Pre-treatment (T1)		Post-treatment (T2)		
	Mean	SD	Mean	SD		Mean	SD	Mean	SD	
SNA (°)	77.5	1.4	81.4	3.9	0.000	77.2	2.0	81.0	3.4	0.000
SNB (°)	79.6	2.4	77.8	4.3	NS	80.3	2.5	78.4	2.8	0.001
ANB (°)	-2.1	1.4	3.6	1.8	0.000	-3.3	2.2	3.4	2.1	0.000
SN-MP (°)	35.6	2.5	39.8	6.2	0.007	34.3	3.4	38.1	5.0	0.000
SN-PP (°)	9.7	3.7	8.7	3.8	NS	8.9	3.3	7.3	2.9	NS
A to N Perp (mm)	-2.7	1.5	0.5	3.2	0.001	-3.3	2.5	-0.4	3.9	0.001
Pog-N Perp (mm)	-1.1	3.5	-5.0	5.0	0.031	-0.8	4.4	-5.6	5.2	0.000
N-Me (mm)	102.1	7.2	109.2	6.8	0.001	100.9	6.3	105.8	6.7	0.000
N-ANS (mm)	45.9	3.5	47.6	2.2	NS	44.9	3.6	44.3	3.2	NS
ANS-Me (mm)	57.3	5.2	63.1	5.4	0.000	55.4	4.0	60.7	4.3	0.000
Interincisal angle (°)	132.8	10.2	130.4	9.4	NS	137.1	11.9	131.1	9.7	0.000
U1-NA (mm)	3.3	1.8	2.7	1.7	NS	4.0	2.3	2.7	2.1	0.015
U1-NA (°)	24.3	6.3	21.9	6.2	NS	26.3	7.1	22.5	7.0	0.008
U1-PP (°)	111.2	7.0	111.1	6.0	NS	112.3	7.3	111.2	6.6	NS
L1-NB (mm)	3.5	1.4	4.2	1.9	NS	2.2	1.2	3.4	1.9	0.000
L1-NB (°)	25.0	5.6	24.8	7.2	NS	19.7	6.7	24.2	6.1	0.000
L1-MP (°)	90.2	6.3	87.4	8.2	NS	85.7	7.1	87.9	7.3	0.021
Nasolabial angle (°)	111.2	11.5	110.5	11.4	NS	108.5	9.6	108.2	9.5	NS
UL to E plane (mm)	-3.5	1.8	-1.2	2.1	0.001	-4.0	2.2	1.3	2.3	0.001
LL to E plane (mm)	0.6	2.1	1.3	2.3	NS	0.0	2.1	-0.8	2.4	0.000



Table 4. Continued

Measurements	Group 3					Post-Hoc Test		
	Pre-control (1D)		Post-control (1P)		Wilcoxon p value	p value		
	Mean	SD	Mean	SD		(1-2)	(1-3)	(2-3)
SNA (°)	78.0	2.0	78.7	2.2	0.041	NS	0.000	0.001
SNB (°)	79.8	2.4	80.9	2.8	0.004	NS	0.016	0.005
ANB (°)	-1.9	1.7	-2.2	2.0	NS	NS	0.000	0.000
SN-MP (°)	34.9	2.3	34.1	2.5	NS	NS	0.000	0.001
SN-PP (°)	9.4	3.3	8.9	3.1	NS	NS	NS	NS
A to N Perp (mm)	-1.9	1.9	-2.4	2.6	NS	NS	0.001	0.000
Pog-N Perp (mm)	-0.2	4.0	-0.7	5.8	NS	NS	NS	0.006
N-Me (mm)	103.1	7.0	106.3	7.3	0.007	NS	NS	NS
N-ANS (mm)	46.1	3.7	47.7	3.6	0.032	NS	NS	NS
ANS-Me (mm)	57.8	4.7	59.2	5.0	NS	NS	NS	NS
Interincisal angle (°)	136.3	9.8	133.3	8.3	NS	NS	NS	NS
U1-NA (mm)	2.9	2.5	3.7	2.7	NS	NS	NS	0.007
U1-NA (°)	23.9	8.7	26.6	7.9	NS	NS	NS	0.013
U1-PP (°)	111.3	9.1	114.2	8.3	NS	NS	NS	NS
L1-NB (mm)	2.9	1.4	3.1	1.5	NS	NS	NS	NS
L1-NB (°)	21.7	6.2	22.3	5.8	NS	NS	NS	NS
L1-MP (°)	87.0	7.1	87.4	6.0	NS	NS	NS	NS
Nasolabial angle (°)	108.2	12.8	110.5	11.2	NS	NS	NS	NS
UL to E plane (mm)	-4.1	2.3	-3.9	1.3	NS	NS	0.002	0.000
LL to E plane (mm)	-0.1	2.5	-0.2	2.1	NS	NS	NS	NS

SD, Standard deviation; NS, not significant.

Class III malocclusions could have beneficial effects from early orthopedic intervention, but cases should be selected carefully. The facial growth pattern, age, heredity and amount of pretreatment overbite and overjet are factors to be considered for prognosis and also for prevention of relapse.<sup>28</sup> For that reason, patients presenting normally directed vertical growth patterns with normal overbite were included but patients with craniofacial anomaly, psychosocial impairment, or skeletal openbite were excluded from the study.

Conventional and modified facemasks have different biomechanical properties. In the conventional facemask group, force was applied below from the center of resistance of the maxillary dentition. On the other hand, in the modified facemask group, force was applied

from the maxillary incisor root apex area. As a consequence, the maxillary incisor teeth were retroclined.

Both treatment groups demonstrated significant responses to facemask/expansion therapies, which affect many areas of the dentofacial complex, when compared to the control group. Skeletal change was primarily a result of an anterior movement of the maxilla. When the treatment groups' maxillary change was compared to the control, the results confirmed a maxillary orthopedic effect resulting from treatment (change in SNA: Group 1, 3.9°; Group 2, 3.8°; Group 3, 0.7°; change in A to N perp: Group 1, 3.2 mm; Group 2, 2.9 mm; Group 3, -0.50 mm). Ishii et al.<sup>10</sup> and Mermigos et al.<sup>7</sup> have reported similar findings for maxillary movement.

Many investigators have stated that facemasks worsened the vertical growth pattern in Class III cases characterized by maxillary retrognathism and an openbite tendency.<sup>24</sup> The reason for this was the counter-clockwise rotation of the maxilla that occurred in patients treated with facemask therapy.<sup>6</sup> Frequently counter-clockwise rotation of the maxilla brought aggravation in the vertical dimension. Authors<sup>10,18</sup> observed significant rotation of the palatal plane with conventional facemask appliance. Palatal plane rotation was not observed in the present study for both treatment groups. The rotation of the palatal plane described in other studies may be affected by many factors, including site of force application, direction of elastic traction, as well as the facial pattern of the patient. Hata et al.<sup>11</sup> studied the effects of changing the level of force application on the maxilla during protraction procedures. Studies were carried out on dried skulls and facemasks were used while applying the force from different levels. The researchers found that applying the force from 10 mm above the palatal plane resulted in elimination of the counter-clockwise rotation effect on the maxilla.<sup>11</sup> All patients in Group 1 were treated with elastic traction attached in the area of the lateral incisor hook which is 10 - 15 mm above the maxillary occlusal plane, with the direction of pull predominately downward (20°) from the horizontal. In group 1, as a consequence of this procedure, the maxilla moved anteriorly without rotation. In group 2, patients were treated with the modified facemask and this allowed the point of force application to be provided at the level of the dentomaxillary center of resistance. Keles et al.<sup>6</sup> and Göyenc and Ersoy<sup>14</sup> investigated similarly designed modified facebow effects and they stated that anterior translation of the maxilla without rotation had occurred. The results for group 2 from the present study were similar to these research.

Clockwise rotation of the mandible is ideally suited for patients with excessive overbite and vertical maxillary deficiency. It should be noted, however, that the subjects in this study did not demonstrate severe vertical growth patterns and an openbite tendency. Significant changes in the mandibular position also contributed to the Class III correction. Downward and backward movement of the mandible that was shown

in both treatment groups was consistent with other investigators.<sup>10,18</sup> In contrast, Mermigos<sup>7</sup> who used maxillary protraction alone, reported that the mandibular plane remained unchanged. Mandibular rotation may be due to a combination of vertical maxillary movement, eruption of the maxillary molar, and a distalizing or retraction force on the chin.<sup>19</sup> Baccetti et al.<sup>21</sup> observed a backward positional rotation of the mandible associated with an increase in lower anterior facial height in Class III patients treated with the facemask. Consequently, a redirection of future mandibular growth in a more downward and backward vector could be expected after treatment due to extrusion of maxillary posterior teeth and downward growth of the maxilla.

Dental changes related to orthopedic protraction forces to the maxilla have been widely studied and maxillary incisor protrusion have been reported.<sup>18</sup> These researchers found maxillary counter-clockwise rotation; however, this rotation may reflect the maxillary incisor position. In group 1, the maxillary incisor position did not change with the treatment. However, in group 2, U1-NA measurements were increased, but U1-PP measurement was stable because of maxillary parallel anterior movement.

Macdonald et al.<sup>29</sup> stated mandibular incisors become upright after treatment whereas Ngan et al.<sup>30</sup> and Baik<sup>22</sup> reported a decrease in the inclination of the lower incisors. In both treatment groups, lower incisor inclination could not be changed with facemask therapy. Because facemasks have different biomechanical properties, lower incisor inclination was decreased in group 1 and was increased in group 2 but these changes were not statistically significant. Similarly Göyenc and Ersoy<sup>14</sup> used the modified protraction headgear and they did not report any changes in lower incisor position.

Significant correlations were found between changes in the sagittal relationships of the skeletal and soft tissue profiles in both the maxilla and mandible.<sup>1</sup> Kapust et al.<sup>19</sup> reported forward movement of the upper lip and retraction of the lower lip. In this study we determined that the upper lip moved forward; but lower lip position did not change during the therapy for both treatment groups.

Future studies are needed in order to examine the long-term stability of the skeletal and dental changes related to the maxilla and mandible.

## CONCLUSION

Modified facemask appliance can be used effectively in Class III patients with a retrognathic maxilla. Face-mask therapies with expansion resulted in an anterior advancement and translation of the maxilla without rotation and the mandible moved downward and backward in both treatment groups. Both treatment protocols have similar effects except for incisor positions.

- 국문초록 -

변형된 페이스 마스크의 치아 및 골격적 효과

Ahmet Yagci, Tancan Uysal

이번 연구의 목적은 기존의 페이스 마스크와 변형된 페이스 마스크의 치아 및 골격적 효과를 평가하고자 III급 부정교합환에서 치료군과 비치료군을 비교하였다. 24명의 환자(여자: 13명, 남자: 11)로 구성된 기존의 페이스 마스크 그룹(Group 1, mean age,  $9.2 \pm 1.4$  years)과 24명의 환자(여자: 12명, 남자: 12명)로 구성된 변형된 페이스 마스크(Group 2, mean age,  $9.3 \pm 1.6$  years); 그리고 21명(여자: 11명, 남자: 10명)으로 구성된 대조군 그룹(Group 3, mean age,  $9.8 \pm 1.9$  years)으로 분류하였다. 그룹 내 그룹 간에 치료군과 대조군을 통계학적으로 분석하였다. 그룹 내 비교는 비모수적인 방법의 Wilcoxon's test으로 그룹 간의 변화는 Kruskal-Wallis test를 이용하여 분석하였다. 이후 그룹 간의 통계적인 유효성 검증을 위하여 Mann-Whitney test와 Bonferroni's correction을 시행하였다 ( $p < 0.016$ ). Group 1에서 SNB 변화가 대조군보다 적었다. SNA, ANB, SN-MP, A to N perp과 Upper lip to E plane이 증가하였다. Group 2에서는 SNB, U1-NA (mm) U1-NA ( $^{\circ}$ ) and Pog to N perp (mm) 변화는 대조군보다 적었다. SNA, ANB, SN-MP, A to N perp과 Upper lip to E plane이 증가하였다. 변형된 페이스 마스크는 상악 열성장이 있는 III급 부정교합 환자에게 효과적으로 사용될 수 있다. 상악궁 확장을 동반한 페이스 마스크를 통하여 상악은 회전을 야기시키지 않고 전방으로 이동하였으며 모든 치료군에서 하악은 후하방으로 이동하였다.

주요 단어: 부정교합, Angle Class III, 구외 견인장치, 구개

확장장치, 측모두부방사선사진

## REFERENCES

1. Ngan P, Hägg U, Yiu C, Merwin D, Wei SH. Soft tissue and dentoskeletal profile changes associated with maxillary expansion and protraction headgear treatment. *Am J Orthod Dentofacial Orthop* 1996;109:38-49.
2. Guyer EC, Ellis EE 3rd, McNamara JA Jr, Behrents RG. Components of class III malocclusion in juveniles and adolescents. *Angle Orthod* 1986;56:7-30.
3. Ellis E 3rd, McNamara JA Jr. Components of adult Class III malocclusion. *J Oral Maxillofac Surg* 1984;42:295-305.
4. Jackson GW, Kokich VG, Shapiro PA. Experimental and post-experimental response to anteriorly directed extraoral force in young *Macaca nemestrina*. *Am J Orthod* 1979;75:318-33.
5. Kambara T. Dentofacial changes produced by extraoral forward force in the *Macaca irus*. *Am J Orthod* 1977;71:249-77.
6. Keles A, Tokmak EC, Erverdi N, Nanda R. Effect of varying the force direction on maxillary orthopedic protraction. *Angle Orthod* 2002;72:387-96.
7. Mermigos J, Full CA, Andreasen G. Protraction of the maxillofacial complex. *Am J Orthod Dentofacial Orthop* 1990;98:47-55.
8. McNamara JA Jr, Brudon WL. Orthodontic and orthopedic treatment in the mixed dentition. Ann Arbor, MI: Needham Press; 1993. p. 285-93.
9. Hickham JH. Maxillary protraction therapy: diagnosis and treatment. *J Clin Orthod* 1991;25:102-13.
10. Ishii H, Morita S, Takeuchi Y, Nakamura S. Treatment effect of combined maxillary protraction and chin cap appliance in severe skeletal Class III cases. *Am J Orthod Dentofacial Orthop* 1987;92:304-12.
11. Hata S, Itoh T, Nakagawa M, Kamogashira K, Ichikawa K, Matsumoto M, et al. Biomechanical effects of maxillary protraction on the craniofacial complex. *Am J Orthod Dentofacial Orthop* 1987;91:305-11.
12. Nanda R. Biomechanical and clinical considerations of a modified protraction headgear. *Am J Orthod* 1980;78:125-39.
13. Alcan T, Keles A, Erverdi N. The effects of a modified protraction headgear on maxilla. *Am J Orthod Dentofacial Orthop* 2000;117:27-38.
14. Göyenc Y, Ersoy S. The effect of a modified reverse headgear force applied with a facebow on the dentofacial structures. *Eur J Orthod* 2004;26:51-7.
15. Petit H. Adaptations following accelerated facial mask therapy. In: McNamara JA Jr, Ribbens KA, Howe RP, editors. Clinical alteration of the growing face. Monograph no. 14, Craniofacial growth series. Ann Arbor: Center for Human Growth and Development, University of Michigan; 1983. p. 48-59.
16. Erbay EF, Caniklioglu CM, Erbay SK. Soft tissue profile in Anatolian Turkish adults: Part I. Evaluation of horizontal lip position using different soft tissue analyses. *Am J Orthod Dentofacial Orthop* 2002;121:57-64.
17. Swlerenga D, Oesterle LJ, Messersmith ML. Cephalometric values for adult Mexican-Americans. *Am J Orthod Dentofacial Orthop* 1994;106:146-55.

18. Takada K, Petdachai S, Sakuda M. Changes in dentofacial morphology in skeletal Class III children treated by a modified maxillary protraction headgear and a chin cup: a longitudinal cephalometric appraisal. *Eur J Orthod* 1993;15:211-21.
19. Kapust AJ, Sinclair PM, Turley PK. Cephalometric effects of face mask/expansion therapy in Class III children: a comparison of three age groups. *Am J Orthod Dentofacial Orthop* 1998;113:204-12.
20. Kajiyama K, Murakami T, Suzuki A. Comparison of orthodontic and orthopedic effects of a modified maxillary protractor between deciduous and early mixed dentitions. *Am J Orthod Dentofacial Orthop* 2004;126:23-32.
21. Baccetti T, Franchi L, McNamara JA Jr. Treatment and post-treatment craniofacial changes after rapid maxillary expansion and facemask therapy. *Am J Orthod Dentofacial Orthop* 2000;118:404-13.
22. Baik HS. Clinical results of the maxillary protraction in Korean children. *Am J Orthod Dentofacial Orthop* 1995;108:583-92.
23. Yüksel S, Uçem TT, Keykubat A. Early and late facemask therapy. *Eur J Orthod* 2001;23:559-68.
24. Merwin D, Ngan P, Hagg U, Yiu C, Wei SH. Timing for effective application of anteriorly directed orthopedic force to the maxilla. *Am J Orthod Dentofacial Orthop* 1997;112:292-9.
25. Proffit WR, Fields HW. *Contemporary orthodontics*. St Louis: Mosby; 1993. p. 456-9.
26. Haas AJ. The treatment of maxillary deficiency by opening the midpalatal suture. *Angle Orthod* 1965;35:200-17.
27. Kiliçoğlu H, Kirişçi Y. Profile changes in patients with class III malocclusions after Delaire mask therapy. *Am J Orthod Dentofacial Orthop* 1998;113:453-62.
28. Battagel JM, Orton HS. Class III malocclusion: the post-retention findings following a non-extraction treatment approach. *Eur J Orthod* 1993;15:45-55.
29. Macdonald KE, Kapust AJ, Turley PK. Cephalometric changes after the correction of class III malocclusion with maxillary expansion/facemask therapy. *Am J Orthod Dentofacial Orthop* 1999;116:13-24.
30. Ngan P, Wei SH, Hagg U, Yiu CK, Merwin D, Stickel B. Effect of protraction headgear on Class III malocclusion. *Quintessence Int* 1992;23:197-207.