

Full mouth fixed implant rehabilitation in a patient with generalized aggressive periodontitis

Yoon-Hyuk Huh, MSD, Hyung-Joo Shin, MSD, Dae-Gon Kim, MSD, Chan-Jin Park, PhD, Lee-Ra Cho*, PhD

Department of Prosthodontics and Research Institute of Oral Science, College of Dentistry, Gangneung-Wonju National University, Gangneung, Korea

BACKGROUND. Generalized aggressive periodontitis (GAP) is a destructive periodontal disease that can develop in young age. Only a few cases of full mouth rehabilitation, using dental implants, have been reported in a patient with aggressive periodontitis. **CASE DESCRIPTION.** This clinical report describes the treatment procedures and results of full mouth rehabilitation in a patient with aggressive periodontitis. After all teeth were extracted, 6 implants were placed in the maxilla and mandible, respectively. Fixed detachable implant prostheses were made. The patient was satisfied with the final results. She was followed for 10 months postloading. **CLINICAL IMPLICATION.** For a long-term success, continuous maintenance care is critical, as the contributing factors of the disease (such as immune factors or periodontal pathogens) may not be controlled adequately. [J Adv Prosthodont 2010;2:154-9]

KEY WORDS. Dental implants, Fixed-detachable prosthesis, Full mouth rehabilitation, Generalized aggressive periodontitis

INTRODUCTION

Generalized aggressive periodontitis (GAP) is a subtype of chronic periodontitis that can occur in early age of one's life. It is an uncommon and destructive type of periodontal disease, and is characterized by rapid attachment loss and bone destruction.¹ Patients with GAP lose most of their teeth due to severe tooth mobility and bone loss. Causes of the GAP are not completely revealed. They frequently have elevated proportions of *Aggregatibacter actinomycetemcomitans*, and *Porphyromonas gingivalis*.² Moreover, the patients with GAP may have a problem in the host immune system or underlying systemic problem.³ In some cases of GAP patients, phagocyte abnormalities or hyper-responsive macrophage phenotype including elevated levels of prostaglandin E₂ and interleukin 1 β were found.² Hormonal changes during pregnancy can aggravate existing GAP.

Young GAP patients would have an experience of edentulism in very young age. In such cases, masticatory function, phonetics, and esthetics should be restored with implants. Treatment alternatives for the edentulous arch include: (1) fixed-detachable prostheses, (2) conventional implant-supported fixed partial dentures, (3) implant-retained overdentures, and (4) implant-supported overdentures.⁴ Each treatment option has its own advantages and disadvantages. Accurate diagnosis and

treatment planning is essential for successful treatment. Shape and quality of the residual bone and intermaxillary relationship should be considered in the diagnostic stage. Esthetics, phonetics, hygiene, as well as cost considerations will also help in selecting adequate treatment plan.

Full mouth rehabilitation using implants in periodontally healthy patients has been well documented.⁵ However, implant treatment in periodontitis-susceptible individuals is frequently debated. The periodontal pathogens may jeopardize the success of implant treatment in partially edentulous patient. The periodontal pathogens were believed to be eliminated with the extraction of all natural teeth. Therefore, in the past an edentulous patient who had a history of periodontitis was considered as a safe subject of implant installation. A recent research was conducted on bacterial floras of edentulous patients who were edentulous for at least 1 year. Periodontal pathogens such as *Actinomyces* species, and *Porphyromonas gingivalis* were observed in significant numbers in the edentulous subject.⁶ Therefore, careful implant installation and maintenance care are essential.

A few case reports were presented on the implant restoration in GAP patients.⁷⁻⁹ However, full mouth rehabilitation using implants in GAP patients have rarely been reported. This clinical report describes the comprehensive treatment sequence and result of a patient who lost all teeth due to GAP.

Corresponding author: Lee-Ra Cho

Department of Prosthodontics, College of Dentistry, Gangneung-Wonju National University 1, GangneungDaehangno, Gangneung, 210-702, Korea

Tel. 82 33 640 3153; e-mail, lila@gwnu.ac.kr

Received August 11, 2010 / Last Revision August 30, 2010 / Accepted October 5, 2010

© 2010 The Korean Academy of Prosthodontics

This is an Open Access article distributed under the terms of the Creative Commons Attribution Non-Commercial License (<http://creativecommons.org/licenses/by-nc/3.0>) which permits unrestricted non-commercial use, distribution, and reproduction in any medium, provided the original work is properly cited.

CLINICAL REPORT

A 37-year-old female patient came to the Department of Prosthodontics in the Gangneung-Wonju National University Dental Hospital complaining that "all the teeth in my mouth are moving." The patient reported that her mouth condition became worsened during her pregnant period 4 years ago. Clinical examination revealed the third degree of hypermobility on all the teeth excluding upper and lower right third molars (Fig. 1). A dental history was elicited that #13 - #21 with metal ceramic fixed prosthesis were severely extruded. Teeth #14 and #32 were extracted due to hypermobility and abscess formation. Her face had reverse triangular shape due to atrophy of masseter muscles. Residual root at #15 area and several diastema due to migration of teeth were noticed. Radiographic examination revealed generalized severe bone loss and periapical radiolucencies of several teeth (Fig. 2). Periodontal examina-

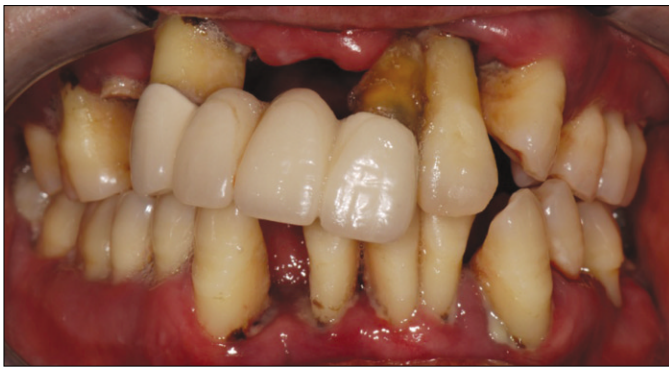

Fig. 1. Intraoral frontal view when the patient presented initially.

tion revealed poor oral hygiene. Subsequent discussion with the periodontist led to the diagnosis of aggressive generalized periodontitis. All her teeth were diagnosed as hopeless and planned to be extracted. The objectives of treatment were to motivate and educate the patient, improve oral hygiene, rehabilitate fully edentulous arches, and establish a stable and predictable outcome.

Several treatment options including complete denture and prosthesis using implants were provided. The patient chose the treatment modality of implant supported fixed prosthesis. Impressions were made with irreversible hydrocolloid impression material (Aromafine, GC Corp., Tokyo, Japan). Diagnostic casts were made and mounted in centric relation for evaluation of the vertical dimension. Provisional dentures were fabricated on the articulator. All teeth except right side third molars for maintaining the vertical dimension were extracted. During surgical procedure, alveoplasty was done. After placing the provisional dentures in the patient's mouth, vertical dimension and phonetics were clinically verified.

The patient was opposed to the proposal of complete denture treatment. A detailed discussion was held with the patient about the advantages and disadvantages of treatment options. To select an optimal treatment option for the patient, several aspects of patient's status should be considered (Table 1).¹⁰ This patient had Angle Class I relation and insufficient vertical space. However, she had insufficient bone volume and lip support to be restored with fixed prosthesis (Fig. 3). Therefore, fixed detachable prostheses for maxilla and mandible were planned.

The patient was satisfied with the provisional dentures, and radiographic stents were fabricated by duplicating the provisional dentures (Fig. 3). A panoramic radiography and

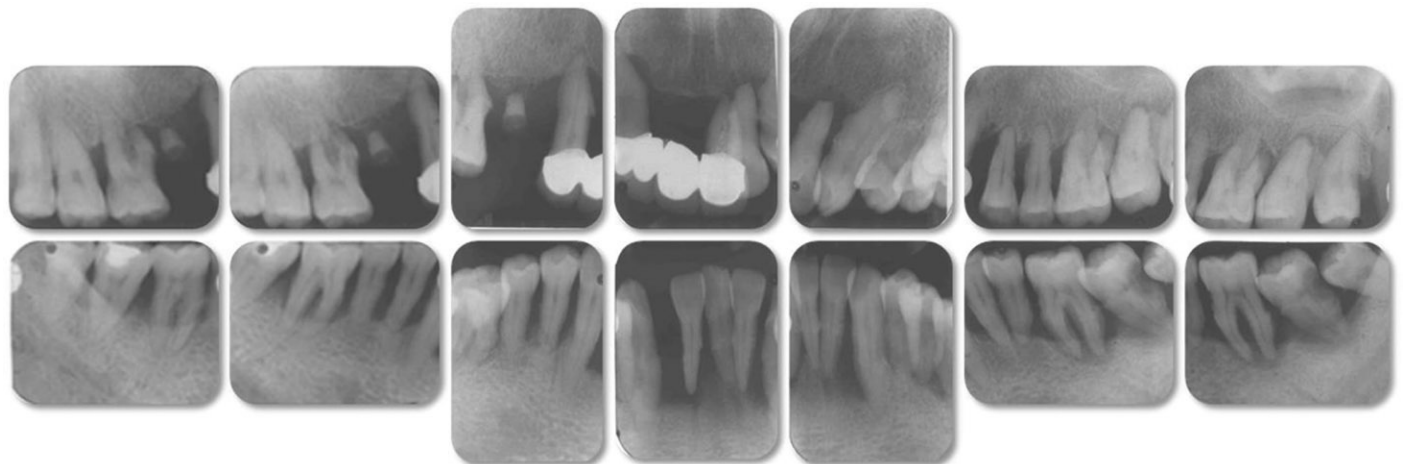

Fig. 2. Initial full-mouth radiography.

Table 1. Factors to consider for the treatment of edentulous arches

	Bone resorption	Jaw relation	Vertical space	Alveolar ridge	Labial support	Mucosa	Smile line
Fixed	minimum	class I	≤ 15 mm	sufficient volume	sufficient	thick keratinized	low
Removable	severe	class III	≥ 15 mm	volume deficiency	insufficient	thin movable	high

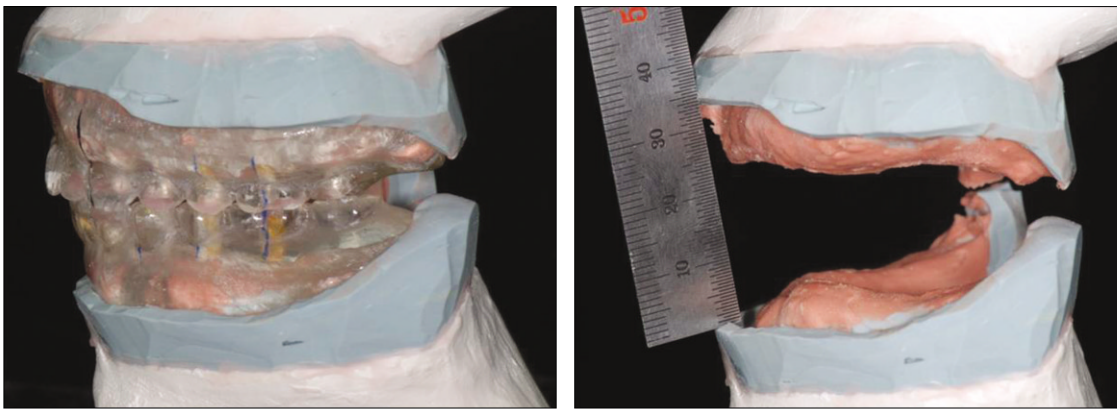


Fig. 3. Radiographic stents duplicated from the provisional dentures (left), and measurement of occluso-vertecal arch relationship (right).

computerized tomography scan were taken to identify suitable implant sites. Especially, the deficiency of alveolar bone volume was found at the upper incisal area. In maxilla, 6 implants were planned to be installed avoiding incisal area. Evenly distributed 6 implants were planned for the mandible. Six implants (USII, Osstem, Busan, Korea) were placed in maxilla with articulate bovine bone material (Bio-Oss, Geistlich, Wolhusen, Switzerland) and non-resorbable membrane (Gore-Tex membrane, W.L. Gore medical, Flagstaff, USA). Same implants were placed in mandible with an appropriate torque and no postsurgical complication (Fig. 4).

The tissues healed adequately and after 6 months from the installation of maxillary implants, the restorative process was started. The impression was taken on fixture level with transfer type impression coping with polyvinyl siloxane impression material (Examixfine, GC, Tokyo, Japan). Master casts (Die keen, Heraeus Kulzer Inc. Lafayette Blvd., USA) were fabricated. A diagnostic mounting and tooth-arrangement were completed for definitive evaluation of occlusal vertical dimension, interarch distance, centric relation, and the evaluation of the patient's esthetic anticipation. After considering these factors, third molars on the right side were extracted.

Denture teeth index was made with putty type of polyvinyl siloxane (Examixfine, GC, Tokyo, Japan) (Fig. 5). Clearance of denture teeth was verified with a denture teeth index.

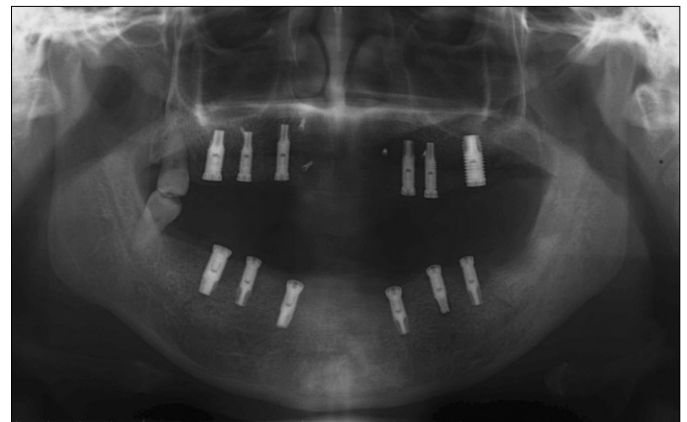


Fig. 4. Panoramic radiograph after implant installation.

A verification index made with pattern resin (Duralay, Reliance Dental Mfg Co, Worth, USA) was tried on each arch (Fig. 6). Due to the length of verification index, it was cut and re-connected with pattern resin. Fixed detachable metal frameworks were made with Type III gold (Goldenian C-75, Shinhung, Seoul, Korea). Heat curing acrylic resin (Paladent 20, Heraeus Kulzer GmbH, Hanau, Germany) was processed on the metal framework. The final prostheses were tried in (Fig. 7). The occlusion of prostheses was adjusted to achieve simultaneous centric relation contact and canine protected occlu-

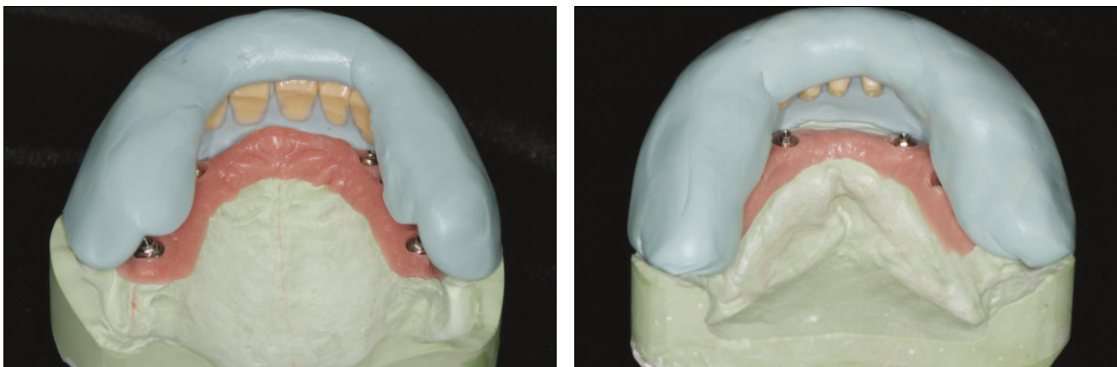


Fig. 5. Denture teeth indices (Left: Maxilla, Right: Mandible).

sion. After tightening the retaining screws with the recommended torque, periapical radiographs were taken for the examination. One week later, the occlusion was re-adjusted and screw access holes were filled with the flowable resin (Elite-flo, Bisco Inc., Schaumburg, USA). Postoperative instructions including hygiene care were given to the patient. Multidisciplinary regular check-up was emphasized. The patient was followed

at 1, 3, 6 and 10 months post-loading. Periapical radiographs were taken (Fig. 8) and maintenance care was taken in the Department of Periodontics. No complication except mild soft tissue inflammation was found. Professional maintenance care and personal care with Waterpik (Waterpik, Denver, USA) were recommended.

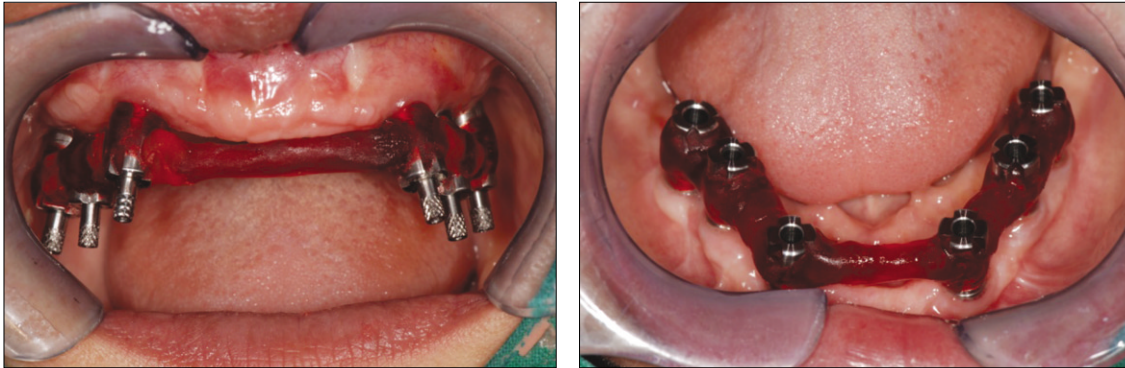


Fig. 6. Verification indices using pattern resin.

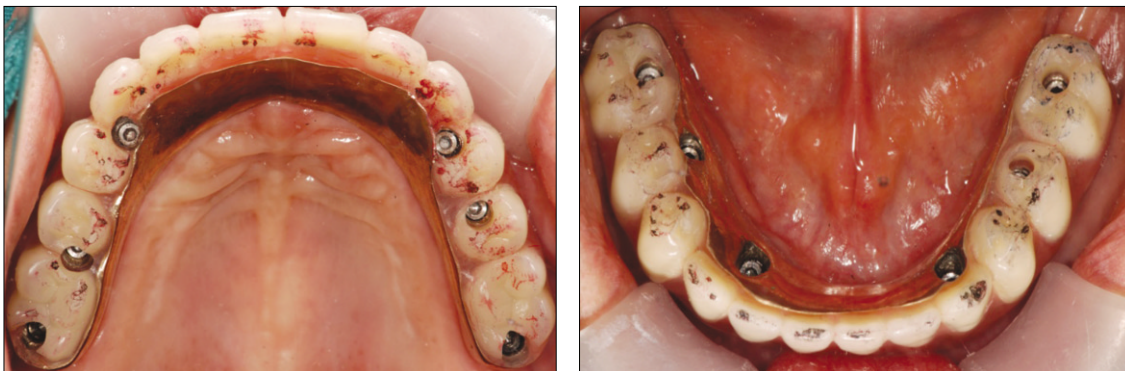


Fig. 7. Final fixed detachable prosthesis.

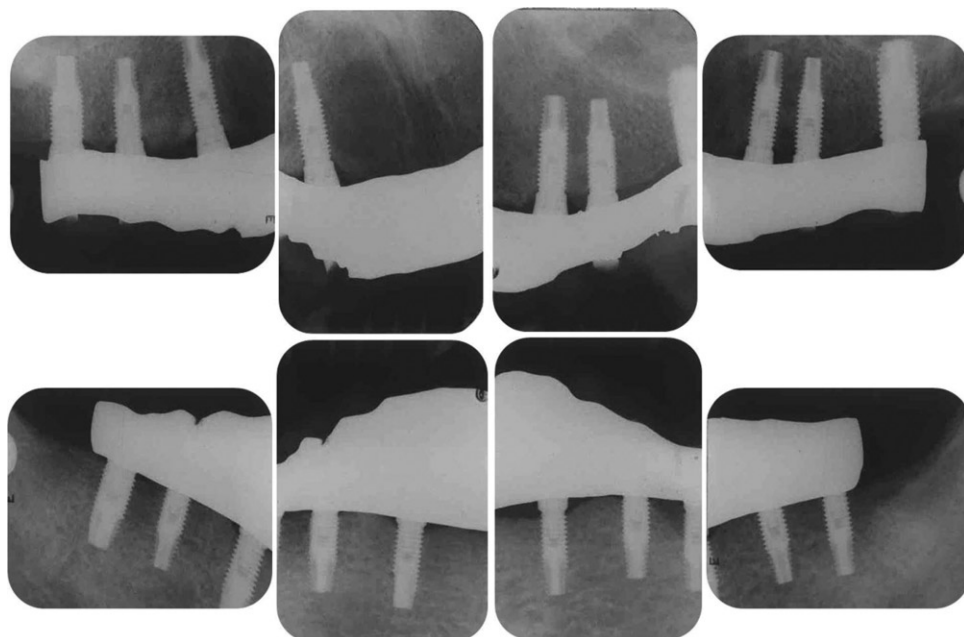


Fig. 8. Periapical radiography at 10 months after delivery of prosthesis.

DISCUSSION

Some studies^{11,12} reported that the long term implant prognosis in chronic periodontitis patients was similar to that of patients without periodontal disease. GAP patients also showed favorable results of implants in some reports.^{7,9} There is no randomized clinical trial to show that the aggressive periodontitis is not a risk factor in the survival of dental implants. However, the incidence of periimplantitis was higher in patients with aggressive periodontitis as opposed to those with chronic periodontitis.¹³ In this study, Schon insisted that the higher incidence of periimplantitis may reduce the potential longevity of the implant treatment. When treating aggressive periodontitis patients, it is recommended that all severely compromised teeth to be extracted before implant placement. After extraction of all teeth, abundant periodontal pathogens could still be found in the edentulous subject.⁶ In addition, the contributing factors such as immune factors may not be adequately controlled after implant treatment. Therefore, patient motivation and maintenance care are critical for the long-term success. Long-term clinical studies would be necessary to elucidate the susceptibility of implants to several aggravating factors of GAP.

In case of the patient described above, all the teeth were extracted. Several treatment options for rehabilitation with implant were considered. With moderate to advanced alveolar bone resorption, a fixed detachable prosthesis can replace lost bone and soft tissue.⁴ Also, inappropriate position of implant could be compromised with this type of prosthesis.⁴ In addition, this prosthesis offers the benefit of fixed prosthesis.

Although high survival rate of a fixed detachable prosthesis over a 15-year period has been reported,¹⁴ complications are also notable. Phonetic problems were the most frequent complaint (32%) during the first year, and after the first annual appointment, 13% of the patients still had speech difficulties.¹⁵ The patients with higher smile line had more esthetic problems.¹⁶ In this case, the contact to the soft tissue was accomplished with the flange extension of gold framework to avoid the phonetic and esthetic difficulties. Hygiene may be compromised with flange extension over abutments. This extension may produce hyperplastic tissue, also. Professional maintenance care and personal hygiene care are essential.

On the mandibular arch, continuous prosthetic stability has been reported as 99% of fixed detachable prostheses over 15-years.¹⁴

In the treatment planning stage, a complete denture for maxillary arch was considered. There was more maxillary bone loss under a complete denture opposing the fixed detachable prosthesis compared with the mandibular overdenture supported by two implants.¹⁷ More frequent maxillary denture relines and the solution for the retention problems are needed.¹⁷ Considering the patient's age and life-long maintenance, full mouth rehabilitation with implants on both arch was planned.

In fixed detachable prosthesis, maintenance problems of loose or fractured gold alloy screw, fractured acrylic resin matrix, and occlusal wear are common.¹⁸ Occlusal scheme should be planned to protect the component maintenance. Wie¹⁹ reported more failing screw joints in fixed-detachable prostheses with canine guidance when compared with group function or bilateral balanced occlusion. However, Chapman²⁰ recommended canine-guidance occlusion for fixed implant prostheses, while bilateral balanced occlusion was appropriate for mandibular implant overdentures only. With any of the occlusal scheme, the occlusion should distribute the masticatory forces evenly among the implants. For this purpose, bilateral simultaneous contact and smooth lateral contact were established at the time of insertion. Monitoring and adjusting the occlusal contacts would be necessary at recall visit.

SUMMARY

This case report presented the treatment procedures and results of a patient who lost whole dentitions due to GAP. To select adequate treatment option, bone resorption, jaw relation, vertical space and esthetic problems should be considered. After thorough clinical examination, radiographic assessment and provisional treatment, fixed detachable prostheses were selected because of the insufficient bone volume and compromised vertical space of the patient. With the provisional prostheses and diagnostic wax-up, the patient's esthetics and functions can be restored successfully. Multidisciplinary recall program is necessary to prevent maintenance complications.

REFERENCES

1. Armitage GC. Development of a classification system for periodontal diseases and conditions. *Ann Periodontol* 1999;4:1-6.
2. Albandar JM, Tinoco EM. Global epidemiology of periodontal diseases in children and young persons. *Periodontol* 2000;29:153-76.
3. Page RC, Altman LC, Ebersole JL, Vandesteen GE, Dahlberg WH, Williams BL, Osterberg SK. Rapidly progressive periodontitis. A distinct clinical condition. *J Periodontol* 1983;54:197-209.
4. Sadowsky SJ. The implant-supported prosthesis for the edentulous arch: design considerations. *J Prosthet Dent* 1997;78:28-33.
5. Albrektsson T, Zarb G, Worthington P, Eriksson AR. The long-term efficacy of currently used dental implants: a review and proposed criteria of success. *Int J Oral Maxillofac Implants* 1986;1:11-25.
6. Sachdeo A, Haffajee AD, Socransky SS. Biofilms in the edentulous oral cavity. *J Prosthodont* 2008;17:348-56.
7. Mengel R, Lehmann KM, Metke W, Wolf J, Flores-de-Jacoby L. A telescopic crown concept for the restoration of partially edentulous patients with aggressive generalized periodontitis: two case reports. *Int J Periodontics Restorative Dent* 2002;22:129-37.
8. Wu AY, Chee W. Implant-supported reconstruction in a patient with generalized aggressive periodontitis. *J Periodontol* 2007;78:777-82.
9. Yalcin S, Yalcin F, Gunay Y, Bellaz B, Onal S, Firatli E. Treatment of aggressive periodontitis by osseointegrated den-

- tal implants. A case report. *J Periodontol* 2001;72:411-6.
10. Park HS, Hwang JW. *Implant overdenture & fixed complete prosthesis*. 1st ed. Seoul; Well Pub. Co.; 2005.
 11. Ellegaard B, Baelum V, Karring T. Implant therapy in periodontally compromised patients. *Clin Oral Implants Res* 1997;8:180-8.
 12. Karoussis IK, Salvi GE, Heitz-Mayfield LJ, Bragger U, Hammerle CH, Lang NP. Long-term implant prognosis in patients with and without a history of chronic periodontitis: a 10-year prospective cohort study of the ITI Dental Implant System. *Clin Oral Implants Res* 2003;14:329-39.
 13. Schou S. Implant treatment in periodontitis-susceptible patients: a systematic review. *J Oral Rehabil* 2008;35:9-22.
 14. Adell R, Eriksson B, Lekholm U, Branemark PI, Jemt T. Long-term follow-up study of osseointegrated implants in the treatment of totally edentulous jaws. *Int J Oral Maxillofac Implants* 1990;5:347-59.
 15. Jemt T. Fixed implant-supported prostheses in the edentulous maxilla. A five-year follow-up report. *Clin Oral Implants Res* 1994;5:142-7.
 16. Lewis S, Sharma A, Nishimura R. Treatment of edentulous maxillae with osseointegrated implants. *J Prosthet Dent* 1992;68:503-8.
 17. Jacobs R, van Steenberghe D, Nys M, Naert I. Maxillary bone resorption in patients with mandibular implant-supported overdentures or fixed prostheses. *J Prosthet Dent* 1993;70:135-40.
 18. Zarb GA, Schmitt A. The longitudinal clinical effectiveness of osseointegrated dental implants: the Toronto study. Part III: Problems and complications encountered. *J Prosthet Dent* 1990;64:185-94.
 19. Wie H. Registration of localization, occlusion and occluding materials for failing screw joints in the Brånemark implant system. *Clin Oral Implants Res* 1995;6:47-53.
 20. Chapman RJ. Principles of occlusion for implant prostheses: guidelines for position, timing, and force of occlusal contacts. *Quintessence Int* 1989;20:473-80.