

Effect of *Epimedium Koreanum* on the 2-Bromopropane Induced-Reproductive Damage

Joo-Wan Kim, Hong-Tae Kim*, Sung-Dong Lee, Mee-Kyoung Lim**,
Sae-Kwang Ku***, Hyun-Jeong Park****, Tae-Ho Oh and Keun-Woo Lee¹

Department of Veterinary Internal Medicine, College of Veterinary Medicine, Kyungpook National University, Daegu 702-701, Korea

*Busan Metropolitan City Institute of Health & Environment, Gwangan 453, Suyounggu, Busan 613-104, Korea

**Department of Food Science and Nutrition, College of Human Ecology, Kyungpook National University, Sankyukdong, Daegu 702-701, Korea

***Department of anatomy and histology, College of Oriental Medicine, Daegu Haany University, Kyungsansi, Kyungsangbukdo 617-763, Korea

**** Department of Veterinary Radiology, College of Veterinary Medicine, Jeju National University, Jeju 690-756, Korea

(Accepted : August 17, 2010)

Abstract : *Epimedium koreanum* nakai (EKN) has been used for treatment of reproductive disorders. In this study, we evaluated the effects of EKN water extract on the 2-bromopropane (2-BP) induced reproductive dysfunction. The daily sperm production (DSP), sperm counts and histological changes of reproductive organs were investigated after 4 weeks of EKN administration in 2-BP induced reproductive damaged rats. Although the weights of epididymis and seminal vesicle were increased dose-dependently, they were lower than control group. DSP of EKN-dosing groups were increased compared to control group. In EKN-dosing groups, the number of degenerative seminiferous tubules and the number of epididymal tubules showing epithelial cell vacuolation and decreased spermatozoa in the lumen were significantly ($p < 0.01$) decreased compared to control group dose-dependently. Significant ($P < 0.05$ or $P < 0.01$) increases of the number of sertoli cells, spermatogonia, pachytene spermatocytes, round spermatids and elongated spermatids were observed in EKN-dosing groups compared control group. Consequently, based on the results, EKN water extract could treat 2-BP induced reproductive damages dramatically.

Key words : *Epimedium koreanum*, reproductive disorder, 2-bromopropane, rat.

Introduction

2-bromopropane (2-BP) is well known toxic material as cause of amenorrhea, oligozoospermia, azoospermia and anemia (16) as well as immunotoxic potentials (12,14). It can also decrease spermatogenesis by adversely effecting spermatogonia followed by depletion of spermatocytes, spermatids and spermatozoa with subsequent testicular atrophy (25,33).

Epimedium Koreanum Nakai (EKN) has been traditionally used as diuretic, tonic and antirheumatic and for improving of impotency in the oriental medicine (20). It also has other effects such as: anti-oxidant (19); anti-cancer in human lung cancer cells and prostate carcinoma (7); anti-osteoporosis by stimulating proliferation of bone marrow stromal cells (2); stimulation of erectile function of penis (18,20,35); anti-depressant by decreasing serum corticotropin-releasing factor and cortisol levels in rats (27).

EKN is known to contain a lot of medicinal components, such as prenylflavonol glycoside (26), icariin (31,32), magnof-

lorine (4), chlorogenic acid (30), korepimedeside A and B (34), hyperin (29) and etc. Especially, many researchers have been interested in icariin as main component of sexual function and antiosteoporosis (3,6,18,24,35,40).

Although EKN has shown medical effects for the aforementioned disorders and some of the effects were pharmaceutically proven, many of pharmacological actions and components of the EKN remain to be systemically determined.

Therefore, we performed this study to investigate the effects of EKN water extract on reproductive failure induced by 2-BP in Sprague-Dawley rats.

Materials and Methods

Preparation of materials

We obtained dried leaves of EKN from herbal market in Daegu, Korea. The extraction procedure was according to the method of Kim *et al* (15). Briefly, ground powder of dried EKN leaves were mixed with distilled water (100 g : 1000 ml) and the mixture was shaken with 140 rpm at 37°C water bath for 4 h. It was centrifuged at 3000 rpm, 4°C for 20 min, and the supernatant was filtered by No. 2 filter paper. The filtrate

¹Corresponding author.
E-mail : kwolee@knu.ac.kr

was concentrated by a rotator evaporator, lyophilized (19.5%) and stored at -20°C until use.

2-BP was obtained from Sigma (MO, USA) as liquid ($(\text{CH}_3)_2\text{CHBr}$, 99%). Olive oil was obtained from Junsei Chemical Co. Ltd (Japan). 2-BP was homogenized in olive oil (2-BP : olive oil = 1 : 1, v/v) and was administered 1,355 mg/kg subcutaneously. Homogenized 2-BP in olive oil was stored in stopper tube at room temperature.

Animals

Thirty-two 8 week-old male Sprague-Dawley rats (Crj/Bgi; CD(SD)IGS: 236 ± 21 g body weight) were obtained from Oriental Bio (Seoul, Korea) and used after acclimatization for 1 week. The rats were housed in a room with humidity of $50 \pm 10\%$ at $20 \pm 2^{\circ}\text{C}$, under 12h-intervals of light and dark cycle, and food and water were given *ad libitum*.

Experimental design

All experimental procedures were conducted according to the Guide for the Care and Use of Laboratory Animals of the Korea Food and Drug Administration (Seoul, 2005). All rats were injected 2-BP at dose of 1,355 mg/kg subcutaneously once a day for 28 days. In the day after last injection of 2-BP, the rats were divided into 3 EKN-dosing groups by body weights: EKN-10 (10 mg/kg EKN-dosing group), EKN-100 (100 mg/kg EKN-dosing group), EKN-500 (500 mg/kg EKN-dosing group) and control group in which each of 8 consisted. Then the test article was administered to the 3-EKN-dosing groups *per os* using a gastric gavage once a day for 28 days while control group was given with DW in the same manner instead of the test article.

Sample collection and histological examination

The day after last administration of the test article, all rats were anesthetized and bled via caudal vena cava. Blood samples were subjected to hematological analysis by an automatic analyzer (MS9-5, Japan). Organ samples were dissected, weighed and fixed with bouin solution or 10% neutral buffered formaldehyde. All of the samples were embedded, sectioned ($3\sim 4\ \mu\text{m}$) and stained with hematoxylin and eosin, and observed under light microscope. The right testis and epididymis were stored at -20°C and used for calculation of DSP and total sperm count, respectively.

DSP of the right testis and Sperm count of the right cauda epididymis

DSP was examined with the right testis according to the methods of Blazak *et al* (1). Briefly, frozen testis was thawed on ice, weighed after decapsulation, and homogenized in 50 ml of Hank's solution. The homogenate was allowed to settle down tissue debris for 1 min, and the supernatant sperm was decanted to a new tube. The sperm solution was evenly suspended and 10 ml-aliquot of the solution was collected into each glass vial and stored on ice. After complete mixing, the number of sperm heads was counted with a hemocytometer.

The number of produced sperms per gram of testicular tissue was calculated according to the following formula: the average count of sperm heads in four chambers \times square factor [5] \times hemocytometer factor [10^4] \times dilution factor [50] divided by testis weight [g] and the time of 6.1 days (28) in which the sperm was undamaged by homogenization after spermatogenesis.

To count the sperm number in the cauda epididymis, 0.5 ml of homogenate of right cauda epididymis was diluted with 4.5 ml of Hank's solution. The total number of sperm heads was counted using a hemocytometer, and the mean of three calculations per gram of cauda epididymis was calculated (28,37).

Histomorphometrical examination

The number of seminiferous tubules showing atrophic changes or containing vacuolated sertoli cells in testis, the number of epididymal tubules showing oligospermatozoa or aspermatozoa, and the number of epididymal tubules showing epithelial cell vacuolation were calculated as the number per 100 tubules, respectively. The histomorphometry was conducted using automated image analysis (DMI-300 Image Processing; DMI, Korea) under magnification 200 of microscopy (Nikon, Japan) at 5 fields ($n = 5$), respectively.

Spermatogenesis in seminiferous tubules

The number of sertoli cells, spermatogonia (Type A and B), preleptotene spermatocytes, leptotene spermatocytes, zygote spermatocytes, pachytene spermatocytes, round and elongated spermatids were counted at stages II-III, V, VII and XII in a total of 10 round or ovoid seminiferous tubules (number/tubules) as previously reported (21). These stages were chosen as the representative to include morphologically identifiable stages. Spermatogenic staging evaluation of testis was performed according to the previously described method (5).

Statistics

Multiple comparison tests (Mann-Whitney U-Wilcoxon Rank Sum W test) for different dosing groups were conducted in all data. Statistical analyses were conducted using SPSS for Windows (Release 10.0.7., SPSS Inc., USA). The values significantly different from control group were indicated at $P < 0.05$, $P < 0.01$

Results

Organ weight

After administration of EKN extract for 28 days in reproductive damaged rats induced by 2-BP, the absolute spleen weight in EKN-500 group was significantly ($P < 0.05$) decreased compared to control group but no significant change was observed in relative weight. The kidney weight in EKN-100 group was significantly ($P < 0.05$) increased compared to control group but no significant change was observed in other groups. The liver weight was not affected by 2-BP (data not shown). In EKN-10 and EKN-100 groups, not only the both absolute epididymis weights were significantly ($P < 0.05$) decreased

but the both absolute and relative seminal vesicle weights were significantly ($P < 0.01$ or $P < 0.05$) decreased compared to control group. The weights of epididymis and seminal vesicle were increased dose-dependently in EKN-dosing groups. No significant change was observed in testis and prostate (Table 1).

Hematological and serum chemistry exam

The platelet and white blood cell (WBC) of EKN-dosing groups were significantly ($P < 0.01$ or $P < 0.05$) decreased, respectively, and mean corpuscular volume (MCV) of EKN-500 group was decreased significantly ($P < 0.01$) compared to control group. There was no significant change in red blood cell (RBC), hemoglobin (Hb), packed cell volume (PCV), mean corpuscular hemoglobin (MCH) and mean corpuscular hemoglobin concentration (MCHC) (data not shown).

DSP and sperm count changes

The testis DSPs of EKN-dosing groups were increased compared to control group. Especially, the DSP in EKN-10 and EKN-100 groups was significantly ($P < 0.05$) increased compared to control group. The sperm count of the right cauda

epididymis in EKN-10 and EKN-500 groups was increased while EKN-100 group was decreased compared to control group. Sperm count in EKN-500 group was significantly ($P < 0.01$) increased compared to control group (Table 2).

Histological changes

The number of degenerative seminiferous tubules and the number of epididymal tubules showing epithelial cell vacuolation and decreased spermatozoa in the lumen in EKN-dosing groups were significantly ($p < 0.01$) decreased compared to control group dose-dependently (Table 3, fig 1). Significant ($p < 0.01$) increases of the number of sertoli cells, spermatogonia, preleptotene spermatocytes, leptotene spermatocytes, zygote spermatocytes, pachytene spermatocytes, round and elongated spermatids were observed in EKN-100 and EKN-500 at all stages and significant ($P < 0.05$ or $P < 0.01$) increase of those were observed in EKN-10 at all stages except stage XII compared to control group (Table 4, fig 2).

No abnormal histopathological change was observed in the liver, spleen, kidney, prostate and seminal vesicle in this study including control.

Table 1. Changes of reproductive organ weights after administration of EKN extract in 2-BP induced-reproductive damaged rats

Items	A dose of EKN extract administered ^{a)}			
	control	EKN-10	EKN-100	EKN-500
Absolute organ weight (g)				
Testis	0.81 ± 0.07 ^{b)}	0.81 ± 0.03	0.84 ± 0.05	0.81 ± 0.02
Epididymis	0.49 ± 0.01	0.45 ± 0.02 [#]	0.47 ± 0.01 [#]	0.50 ± 0.05
Prostate	0.79 ± 0.11	0.75 ± 0.22	0.69 ± 0.07	0.85 ± 0.10
Seminal vesicle	0.76 ± 0.13	0.33 ± 0.99 ^{###}	0.51 ± 0.18 ^{##}	0.76 ± 0.16
Relative organ weight (%) ^{c)}				
Testis	0.26 ± 0.02	0.26 ± 0.03	0.27 ± 0.03	0.27 ± 0.03
Epididymis	0.16 ± 0.00	0.14 ± 0.02	0.15 ± 0.01	0.16 ± 0.03
Prostate	0.25 ± 0.03	0.24 ± 0.08	0.22 ± 0.02	0.28 ± 0.06
Seminal vesicle	0.24 ± 0.04	0.11 ± 0.03 ^{##}	0.17 ± 0.05 [#]	0.25 ± 0.07

^{a)}; each of 10, 100 and 500 mg/kg of EKN extract was administered each 8 reproductive damaged rats orally for 28 days. ^{b)}; The values were expressed with mean ± SD. ^{c)}; Ratio of the organ weight divided by body weight.

^{###}; each of indicated $P < 0.05$, $P < 0.01$, respectively compared to control group.

Table 2. Changes of DPS of the testis and sperm count of cauda epididymis after administration of EKN extract in 2-BP induced-reproductive damaged rats

Items	A dose of EKN extract administered ^{a)}			
	control	EKN-10	EKN-100	EKN-500
Right testis weight (g)	0.79 ± 0.13 ^{b)}	0.65 ± 0.10	0.69 ± 0.06	0.77 ± 0.04
DSP ($\times 10^8$ /g)	4.08 ± 0.72	6.02 ± 0.94 [#]	5.41 ± 0.67 [#]	4.80 ± 0.13
Cauda epididymis weight (g)	0.20 ± 0.02	0.19 ± 0.03	0.19 ± 0.02	0.20 ± 0.01
Sperm count ($\times 10^8$ /g)	9.31 ± 0.41	10.54 ± 1.77	8.38 ± 0.80	12.64 ± 1.06 ^{##}

^{a)}; each of 10, 100 and 500 mg/kg of EKN extract was administered each 8 reproductive damaged rats orally for 28 days. ^{b)}; The values were expressed with mean ± SD.

^{##}; indicated $P < 0.05$, $P < 0.01$ compared to control group.

Table 3. Changes of the number of abnormal seminiferous and epididymal tubules after administration of EKN extract in 2-BP induced-reproductive damaged rats

Items Groups (N/100 ubules)	No. of seminiferous tubules showing atrophic changes or contains vacuolated sertoli cells	No. of epididymal tubules	
		Decreases spermatozoa of spermatozoa in the lumens	vacuolated epithelia lining
Control	80.80 ± 6.65 ^{b)}	86.60 ± 5.41	76.00 ± 4.47
EKN-10 ^{a)}	64.80 ± 7.63 ^{##}	67.00 ± 4.36 ^{##}	51.80 ± 3.11 ^{##}
EKN-100	41.40 ± 3.05 ^{##}	39.60 ± 6.02 ^{##}	36.20 ± 4.87 ^{##}
EKN-500	30.20 ± 4.66 ^{##}	31.40 ± 3.21 ^{##}	28.80 ± 7.85 ^{##}

^{a)}; each of 10, 100 and 500 mg/kg of EKN extract was administered each 8 reproductive damaged rats orally for 28days. ^{b)}; The values were expressed with mean ± SD. n=5 (5 fields of microscopy)

^{##}; indicated P < 0.01 compared to control group.

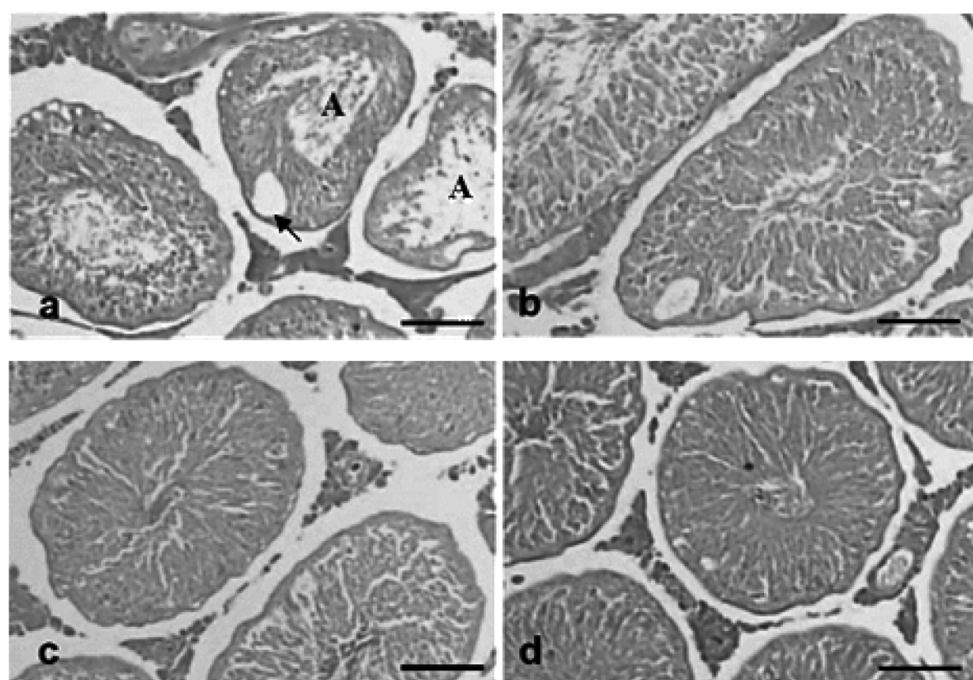


Fig 1. Histological profiles of the testis in the control (a), EKN-10 (b), EKN-100 (c) and EKN-500 (d). Note that epithelial lining cell vacuolation (arrows) and aspermatozoa (A) were observed in the lumen of epididymal tubules after administration of control. However, these epididymal histopathological changes were dramatically inhibited by administration of the EKN-dosing group. All HE stain; Scale bars = 80 μ m.

Discussion

EKN has been traditionally used for improving of impotency in oriental medicine (20). Recently, some researchers lively have been studying the components, flavonoids (26,32,31,4) of EKN, and its sexual or immunological effects on normal mice or rats. To investigate of effects of EKN in reproductive damage, we used 2-BP to induced reproductive damage, especially inhibition of spermatogenesis. Over 1,000 ppm exposure level of 2-BP, the spermatogenesis in the most of rats were inhibited. The 1,000 ppm exposure level is calculated to be approximately 1,355 mg/kg per day (9,22).

In the previous studies (17,36,9,12,39,13), the weights of body, thymus, spleen, testis, epididymis, prostate and seminal

vesicle were decreased in 2-BP treated rats. In this study, however, EKN did not affect the weights of liver, spleen and kidney in 2-BP treated rats. Spleen weight was slightly decreased whereas kidney weight was slightly increased compared to control group. But there was no scientific evidence about increases of liver, kidney and spleen weight after administration of EKN extract in reproductive damaged rats (Table 1). The weights of epididymis, prostate, and seminal vesicle were dose-dependently increased in the EKN-dosing groups but they were lower than control group. In EKN-10 and EKN-100 groups, they were significantly ($P < 0.01$ or $P < 0.05$) lower than control group but those of EKN-500 group were higher than control group or similar. Testis did not changed in this study (Table 2). Unexpected result of reproductive tissue weight was showed in EKN-10

Table 4. Cell types and numbers of seminiferous tubules after administration of EKN extract in 2-BP induced-reproductive damaged rats

Items	A dose of EKN extract administered ^{a)}			
	control	EKN-10	EKN-100	EKN-500
Stage I-III				
Sertoli cells	8.30 ± 2.36 ^{b)}	12.40 ± 2.59 ^{##}	13.50 ± 1.27 ^{##}	14.00 ± 2.26 ^{##}
Spermatogonia	1.90 ± 0.57	8.70 ± 3.16 ^{##}	11.00 ± 1.15 ^{##}	12.40 ± 1.65 ^{##}
Pachytene spermatocytes	10.40 ± 1.90	14.60 ± 3.50	16.60 ± 3.37 ^{##}	17.90 ± 5.22 ^{##}
Round spermatids	80.40 ± 31.79	125.00 ± 8.65 ^{##}	131.10 ± 7.68 ^{##}	138.20 ± 12.19 ^{##}
Elongated spermatids	93.00 ± 20.34	119.90 ± 13.24 ^{##}	131.80 ± 8.97 ^{##}	132.80 ± 7.61 ^{##}
Stages V				
Sertoli cells	8.30 ± 2.00	11.10 ± 1.10 ^{##}	12.40 ± 1.17 ^{##}	13.00 ± 1.63 ^{##}
Spermatogonia	1.90 ± 2.56	6.50 ± 2.76 ^{##}	8.80 ± 2.10 ^{##}	10.80 ± 1.32 ^{##}
Pachytene spermatocytes	20.20 ± 4.78	32.40 ± 5.02 ^{##}	35.50 ± 9.59 ^{##}	44.40 ± 10.15 ^{##}
Round spermatids	104.40 ± 14.91	121.20 ± 6.30 ^{##}	125.20 ± 9.98 ^{##}	128.70 ± 7.47 ^{##}
Elongated spermatids	94.90 ± 16.64	115.00 ± 10.01 ^{##}	126.80 ± 8.84 ^{##}	131.30 ± 11.74 ^{##}
Stages VII				
Sertoli cells	8.70 ± 3.37	12.50 ± 1.08 ^{##}	12.60 ± 1.71 ^{##}	12.70 ± 1.34 ^{##}
Spermatogonia	0.90 ± 0.74	2.20 ± 0.79	2.40 ± 0.84 ^{##}	2.40 ± 0.84 ^{##}
Preleptotene spermatocytes	12.40 ± 3.13	18.60 ± 2.88 ^{##}	21.60 ± 3.63 ^{##}	24.60 ± 4.14 ^{##}
Pachytene spermatocytes	21.40 ± 2.28	27.10 ± 4.93 ^{##}	29.60 ± 3.03 ^{##}	31.70 ± 3.53 ^{##}
Round spermatids	101.80 ± 29.59	131.10 ± 5.97 ^{##}	133.50 ± 10.78 ^{##}	141.30 ± 15.57 ^{##}
Elongated spermatids	90.60 ± 11.53	113.60 ± 10.01 ^{##}	120.80 ± 9.60 ^{##}	126.20 ± 11.31 ^{##}
Stages XII				
Sertoli cells	10.70 ± 1.49	12.40 ± 1.17	13.10 ± 2.51 [#]	13.90 ± 2.13 ^{##}
Spermatogonia	1.00 ± 0.94	2.20 ± 0.63 ^{##}	2.30 ± 0.67 ^{##}	2.40 ± 0.70 ^{##}
Pachytene spermatocytes	11.60 ± 2.63	20.20 ± 4.52 ^{##}	22.10 ± 4.12 ^{##}	24.10 ± 7.67 ^{##}
Round spermatids	8.60 ± 2.37	13.10 ± 2.47 ^{##}	13.60 ± 2.55 ^{##}	14.20 ± 3.22 ^{##}
Elongated spermatids	83.90 ± 20.84	112.60 ± 13.38 ^{##}	119.80 ± 8.40 ^{##}	124.90 ± 10.39 ^{##}

^{a)}; each of 10, 100 and 500 mg/kg of EKN extract was administered each 8 reproductive damaged rats orally for 28 days. ^{b)}; The values were expressed with mean ± SD. n = 10 (10 round or ovoid seminiferous tubules).

[#], ^{##}; each of indicated p < 0.05, p < 0.01 compared to control group.

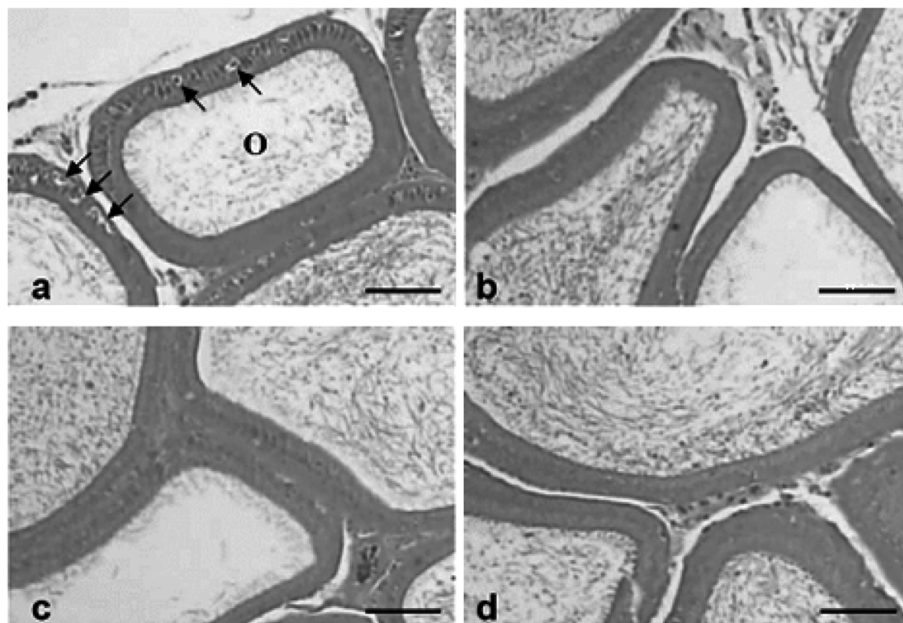


Fig 2. Histological profiles of the epididymis in the control (a), EKN-10 (b), EKN-100 (c) and EKN-500 (d). Note that epithelial lining cell vacuolation (arrows) and oligospermatozoa (O) were observed in the lumen of epididymal tubules after administration of control. However, these epididymal histopathological changes were dramatically inhibited by administration of EKN-dosing group. All HE stain; Scale bars = 80 μm.

and EKN-100.

In this study, any significant change of reproductive organ was not observed in the low dose (EKN-10) group. Therefore further investigation about it might be needed. Over the 500 mg/kg of EKN extract has anti-impotent effect against 2-BP induced-genital damage by increasing the weight of reproductive organ.

Jeong *et al* (12) reported RBC was slightly decreased and platelet was significantly ($P < 0.05$) decreased and PCV, MCV and MCH were not affected in 2-BP treated rats. In this study, some parts of hematological items, MCV in EKN-500, platelet in EKN-10, were shown significant ($P < 0.01$) changes, but all of the hematological data were within the reference index. EKN did not affect hematological changes in 2-BP induced-reproductive damaged rats.

In the previous studies (17,36), the decreases of DSP and sperm number in 2-BP treated rats resulted from apoptosis. In this study, DSPs of EKN-dosing groups were decreased with dose-dependent pattern while this result came into conflict with histomorphological results (low damage of spermatozoa). It was supposed that DSP ability had relation to sperm count, that is, plenty of sperms stimulated negative feedback as low DSP. Sperm counts of EKN-dosing groups were increased dose-dependently. Although epididymis weights of EKN-dosing groups were decreased, but sperm count was increased compared to control group. It is considered that the sperm production could be affected by EKN and DSP could be affected by decreased sperm count. So we assume that EKN has an active function as stimulating spermatozoa and/or sertoli cell, because in control group, they did not act like in EKN-dosing groups (Table 3). So we examined the histological aspect, well corresponded to the previous studies (9,10,17,38), atrophic changes of seminiferous tubules, vacuolation of sertoli cells were detected, and epithelial lining cell vacuolation and oligo- or aspermatozoa were detected in the lumen of epididymal tubules at histopathological observation after 28 days of serial injection of 1,355 mg/kg of 2-BP treatment, and these 2-BP induced reproductive damages are reconfirmed with histomorphometry. 2-BP induced-reproductive damages were dramatically decreased in EKN-dosing groups compared to control group (Figs 1 and 2). The number of degenerative seminiferous tubules and the number of epididymal tubules showing epithelial cell vacuolation and decreased spermatozoa in the lumen were significantly ($p < 0.01$ or $p < 0.05$) decreased after treatment of 10, 100 or 500 mg/kg of EKN (Table 4). These are considered as direct evidences that EKN effectively treated the 2-BP induced-reproductive damages.

DSP parameter in the histological sections of testis can be used as a valid assay of spermatogonia survival for cytotoxic agents (23) and has been used as an indicator of spermatogenesis (8,11). At dose of 1,355 mg/kg of 2-BP, the numbers of sertoli cells, spermatogonia, preleptotene spermatocytes, leptotene spermatocytes, zygotene spermatocytes, pachytene spermatocytes, round and elongated spermatids were dramatically decreased on 15 days of continuous treatment (17). 2-BP primarily targets to

spermatogonia by apoptosis (17,25,39) and consequently decreases of spermatocytes and spermatids were induced. In this study, significant ($p < 0.01$ or $p < 0.05$) increases of the numbers of sertoli cells, spermatogonia, preleptotene spermatocytes, leptotene spermatocytes, zygotene spermatocytes, pachytene spermatocytes, round and elongated spermatids were observed in EKN-100 and EKN-500 at all stages, compared to control group. Although significant ($p < 0.01$ or $p < 0.05$) increases were restricted to some cell types of some stages, dramatic increases of all cell types at all stages were also detected in EKN-dosing groups compared to control group, respectively (Table 4). These are considered as direct evidences that EKN effectively inhibits decreases of spermatogenesis induced by 2-BP. No abnormal histopathological change was observed in liver, spleen, kidney, prostate and seminal vesicle including control group.

Based on the results, it is concluded that EKN water extract dramatically treats the 2-BP induced-reproductive damages from 10 mg/kg of dose levels, the lowest levels. Although 10 mg/kg of EKN extract also inhibited the decreases of spermatogenesis, the effective dosage of EKN inhibiting both reproductive damages and decreases of spermatogenesis by 2-BP was considered as 100 mg/kg in rats because significant inhibition of spermatogenesis decreases was restricted to some stages of some cell types in 10 mg/kg dosing group.

References

1. Blazak WF, Treinen KA, Junievicz PE. Application of testicular sperm head counts in the assessment of male reproductive toxicity. In: chapin RE, Heindel JJ, editors. Methods in toxicology: male reproductive toxicology. San Diego: Academic press. 1993: 86-94.
2. Chen KM, Ge BF, Ma HP, Liu XY, Bai MH, Wang Y. Icaritin, a flavonoid from the herb *Epimedium* enhances the osteogenic differentiation of rat primary bone marrow stromal cells. *Pharmazie* 2005; 60: 939-942.
3. Chen KM, Ge BF, Liu XY, Ma PH, Lu MB, Bai MH, Wang Y. Icaritin inhibits the osteoclast formation induced by RANKL and macrophage-colony stimulating factor in mouse bone marrow culture. *Pharmazie* 2007; 62: 388-391.
4. Chen C, Sha M, Yang S, Zhan L. Quantitative study of Magnoflorine in *Epimedium Koreanum nakai*. *Zhongguo Zhong Yao Za Zhi* 1996; 21: 681-682, 704.
5. Creasy DM. Evaluation of testicular toxicity in safety evaluation studies: the appropriate use of spermatogenic staging. *Toxicol Pathol* 1997; 25: 119-131.
6. Huang J, Yuan L, Wang X, Zhang TL, Wang K. Icaritin and its glycosides enhance osteoblastic, but suppress osteoclastic, differentiation and activity in vitro. *Life Sci* 2007; 81: 832-840.
7. Huang X, Zhu D, Lou Y. A novel anticancer agent, icaritin, induced cell growth inhibition, G1 arrest and mitochondrial transmembrane potential drop in human prostate carcinoma PC-3 cells. *Eur J Pharmacol* 2007; 564: 26-36.
8. Hou M, Chrysis D, Nurmio M, Parvinen M, Eksborg S, Soder O, Jahnukainen K. Doxorubicin induces apoptosis in germ line stem cells in the immature rat testis and amifostine cannot protect against this cytotoxicity. *Cancer Res* 2005; 65: 9999-10005.

9. Ichihara G, Asaeda N, Kumazawa T, Tagawa Y, Kamijima M, Yu X, Konda H, Nakajima T, Kitoh J, Yu IJ, Moon YH, Hisanaga N, Takeuchi Y. Testicular toxicity of 2-bromopropane. *J Occup Health* 1996; 38: 205-206.
10. Ichihara G, Asaeda N, Kumazawa T, Tagawa Y, Kamijima M, Yu X, Konda H, Nakajima T, Kitoh J, Yu IJ, Moon YH, Hisanaga N, Takeuchi Y. Testicular and hematopoietic toxicity of 2-bromopropane, a substitute for ozone layer-depleting chlorofluorocarbons. *J Occup Health* 1997; 39: 57-63.
11. Jahnukainen K, Chrystis D, Hou M, Parvinen M, Eksborg S, Soder O. Increased apoptosis occurring during the first wave of spermatogenesis is stage-specific and primarily affects midpachytene spermatocytes in the rat testis. *Biol Reprod* 2004; 70: 290-296.
12. Jeong TC, Lee ES, Chae W, Koh WS, Kang BH, Han SS. Immunotoxic effects of 2-bromopropane in male Sprague-dawley rats: a 28-day exposure study. *J Toxicol Environ Health A* 2002; 65: 383-394.
13. Kang KS, Li GX, Che JH, Lee YS. Impairment of male rat reproductive function in F1 offspring from dams exposed to 2-bromopropane during gestation and lactation. *Reprod Toxicol* 2002; 16: 151-159.
14. Kim HJ, Kang BN, Cho SW, Son HY, Jeong NS, Park SJ, Kim SH, Kim SR, Kim TH, An MY, Ryu SY. Effect of Benzo[a]pyrene, 2-bromopropane, phenol and 2,3,7,8-tetrachlorodibenzo-p-dioxin on proinflammatory cytokines gene expression by mice spleen cells. *J Vet Sci* 2002; 3: 247-254.
15. Kim HT, Kim JW, Lim MK, Jin TW, Yeo SG, Jang KH, Oh TH, Lee KW. Cytotoxic effect of *Artemisia capillaris* extracts on the cancer cells on in vitro. *J Vet Clin* 2007; 24: 367-371.
16. Kim Y, Jung K, Hwang T, Jung G, Kim H, Park J, Kim J, Park J, Park D, Park S, Choi K, Moon Y. Hematopoietic and reproductive hazards of Korean electronic workers exposed to solvents containing 2-bromopropane. *Scand J Work Environ Health* 1996; 22: 387-391.
17. Li GX, Kang KS, Lee YS. 2-bromopropane induced germ cell apoptosis during spermatogenesis in male rat. *J Vet Med Sci* 2000; 63: 373-382.
18. Liu WJ, Xin ZC, Xin H, Yuan YM, Tian L, Guo YL. Effects of icariin on erectile function and expression of nitric oxide synthase isoforms in castrated rats. *Asian J Androl* 2005; 7: 381-388.
19. Liu ZQ. Icariin: A special antioxidant to protect linoleic acid against free-radical-induced peroxidation in micelles. *J Phys Chem A* 2006; 110: 6372-6378.
20. Makarova MN, Pozharitskaya ON, Shikov AN, Tesakova SV, Makarov VG, Tikhonov VP. Effect of lipid-based suspension of *Epimedium koreanum* Nakai extract on sexual behavior in rats. *J Ethnopharmacol* 2007; 114: 412-416.
21. Matsui H, Toyoda K, Kawanashi T. Advantages of simplified quantitative morphometry using stage grouping analysis of spermatogenic cycle for evaluation of the testicular toxicity of ethylene-1, 2-dimethanesulfonate in rats. *J Toxicol Pathol* 1996; 9: 285-292.
22. Mauderly JL, Tesarek JE, Sifford LJ, Sifford LJ. Respiratory measurements of unsedated small laboratory mammals using nonbreathing valves. *Lab Anim Sci* 1979; 29: 323-329.
23. Meistrich ML. Relationship between spermatogonial stem cell survival and testis function after cytotoxic therapy. *Br J Cancer (Suppl)* 1986; 7: 89-101.
24. Nian H, Ma MH, Nian SS, Xu LL. Antiosteoporotic activity of icariin in ovariectomized rats. *Phytomedicine* 2009; 16: 320-326.
25. Omura M, Romero Y, Zhao M, Inoue N. Histopathological evidence that spermatogonia are the target cells of 2-Bromopropane. *Toxicology Letters* 1999; 104: 19-26.
26. Pachaly P, Schonherr-Weissbarth C, Sin KS. New prenyl-flavonoid glycosides from *Epimedium Koreanum*. *Planta Med* 1990; 56: 277-280.
27. Pang Y, Zhang WY, Xia X, Kong LD. Effects of icariin on hypothalamic-pituitary-adrenal axis action and cytokine levels in stressed Sprague-Dawley rats. *Biol Pharm Bull* 2006; 29: 2399-2403.
28. Robb GW, Amann RP, Killian GJ. Daily sperm production and epididymal sperm reserves of pubertal and adult rats. *J Reprod Fertil* 1978; 54: 103-107.
29. Sha M, Cao A, Yang S. Determination of hyperin in *epimedium koreanum* Nakai by HPLC. *Zhongguo Zhong Yao Za Zhi* 1995; 20: 357-358, 384.
30. Sha M, Cao A, Yang S. Determination of chlorogenic acid in *epimedium koreanum* nakai by HPLC. *Zhongguo Zhong Yao Za Zhi* 1996; 21: 108-109, 128.
31. Sha M, Cao A, Yang S, Xue Y. Determination of icariin in *epimedium koreanum* nakai by high performance liquid chromatography. *Se Pu* 1997; 15: 166-167.
32. Shin KH, Kang SS, Chung SG, Cho EH. Determination of icariin in *Epimedium herba* by high performance liquid chromatography. *Kor J Pharmacogn* 1989; 20: 21-24.
33. Son HY, Kim YB, Kang BH, Gho SW, Ha CS, Roh JK. Effects of 2-bromopropane on spermatogenesis in the Sprague-Dawley rats. *Reprod Toxicol* 1999; 13: 179-187.
34. Sun PY, Chen YJ, Wen Y, Pei YP, Liu ZH, Yao XS, Takeda T, Ogihara Y. Structure determination of korepimidoside A and korepimidoside B from *Epimedium koreanum* nakai. *Yao Xue Xue Bao* 1996; 31: 602-606.
35. Tian L, Xin ZC, Yuan YM, Fu J, Liu WJ, Wang LL. Effects of icariin on intracavernosal pressure and systematic arterial blood pressure of rat. *Zhonghua Yi Xue Za Zhi* 2004; 84: 142-145.
36. Wu X, Faqi AS, Yang J, Ding X, Jiang X, Chahoud I. Male reproductive toxicity and beta-luteinizing hormone gene expression in sexually mature and immature rats exposed to 2-bromopropane. *Hum Exp Toxicol* 1999; 18: 683-690.
37. Yamada T, Inoue T, Sato A, Yamagishi K, Sato M. Effects of short-term administration of alpha-chlorohydrin on reproductive toxicity parameters in male Sprague-Dawley rats. *J Toxicol Sci* 1995; 20: 195-205.
38. Yu IJ, Chung YH, Lim CH, Maeng SH, Lee JY, Kim HY, Lee SJ, Kim CH, Kim TG, Lim CH, Park JS, Moon YH. Reproductive toxicity of 2-bromopropane in Sprague Dawley rats. *Scand J Work Environ Health* 1997; 23: 281-288.
39. Yu IJ, Kim HY, Lim CH, Lee YM, Moon YH. The occupational exposure level (OEL) for 2-bromopropane: the first OEL established by Korea. *Appl Occup Environ Hyg* 1999; 14: 356-358.
40. Zhang ZB, Yang QT. The testosterone mimetic properties of icariin. *Asian J Androl* 2006; 8: 601-605.

2-bromopropane으로 유발된 생식기 장애에서 음양곽 물추출물의 효과

김주완 · 김홍태* · 이성동 · 임미경** · 구세광*** · 박현정**** · 오태호 · 이근우¹

경북대학교 수의과대학, *부산광역시 보건환경연구원,
경북대학교 생활과학대학, *대구한의대학교 한의과대학, ****제주대학교 수의과대학

요 약 : 음양곽(*Epimedium Koreanum nakai*)은 예부터 생식기 장애치료를 위해 사용되어 왔다. 본 연구에서는 2-브로모프로판(2-bromopropane; 2-BP)으로 유발된 생식기 장애에서 음양곽 물추출물의 생식기장애 치료효과를 평가하였다. 2-BP를 체중kg당 1,355 mg씩 28일간 피하로 투여하여 생식기 장애를 유발하였으며, 음양곽 추출물은 용량별(10, 100, 500 mg/kg)로 4주간 경구투여 하였다. 그 결과 일일정자생성(daily sperm production)은 대조군에 비하여 증가하였으나 용량의존적 감소를 나타내었으며, 정세관과 부고환에서는 조직학적 유의한 변화를 나타내었다. 이러한 결과는 음양곽물추출이 2-BP로 유발된 생식기장애의 치료에 도움이 될 것으로 생각된다.

주요어 : 음양곽, 생식기장애, 2-브로모프로판, 랫