

Case Report

Pseudoaneurysm of Ulnar Artery after Endoscopic Carpal Tunnel Release

Sung-Joo Ryu, M.D., In-Soo Kim, M.D., Ph.D.

Department of Neurosurgery, Dongsan Medical Center, Keimyung University School of Medicine, Daegu, Korea

The authors present an extremely rare case of a pseudoaneurysm of the ulnar artery as a complication of a two-portal endoscopic carpal tunnel release (ECTR). A 70-year-old man with chronic renal failure and on maintenance hemodialysis with a left arteriovenous fistula presented with paresthesia of his right hand. A clinical diagnosis of right carpal tunnel syndrome was confirmed by ultrasonography and an electrophysiologic study. He underwent two-portal ECTR, and the paresthesia was much improved. However, he presented to us one month after operation with severe pain, a tender mass distal to the right wrist crease and more aggravation of the paresthesia in the ulnar nerve distribution. Doppler ultrasound was performed and revealed a hypoechoic lesion 20 mm in diameter in the right palm, with arterial Doppler flow inside connected to the palmar segment of the ulnar artery. An ulnar artery pseudoaneurysm was diagnosed and treated by ultrasound-guided percutaneous thrombin injection. Transverse color Doppler ultrasound image showed complete thrombosis of the pseudoaneurysm and flow cessation after a total injection of 500 units of thrombin. The symptoms were also improved.

KEY WORDS : Endoscopic carpal tunnel release · Complication · Pseudoaneurysm.

INTRODUCTION

Endoscopic carpal tunnel release (ECTR) has been used to decrease postoperative complication rates, to reduce postoperative pain, to speed up recovery, and to improve the preservation of grip strength compared with open carpal tunnel release. However, various complications may occur such as incomplete release of the retinaculum, and injury to the median nerve and vessels¹⁴. A literature review was conducted of the PubMed database. "Neurovascular complication", "endoscopic carpal tunnel release", "complications related carpal tunnel release" and "pseudoaneurysm" were used as medical subject headlines in combination with "carpal tunnel syndrome" as a key word in the abstracts or the title in the PubMed database. In our search, there was only one report of an ulnar artery pseudoaneurysm after ECTR. Here, we report on a case with a pseudoaneurysm of the ulnar artery as a

complication of two-portal ECTR.

CASE REPORT

A 70-year-old, right hand dominant man with chronic renal failure and on maintenance hemodialysis with a left arteriovenous fistula for 10 years presented with a 10 year history of paresthesia involving the palms of his right hand. A clinical diagnosis of right carpal tunnel syndrome was confirmed by ultrasonography and an electrophysiologic study. Ultrasonography showed mild thickening of the flexor retinaculum, mild flattening of the median nerve, and no definite anatomic malformations. In the electrophysiologic study, absence of sensory nerve action potential and compound motor action potential at the abductor pollicis brevis with median nerve stimulation were compatible with severe-grade median nerve neuropathy at the wrist. The patient underwent two-portal ECTR under lidocaine IV anesthesia, and the paresthesia was much improved. However, he presented to us one month after the operation with severe pain, a tender mass distal to the right wrist crease and more aggravation of the paresthesia in the ulnar nerve distribution. Doppler ultrasound was performed and revealed a hypoechoic lesion 20 mm in diameter in the right palm, with arterial Doppler

• Received : February 19, 2010 • Revised : October 5, 2010

• Accepted : October 6, 2010

• Address for reprints : In-Soo Kim, M.D., Ph.D.

Department of Neurosurgery, Dongsan Medical Center, Keimyung University School of Medicine, 216 Dalseong-ro, Jung-gu, Daegu 700-712, Korea

Tel : +82-53-250-7730, Fax : +82-53-250-7820

E-mail : neurokim@dsmc.or.kr

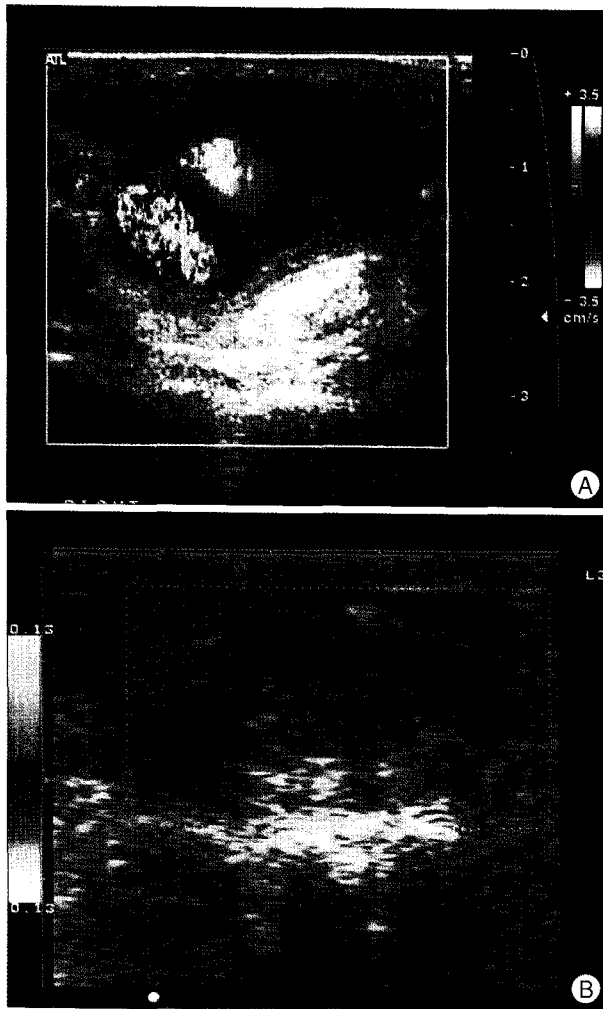


Fig. 1. Transverse color Doppler ultrasound image showing the distal ulnar artery showing a pseudoaneurysm with turbulent flow in its lumen (A) and complete thrombosis of the pseudoaneurysm and flow cessation after a total injection of 500 units of thrombin (B).

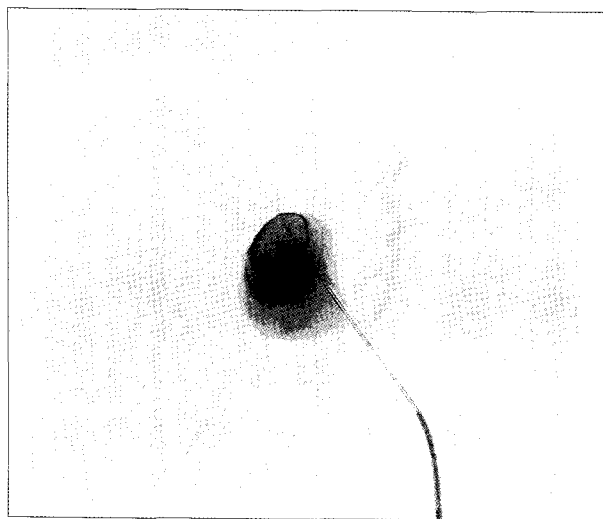


Fig. 2. Arteriography after direct puncture of the pseudoaneurysm showing the unilobulated pseudoaneurysm originating from the palmar segment of the ulnar artery through a narrow neck.

flow inside connected to the palmar segment of the ulnar artery and compressing the ulnar nerve distally. The ulnar artery pseudoaneurysm was diagnosed and treated by ultrasound-guided percutaneous thrombin injection. An echogenic needle was percutaneously injected with a side delivery port to the middle of the pseudoaneurysm, away from the neck. Arteriography after direct puncture of the pseudoaneurysm showed the unilobulated pseudoaneurysm originating from the palmar segment of the ulnar artery through a narrow neck. (Fig. 1). Transverse color Doppler ultrasound image showed complete thrombosis of the pseudoaneurysm and flow cessation after a total injection of 500 units of thrombin. (Fig. 2). The symptoms were improved.

DISCUSSION

Carpal tunnel syndrome is the most common nerve entrapment disorder of the upper extremity with an estimated life time risk of 10% and an overall prevalence of 2.1% in the general population¹¹. The syndrome is usually related to compression of the median nerve within the carpal tunnel because of a variety of etiologic factors⁶. A number of medical conditions also increase the risk of carpal tunnel syndrome. The incidence and recurrence of carpal tunnel syndrome in long-term hemodialysis patients are higher than in the general population¹². In our case, the patient had chronic renal failure and was receiving hemodialysis with the arteriovenous fistula on the unaffected side.

With typical clinical presentation and characteristic electrophysiologic findings, the diagnosis is made in most cases¹⁶. Initially, conservative treatments such as medication and steroid injection are considered. In patients receiving long term hemodialysis, open carpal tunnel release has been considered as the operative procedure of choice because of the anatomic deterioration of the carpal tunnel tissue caused by beta-2 microglobulin amyloid deposition and the need for neurolysis of the median nerve. However, Gelberman et al.⁵ reported that neurolysis is no longer indicated for routine or severe carpal tunnel syndrome. In the current reports, long term hemodialysis patients who suffered from carpal tunnel syndrome have almost the same or better recovery rate than idiopathic patients using ECTR^{7,10,17}.

The most common complication is neuroma of the palmar cutaneous branch of the median nerve¹. Other complications are hypertrophic scar, pillar pain, scar tenderness, failure to relieve symptoms and neuromas of the dorsal sensory branch of the radial nerve^{3,8,15}. Various complications after carpal tunnel decompression have been reported. However, in our knowledge, there is only one report of an ulnar artery pseudoaneurysm after ECTR. ECTR usually demonstrates a

reduction of postoperative pain and a faster recovery of strength compared with open carpal tunnel release⁹⁾. Leon et al. reported that structural complications to nerves, arteries, or tendons are 0.19% for the endoscopic technique compared with 0.49% for the open approach²⁾. Despite the success of this procedure, complications may occur, such as incomplete release of the retinaculum, injury to the palmar branch of the median nerve and injuries to adjacent vessels¹³⁾.

Ultrasonography is widely used in the preoperative examination. Although an electrophysiologic study is the gold standard in the diagnosis, localization and typing of a nerve lesion, it may not yield enough information⁴⁾. Ultrasonography may confirm the diagnosis and offer some reliable information about the morphological status of the affected nerve and surrounding structures prior to surgery. Although we preoperatively confirmed that there were no anatomical variations or other local pathologies using ultrasonography, and postoperatively excluded complete injury of the palmar branch of the median nerve and adjacent vessels by careful observation after tourniquet release, an ulnar artery pseudoaneurysm developed. We believe this injury occurred because the ulnar artery is a mobile structure and is positioned around the median nerve. The ulnar artery runs along the ulnar border to the wrist and crosses the transverse carpal ligament on the radial side of the pisiform bone adjacent to the median nerve. We thought the injury to the ulnar artery could also be due to the endoscope, which was advanced medial to the ulnar neurovascular bundle. We thought that minimal incomplete arterial injury developed after ECTR, and hemodynamic factors might play a role in pseudoaneurysm formation in addition to amyloidosis. If there is a pulsatile mass around the operation site after ECTR, a pseudoaneurysm should be considered.

CONCLUSION

Two-portal ECTR is a safe and effective method for carpal tunnel release. However, it limits the visual field and leads to operation-related complications such as pseudoaneurysm as in this case. Also, patients with chronic renal failure are susceptible to vascular and nerve damage because of underlying pathophysiology. So, more careful procedures are needed in high risk patients.

References

1. Akhtar S, Arenas Prat J, Sinha S : Neuropraxia of the palmar cutaneous branch of the ulnar nerve during carpal tunnel decompression. *Ann R Coll Surg Engl* 87 : W1-W2, 2005
2. Benson LS, Bare AA, Nagle DJ, Harder VS, Williams CS, Visotsky JL : Complications of endoscopic and open carpal tunnel release. *Arthroscopy* 22 : 919-924, 2006
3. Boya H, Ozcan O, Oztekin HH : Long-term complications of open carpal tunnel release. *Muscle Nerve* 38 : 1443-1446, 2008
4. Cokluk C, Aydın K : Ultrasound examination in the surgical treatment for upper extremity peripheral nerve injuries : part I. *Turk Neurosurg* 17 : 277-282, 2007
5. Gilbert MS, Robinson A, Baez A, Gupta S, Glabman S, Haimov M : Carpal tunnel syndrome in patients who are receiving long-term renal hemodialysis. *J Bone Joint Surg Am* 70 : 1145-1153, 1988
6. Katz JN, Simmons BP : Clinical practice. Carpal tunnel syndrome. *N Engl J Med* 346 : 1807-1812, 2002
7. Kim SJ, Shin SJ, Kang ES : Endoscopic carpal tunnel release in patients receiving long-term hemodialysis. *Clin Orthop Relat Res* : 141-148, 2000
8. Louis DS, Greene TL, Noellert RC : Complications of carpal tunnel surgery. *J Neurosurg* 62 : 352-356, 1985
9. Mackenzie DJ, Hainer R, Wheatley MJ : Early recovery after endoscopic vs. short-incision open carpal tunnel release. *Ann Plast Surg* 44 : 601-604, 2000
10. Okutsu I, Hamanaka I, Ninomiya S, Takatori Y, Shimizu K, Ugawa Y : Results of endoscopic management of carpal-tunnel syndrome in long-term haemodialysis versus idiopathic patients. *Nephrol Dial Transplant* 8 : 1110-1114, 1993
11. Pingree MJ, Bosch EP, Liu P, Smith BE : Delayed ulnar neuropathy at the wrist following open carpal tunnel release. *Muscle Nerve* 31 : 394-397, 2005
12. Staub F, Dombert T, Assmus H : [Carpal tunnel syndrome in haemodialysis patients : analysis of clinical and electrophysiological findings in 268 patients (395 hands).] *Handchir Mikrochir Plast Chir* 37 : 150-157, 2005
13. Subasi M, Ay S, Tuzuner T : Transection of the ulnar nerve as a complication of two-portal endoscopic carpal tunnel release. *Isr Med Assoc J* 6 : 443-444, 2004
14. Thoma A, Veltri K, Haines T, Duku E : A systematic review of reviews comparing the effectiveness of endoscopic and open carpal tunnel decompression. *Plast Reconstr Surg* 113 : 1184-1191, 2004
15. Uygur F, Sever C, Yüksel F : Comparing the results of limited incision technique and standard longitudinal incision technique for carpal tunnel decompression by numerical grading system. *Turk Neurosurg* 19 : 51-57, 2009
16. Vogt T, Mika A, Thömke F, Hopf HC : Evaluation of carpal tunnel syndrome in patients with polyneuropathy. *Muscle Nerve* 20 : 153-157, 1997
17. Yoshida A, Okutsu I, Hamanaka I, Motomura T : Results of endoscopic management of primary versus recurrent carpal tunnel syndrome in long-term haemodialysis patients. *Hand Surg* 9 : 165-170, 2004