

## Clinical Article

# Comparison of Fusion with Cage Alone and Plate Instrumentation in Two-Level Cervical Degenerative Disease

Yong-Hun Joo, M.D., Jong-Won Lee, M.D., Ki-Young Kwon, M.D., Jong-Joo Rhee, M.D., Hyun-Koo Lee, M.D.

Department of Neurosurgery, Cheongju St. Mary's Hospital, Cheongju, Korea

**Objective :** This study assessed the efficacy of anterior cervical discectomy and fusion (ACDF) with cage alone compared with ACDF with plate instrumentation for radiologic and clinical outcomes in two-level cervical degenerative disease.

**Methods :** Patients with cervical degenerative disc disease from September 2004 to December 2009 were assessed retrospectively. A total of 42 patients received all ACDF at two-level cervical lesion. Twenty-two patients who underwent ACDF with cage alone were compared with 20 patients who underwent ACDF with plate fixation in consideration of radiologic and clinical outcomes. Clinical outcomes were assessed using Robinson's criteria and posterior neck pain, arm pain described by a 10 point-visual analog scale. Fusion rate, subsidence, kyphotic angle, instrument failure and the degenerative changes in adjacent segments were examined during each follow-up examination.

**Results :** VAS was checked during each follow-up and Robinson's criteria were compared in both groups. Both groups showed no significant difference. Fusion rates were 90.9% (20/22) in ACDF with the cage alone group, 95% (19/20) in ACDF with the plate fixation group ( $p = 0.966$ ). Subsidence rates of ACDF with cage alone were 31.81% (7/22) and ACDF with plate fixation were 30% (6/20) ( $p = 0.928$ ). Local and regional kyphotic angle difference showed no significant difference. At the final follow-up, adjacent level disease developed in 4.54% (1/22) of ACDF with cage alone and 10% (2/20) of ACDF with plate fixation ( $p = 0.654$ ).

**Conclusion :** In two-level ACDF, ACDF with cage alone would be comparable with ACDF with plate fixation with regard to clinical outcome and radiologic result with no significant difference. We suggest that the routine use of plate and screw in 2-level surgery may not be beneficial.

**KEY WORDS :** ACDF with cage alone · ACDF with plate fixation · Fusion rate · Subsidence · Adjacent level degeneration.

## INTRODUCTION

Cervical spondylosis usually arises in the disc, e.g., disc herniation, osteophyte formation at end plates, and uncovertebral joints. Anterior approaches to the cervical disc provide direct decompression. In the past few years, anterior cervical discectomy and fusion (ACDF) is currently the gold standard for surgical treatment of degenerative disc disease of the cervical spine<sup>6,17,18</sup>. Relatively good results have been reported with performing ACDF with cage alone<sup>21</sup>. However, controversy remains with regard to fusion rate, subsidence, pseudoarthrosis compared to plate augmentation in ACDF<sup>10,15</sup>.

In clinical aspects, multilevel ACDF, especially two-level ACDF, was usually performed in the cervical degenerative disease. However, a few studies were reported in two-level ACDF with cage alone regarding to ACDF with plate fixation.

In our study, we performed ACDF with cage alone and plate augmentation in an attempt to compare the outcome between two groups. We compared and analyzed the radiologic and clinical outcomes of ACDF with cage alone and ACDF with plate augmentation for their surgical treatments of two-level degenerative cervical disease to evaluate the efficacy of ACDF with cage alone.

## MATERIALS AND METHODS

### Materials

Patients who presented to our hospital from September 2004 to December 2009 with cervical degenerative disc disease were included retrospectively. Patients were randomly selected

• Received : August 18, 2010 • Revised : October 8, 2010

• Accepted : October 11, 2010

• Address for reprints : Yong-Hun Joo, M.D.

Department of Neurosurgery, Cheongju St. Mary's Hospital,

589-5 Jujung-dong, Sangdang-gu, Cheongju 360-568, Korea

Tel : +82-43-219-8467, Fax : +82-43-211-7925

E-mail : organelle1@naver.com

based on timing of their presentation to our institution. No specific guidelines or indications were used in dividing the patients among two groups. Subjects were divided into two groups based on whether or not plate augmentation was used. Subjects with less than 6 months of follow-up following ACDF with cage alone or ACDF with plate fixation were excluded from this study. All patients had anterior cervical discectomy and fusion for two level cervical degenerative disc disease by the Smith-Robinson methods. Twenty-two patients received ACDF with cage alone and 20 patients received ACDF with plate fixation in two-level cervical lesion (Table 1). In one patient, autologous iliac bone graft was used in ACDF with cage alone group. Solis™ cage was used in other 21 patients. In ACDF with plate fixation group, autologous iliac bone graft was used in two patients. Solis™ cage was used in other 18 patients. And, Maxima plate was used in all patients received plate fixation. Regarding surgical level, in ACDF with cage alone, there were 7 C4-6, 14 C5-7, 1 C3-5. In ACDF with plate fixation, there were 6 C4-6, 12 C5-7, 2 C3-5. In both groups, C5-7 was most prevalent. The mean age of ACDF with cage alone was 59.09 (38-75) years and ACDF with plate augmentation was 54.33 (33-73) years. ACDF with cage alone group consisted of 15 males and 7 females (Table 1). ACDF with plate fixation consisted of 13 males and 7 females. The mean follow-up period of ACDF with cage alone group was 15.7 (6-30) months, while that of ACDF with plate fixation group was 16.2 (6-47) months (Table 1).

## Methods

To correlate the clinical symptoms, preoperative magnetic resonance imaging was carried out to determine the levels of surgery. Clinical and radiologic follow-up was performed immediately, 1 month, 3 months, 6 months, 9 months, 12 months, and 24 months after surgery. The presence or absence of bone fusion, subsidence, instrument failure, kyphotic angle and the degenerative changes in adjacent segments were examined using antero-posterior, lateral and flexion-extension lateral plain radiographs. The plain radiographs were obtained during each follow-up examination. CT scans were used as a secondary measure when fusion was not uncertain at plain radiographs or complicated clinical symptoms developed. Assessment of fusion status was conducted by an inde-

pendent radiologist.

Fusion was defined as no lucency between the graft and the vertebral body and evidence of remodeling. It may exhibit bridging trabecular bone between the endplates on antero-posterior, and lateral views. There were no signs of implant failures of the anterior plate system<sup>3,13</sup>.

Subsidence was defined as a change in interbody space of at least 3 mm. Distance of interbody space was measured as total vertical height of two fused bodies between the midpoint of the upper margin of the upper vertebral body and the lower margin of the lower vertebral body on lateral plain radiographs<sup>1,10</sup>. We decided the subsidence as the change of the total vertical height of two fused bodies in each surgical level.

Radiological assessment involved plain X-ray film assessment of local kyphotic angle, regional kyphotic angle. Local and regional kyphotic angles were determined on lateral cervical radiographs. Local kyphotic angle was defined as the angle formed between the lines drawn parallel to the upper endplate of the most cranial vertebra and the lower endplate of the most caudal vertebra at surgical level. The regional kyphotic angle was defined as the angle formed by the lines drawn parallel to the upper endplate of C3 and the lower endplate of C7.

Adjacent level degeneration was determined using the modified hilibrand criteria<sup>12</sup>. Adjacent level disease was divided depending on the presence of a decrease in disc height and posterior osteophyte formation. Radiographs at different time points were compared to preoperative plain radiographs.

Based on pain severity, need for medications, work status, and activity level, clinical outcomes were assessed using Robinson's criteria and using posterior neck pain, arm pain described by 10 point-visual analog scale (Fig. 1)<sup>19</sup>. Postoperative complication and symptomatic changes were assessed by reviewing the subjects' medical records. A statistician reviewed the data, using the Mann-whitney tests and chi-squared tests. All statistical analyses was performed using SPSS and statistical significance was defined as  $p < 0.05$ .

## RESULTS

Robinson's criteria and VAS were used to evaluate the clinical outcomes during the final follow-up examination. Using Robinson's criteria, the outcomes with a grade better than 'good' totaled 19/22 (86.36%) in ACDF with cage alone and 17/20 (85%) in ACDF with plate fixation (Table 2) ( $p = 0.480$ ). No significant difference was found.

In both groups, most of all patients' clinical symptoms such as posterior neck

**Table 1.** Demographic data

	ACDF with cage alone	ACDF with plate fixation
No. of cases	22 pts	20 pts
Male	15 pts	13 pts
Female	7 pts	7 pts
Mean age (years)	59.09 (38-75)	54.33 (33-73)
Mean F/U (months)	15.7 (6-30)	16.2 (6-47)

pain, arm pain were improved compared with preoperative symptoms. VAS was checked at each follow-up (Fig. 1). Mean preoperative VAS was scored 7.95 in ACDF with cage alone and 7.8 in ACDF with plate fixation. Twelve month follow-up VAS was scored 2.6 in ACDF with cage alone and 3 in ACDF with plate fixation. VAS difference was 0.4. In both groups, VAS difference between preoperative VAS and final

follow-up VAS was not significantly distinctive ( $p = 0.395$ ).

At final follow up, the fusion rates were 90.9% (20/22) in the ACDF with cage alone group, 95% (19/20) in the ACDF with plate fixation group (Fig. 2). In the fusion rates between both groups, there was no significant difference (Table 3) ( $p = 0.966$ ).

Subsidence occurred in 31.81% (7/22) of ACDF with cage alone and in 30% (6/20) of ACDF with plate fixation. There was likewise no statistically significant difference ( $p = 0.928$ ) (Table 3).

There was improvement in the local kyphotic angle following surgery in both groups. In ACDF with cage alone group, preoperative local kyphotic mean angle was 1.36° (range -2° to 4°). At the final follow-up, postoperative local kyphotic mean angle was -4.36° (range -7° to -1°). In ACDF with plate fixation group, preoperative local kyphotic mean angle was 1.30° (range 0° to 3°). At the final follow-up, postoperative local kyphotic mean angle was -4.20° (range -6° to -1°). Kyphotic angle change between preoperative local kyphotic angle and final follow-up local kyphotic angle was not significantly distinctive ( $p = 7.524$ ) (Table 4).

In ACDF with cage alone group, preoperative regional kyphotic mean angle was 1.52° (range -3° to 4°). At the final follow-up, postoperative regional kyphotic mean angle was -4.71° (range -9° to -2°). In ACDF with plate fixation group, preoperative regional kyphotic mean angle was 1.40° (range -1° to 6°). At the final follow-up, postoperative regional kyphotic mean angle was -4.63° (range -8° to -2°). Kyphotic angle difference between preoperative regional kyphotic angle and final follow-up regional kyphotic angle was not significantly distinctive ( $p = 6.985$ ) (Table 4).

In ACDF with plate fixation, hardware related complication, such as screw back out or plate loosening, was developed in 1 case. Because associated symptoms did not manifest, revision surgery was not performed. Anterior migration or displacement of the cage,

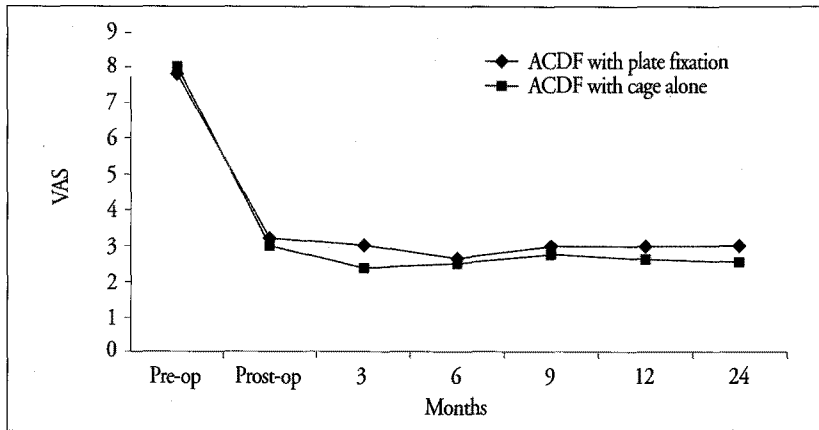


Fig. 1. The mean posterior neck and arm pain VAS of both groups before surgery and at the different follow-up intervals.

Table 2. Robinson's clinical outcome assessment

	ACDF with cage alone	ACDF with plate fixation	p-value
Excellent	5 pts	4 pts	
Good	14 pts	13 pts	
Fair	2 pts	2 pts	
Poor	1 pt	1 pt	
> Good	19 (86.36%)	17 (85%)	0.480

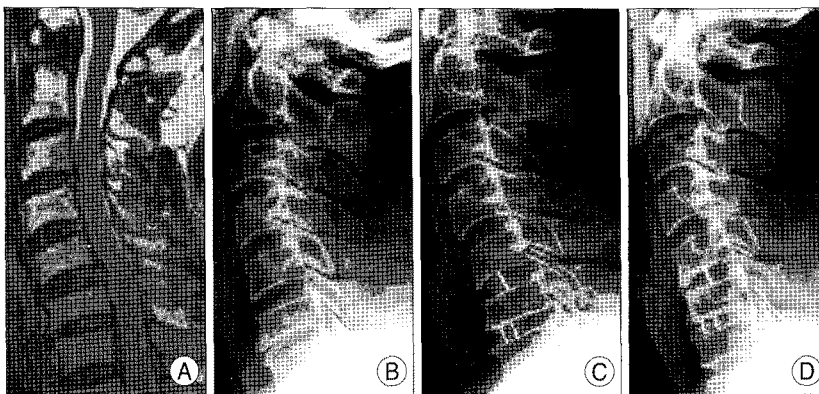


Fig. 2. A : Pre-operative magnetic resonance (MR) image shows disc herniation at C5-6 and C6-7. B : Pre-operative simple lateral radiograph. C : Postoperative simple lateral radiograph immediately shows ACDF, C5-6 & C6-7 with Solis cage. D : Simple lateral radiograph at two years postoperative shows fusion state without subsidence and adjacent level degeneration.

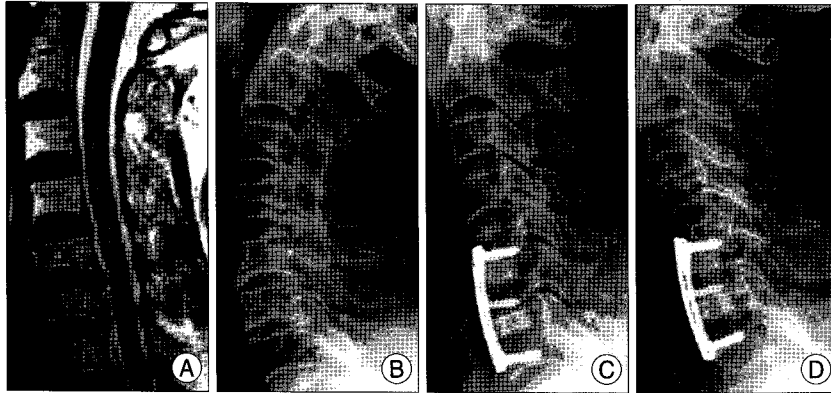
Table 3. Radiologic results

	ACDF with cage alone (n=22)	ACDF with plate fixation (n=20)	p-value
Fusion rate	20 (90.9%)	19 (95%)	0.966
Subsidence	7 (31.81%)	6 (30%)	0.928
ALD	1 (4.54%)	2 (10%)	0.654

ALD : adjacent level disease

**Table 4.** Local kyphotic angle and regional kyphotic angle

Mean angle	ACDF with cage alone	ACDF with plate fixation
Pre-Op. (Local)	1.36° (range -2° to 4°)	1.30° (range 0° to 3°)
Post-Op. (Local)	-4.36° (range -7° to -1°)	-4.20° (range -6° to -1°)
Pre-Op. (Regional)	1.52° (range -3° to 4°)	1.40° (range -1° to 6°)
Post-Op. (Regional)	-4.71° (range -9° to -2°)	-4.63° (range -8° to -2°)



**Fig. 3.** A : Pre-operative magnetic resonance (MR) image shows disc herniation at C5-6 & C6-7. B : Pre-operative simple lateral radiograph. C : Postoperative simple lateral radiograph immediately shows ACDF, C5-6 & C6-7 with plate fixation. D : Simple lateral radiograph at six months postoperative shows anterolisthesis at C4-5.

pseudoarthrosis was not developed in any cases of both two groups. Swallowing difficulty occurred in 2 cases of the ACDF with plate fixation group only (2/20). Revision operation was not necessary in these patients. At the final follow-up, adjacent level disease developed in 4.54% (1/22) of ACDF with cage alone and 10% (2/20) of ACDF with plate fixation ( $p = 0.654$ ) (Table 3) (Fig. 3). There was no significant difference. All cases did not require any additional procedure.

## DISCUSSION

ACDF has been widely used as a surgical treatment for degeneration of the cervical spine. However, there still remains a controversy on which procedure yields the best clinical outcome : ACD alone, ACDF, or discectomy with intervertebral fusion and instrumentation. A recent prospective randomized study comparing ACD, ACDF and ACF with instrumentation in patients with cervical disc disease showed no significant differences in clinical outcome at 2-year follow-up<sup>23</sup>.

Some authors reported lesser graft dislocations and graft collapse and higher fusion rates after ACDF with internal fixation compared with ACDF<sup>5,8,9,22,24</sup>. Some spine surgeons have reported poor outcomes and fusion rates secondary to a high rate of cage subsidence, pseudoarthrosis<sup>14,16</sup>. They believed that this phenomenon occurred as a result of insufficient fixation power of cage alone. This may indicate lack of a strong fixation force in ACDF with cage alone, allowing postoperative micromotions to continuously occur between

the contact surface of the cage and vertebra. These continuous micromotions prevent the induction of bone fusion<sup>1,14,16</sup>. In two-level cervical disc disease, some studies suggested that ACDF with internal fixation improves fusion and outcome of two-level fusion when compared with single level procedure<sup>2-4,7</sup>.

On the other hand, our experience has shown us that there was no statistically significant difference between ACDF with cage alone and ACDF with plate fixation in fusion rates, subsidence rates and kyphotic angle changes. The fusion rates in ACDF with the cage alone group were 90.9% compared to 95% in ACDF with plate fixation group (Table 3). In the same manner, the subsidence in ACDF with cage alone occurred 31.81% compared to

30% in ACDF with plate fixation groups (Table 3). As a matter of course, there were no statistically significant difference. In local and regional kyphotic angle difference between both groups, there were no significant differences. Furthermore, there was no significant difference between clinical outcomes. On the contrary, swallowing difficulty (2/20) and hardware related complication was developed in ACDF with plate fixation.

In both groups, posterior neck pain, arm pain, and other neurologic symptoms were relieved when compared to preoperative symptoms at final follow-up. In fact, some studies showed the clinical outcomes had no significant difference between ACDF with cage alone and ACDF with plate fixation, although plate fixation showed better radiologic result than ACDF with cage alone<sup>23</sup>.

Additionally, adjacent level disease was slightly more prevalent with ACDF with plate fixation than with ACDF with cage alone. However, this was not statistically significant. ACDF and ACDF with plate fixation reduce segmental motion and cause heightened stress on the discs below and above the fusion, which in turn may induce adjacent level degeneration. In ACDF with plate fixation, this may be due to the increased fixation force provided by the additional plate augmentation, increasing the level of stress generated in adjacent intervertebral discs during cervical vertebral motion after surgery<sup>20</sup>.

In consideration of these things and our study, ACDF with cage alone was favorably comparable with ACDF with plate fixation. Also, ACDF cage alone has the advantage of shorter

operation time, minimal blood loss, and relative simplicity of procedure when compared to ACDF with plate fixation.

The short follow-up period and small subject size from our study do not allow a thorough evaluation. Therefore, long-term follow-up and large designed studies are necessary. Another weakness of this study is that it is retrospective. A prospective randomized study is required in the future.

## CONCLUSION

In two-level ACDF in particular, ACDF with cage alone would be comparable with ACDF with plate fixation in terms of clinical outcome and radiologic results. In our study, ACDF with cage alone yielded insignificantly distinctive clinical symptoms such as posterior neck pain, arm pain and outcome impairing complication. Also, in the radiologic results such as fusion, subsidence and adjacent level disease, there were no significant difference between both groups. We suggest that the routine use of plate and screw in 2-level surgery may not be of benefit and that it may add a potentially unnecessary expense.

## References

1. Barsa P, Suchomel P : Factors affecting sagittal malalignment due to cage subsidence in standalone cage assisted anterior cervical fusion. *Eur Spine J* 16 : 1395-1400, 2007
2. Bohlman HH, Emery SE, Goodfellow DB, Jones PK : Robinson anterior cervical discectomy and arthrodesis for cervical radiculopathy. Long-term follow-up of one hundred and twenty-two patients. *J Bone Joint Surg Am* 75 : 1298-1307, 1993
3. Bolesta MJ, Rehtine GR 2nd, Chrin AM : One- and two-level anterior cervical discectomy and fusion : the effect of plate fixation. *Spine J* 2 : 197-203, 2002
4. Cauthen JC, Kinard RE, Vogler JB, Jackson DE, DePaz OB, Hunter L, et al. : Outcome analysis of noninstrumented anterior cervical discectomy and interbody fusion in 348 patients. *Spine (Phila Pa 1976)* 23 : 188-192, 1998
5. Cho DY, Lee WY, Shew PC : Treatment of multilevel cervical fusion with cages. *Surg Neurol* 62 : 378-385; discussion 385-386, 2004
6. Cloward RB : The anterior approach for removal of ruptured cervical disc. *J Neurosurg* 15 : 602-617, 1958
7. Emery SE, Fisher JR, Bohlman HH : Three-level anterior cervical discectomy and fusion : radiographic and clinical results. *Spine (Phila Pa 1976)* 22 : 2622-2625, 1997
8. Fountas KN, Kapsalaki EZ, Nikolakakos LG, Smisson HF, Johnston KW, Grigorian AA, et al. : Anterior cervical discectomy and fusion associated complications. *Spine (Phila Pa 1976)* 32 : 2310-2317, 2007
9. Fraser JF, Härtl R : Anterior approaches to fusion of the cervical spine : a metaanalysis of fusion rates. *J Neurosurg Spine* 6 : 298-303, 2007
10. Ha SK, Park JY, Kim SH, Lim DJ, Kim SD, Lee SK : Radiologic Assessment of subsidence in Stand-Alone Cervical Polyetheretherketone (PEEK) cage. *J Korean Neurosurg Soc* 44 : 370-374, 2008
11. Hacker RJ : Threaded cages for degenerative cervical disease. *Clin Orthop Relat Res* : 39-46, 2002
12. Hilibrand AS, Carlson GD, Palumbo MA, Jones PK, Bohlman HH : Radiculopathy and myelopathy at segments adjacent to the site of a previous anterior cervical arthrodesis. *J Bone Joint Surg Am* 81 : 519-528, 1999
13. Kandziora F, Pflugmacher R, Scholz M, Schnake K, Putzier M, Khodadadyan-Klostermann C, et al. : Treatment of traumatic cervical spine instability with interbody fusion cages : a prospective controlled study with a 2-year follow-up. *Injury* 36 Suppl 2 : B27-B35, 2005
14. Kast E, Derakhshani S, Bothmann M, Oberle J. : Subsidence after anterior cervical interbody fusion. A randomized prospective clinical trial. *Neuro-surg Rev* 32 : 207-214; discussion 214, 2009
15. Majd ME, Vadhva M, Holt RT : Anterior cervical reconstruction using titanium cages with anterior plating. *Spine (Phila Pa 1976)* 24 : 1604-1610, 1999
16. Resnick DK, Trost GR : Use of Ventral plate for cervical arthrodesis. *Neurosurgery* 60 : 112-117, 2007
17. Robinson RA, Smith GW : Anterolateral cervical disc removal and interbody fusion for cervical disk syndrome. *Bull Johns Hopkins Hosp* 96 : 223-224, 1955
18. Smith GW, Robinson RA : The treatment of certain cervical-spine disorders by anterior removal of the intervertebral disc and interbody fusion. *J Bone Joint Surg Am* 40-A : 607-624, 1958
19. Robinson RA, Walker AE, Ferlic DC, Wiecking DK : The results of anterior interbody fusion of cervical spine. *J Bone Joint Surg* 44-A : 1569-1587, 1962
20. Song KJ, Kim GH, Choi BW, Lee KB : Does Plate Construct improve the result of 1- or 2-level anterior cervical fusion? *Neurosurg Q* 18 : 172-177, 2008
21. Varruch L, Hedlund R, Javid D, Leszniewski W, Shalabi A : A prospective randomized comparison between the cloward procedure and a carbon fiber cage in the cervical spine : a clinical and radiologic study. *Spine (Phila Pa 1976)* 27 : 1694-1701, 2002
22. Wang JC, McDonough PW, Endow KK, Delamarter RB : Increased fusion rates with cervical plating for two-level anterior cervical discectomy and fusion. *Spine (Phila Pa 1976)* 25 : 41-45, 2000
23. Xie JC, Hurlbert RJ : Discectomy versus discectomy with fusion versus discectomy with fusion and instrumentation : a prospective randomized study. *Neurosurgery* 61 : 107-116; discussion 116-117, 2007
24. Zoëga B, Kärrholm J, Lind B : Plate fixation adds stability to two-level anterior fusion in the cervical spine : a randomized study using radiostereometry. *Eur Spine J* 7 : 302-307, 1998