

## Clinical Article

# Laparotomy versus Laparoscopic Placement of Distal Catheter in Ventriculoperitoneal Shunt Procedure

Young Seop Park, M.D., In Sung Park, M.D., Kyung Bum Park, M.D., Chul Hee Lee, M.D., Soo Hyun Hwang, M.D., Jong Woo Han, M.D.

Department of Neurosurgery, Gyeongsang National University School of Medicine, Jinju, Korea

**Objective :** Traditionally, peritoneal catheter is inserted with midline laparotomy incision in ventriculoperitoneal (V-P) shunt procedures. Complications of V-P shunt is not uncommon and have been reported to occur in 5-37% of cases. The aim of this study is to compare the clinical outcomes and the operation time between laparotomy and laparoscopic groups.

**Methods :** A total of 155 V-P shunt procedures were performed to treat hydrocephalic patients of various origins in our institute between June 2006 to January 2010; 95 of which were laparoscopically guided and 65 were not. We reviewed the operation time, surgery-related complications, and intraoperative and postoperative problems.

**Results :** In the laparoscopy group, the mean duration of the procedure (52 minutes) was significantly shorter ( $p < 0.001$ ) than the laparotomy group (109 minutes). There were two cases of malfunctions and one incidence of diaphragm injury in the laparotomy group. In contrast, there were neither malfunction nor any internal organ injuries in the laparoscopy group ( $p = 0.034$ ). There were total of two cases of infections from both groups ( $p = 0.7$ ).

**Conclusion :** Laparoscopically guided insertions of distal shunt catheter is considered a fast and safe method in contrast to the laparotomy technique. This method allows the exact localization of the peritoneal catheter and a confirmation of its patency.

**KEY WORDS :** Hydrocephalus · Laparoscopy · Peritoneal catheter.

## INTRODUCTION

A number of techniques have been described for the treatment of hydrocephalus. Ventriculoperitoneal (V-P) shunt is the preferred procedure for treating hydrocephalus of various etiologies in children and adults.

Laparoscopy-assisted distal shunt catheter placement was first described in 1993<sup>2)</sup>. Traditionally, the peritoneal portion involves a small midline incision.

Complications from the traditional V-P shunt placement is not uncommon and have been reported to occur in 5-37% of the cases<sup>1,6,7,24,31,32)</sup>.

Laparoscopy-assisted techniques have greatly reduced these potential morbidities through direct visualization of the peritoneal cavity, as well as the risk of incisional hernia after lapa-

rotomy<sup>4,5,9,16-19,26,27,30)</sup>. This study focuses on the following results of laparoscopically guided implantation of a distal catheter compared to the laparotomy group : the operation time, intra-operative and extra-operative problems.

## MATERIALS AND METHODS

### Patient population

A total of 155 V-P shunt procedures were performed for the treatment of hydrocephalus of various origins between June 2006 to January 2010, 95 consecutive patients of which were laparoscopically guided, whereas 65 patients were not (Table 1). The operations for each group were performed by two neurosurgeons at a single institute. The data of the patients were retrospectively collected from their medical records and follow-up notes in order to assess the operation time, intra-operative and post-operative problems.

### Technical aspects

Laparotomy shunt procedures were performed by a neurosurgical resident and a senior neurosurgeon. Laparoscopy-

• Received : April 19, 2010 • Revised : September 22, 2010

• Accepted : October 5, 2010

• Address for reprints : In Sung Park, M.D.

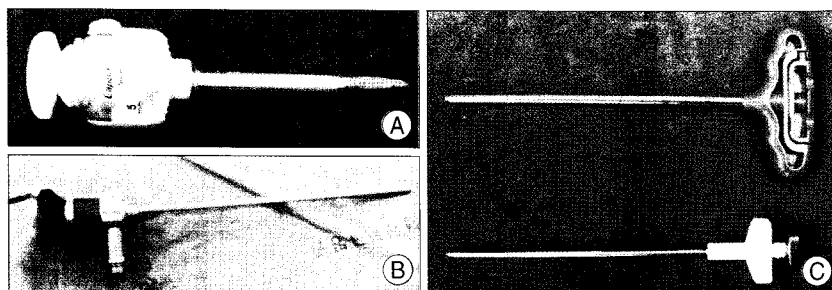
Department of Neurosurgery, Gyeongsang National University School of Medicine, 90 Chiram-dong, Jinju 660-702, Korea

Tel : +82-55-750-8018, Fax : +82-55-759-0817

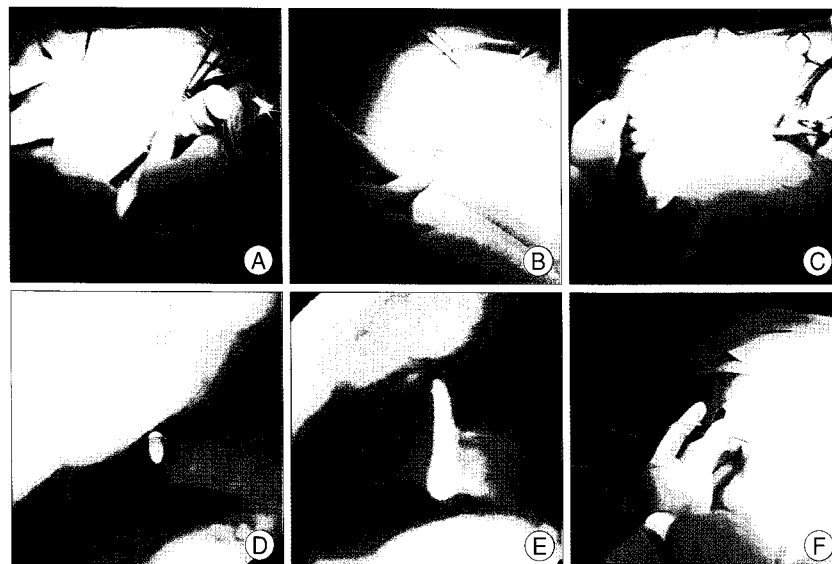
E-mail : gnuhps@nongae.gsnu.ac.kr

**Table 1.** Indications for V-P shunt procedure

Indication	No. of patients (%)	
	Laparotomy (n = 65)	Laparoscopy (n = 95)
Aneurysmal SAH	38 (58.46)	62 (65.26)
Normal pressure hydrocephalus	12 (18.46)	13 (13.68)
Intracerebral ventricular hemorrhage	9 (13.85)	11 (11.58)
Posttraumatic hydrocephalus	3 (4.62)	5 (5.26)
Tumor-related hydrocephalus	1 (1.54)	1 (1.05)
Shunt malfunction	1 (1.54)	2 (2.10)
Post infection	1 (1.54)	1 (1.05)



**Fig. 1.** Instruments that are used for laparoscopic placement of peritoneal catheter. A : 5 mm trochar. B : 30° angled laparoscope. C : Various vertebroplasty needle.



**Fig. 2.** Key steps in the laparoscopic placement of peritoneal catheter. A : 5 mm trochar and laparoscope are inserted after 1 cm incision was made below the umbilicus. B : 5 mm incision is made below the xyphoid process upon inflation with CO<sub>2</sub> gas. C : Vertebroplasty needle is inserted under the guidance of laparoscope. D : After inserting the needle, laparoscope is used to localize it. E : The catheter is placed in a required position through the needle. F : Vertebroplasty needle is removed.

assisted shunt procedures were performed by a neurosurgical resident and a senior neurosurgeon in collaboration with a resident from department of general surgery, experienced in laparoscopic procedures from the initial 30 cases and the operations on the last 65 cases were performed by two neurosurgeons. Patients were anesthetized and placed in the supine position for the V-P shunt procedures. The laparoscopic part of the operation was performed simultaneously with the procedure of the cranial component.

**Procedure description**

A curve-linear paraumbilical 10 mm incision was made. The peritoneum was punctured directly with a veress needle. Through the needle, pneumoperitoneum was created up to 10 mmHg, with carbon dioxide gas. After removing the veress needle, a five millimeter trocar was inserted and a 30 degree five millimeter laparoscope was introduced into the peritoneal cavity (Fig. 1, 2A). The intra-peritoneal cavity was inspected and a site along the subcostal region was chosen for intra-abdominal catheter insertion. A five millimeter vertical skin incision was made and under the direct vision the peritoneum was punctured with vertebroplasty needle (Fig. 1C, 2B, C). Peritoneal catheter was inserted via the vertebroplasty needle and guided toward the left lower abdominal portion under videoscopic inspection (Fig. 2D, E). After catheter was introduced through the needle into the peritoneal cavity about 20 cm, vertebroplasty needle was carefully removed (Fig. 2F). After drawing out the needle, the peritoneum was deflated.

After traversing a malleable tunneler (65 cm long) from the subcostal incision through the subcutaneous tissue to the retroauricular area, the cranial part of catheter was placed at retroauricular area. The pressure of cerebrospinal fluid (CSF) was examined after the deflating the peritoneum in order to avoid the deleterious effects of increased abdominal pressure on the intracranial pressure<sup>14,22,25</sup>.

After connecting the valve with peritoneal and ventricular catheter, pneumoperitoneum was recreated. The flow of CSF was confirmed under the laparoscopic observation (Fig. 3). Following the desufflation, the trocar was removed. Neither incision required fascial closure while two small incisions were closed absorbable intracutaneous stitches.

**RESULTS**

In the laparoscopy group (52 minutes), the mean proce-

duration, defined as the time from initial incision to final dressing placement, was significantly shorter ( $p < 0.001$ , Student's *t*-test) than the laparotomy group (109 minutes) (Table 2).

There were two cases of malfunctions and one incidence of diaphragm injury in the laparotomy group. In contrast, there were neither malfunction nor internal organ injuries in the laparoscopy group. Lower incidence of malfunction and internal organ injuries were shown in the laparoscopy group (0%) compare to the laparotomy group (3.08%) ( $p = 0.034$ , Student's *t*-test).

There were total of two cases of infections from both groups, which showed no statistically significant differences ( $p = 0.7$ , Student's *t*-test).

## DISCUSSION

Traditionally, laparotomy procedures were performed despite its inherent disadvantages of postoperative pain, wound infection and hernia formations<sup>9</sup>. The ideal implantation method involves minimal trauma such as negative postoperative ileus or late intraabdominal adhesions and easy access in catheter insertions even in cases of postoperative peritoneal adhesions. The laparoscopic method fulfills all these criteria. The abdominal wall is minimally incised and its closure is usually possible with a single stitch, thus minimizing the postoperative pain. Furthermore, the cosmetic satisfaction is excellent without any risk of incisional hernias.

One third of all shunt failures are thought to be due to malfunction of the distal catheter which may be caused by dislocation or obstruction or migration into the anterior abdominal wall<sup>8,20</sup>. The distal failure rate may be higher in patients with abdominal adhesions, obesity, or scoliosis<sup>17</sup>.

A strong advantage of laparoscopically guided catheter insertion lies in its ability to insert the catheter correctly without failure<sup>12</sup>. Furthermore, it is possible to check the flow of CSF into the peritoneal cavity by giving vertical pressures on the reservoir<sup>17</sup>. Upon finishing all the procedures, the passing of the CSF has failed in one patient in which a malposition of the ventricular catheter was identified and its location was corrected. Hence, a reoperation was not necessary. The ability to visualize the entire peritoneal cavity also allows the retrieval of foreign bodies, lysis of adhesions and culturing of abdominal fluid. Also, the lysis of adhesions may decrease the need for pleural or atrial shunts<sup>10-13,25,28,29</sup>.

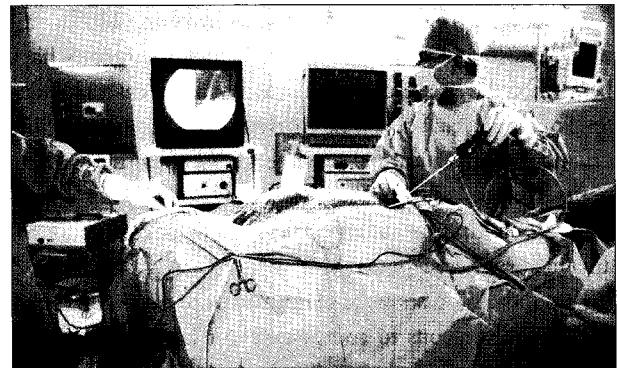
**Table 2.** Comparison of results between laparoscopic and nonlaparoscopic groups

Parameter	Surgical Group	
	Laparotomy (n = 65)	Laparoscopy (n = 95)
Gender (male : female)	28 : 37	40 : 55
Mean duration of operation (minutes)	109 (45-175)	52 (25-85)
Mean follow-up duration	20 (2-45)	27 (6-45)
Complication (no. of cases)	5 (7.69%)	2 (2.11%)
Infection	2 (3.08%)	2 (2.11%)
Malfunction	2 (3.08%)	0 (0%)
Organ injury	1 (1.54%)	0 (0%)
	(Diaphragm)	

**Table 3.** Usage of laparoscopy in patients with positive abdominal surgery

Previous abdominal pathology	Intraoperative findings	Outcome
Shunt malfunction	No adhesions	Good
Shunt infection	Adhesions	Good
Appendectomy	No adhesions	Good
Appendectomy	Adhesions	Good
Laparoscopic cholecystectomy	Adhesions	Good
Conventional cholecystectomy	Adhesions	Good
Gastrectomy (EGC)	Adhesions	Good

EGC : early gastric cancer



**Fig. 3.** Vertical pressure is given to the reservoir to check the patency of CSF flow at the end of V-P shunt procedure.

In all patients, the insertion of the catheter within the abdominal cavity was performed with only one veress needle and one laparoscope with five millimeter trocar. However, one patient had an additional five millimeter port and dissecting forceps to tract the tube in order to correct the insertion difficulty. This problem was corrected by inserting the veress needle in the abdominal wall with a widened insertion margin. Seven patients with previous abdominal operations and four severely obese patients showed no difficulty in distal catheter insertions (Table 3).

Ochalski et al.<sup>23</sup> have introduced a modified percutaneous insertion technique which is a variation of a similar technique initially described by Lockhart et al.<sup>23</sup>. They have used a percutaneous (Veress needle and Peel-Apart introducer) minimal-access technique as the first-line approach for the distal intraperitoneal catheter insertions. Retrospective analy-

sis of 100 cases of distal catheter minimal-access insertion showed 91 patients had neither distal catheter misplacements nor any internal organ injuries from the insertion of Veress needle or Peel-Apart Percutaneous Introducer. However, procedural changes were made in the remaining 9 cases, where an open mini-laparotomy or laparoscopically assisted insertion were carried out. Also, the total rate of shunt system revision secondary to malfunction was 17%.

Lockhart et al.<sup>21)</sup> have used the Veress needle to establish peritoneal access which was then replaced with a peel-away sheath using a guide-wire exchange technique. Distal catheter insertion was performed in a similar fashion, however, gas insufflation was not used to establish pneumoperitoneum.

At the beginning of the study, we used peel-off needles that were introduced in other reports<sup>3,12,21,23)</sup>. However, there were cases of catheter breakage provoked by the split edges on the needle. Instead, vertebroplasty needles were used and such problems were resolved with much success. It is postulated that the reason for the shortening of the procedure duration is due to shortened catheter insertion time and the assurance of a successful intraabdominal placements.

Turner et al.<sup>30)</sup> have published a series involving 113 laparoscopy-assisted shunt placements. General surgeons have performed the laparoscopy in all cases and any cases of shunt revisions were excluded. The mean age of their patients was 66 and 80% had normal-pressure hydrocephalus. They reported the one year shunt survival rate to be 91%. It is important to note that no catheter migration or disconnection or any fractures were reported<sup>30)</sup>.

The initial 30 cases were performed with some help from the general surgeons to compensate our lack of experience. However, recently, only two neurosurgeons are required for the operation and much shortened procedure duration has been achieved. Other studies report a relatively higher infection rates in concurrent operations with the general surgeons<sup>15)</sup>. However, our study showed no statistically significant differences.

Current medical fee for the laparoscopically guided V-P shunt has not been settled by the Health Insurance Review & Assessment Service, and hence its cost is identical to the laparotomy method.

## CONCLUSION

Laparoscopically guided insertions of distal shunt catheter is considered as fast and safe method with more advantages than the laparotomy technique. This method allows the exact localization of the peritoneal catheter and confirmation of its patency.

Laparoscopically guided surgeries are neglected in the

neurosurgical field due to its unfamiliarity. However, it is an uncomplicated method which does not require help from the general surgeons.

## References

1. Abu-Dalu K, Pode D, Hadani M, Sahar A : Colonic complications of ventriculoperitoneal shunts. *Neurosurgery* 13 : 167-169, 1983
2. Armbruster C, Blauensteiner J, Ammerer HP, Kriwanek S : Laparoscopically assisted implantation of ventriculoperitoneal shunts. *J Laparoendosc Surg* 3 : 191-192, 1993
3. Bani A, Telker D, Hassler W, Grundlach M : Minimally invasive implantation of the peritoneal catheter in ventriculoperitoneal shunt placement for hydrocephalus : analysis of data in 151 consecutive adult patients. *J Neurosurg* 105 : 869-872, 2006
4. Basauri L, Selman JM, Lizana C : Peritoneal catheter insertion using laparoscopic guidance. *Pediatr Neurosurg* 19 : 109-110, 1993
5. Box JC, Young D, Mason E, Angood P, Yancey M, Schiess R, et al. : A retrospective analysis of laparoscopically assisted ventriculoperitoneal shunts. *Surg Endosc* 10 : 311-313, 1996
6. Bryant MS, Bremer AM, Tepas JJ 3rd, Mollitt DL, Nguyen TQ, Talbert JL : Abdominal complications of ventriculoperitoneal shunts. Case reports and review of the literature. *Am Surg* 54 : 50-55, 1988
7. Chan Y, Datta NN, Chan KY, Rehman SU, Poon CY, Kwok JC : Extrusion of the peritoneal catheter of a VP shunt system through a gastrostomy wound. *Surg Neurol* 60 : 68-69; discussion 70, 2003
8. Cozzens JW, Chandler JP : Increased risk of distal ventriculoperitoneal shunt obstruction associated with slit valves or distal slits in the peritoneal catheter. *J Neurosurg* 87 : 682-686, 1997
9. Cuatico W, Vannix D : Laparoscopically guided peritoneal insertion in ventriculoperitoneal shunts. *J Laparoendosc Surg* 5 : 309-311, 1995
10. Deinsberger W, Langhans M, Winking M, Böker DK : Retrieval of a disconnected ventriculoperitoneal shunt catheter by laparoscopy in a newborn child : case report. *Minim Invasive Neurosurg* 38 : 123-124, 1995
11. Guzinski GM, Meyer WJ, Loeser JD : Laparoscopic retrieval of disconnected ventriculoperitoneal shunt catheters. Report of four cases. *J Neurosurg* 56 : 587-589, 1982
12. Handler MH, Callahan B : Laparoscopic placement of distal ventriculoperitoneal shunt catheters. *J Neurosurg Pediatric* 2 : 282-285, 2008
13. Jea A, Al-Otibi M, Bonnard A, Drake JM : Laparoscopy-assisted ventriculoperitoneal shunt surgery in children : a series of 11 cases. *J Neurosurg* 106 : 421-425, 2007
14. Josephs LG, Este-McDonald JR, Birkett DH, Hirsch EF : Diagnostic laparoscopy increases intracranial pressure. *J Trauma* 36 : 815-818; discussion 815-818, 1994
15. Kast J, Duong D, Nowzari F, Chadduck WM, Schiff SJ : Time related patterns of ventricular shunt failure. *Childs Nerv Syst* 10 : 524-528, 1994
16. Khaitan L, Brennan EJ Jr : A laparoscopic approach to ventriculoperitoneal shunt placement in adults. *Surg Endosc* 13 : 1007-1009, 1999
17. Khosrovi H, Kaufman HH, Hrabovsky E, Bloomfield SM, Prabhu V, el-Khadi HA : Laparoscopic-assisted distal ventriculoperitoneal shunt placement. *Surg Neurol* 49 : 127-134; discussion 134-135, 1998
18. Kirshtein B, Benifla M, Roy-Shapira A, Merkin V, Melamed I, Cohen Z, et al. : Laparoscopically guided distal ventriculoperitoneal shunt placement. *Surg Laparosc Endosc Percutan Tech* 14 : 276-278, 2004
19. Kubo S, Nakata H, Yoshimine T : Peritoneal shunt tube placement performed using an endoscopic threaded imaging port. Technical note. *J Neurosurg* 94 : 677-679, 2001
20. Lazareff JA, Peacock W, Holly L, Ver Halen J, Wong A, Olmstead C : Multiple shunt failures : an analysis of relevant factors. *Childs Nerv Syst* 14 : 271-275, 1998

21. Lockhart C, Selman W, Rodziewicz G, Spetzler RF : Percutaneous insertion of peritoneal shunt catheters with use of the Veress needle. Technical note. *J Neurosurg* **60** : 444-446, 1984
22. Mobbs RJ, Yang MO : The dangers of diagnostic laparoscopy in the head injured patient. *J Clin Neurosci* **9** : 592-593, 2002
23. Ochalski PG, Horowitz MB, Mintz AH, Hughes SJ, Okonkwo DO, Kassam AB, et al. : Minimal-access technique for distal catheter insertion during ventricular peritoneal shunt procedures : a review of 100 cases. *J Neurosurg*. **13** : 1-4, 2009
24. Ozveren MF, Kazez A, Cetin H, Ziyal IM : Migration of the abdominal catheter of a ventriculoperitoneal shunt into the scrotum--case report. *Neurol Med Chir (Tokyo)* **39** : 313-315, 1999
25. Roth J, Sagie B, Szold A, Elran H : Laparoscopic versus non-laparoscopic-assisted ventriculoperitoneal shunt placement in adults. A retrospective analysis. *Surg Neurol* **68** : 177-184; discussion 184, 2007
26. Roth JS, Park AE, Gewirtz R : Minilaparoscopically assisted placement of ventriculoperitoneal shunts. *Surg Endosc* **14** : 461-463, 2000
27. Schievink WI, Wharen RE Jr, Reimer R, Pettit PD, Seiler JC, Shine TS : Laparoscopic placement of ventriculoperitoneal shunts : preliminary report. *Mayo Clin Proc* **68** : 1064-1066, 1993
28. Schrenk P, Woisetschlager R, Wayand WU, Polanski P : Laparoscopic removal of dislocated ventriculoperitoneal shunts. Report of two cases. *Surg Endosc* **8** : 1113-1114, 1994
29. Tanaka J, Kikuchi K, Sasajima H, Koyama K : Laparoscopic retrieval of disconnected ventriculoperitoneal shunt catheters : report of two cases. *Surg Laparosc Endosc* **5** : 263-266, 1995
30. Turner RD, Rosenblatt SM, Chand B, Luciano MG : Laparoscopic peritoneal catheter placement : results of a new method in 111 patients. *Neurosurgery* **61** : 167-172; discussion 172-174, 2007
31. Wani AA, Ramzan A, Wani MA. Protrusion of a peritoneal catheter through the umbilicus : an unusual complication of a ventriculoperitoneal shunt. *Pediatr Surg Int* **18** : 171-172, 1999
32. Yamashita K, Yonekawa Y, Kawano T, Ihara I, Taki W, Kobayashi A et al. : Intra-abdominal cyst following revision of ventriculoperitoneal shunt--case report. *Neurol Med Chir (Tokyo)* **30** : 748-752, 1990