

Thymolipoma in a 13-year-old Korean girl

Su-Jin Park, M.D., Ji Young Baek, M.D., Junjeong Choi M.D.*, Kyung Won Kim, M.D.
Myung Joon Kim, M.D.[†], Myung Hyun Sohn, M.D. and Kyu-Earn Kim, M.D.

Departments of Pediatrics, Pathology*, Radiology[†], Yonsei University College of Medicine, Seoul, Korea

= Abstract =

Thymolipoma is a rare benign tumor of anterior mediastinum. Most patients are asymptomatic with incidental finding of the tumor during a diagnostic workup of other medical problems. We present a case of 13-year-old girl with anterior mediastinal thymolipoma, surgically removed after an incidental diagnosis. (Korean J Pediatr 2010;53:103-105)

Key Words: Thymolipoma, Lipoma, Thymic neoplasm, Mediastinal neoplasm

Introduction

Thymolipoma is a rare benign tumor of anterior mediastinum first described in 1916 by Lange¹. There are fewer than 200 reported cases worldwide and 6 cases reported in Korea with only 2 cases in children^{2,3}. We present a case of 13-year-old girl with anterior mediastinal thymolipoma, surgically removed after an incidental diagnosis.

Case report

A 13-year-old girl presented to the hospital with complaints of fever and headache for 1 day. The patient underwent operation at the age of 6 month, for resection of lipomeningomyelocele of the lower spine, but she had no medical history otherwise. The patient did not show any signs of respiratory infection such as cough, sputum, and dyspnea. She did not show symptoms of myasthenia gravis and did not show any constitutional symptoms. On physical examination, chest wall showed symmetric expansion without retraction, but decreased lung sounds in right lower lung field was noted. Heart beat was regular without notable murmur. Arterial blood gases analysis was within normal range and other laboratory findings were unremarkable.

On standard chest x-ray, bulging mass shadow with obliteration of the entire right diaphragm and right cardiac border was noted (Fig. 1A, B). A computerized tomography (CT) scan of her chest revealed an anterior mediastinal soft tissue mass with internal fat content, extending along right cardiac border and right diaphragm (Fig. 2). The mass lesion was plastic with change and shape according to change of position. After videothoroscopic inspection of the mass, right lateral thoracotomy was performed due to the large size of the mass. A 30×20×10 cm sized well-capsulated mass, with adhesion to pericardial fat was excised. The mass weighed 590 gm and the pathologic diagnosis of the resected block was consistent with thymolipoma (Fig. 3). The patient was discharged on postoperative day 4 in good health. Follow-up CT scan was performed 1 year after the operation with no evidence of residual or recurrent lesion.

Discussion

Thymolipoma is a rare, benign, slow growing tumor accounting for 2–9% of all thymic neoplasm⁴. Most patients are asymptomatic with incidental finding of the tumor during a diagnostic workup of other medical problems⁵. However, there have been studies where more than 50% of patients presented with symptoms⁶. The most frequently reported presentations are shortness of breath, chest pain, upper respiratory infections and chest heaviness⁶. Up to 10% of the cases are reported to be associated with myasthenia gravis and association with aplastic anemia, Graves' disease, lymphangiomatous lymphatic leukemia, Hodg-

Received : 13 July 2009, Revised : 30 September 2009

Accepted : 26 October 2009

Address for correspondence : Myung Hyun Sohn, M.D.

Department of Pediatrics, Yonsei University College of Medicine 250 Seongsan-no, Seodaemun-gu, Seoul 120-752, Korea

Tel : +82.2-2228-2062, Fax : +82.2-393-9118

E-mail : mhsohn@yuhs.ac

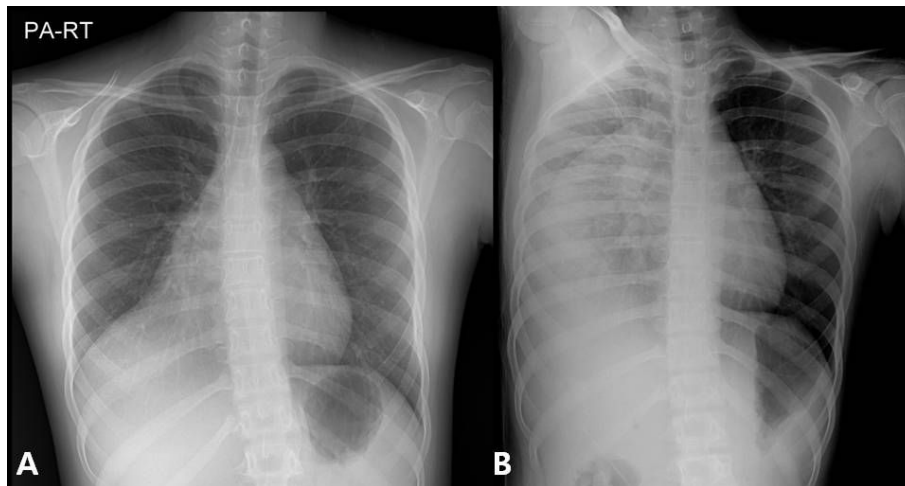


Fig. 1. (A) Preoperative chest X-ray. Chest X-ray shows bulging mass shadow with obliteration of the entire right diaphragm and right cardiac border. (B) Preoperative right chest decubitus X-ray. The mass lesion shows plasticity in shape, according to positional change.

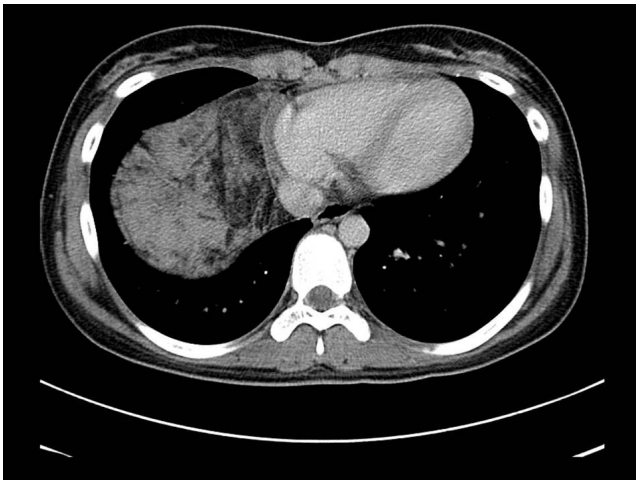


Fig. 2. Preoperative chest computerized tomography. Contrast enhanced CT shows mediastinal soft tissue mass with internal fat content from anterior mediastinum, extending along the right cardiac border and right diaphragm.

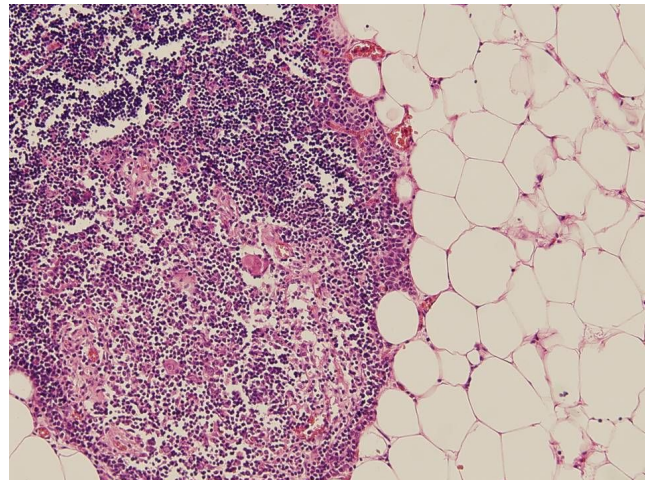


Fig. 3. Pathologic finding of surgical specimen (H&E stain, $\times 100$ magnification). The specimen consists of normal thymic tissue with fat tissue (H&E stain, $\times 100$ magnification).

kin's disease, systemic erythematosus lupus, hypogammaglobulinemia, and erythroblastopenia has also been reported⁶. Our patient did not show any significant symptoms, even 6 months after birth when she had a surgery for lipomeningomyelocele. The relationship between thymolipoma and lipomeningomyelocele needs yet to be investigated, but there is no, c known reported case other than our patient. On standard chest X-ray, the radiologic features can mimic several conditions such as cardiomegaly, pericardial effusion, and pericardial tumors⁷. Differential diagnosis with large pleural tumor, basal atelectasis, and pulmonary sequestration is necessary⁸. In our patient, the standard chest x-ray

showed a large mass, plastic in shape according to positional change, a noticeable factor in thymolipoma. A preoperative chest CT is helpful in diagnosis, while an MRI is not essential in most cases⁹. On CT scan, the tumor appears as linear strands and whorls of soft tissue surrounded by fat¹⁰. Diagnosis can be established by imaging study, therefore a biopsy might not be necessary.

Thymolipomas are consisted of elements of varying embryonic origin, both mesodermal (fat) and endodermal (thymic epithelium)¹¹. They are usually well encapsulated, lobulated, and do not infiltrate adjacent structures. The pathologic finding of our patient showed well encapsulated

lesion with normal thymic tissue along with adipose tissue, fitting the description of thymolipoma. Total resection of the mass by surgical method, is the only curative treatment⁵⁾. The present report is significant in that thymolipoma is very rare among Korean population, especially in children, and our patient had co-existing lipomeningomyelocele, also a slow-growing lipoma. The outcome after surgical removal is known to be excellent. Our patient underwent surgical removal of mass and was closely followed-up after the operation, with no complications.

한 글 요약

국내에 보고된 13세 여아의 흉선 지방종 1예

연세대학교 의과대학 소아과학교실, 병리학교실*,
진단방사선과학교실†

박수진 · 백지영 · 최준정* · 김경원
김명준† · 손명현 · 김규연

흉선 지방종은 증격동 전방에서 유레하는 매우 드문 종양이다. 대부분의 환자들은 증상이 없어 다른 이유로 시행한 검사상에서 우연히 발견되는 경우가 많다. 저자들은 13세된 여아에서 발견되어 수술한 흉선 지방종 환자를 경험하였기에 이를 보고하는 바이다.

References

- 1) Lange I. Uber ein lipom des thymus. Cited from Zentralbl Allg Pathol Anat 1916;27:97-100.
- 2) Son SW. A case of thymolipoma in a child. Korean Assoc Pediatr Surg 2004;10:39-42.
- 3) Choi R, Kim YC, Cha HJ, Lee SJ, Lee CS, Ro JK, et al. Two cases of thymolipoma. J Korean Pediatr Soc 1991;34:1605-11.
- 4) Halkos ME, Symbas JD, Symbas PN. Acute respiratory distress caused by massive thymolipoma. South Medical J 2004;97:1123-5.
- 5) Ceran S, Tulek B, Sunam G, Suerdem M. Respiratory failure caused by giant thymolipoma. Ann Thorac Sur 2008;86:661-3.
- 6) Roque C, Rodriguez P, Quintero C, Santana N, Hussein M, Freixinet J. Giant thymolipoma. Arch Bronconeumol 2005;41:402-3.
- 7) Gamanagatti S, Sharma R, Hatimota P, Guleria R, Arvind S. Giant thymolipoma. AJR Am J Roentgenol 2005;185:283-4.
- 8) Teplick JG, Nedwich A, Haskin ME. Roentgenographic features of thymolipoma. Am J Roentgenol Radium Ther Nucl Med 1973;117:873-80.
- 9) Shirkhoda A, Chasen MH, Eftekhari F, Goldman AM, Decaro LF. MR imaging of mediastinal thymolipoma. J Computer Assist Tomogr 1987;11:364-5.
- 10) Rosado-de-Christenson ML, Pugatch RD, Moran CA, Galobardes J. Thymolipoma: analysis of 27 cases. Radiology 1994;193:121-6.
- 11) Moran CA, Rosado-de-Christenson M, Suster S. Thymolipoma: clinicopathologic review of 33 cases. Mod Path 1995;8:741-4.