

Clinical Article

Minimally Invasive Muscle Sparing Transmuscular Microdiscectomy : Technique and Comparison with Conventional Subperiosteal Microdiscectomy during the Early Postoperative Period

Beom-Seok Park, M.D., Young-Joon Kwon, M.D., Ph.D., Yu-Sam Won, M.D., Hyun-Chul Shin, M.D., Ph.D.

Department of Neurosurgery, Kangbuk Samsung Hospital, Sungkyunkwan University School of Medicine, Seoul, Korea

Objective : The authors introduce a minimally invasive muscle sparing transmuscular microdiscectomy (MSTM) to treat herniated lumbar disc disease. Its results are compared with conventional subperiosteal microdiscectomy (CSM) to validate the effectiveness.

Methods : Muscle sparing transmuscular microdiscectomy, which involves muscle dissection approach using the natural fat cleavage plane between the multifidus to expose the interlaminar space, was performed in 23 patients to treat a single level unilateral lumbar radiculopathy. The creatine phosphokinase (CPK)-MM serum levels were measured on admission and at 1, 3, and 5 days postoperatively. Postoperative pain was evaluated using a 10-point visual analogue scale (VAS) and recorded on admission and at 1, 3, and 5 days postoperatively. The results were compared to those from the conventional subperiosteal microdiscectomy (43 patients).

Results : The CPK-MM levels were significantly lower in the serum of the MSTM group compared to the CSM group on postoperative days three and five ($p = 0.03$ and $p = 0.02$, respectively). The clinical scales for back pain using VAS were significantly lower in the MSTM group than in the CSM group on postoperative days three ($p = 0.04$). The mean VAS scores for leg pain in both groups showed no significant differences during the early postoperative period.

Conclusion : Muscle sparing transmuscular microdiscectomy is a minimally invasive surgical option to treat lumbar radiculopathy due to herniated disc. The approach affected minimal injury to posterior lumbar supporting structures with alleviated postoperative back pain.

KEY WORDS : Lumbar spine · Muscle sparing technique · Microdiscectomy · Minimally invasive surgery.

INTRODUCTION

Since Caspar reported on the use of the microscope for lumbar discectomy procedures to treat intervertebral disc herniation⁵, microscopic lumbar discectomy became a popular procedure with high success rate and low surgical morbidity. Caspar used the subperiosteal muscle stripping method to expose the lamina. However, this subperiosteal approach required the incision of midline ligamentous structures and detachment/retraction of tendinous insertions of

the paraspinal muscles from the spinous process. The intraoperative injury of the posterior supporting structures of the lumbar spine could lead to postoperative back pain, spinal instability, and even the failed back surgery syndrome^{9,19}.

The microendoscopic discectomy (MED) was introduced by Foley and Smith⁸; it was the first technique that addressed the shortcomings of the conventional subperiosteal approach. Many investigators have reported that MED is associated with less postoperative pain, a shorter hospital stay, and more rapid return to work^{6,13}. However, the MED has some limitations related to a small operation field, visualized through a cylindrical tubular retractor^{1,2}.

The transmuscular muscle-splitting approach between the natural cleavage muscle planes has been shown to cause less damage and retraction of paraspinal muscles compared to the subperiosteal approach^{1,2}. In the present study, a minimally invasive functional muscle sparing transmuscular technique

• Received : May 27, 2010 • Revised : August 12, 2010
• Accepted : September 17, 2010
• Address for reprints : Young-Joon Kwon, M.D., Ph.D.
Department of Neurosurgery, Kangbuk Samsung Hospital, Sungkyunkwan University School of Medicine, 108 Pyeong-dong, Jongno-gu, Seoul 110-746, Korea
Tel : +82-2-2001-2450, Fax : +82-2-2001-2157
E-mail : neuriac@skku.edu

was introduced for microsurgery of herniated lumbar disc disease and its usefulness was evaluated for the muscle sparing approach compared to the conventional subperiosteal approach, by measuring serum levels of creatine phosphokinase (CPK)-MM, and by comparing the visual analogue scale (VAS) scores of postoperative pain during the early postoperative period.

MATERIALS AND METHODS

After institutional review board approval (code no. KBC 10068), the authors retrospectively reviewed 66 patients who underwent a first time, single level unilateral lumbar microdiscectomy at our institution between January 1, 2008 and December 31, 2008. Surgery was performed when conservative management had failed after six weeks, or when acute exacerbation of neurological symptoms was present. The affected site was identified by thorough neurological examination and by magnetic resonance imaging. Medications and conditions that could have interfered with the results such as statins and muscular disease, which can elevate the serum CPK-MM, were assessed and excluded.

The patients had lumbar discectomy by conventional subperiosteal microdiscectomy (CSM) using a standard midline incision 3–4 cm in length as previously described⁵, or a muscle sparing transmuscular microdiscectomy (MSTM). The operations were performed by two surgeons using the different surgical technique. The key difference between the techniques is the management of musculo-ligamentous structures and the type of retractor used (Taylor vs. Caspar). During the first two postoperative days, all patients in both groups received patient-controlled analgesia.

The CPK-MM serum levels were measured on admission and at 1, 3, and 5 days postoperatively. For the early post-

operative pain evaluation, the level of pain was self-recorded by patients using a 10-point visual analogue scale (VAS), in which zero indicated no pain and 10 indicated the worst imaginable pain. The scores were recorded on admission and at 1, 3, and 5 days after the operation by the nurse who was blinded to the patients' type of surgery. Back and leg pain were recorded separately to assess invasiveness to musculo-ligamentous structures and adequacy of decompression, respectively.

The results were analyzed using PASW Statistics, version 17.0. The data are presented as the means \pm standard deviations. Statistical analysis was performed using the Mann-Whitney U test. A *p* value of 0.05 was considered statistically significant.

Muscle sparing transmuscular microdiscectomy technique

Under general anesthesia, the patient was placed in the prone position on the operating table. The target disc was identified by C-arm fluoroscopy after a 23G spinal needle was placed at the presumed affected level. A 2 cm-long skin incision was made 1.0–1.5 cm lateral to the midline. The subcutaneous layer was undermined over the lumbar fascia sufficiently to minimize retraction and pressure on the skin edge. The fascia was incised in a straight fashion using a no. 15 blade along the direction of the deep fascial fibers. This allowed for a functional repair of the fascia after discectomy, if needed. The medial lip of the incised fascia was suspended temporarily with one stitch towards the midline and held with a mosquito clamp to secure the space for applying the retractor. Paraspinal muscles were separated between the multifidus and spinous process using a Penfield dissector and a periosteal elevator along the natural cleavage plane to expose the interlaminar space (Fig. 1). During the muscle splitting, special care was done not to damage surrounding muscle and musculo-ligamentous attachment to bony structures. A few segments of tendinous insertion of deep multifidus overlying the interlaminar space were cut occasionally to obtain a wider operative field. After the interlaminar space was exposed, the dissector was put in the space and the affected level was checked with C-arm fluoroscopy. Then the Caspar retractor was inserted carefully between the muscle cleavage planes. The outward curved blade of the retractor prevented muscle intervening during the operation (Fig. 2A). The widening of the retractor blade was minimized during surgery to maintain reduced the pressure on the surrounding muscle and additional retraction with the lateral retractor blade was not performed (Fig. 2B). Then a microscope was applied into the operative field and a partial hemilaminectomy was performed with a high speed drill and a Kerrison punch.




Fig. 1. Coronal T2-weighted magnetic resonance image showing the natural fat cleavage plane. The fat plane between the bulk of the multifidus muscle at L4/5 interlaminar space is noted (arrows). The plane between the multifidus and the longissimus is also noted (arrow heads).

A flavectomy and a discectomy were also performed. The nerve root at the affected level was sufficiently decompressed with removal the disc material underneath. Unroofing of the lamina over the root was sufficiently performed. The retractor was carefully removed after meticulous hemostasis. Muscle was not sutured routinely and the fascia and subcutaneous tissue were closed with absorbable sutures. The skin was taped with Steristrips®.

RESULTS

Basic demographic data including age, gender, body mass index, level and side of the radiculopathy are presented in Table 1. No statistically significant difference was identified for the demographic data in the groups.

The surgical time and estimated blood loss in the MSTM group was 107 ± 39 minutes and 56 ± 11 mL, respectively. For the CSM group, the surgical time was 102 ± 31 minutes and the estimated blood loss was 58 ± 8 mL. The results were not significantly different in the two groups. During the MSTM, no CSF leakage or other complications were noted. In addition, no conversion to a conventional subperiosteal microdiscectomy was performed. All patients in the MSTM group had an uneventful recovery during the early postoperative period.

The CPK-MM levels, a representative serological marker for muscle injury, were significantly higher in the serum of the CSM group compared to the MSTM group on postoperative days three and five (Table 2). The peak level was noted one day postoperatively in the MSTM group, and three days postoperatively in the CSM group.

The clinical scales for back pain using VAS were lower in the MSTM group than in the CSM group over the three consecutive postoperative periods. Significant statistical differences between the groups were noted on postoperative days three (Table 3). The mean VAS scores for leg pain in both groups showed no

significant differences over the postoperative periods (Table 4).

DISCUSSION

The conventional microdiscectomy has been shown to

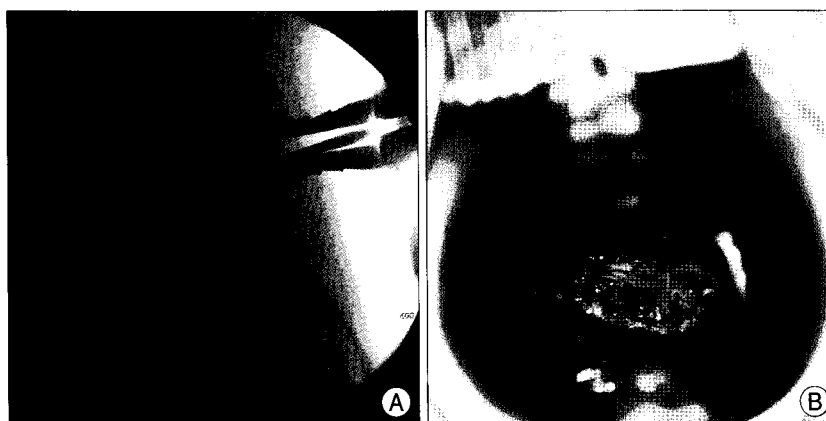


Fig. 2. Intraoperative image showing adequate retractor placement. A : The outward curved blade of the retractor prevented muscle intervening during the operation. B : Operative field is well provided with the retractor while maintaining reduced pressure on the surrounding muscle.

Table 1. Summary of basic demographic data in the MSTM and the CSM groups

Demographics	Operative methods	
	MSTM (23 patients)	CSM (43 patients)
Sex (M/F)	14/9	23/20
Age (yrs)	41.43 \pm 2.99	51.63 \pm 2.43
Body mass index	24.22 \pm 0.62	24.27 \pm 0.49
Level of lesion (no.)		
L23	1	3
L34	1	7
L45	15	21
L5S1	6	12
Side of lesion (no.)		
Left	11	19
Right	12	24

MSTM : muscle sparing transmuscular microdiscectomy, CSM : conventional subperiosteal microdiscectomy

Table 2. Preoperative and postoperative CPK-MM levels in the MSTM and the CSM groups

CPK-MM	MSTM	CSM	p value
PreOD (IU/L)	90.96 \pm 45.66	85.57 \pm 44.29	0.67
POD1 (IU/L)	181.91 \pm 114.63	191.34 \pm 123.31	0.77
POD3 (IU/L)	158.09 \pm 54.72	233.42 \pm 150.26	0.03
POD5 (IU/L)	101.26 \pm 43.19	184.00 \pm 159.61	0.02

CPK : creatine phosphokinase, MSTM : muscle sparing transmuscular microdiscectomy, CSM : conventional subperiosteal microdiscectomy, PreOD : preoperative day, POD : postoperative day

Table 3. Preoperative and postoperative VAS scores for back pain in the MSTM and the CSM groups

VAS	MSTM	CSM	p value
PreOD	5.96 \pm 1.46	5.91 \pm 1.54	0.90
POD1	3.70 \pm 1.19	3.88 \pm 1.03	0.50
POD3	2.57 \pm 1.20	3.16 \pm 1.07	0.04
POD5	2.15 \pm 1.14	2.70 \pm 0.95	0.07

VAS : visual analogue scale, MSTM : muscle sparing transmuscular microdiscectomy, CSM : conventional subperiosteal microdiscectomy, PreOD : preoperative day, POD : postoperative day

Table 4. Preoperative and postoperative VAS scores for leg pain in the MSTM and the CSM groups

VAS	MSTM	CSM	p value
PreOD	7.13 ± 1.52	6.91 ± 1.31	0.53
POD1	3.17 ± 1.19	3.07 ± 1.10	0.72
POD3	2.70 ± 1.15	2.77 ± 0.92	0.78
POD5	2.05 ± 1.21	2.20 ± 0.76	0.56

VAS : visual analogue scale, MSTM : muscle sparing transmuscular microdiscectomy, CSM : conventional subperiosteal microdiscectomy, PreOD : preoperative day, POD : postoperative day

have reduced soft-tissue damage, blood loss and overall morbidity due to the magnification and illumination provided by the microscope¹³. However, this technique requires wide subperiosteal muscle detachment and retraction using a Taylor retractor with significant pressure. Prior investigators have reported that a considerable increase in intramuscular pressure, during lumbar disc surgery caused by a retractor and muscular injury, were closely related to the retraction pressure^{11,20}. Serum CPK levels have been shown to be a good indicator of postoperative muscle injury^{3,7,14}. Among the CPK isoenzymes, CPK-MM usually indicates injury or stress to the skeletal muscle. The serum CPK-MM was used as a marker of muscular damage in the present study.

In 1997, Foley and Smith⁸ introduced an endoscopic approach as a minimally invasive surgical alternative to treat herniated lumbar discs. The herniated tissue with this technique is resected endoscopically using a small incision and a tubular retractor (16 or 18 mm in diameter). This microendoscopic discectomy (MED) has been known to cause less tissue damage than conventional open microdiscectomy procedures with a marked reduction in postoperative pain and muscle spasm, allowing the procedure to be performed in the outpatient setting, and enabling patients to return to their activities of daily living fast^{6,15}. In addition, the MED group showed a lower incidence of persistent residual postoperative low back pain than the conventional microdiscectomy group one year after the operation¹⁶.

However, the MED procedure requires a tubular retractor system that provides a small surgical corridor to the target lesion. Generally, lumbar laminar shows slanting surface to dock this cylindrical type of retractor properly, so cauterizing and cutting some portion of the muscles intruding beneath the retractor is required to provide an adequate surgical field, which may cause muscle damage. The limited surgical field and intruding muscle fibers may cause troublesome condition related to surgical complications or inadequate decompression, especially during the early learning curve period of the procedure.

The authors presented a minimally invasive muscle-sparing transmuscular microdiscectomy using the natural fat cleavage plane between the multifidus muscle to expose the interlaminar space (Fig. 1). The fat plane between the bulk of the

multifidus muscle attached to two adjacent spinous processes provides a natural avascular plane such as the plane between the multifidus and the longissimus used in the original Wiltse approach²¹. A small portion of the deep lumbar multifidus overlying the interlaminar area is dissected. Coagulation

is rarely needed because an avascular plane is used for the approach. Because the natural cleavage plane is used, the retraction pressure on the surrounding muscle can be minimized and musculo-ligamentous attachment to bony structures is not violated. Moreover, the Caspar retractor with curved blade efficiently retracts the muscles and provides a good surgical corridor without excessive pressure to surrounding muscles (Fig. 2). By contrast, the Taylor retractor used for the CSM requires extensive muscle detachment and may cause significant retraction pressure during the operation.

In the present study, perioperative parameters related to invasiveness and outcome were investigated. The CPK-MM, a representative serological marker for skeletal muscle injury¹⁰, showed significantly lower levels in the serum of the MSTM group compared to the CSM group during the early postoperative period. These results suggest that the MSTM technique caused less muscle damage than the conventional technique. A lower postoperative VAS score with regard to back pain in the MSTM group also supports this suggestion, even though all the findings over the early postoperative period were not statistically significant. The use of patient controlled analgesia for two days postoperatively may have masked the possible differences between the two groups. The extensive musculo-ligamentous detachment and retraction during the CSM may result in a less favorable outcome than with the MSTM. Many studies have reported a better and more rapid recovery with the minimal muscular manipulation during spinal surgery. The MED has been associated with reduced paraspinal muscle damage compared to the conventional subperiosteal approach using a serological marker such as CPK-MM¹⁸, or intraoperative electromyography evaluations¹⁷. Brock et al.⁴ reported that compared to the conventional subperiosteal approach, the transmuscular approach required reduced amounts of analgesics during the early postoperative period. There were no significant differences in the postoperative VAS scores of leg pain between the two groups in our study. These findings suggest that the MSTM technique can provide adequate decompression of the root, when compared to the conventional technique.

Despite the short term results during the early postoperative period, the findings suggest that the MSTM was a useful procedure for the treatment of lumbar disc disease using

minimally invasive surgical techniques. To confirm these preliminary results, a prospective randomized controlled comparative study with CSM should be performed. A longer follow up of the MSTM is underway.

CONCLUSION

Muscle sparing transmuscular microdiscectomy using the natural fat cleavage plane between the multifidus is a minimally invasive surgical option for the treatment of herniated lumbar disc disease; it was associated with minimal injury to posterior lumbar supporting structures and alleviated postoperative back pain.

References

1. Anand N, Baron EM, Bray Jr RS : Benefits of the paraspinal muscle-sparing approach versus the conventional midline approach for posterior nonfusion stabilization : comparative analysis of clinical and functional outcomes. *SAS Journal* 1 : 93-99, 2007
2. Anand N, Baron EM, Bray Jr RS : Modified muscle-sparing paraspinal approach for stabilization and interlaminar decompression : a minimally invasive technique for pedicle screw-based posterior nonfusion stabilization. *SAS Journal* 2 : 40-42, 2008
3. Arts MP, Nieborg A, Brand R, Peul WC : Serum creatine phosphokinase as an indicator of muscle injury after various spinal and nonspinal surgical procedures. *J Neurosurg Spine* 7 : 282-286, 2007
4. Brock M, Kunkel P, Papavero L : Lumbar microdiscectomy : subperiosteal versus transmuscular approach and influence on the early postoperative analgesic consumption. *Eur Spine J* 17 : 518-522, 2008
5. Caspar W : A new surgical procedure for lumbar disc herniation causing less tissue damage through a microsurgical approach. *Adv Neurosurg* 4 : 152, 1977
6. Choi YY, Yoon SH, Ha Y, Kim EY, Park HC, Park CO : Posterior microscopic lesionectomy for lumbar disc herniation with tubular retraction using METRx™ system. *J Korean Neurosurg Soc* 40 : 406-411, 2006
7. Dixon SH Jr, Fuchs JC, Ebert PA : Changes in serum creatine phosphokinase activity following thoracic, cardiac, and abdominal operations. *Arch Surg* 103 : 66-68, 1971
8. Foley KT, Smith MM : Microendoscopic discectomy. *Tech Neurosurg* 3 : 301-307, 1997
9. Katayama Y, Matsuyama Y, Yoshihara H, Sakai Y, Nakamura H, Nakashima S, et al. : Comparison of surgical outcomes between macro discectomy and micro discectomy for lumbar disc herniation : a prospective randomized study with surgery performed by the same spine surgeon. *J Spinal Disord Tech* 19 : 344-347, 2006
10. Kawaguchi Y, Matsui H, Tsuji H : Changes in serum creatine phosphokinase MM isoenzyme after lumbar spine surgery. *Spine (Phila Pa 1976)* 22 : 1018-1023, 1997
11. Kawaguchi Y, Yabuki S, Styf J, Olmarker K, Rydevik B, Matsui H, et al. : Back muscle injury after posterior lumbar spine surgery. Topographic evaluation of intramuscular pressure and blood flow in the porcine back muscle during surgery. *Spine (Phila Pa 1976)* 21 : 2683-2688, 1996
12. Kim YB, Hyun SJ : Clinical applications of the tubular retractor on spinal disorders. *J Korean Neurosurg Soc* 42 : 245-250, 2007
13. Koebbe CJ, Maroon JC, Abba A, El-Kadi H, Bost J : Lumbar microdiscectomy : a historical perspective and current technical considerations. *Neurosurg Focus* 13 : E3, 2002
14. Kotil K, Tunckale T, Tatar Z, Koldas M, Kural A, Bilge T : Serum creatine phosphokinase activity and histological changes in the multifidus muscle : a prospective randomized controlled comparative study of discectomy with or without retraction. *J Neurosurg Spine* 6 : 121-125, 2007
15. Riesenburger RI, David CA : Lumbar microdiscectomy and microendoscopic discectomy. *Minim Invasive Ther Allied Technol* 15 : 267-270, 2006
16. Sasaoka R, Nakamura H, Konishi S, Nagayama R, Suzuki E, Terai H, et al. : Objective assessment of reduced invasiveness in MED. Compared with conventional one-level laminotomy. *Eur Spine J* 15 : 577-582, 2006
17. Schick U, Döhner J, Richter A, König A, Vitzthum HE : Microendoscopic lumbar discectomy versus open surgery : an intraoperative EMG study. *Eur Spine J* 11 : 20-26, 2002
18. Shin DA, Kim KN, Shin HC, Yoon DH : The efficacy of microendoscopic discectomy in reducing iatrogenic muscle injury. *J Neurosurg Spine* 8 : 39-43, 2008
19. Sihvonen T, Herno A, Paljärvi L, Airaksinen O, Partanen J, Tapaninaho A : Local denervation atrophy of paraspinal muscles in postoperative failed back syndrome. *Spine (Phila Pa 1976)* 18 : 575-581, 1993
20. Taylor RS : Spinal cord stimulation in complex regional pain syndrome and refractory neuropathic back and leg pain/failed back surgery syndrome : results of a systematic review and meta-analysis. *J Pain Symptom Manage* 31 : S13-S19, 2006
21. Wiltse LL, Bateman JG, Hutchinson RH, Nelson WE : The paraspinal sacrospondylis-splitting approach to the lumbar spine. *J Bone Joint Surg Am* 50 : 919-926, 1968