

Clinical Article

The Avoidance of Microsurgical Complications in the Extradural Anterior Clinoidectomy to Paraclinoid Aneurysms

Hee Eon Son, M.D.,* Moon Sun Park, M.D., Ph.D.,* Seong Min Kim, M.D., Ph.D., Sung Sam Jung, M.D., Ki Seok Park, M.D., Seung Young Chung, M.D., Ph.D.

Department of Neurosurgery, School of Medicine, Eulji University, Daejeon, Korea

Objective : Paraclinoid segment internal carotid artery (ICA) aneurysms have historically been a technical challenge for neurovascular surgeons. The development of microsurgical approach, advances in surgical techniques, and endovascular procedures have improved the outcome for paraclinoid aneurysms. However, many authors have reported high complication rates from microsurgical treatments. Therefore, the present study reviews the microsurgical complications of the extradural anterior clinoidectomy for treating paraclinoid aneurysms and investigates the prevention and management of observed complications.

Methods : Between January 2004 and April 2008, 22 patients with 24 paraclinoid aneurysms underwent microsurgical direct clipping by a cerebrovascular team at a regional neurosurgical center. Microsurgery was performed via an ipsilateral pterional approach with extradural anterior clinoidectomy. We retrospectively reviewed patients' medical charts, office records, radiographic studies, and operative records.

Results : In our series, the clinical outcomes after an ipsilateral pterional approach with extradural anterior clinoidectomy for paraclinoid aneurysms were excellent or good (Glasgows Outcome Scale : GOS 5 or 4) in 87.5% of cases. The microsurgical complications related directly to the extradural anterior clinoidectomy included transient cranial nerve palsy (6), cerebrospinal fluid leak (1), worsened change in vision (1), unplanned ICA occlusion (1), and epidural hematoma (1). Only one of the complications resulted in permanent morbidity (4.2%), and none resulted in death.

Conclusion : Although surgical complications are still reported to occur more frequently for the treatment of paraclinoid aneurysms, the permanent morbidity and mortality resulting from a extradural anterior clinoidectomy in our series were lower than previously reported. Precise anatomical knowledge combined with several microsurgical tactics can help to achieve good outcomes with minimal complications.

KEY WORDS : Extradural anterior clinoidectomy · Paraclinoid aneurysm · Clinical outcomes · Surgical complications.

INTRODUCTION

The paraclinoid segment of the internal carotid artery (ICA) has been named the area from where it exits the cavernous sinus and enters the subarachnoid space to the origin of the posterior communicating artery^{1,3,9,22,29}.

Aneurysms arising from the paraclinoid segment have presented unique challenges in both diagnosis and microsurgical management because of their unique anatomic location, and these types of aneurysms have been associated with high

morbidity and mortality^{5,9,11,36}. Before the development of skull base techniques, the approach for these aneurysms was difficult because the anterior clinoid process (ACP) obstructed the surgical field and restricted the surgeon's working space. The clipping of paraclinoid aneurysms, while attempting to preserve the ophthalmic artery and maintain patency of the ICA, is a technically difficult procedure. A significant number of paraclinoid aneurysms present as giant aneurysms^{1,22,26,41}, lesions that may further add to the difficulties of management.

However, advances in skull base approaches^{10,11}, especially the extradural anterior clinoidectomy^{8,16,24}, have greatly improved surgical outcomes for patients with paraclinoid aneurysms. Furthermore, endovascular procedures have become alternative treatments for paraclinoid aneurysms^{17,27,31}. However, microsurgery continues to result in a larger percentage of total occlusions compared to other methods, especi-

• Received : October 28, 2009 • Revised : July 27, 2010

• Accepted : September 15, 2010

• Address for reprints : Seung Young Chung, M.D., Ph.D.
Department of Neurosurgery, School of Medicine, Eulji University, 1306
Dunsan-dong, Seo-gu, Daejeon 302-799, Korea
Tel : +82-42-611-3442, Fax : +82-42-611-3444
E-mail : neurocsy@eulji.ac.kr

*These authors contributed equally to this work.

ally for large and giant aneurysms, because total obliteration with endovascular treatment is not as likely as it is with surgery^{14,20,39}, and coiling procedures have been associated with a higher rate of recurrent aneurysms compared with that of surgical treatment^{5,19}. Although the extradural anterior clinoidectomy was developed specifically to improve outcomes for paraclinoid aneurysms, many authors still report high complication rates resulting from this approach^{3,4,6,9,11,19,25}.

The purposes of this study are to review our recent experiences using an extradural anterior clinoidectomy to surgically repair paraclinoid segment aneurysms and to analyze the microsurgical complications we have experienced. We also analyzed how to avoid and to manage potential complications based on these results.

MATERIAL AND METHODS

Between January 2004 and April 2008, 22 patients with 24 paraclinoid aneurysms underwent microsurgical direct clipping by a cerebrovascular team at a regional neurosurgical center. We retrospectively analyzed the clinical records in patients with these aneurysms. All paraclinoid aneurysms were confirmed using digital subtraction angiography (DSA), three-dimensional computed tomography angiography (CTA), preoperative temporal bone computed tomography (CT), and magnetic resonance imaging (MRI) (in 12 of the patients). Microsurgery was performed via an ipsilateral pterional craniotomy and with an extradural, extended anterior clinoidectomy^{8,16,24,35}. We retrospectively reviewed the patients' medical charts, office records, radiographic studies, operative records, and videos.

Clinical presentations

The 22 patients included 5 men and 17 women ranging in age from 42 to 69 years (mean 53.5). The clinical presentations of the 24 paraclinoid aneurysms include headache in four cases (16.6%), subarachnoid hemorrhage in six cases (25%), transient ischemic attack or stroke in one case (4.2%), dizziness in one case (4.2%), diplopia in one case (4.2%) and incidental findings including three cases with ruptured other aneurysm in 11 cases (45.8%) (Table 1). In nine patients with subarachnoid hemorrhages, the Hunt and Hess grade was II in five patients, III in one patient, and IV in three patients. Among 22 patients, seven (31.6%) had multiple intracranial aneurysms and three (13.6%) had other aneurysms in the paraclinoid segment.

Aneurysm characteristics

According to an anatomic system based on the aneurysm's presumed vessels of origin and location on the ICA³⁰, the

Table 1. Clinical presentations of 22 patients with 24 paraclinoid aneurysms

Clinical presentation	No. (%)
Incidental	11 (45.8)
Ruptured other aneurysm	3 (12.5)
Unruptured other aneurysm	2 (8.4)
Screening or others	6 (25.0)
Subarachnoid Hemorrhage	6 (25.0)
Headache	4 (16.6)
TIA/Stroke	1 (4.2)
Dizziness	1 (4.2)
Diplopia	1 (4.2)
Total	24

TIA: Transient Ischemic Attack

locations of the 24 paraclinoid aneurysms were as follows : 12 superior hypophyseal (50%), two carotid cave (8.3%), eight ophthalmic (33.3%), one posterior carotid wall (4.2%), and one transitional (4.2%). Aneurysms measuring up to 15 mm were considered small, those from 16 to 24 mm were large, and those measuring 25 mm or more were defined as giant. Twenty patients (83.3%) had small aneurysms, three (12.5%) large aneurysms, and one (4.2%) patient a giant aneurysm. Of the patients with multiple aneurysms, two had contralateral ICA aneurysms. No patient had any other types of vascular malformation.

Surgical approach

All 24 paraclinoid aneurysms were treated using an ipsilateral pterional approach with an extradural, extended ACP removal. First, prior to the craniotomy, proximal control of the ICA was obtained through routine exposure of the cervical ICA, which was then isolated using a rubber loop band. A frontotemporal craniotomy was performed (slightly larger than usual) with a high-speed drill in the lateral end of the superior orbital fissure (SOF). The ACP was partially drilled away, and the frontotemporal dural fold (FTDF) that passes the bony SOF and attaches to the periorbita was exposed. The dura of the anterior and middle fossa was dissected to expose the FTDF superomedially and the SOF inferolaterally. The FTDF and the periorbita-dura junctions were hence uncovered at the anterior limit of the lateral wall of the cavernous sinus (Fig. 1). Then, the FTDF was divided with a sharp scissors, and the outer dura layer of the lateral wall of the cavernous sinus was carefully peeled from the inner layer to expose easily and safely the entire dimension of the ACP. The peeling was performed from the foramen ovale, inferolaterally, and to the SOF-periorbita junction, superomedially. In this way, we were able to uncover the deepest inferolateral surface of the ACP (Fig. 2). The ACP and optic strut were removed extradurally, and an "L" shaped dural incision was performed along the sylvian fissure and frontal base. The dural incision extended anteriorly over the third

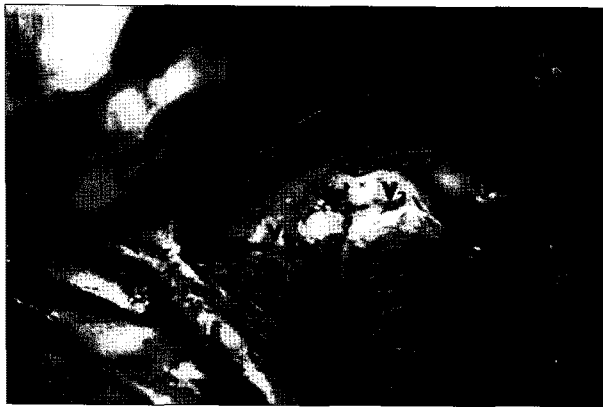

Fig. 1. The greater sphenoid wing is exposed from the foramen ovale laterally to the junction and medially to the lesser wing, and the frontotemporal dural fold is uncovered at the anterior limit of the lateral wall of the cavernous sinus. *Frontotemporal dural fold, V₁: ophthalmic branch of the trigeminal nerve, V₂: maxillary branch of the trigeminal nerve.



Fig. 2. The deepest inferolateral surface of the anterior clinoid process is finally uncovered. *Anterior clinoid process.

cranial nerve and toward the opening of the oculomotor foramen. Next, the optic sheath lateral to the optic nerve was opened, exposing the anterior portion of the roof of the cavernous sinus. After the identification of ophthalmic artery, if necessary, the distal dural ring was completely or partially released to allow for mobilization of the ICA segment in order to improve access to the aneurysm for clipping.

RESULTS

Clinical outcomes

The clinical outcomes are expressed using the Glasgow outcome scale (GOS) after six months of follow-up. The outcomes after an ipsilateral pterional approach with extradural anterior clinoidectomy for 24 paraclinoid aneurysms were defined as excellent or good (GOS 5 or 4) in 21 patients, 87.4%; fair (GOS 3) in two patients, 8.4%; and poor (GOS 2) in one patient, 4.2% (Table 2). The fair and poor outcomes resulted from vasospasm-related ischemia and hydrocephalus in one patient of the Hunt and Hess grade III with SAH and two of grade IV with ruptured other aneurysm. All cases of unruptured paraclinoid aneurysms were treated successfully without additional neurological deficits.

Microsurgical complications

The surgical complications related directly to the extradural anterior clinoidectomy included transient cranial nerve palsy (6), cerebrospinal fluid leakage (1), worsened change in vision (1), unplanned ICA occlusion (1), and epidural hematoma (1) (Table 3). Only one of these complications resulted in permanent morbidity, and none resulted in death. No morbidity was related to ischemia from occlusion of the ICA. The cranial nerve palsies occurred at the third cranial nerve; three of the six patients showed partial ptosis, and two patients had limited gaze adduction combined with ptosis. Only one patient showed almost complete ipsilateral palsy, which included ptosis, gaze limitation, and pupil dilatation. All of these patients fully recovered within one to six months. The patient with a worsened change in vision that resulted in permanent morbidity had a history of a previous ophthalmologic problem. The overall complication rate was 41.7%; however, the permanent morbidity rate was 4.2% and there was no case of surgically

Table 2. Clinical outcomes at the six-month follow-up*

Location	GOS5	GOS4	GOS3	GOS2	GOS1	Total
Superior hypophyseal	11	0	1	0	0	12
Ophthalmic	6	0	1	1	0	8
Carotid cave	2	0	0	0	0	2
Transitional	0	1	0	0	0	1
Posterior wall	1	0	0	0	0	1
Total	20	1	2	1	0	24

*Outcomes are expressed as a score calculated according to the Glasgow Outcome Scale (GOS).

Table 3. Complications related to microsurgery in 24 paraclinoid aneurysms

Location	Transient cranial nerve palsy	CSF leakage	Worsened change in vision	Unplanned ICA occlusion	EDH	Permanent morbidity	Total
Superior hypophyseal	2	1	0	1	0	0	4
Ophthalmic	3	0	0	0	1	0	4
Carotid cave	1	0	0	0	0	0	1
Transitional	0	0	1	0	0	1	1
Posterior wall	0	0	0	0	0	0	0
Total	6	1	1	1	1	1 (4.2%)	10 (41.7%)

CSF : cerebrospinal fluid, ICA : internal carotid artery, EDH : epidural hematoma

related mortality.

DISCUSSION

The paraclinoid segment of the proximal ICA is described using various names, including the ventral internal carotid artery segment¹⁵⁾ and the carotid-ophthalmic segment^{10,11,25)}. These aneurysms have traditionally been a technical challenge because access to the neck of the aneurysm usually requires ACP removal^{5,9,11,36)}. In addition, these aneurysms are frequently large or even giant in size^{1,22,26,41)}, while their location provides a restricted working space. However, the development and refinement of new surgical techniques^{6,10,11)} have greatly improved surgical outcomes for paraclinoid aneurysms.

Endovascular procedures have become alternative and effective treatments in the management of these lesions^{17,27,31)}. However, obliteration of the aneurysm with endovascular treatment has a lower success rate for total occlusion^{14,20,37)}. Furthermore, recurrences are more frequent after endovascular treatment, especially in lesions that were incompletely occlud-

ed during the initial procedure^{5,19)}. Microsurgery, therefore, remains the primary treatment for paraclinoid segment ICA aneurysms, as it provides a higher long-term success rate^{9,19)}, although in some cases, combined surgical and endovascular approaches has been a useful treatment strategy^{1,21,29,33)}.

In 1968, Drake et al.¹³⁾ reported that only 40% of patients (with 14 paraclinoid aneurysms) achieved good outcomes (GOS score of 4 or 5) following microsurgery, while 60% of patients died. However, subsequent clinical series have shown substantial improvements in outcome. In 1994, Batjer et al.³⁾ reported positive outcomes in 87% of cases from a surgical series of 89 paraclinoid aneurysms, with only a 12% morbidity rate. In 2001, Hoh et al.¹⁹⁾ reported that combined surgical and endovascular treatment of paraclinoid aneurysms resulted in good outcomes in 90% of the 145 surgically treated aneurysms. In 2004, Beretta⁴⁾ reported good outcomes in 81% of study patients with a 13% morbidity rate. Recently in 2008, Raco et al.³²⁾ reported good outcomes in 81% of patients and a long-term morbidity rate of 20%. The current study reports favorable outcomes similar to these previously published results.

However, although surgical outcomes for paraclinoid aneurysms have demonstrated an overall decrease over time in postoperative mortality and morbidity, many authors still report a higher rates of surgical complications compared to the surgical treatment of other aneurysms^{3,4,6,9,11,19,25,32,38)}. The current study also documents a relatively high complication rate of 41.7%. Most of these complications, however, were transient, and permanent morbidity was lower in our study than in previous studies.

Transient cranial nerve palsies

The cranial nerves can be injured during ACP removal or clip blade advancement or from excessive retraction or overzealous sinus packing. We experienced a high rate of transient

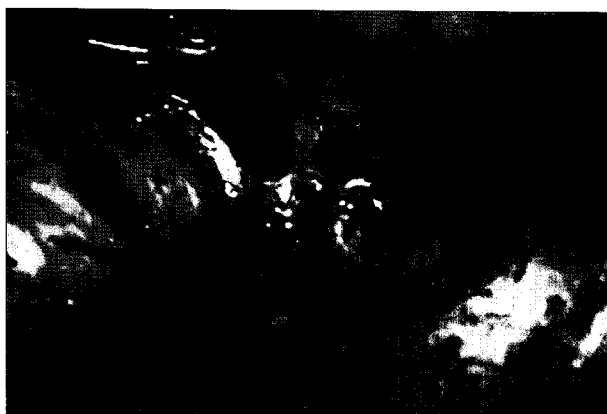

Fig. 3. When dividing the frontotemporal dural fold for anterior clinoid process removal, we used a backward-curved pair of scissors in the direction parallel to the ACP to avoid injury to the cranial nerves.

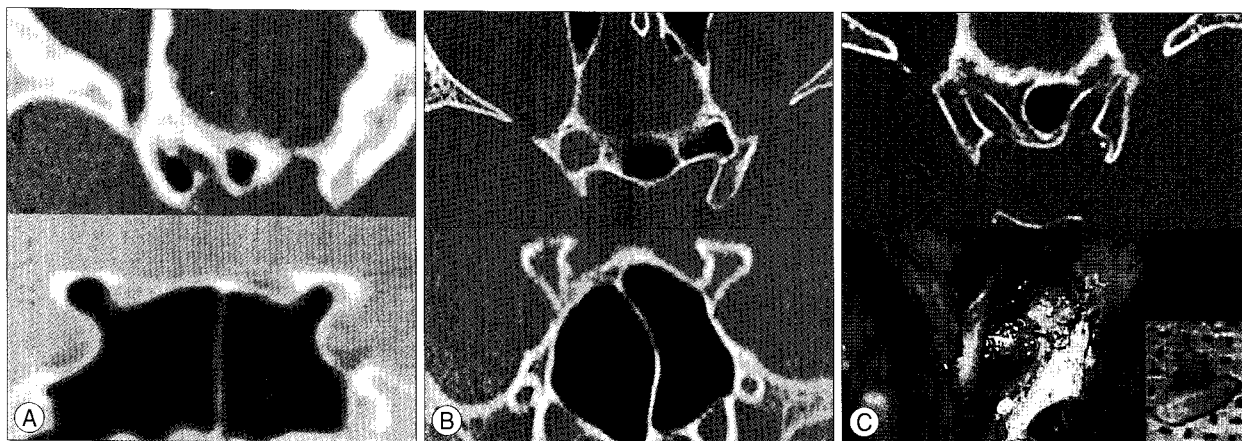


Fig. 4. Preoperative evaluation of the temporal bone by computed tomography (CT). A : Pneumatizations of the anterior clinoid process (ACP) and optical strut - type I²⁸⁾. B : Well developed ethmoid sinus. C : Erosive compression of the ACP in preoperative temporal bone CT and surgical findings.

cranial nerve palsies (25%), mostly of third cranial nerve, which has been previously reported^{6,9,19,38}. However, all nerve palsies were transient and recovered fully within one to six months of surgery. Cranial nerve palsies likely occurred as a result of the traction caused by the peeling of the lateral wall of the cavernous sinus. To prevent permanent nerve injuries, when dividing the FTDF for ACP removal, we used a backward-curved pair of scissors^{11,12} parallel, not perpendicular, to the ACP in order to avoid the injury of the cranial nerves (Fig. 3). We also partially cut only the FTDF and gently retracted its sleeve. When applying the clip, we were careful to confirm whether the end of clip blade injured a cranial nerve. In order to prevent injury while retracting the temporal lobe, the carotid-oculomotor membrane was opened sharply, and the lateral wall of cavernous sinus was peeled back.

Postoperative cerebrospinal fluid leakage

Although other groups^{8,19,32,38} have reported a relatively high incidence of postoperative cerebrospinal fluid leakage, this was not common in our study (4.2%). In our series, 15 incomplete dural closings and three ethmoid or sphenoid sinus openings associated with ACP removal were found. If distal dural rings are completely released and the dura around the ACP is defective, complete closing of the dura will be impossible in almost all cases. In such cases, we suture several points of the incision margin of the dura, and then cover the area with a free graft, such as with a piece of muscle or a small pericranial fascia flap, to prevent cerebrospinal fluid (CSF) leakage through the sphenoid sinus. After this, we reinforce the graft with fibrin glue. This procedure is performed repeatedly until two or three layers of grafting are fixed above the dural defect.

The opening of the ethmoid sinus can also result in postoperative CSF leakage and is associated with injury to the mucous membrane, which can occur during pneumatization of the ACP^{8,19,28,40}. However, this problem can be avoided if the sinus mucous membrane is preserved. In this study, the ethmoid sinus was opened in a few cases (12.5%), although we rarely found injuries to the mucous membrane. The mucous membrane can be preserved through careful preopera-

tive evaluation of the pneumatizations of the ACP and optical strut (OS)²⁸, ACP erosion, and the overall development of the ethmoid sinus². Through careful preoperative evaluations of the temporal bone CT, we were able to prevent mucosal injury to the ethmoid sinus. We analyzed all of the patients in this study for pneumatization of the ACP and OS, erosion of ACP, and for the development of the ethmoid sinus using a preoperative temporal bone CT. Computed tomography scans with a 0.6-mm thickness were obtained, and coronal and sagittal reconstructions of the images were displayed in all cases (Fig. 4). Mikami et al.²⁸ classified pneumatized patterns as type I, type II, and type III, according to the route of pneumatization, via the OS, the anterior root (AR), and both the OS and AR, respectively. We found only two cases of type I pneumatization of the ACP in our study. In those two cases, extremely careful drilling using a diamond bar was performed with ACP removal. Using this technique, the dissector gradually pushes it into the paranasal sinus if the mucous membrane is exposed (Fig. 5), and it can be packed by betadine gel-soaked Gelfoam. En bloc removal of the ACP is also possible after pushing the mucous membrane into the sinus. If the preoperative CT demonstrates erosion, resection of the ACP should be avoided¹⁸ or performed very carefully. In four of our cases the medial margin of clinoidectomy had to be performed carefully according to

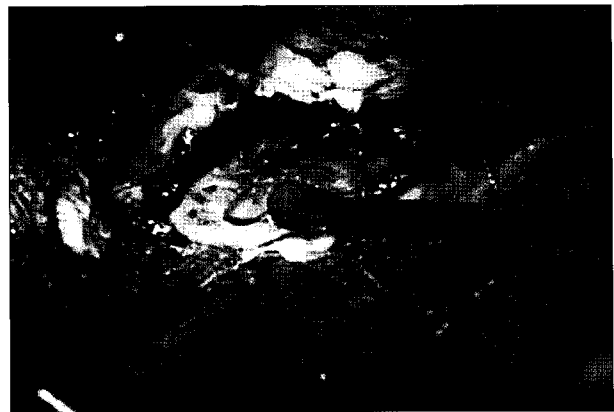


Fig. 5. When the mucosa membrane is exposed, it is detached from the bone and gradually pushed into the paranasal sinus by the dissector. *Sinus mucosal membrane.

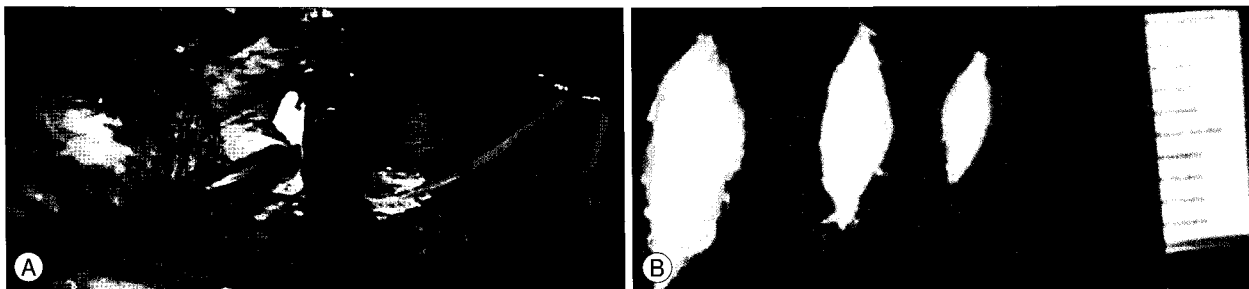


Fig. 6. Bleeding from the cavernous sinus can be well-controlled with gentle packing and hemostatic agents (A). The "cones" made by Avetene[®] is being used (B).

the development of the ethmoid sinuses on the temporal bone CT images, and the mucous membrane had to be pushed into the ethmoid sinus with a dissector. Nevertheless, it was covered with free graft such as a piece of muscle with a small pericranial flap when sinus mucosa was injured and fibrin glue was applied. We had only one postoperative CSF leakage, treated with these tactics, among all the patients. In this case, we performed lumbar spinal drainage followed by bed rest for a week, and the leakage resolved without any permanent morbidity.

Worsened vision

The surgical complication associated with permanent morbidity in our study was worsened vision, which is similar to previous reports^{11,19,25,32}. Rizzo³⁴ found two etiologies of worsened vision, including a fulminant orbital syndrome caused by the compromise of large draining veins of the orbit and a retrobulbar optic neuropathy caused either by direct injury or damage to the small dura vessels of the posterior optic nerve. Kumon²⁵ believed that the occurrence of visual disturbances resulted from injury to the ipsilateral optic nerve caused by excessive retraction or by the heat produced by the diamond drill. Therefore, when the bone is drilled and thinned until only a thin rim remains, care must be taken to avoid heat injuries to the optic nerve. Heat damage can be prevented with the use of continuous cold saline irrigations, and mechanical injury can be prevented with the use of a dissector or a microcurette to unroof the optic canal. Micro-punches or microrongeurs are never used until the optic canal is unroofed. Recently, the bone-cutting ultrasonic aspirator has been used in place of a drill for clinoidectomy. Chang et al.⁷ reported that, with an ultrasonic bone curette, unroofing of the optic canal could be safely completed, with low morbidity and mortality, and it required much less expertise to use the ultrasonic aspirator compared to that required to operate a standard drill. Therefore, there is no need to insert any instrument between the bone and the dura and no danger of thermal injury. Also, during the unroofing procedure, the edge of the bone should always be identifiable. However, the handpiece of the ultrasonic bone curette is somewhat bulky and hinders visibility within the deep and narrow operative field. As the tip of the ultrasonic bone curette is relatively smaller than larger regular drill bits, the resection of a large amount of bone is time-consuming. Finally, the use of this device does not automatically protect the soft tissues. Thus, the angle of the tip and the optic canal should be as close to perpendicular as possible.

Since the inferior lateral wall of the optic canal (situated between the optic nerve and the ICA, also known as the OS) can be removed only by drilling, this portion is drilled inter-

mittently in order to minimize the optic nerve's exposure to heat²⁵. Releasing of the optic nerve sheath at its lateral border reduces the force of retraction, as there is enough space between the nerve and the sheath. This technique allows for the observation of vessel circulation on the surface of the optic nerve, which allows for the detection of excessive retraction⁴⁰.

ICA occlusion and ischemia

Another complication associated with permanent morbidity in previous studies is ICA occlusion, which results in ischemic injury^{11,19,38}. Hoh et al.¹⁹ reported morbidity related to ICA occlusion (four patients, 2%) and other surgery-related ischemia (two patients, 1%) in 180 microsurgical treatments of paraclinoid aneurysms. Although we also experienced one unplanned ICA occlusion (4.2%), this occlusion did not result in any permanent neurological deficits. ICA occlusions can be prevented with the use of a variety of clips, including angled fenestrated clips, which are used for these types of aneurysms. If the aneurysm is thrombosed, a thrombectomy is required and an endarterectomy might also be needed. When an aneurysm cannot be clipped because of calcification within the aneurysm neck or because the aneurysm is incorporated into the ICA, a bypass with a vein graft or radial artery should be performed⁴. Proximal artery control is important in the microsurgical management of paraclinoid aneurysms but also presents a technical challenge. Many different methods have been developed to achieve proximal artery control, including intraoperative balloon occlusion of the ICA³⁵. In this study, we obtained proximal artery control through a cervical exposure prior to craniotomy and found this method to be safe, effective, and practical. Other authors have agreed that this small time investment is well worth the effort^{3,19,40}.

Hemostasis of the cavernous sinus

Hemostasis is also a concern in this procedure, as the outer layer of the lateral dural wall of the cavernous sinus must be carefully peeled away from the inner layer in order to expose the deepest inferolateral surface of the ACP; bleeding is common during this peeling procedure. When bleeding occurs, it is important to locate the original focus of bleeding. Bleeding from the cavernous sinus should be distinguished from bleeding from the dural draining vein, as the former can be well controlled with gentle packing with hemostatic agents (packing appears as "cones" made by the hemostatic agent (Fig. 6), while the latter requires bipolar coagulation. Furthermore, with bleeding from the cavernous sinus, overzealous sinus packing must also be avoided because of potential compressive injuries to the cranial nerves. Recently, another method was introduced that consists of injecting fibrin glue to achi-

eve coagulation during cavernous sinus bleeding²³). The fibrin glue fills the cavernous sinus by forming a local coagulum within the cavernous sinus. It obliterates the main venous channels that lead into the cavernous sinus space, which safely provides a dry cavernous sinus surgical field.

CONCLUSION

The surgical treatment of aneurysms that arise from the paraclinoid segment of the ICA has been a technical challenge for cerebrovascular surgeons. The authors have tried to avoid the several complications in extradural anterior clinoidectomy to paraclinoid aneurysms using several tactics. A backward-curved pair of scissors were used parallel to the ACP in order to avoid injuring the cranial nerves. The ACP was drilled carefully until only a thin rim remains with the cold saline irrigations. ICA occlusions can be prevented with the use of angled fenestrated clips. Also, careful attention on the origin of bleeding is advised when peeling the wall of cavernous sinus. Precise anatomical knowledge combined with these microsurgical tactics for preventing and managing potential challenges can help to achieve good outcomes with minimal complications.

References

1. Arnautović KI, Al-Mefty O, Angtuaco E : A combined microsurgical skull-base and endovascular approach to giant and large paraclinoid aneurysms. *Surg Neurol* 50 : 504-518; discussion 504-518, 1998
2. Avci E, Bademci G, Ozturk A : Microsurgical landmarks for safe removal of anterior clinoid process. *Minim Invasive Neurosurg* 48 : 268-272, 2005
3. Batjer HH, Kopitnik TA, Giller CA, Samson DS : Surgery for paraclinoid carotid artery aneurysms. *J Neurosurg* 80 : 650-658, 1994
4. Beretta F, Andaluz N, Zuccarello M : Aneurysms of the ophthalmic (C6) segment of the internal carotid artery : treatment options and strategies based on a clinical series. *J Neurosurg Sci* 48 : 149-156, 2004
5. Boet R, Wong GK, Poon WS, Lam JM, Yu SC : Aneurysm recurrence after treatment of paraclinoid/ophthalmic segment aneurysms—a treatment-modality assessment. *Acta Neurochir (Wien)* 147 : 611-616; discussion 616, 2005
6. Cawley CM, Zipfel GJ, Day AL : Surgical treatment of paraclinoid and ophthalmic aneurysms. *Neurosurg Clin N Am* 9 : 765-783, 1998
7. Chang HS, Joko M, Song JS, Ito K, Inoue T, Nakagawa H : Ultrasonic bone curettage for optic canal unroofing and anterior clinoidectomy. Technical note. *J Neurosurg* 104 : 621-624, 2006
8. Coscarella E, Başkaya MK, Morcos JJ : An alternative extradural exposure to the anterior clinoid process : the superior orbital fissure as a surgical corridor. *Neurosurgery* 53 : 162-166; discussion 166-167, 2003
9. De Jesús O, Sekhar LN, Riedel CJ : Clinoid and paraclinoid aneurysms : surgical anatomy, operative techniques, and outcome. *Surg Neurol* 51 : 477-487; discussion 487-488, 1999
10. Dolenc VV : A combined epi- and subdural direct approach to carotid-ophthalmic artery aneurysms. *J Neurosurg* 62 : 667-672, 1985
11. Dolenc VV : A combined transorbital-transclinoid and transsylvian approach to carotid-ophthalmic aneurysms without retraction of the brain. *Acta Neurochir Suppl* 72 : 89-97, 1999
12. Dolenc VV : Frontotemporal epidural approach to trigeminal neuromas. *Acta Neurochir (Wien)* 130 : 55-65, 1994
13. Drake CG, Vanderlinden RG, Amacher AL : Carotid-ophthalmic aneurysms. *J Neurosurg* 29 : 24-31, 1968
14. Fernandez Zubillaga A, Guglielmi G, Viñuela F, Duckwiler GR : Endovascular occlusion of intracranial aneurysms with electrically detachable coils : correlation of aneurysm neck size and treatment results. *AJNR Am J Neuroradiol* 15 : 815-820, 1994
15. Fox JL : Microsurgical treatment of ventral (paraclinoid) internal carotid artery aneurysms. *Neurosurgery* 22 : 32-39, 1988
16. Froelich SC, Aziz KM, Levine NB, Theodosopoulos PV, van Loveren HR, Keller JT : Refinement of the extradural anterior clinoidectomy : surgical anatomy of the orbitotemporal periosteal fold. *Neurosurgery* 61 : 179-185; discussion 185-186, 2007
17. Gurian JH, Viñuela F, Guglielmi G, Gobin YP, Duckwiler GR : Endovascular embolization of superior hypophyseal artery aneurysms. *Neurosurgery* 39 : 1150-1154; discussion 1154-1156, 1996
18. Heros RC : Paraclinoid aneurysms. *J Neurosurg* 96 : 647-648, 2002
19. Hoh BL, Carter BS, Budzik RF, Putman CM, Ogilvy CS : Results after surgical and endovascular treatment of paraclinoid aneurysms by a combined neurovascular team. *Neurosurgery* 48 : 78-89; discussion 89-90, 2001
20. Hope JK, Byrne JV, Molyneux AJ : Factors influencing successful angiographic occlusion of aneurysms treated by coil embolization. *Am J Neuroradiol* 20 : 391-399, 1999
21. Jin SC, Kwon do H, Song Y, Kim HJ, Ahn JS, Kwun BD : Multimodal treatment for complex intracranial aneurysms : clinical research. *J Korean Neurosurg Soc* 44 : 314-319; discussion 314-319, 2008
22. Kattner KA, Bailes J, Fukushima T : Direct surgical management of large bulbous and giant aneurysms involving the paraclinoid segment of the internal carotid artery : report of 29 cases. *Surg Neurol* 49 : 471-480, 1998
23. Krayenbühl N, Hafez A, Hernesniemi JA, Krisht AF : Taming the cavernous sinus : technique of hemostasis using fibrin glue. *Neurosurgery* 61 : E52; discussion E52, 2007
24. Krisht AF : Transcavernous approach to diseases of the anterior upper third of the posterior fossa. *Neurosurg Focus* 19 : E2, 2005
25. Kumon Y, Sakaki S, Kohno K, Ohta S, Ohue S, Oka Y : Asymptomatic, unruptured carotid-ophthalmic artery aneurysms : angiographical differentiation of each type, operative results, and indications. *Surg Neurol* 48 : 465-472, 1997
26. Kyoshima K, Kobayashi S, Orz IO : Ophthalmic aneurysms in Kaye AH, Black P (eds) : *Operative Neurosurgery*. London : Harcourt Publishers, 2000, pp973-984
27. Lanzino G, Wakhloo AK, Fessler RD, Hartney ML, Guterman LR, Hopkins LN : Efficacy and current limitations of intravascular stents for intracranial internal carotid, vertebral, and basilar artery aneurysms. *J Neurosurg* 91 : 538-546, 1999
28. Mikami T, Minamida Y, Koyanagi I, Baba T, Houkin K : Anatomical variations in pneumatization of the anterior clinoid process. *J Neurosurg* 106 : 170-174, 2007
29. Mizoi K, Takahashi A, Yoshimoto T, Fujiwara S, Kosu K : Combined endovascular and neurosurgical approach for paraclinoid internal carotid artery aneurysms. *Neurosurgery* 33 : 986-992, 1993
30. Ogilvy CS : Paraclinoid carotid aneurysms in Ojemann RG, Ogilvy CS, Crowell RM, Heros RC (eds) : *Surgical Management of Neurovascular Disease*, ed 3. Baltimore : Williams & Wilkins, 1995, pp185-213
31. Park HK, Horowitz M, Jungreis C, Kassam A, Koebbe C, Geneva J, et al. : Endovascular treatment of paraclinoid aneurysms: experience with 73 patients. *Neurosurgery* 53 : 14-23; discussion 24, 2003
32. Raco A, Frati A, Santoro A, Vangelista T, Salvati M, Delfini R, et al. : Long-term surgical results with aneurysms involving the ophthalmic segment of the carotid artery. *J Neurosurg* 108 : 1200-1210, 2008

33. Ricci G, Ricci A, Gallucci M, Zotta D, Scogna A, Costagliola C, et al. : Combined endovascular and microsurgical approach in the treatment of giant paraclinoid and vertebrobasilar aneurysms. *J Neurosurg Sci* 49 : 1-6, 2005
34. Rizzo JF : Visual loss after neurosurgical repair of paraclinoid aneurysms. *Ophthalmology* 102 : 905-910, 1995
35. Shucart WA, Kwan ES, Heilman CB : Temporary balloon occlusion of a proximal vessel as an aid to clipping aneurysms of the basilar and paraclinoid internal carotid arteries : technical note. *Neurosurgery* 27 : 116-119, 1990
36. Tanaka Y, Hongo K, Tada T, Nagashima H, Horiuchi T, Goto T, et al. : Radiometric analysis of paraclinoid carotid artery aneurysms. *J Neurosurg* 96 : 649-653, 2002
37. Viñuela F, Duckwiler G, Mawad M : Guglielmi detachable coil embolization of acute intracranial aneurysm : perioperative anatomical and clinical outcome in 403 patients. *J Neurosurg* 86 : 475-482, 1997
38. Xu BN, Sun ZH, Jiang JL, Wu C, Zhou DB, Yu XG, et al. : Surgical management of large and giant intracavernous and paraclinoid aneurysms. *Chin Med J (Engl)* 121 : 1061-1064, 2008
39. Yasargil MG, Gasser JC, Hodosh RM, Rankin TV : Carotid-ophthalmic aneurysms : direct microsurgical approach. *Surg Neurol* 8 : 155-165, 1977
40. Zhao J, Wang S, Zhao Y, Sui D, Zhang Y, Tang J, et al. : Microneurosurgical management of carotid-ophthalmic aneurysms. *J Clin Neurosci* 13 : 330-333, 2006
41. Zipfel GJ, Day AL : Surgical treatment of paraclinoid internal carotid artery aneurysms in Batjer HH, Loftus CM (eds) : *Textbook of Neurological Surgery*. Philadelphia : Lippincott, Williams & Wilkins, 2003, pp 2372-2382