

## Case Report

# Hemifacial Spasm Caused by a Huge Tentorial Meningioma

Hun Park, M.D., Sun-Chul Hwang, M.D., Bum-Tae Kim, M.D., Won-Han Shin, M.D.

Department of Neurosurgery, Soonchunhyang University College of Medicine, Bucheon Hospital, Bucheon, Korea

A rare case of hemifacial spasm caused by an ipsilateral tentorial meningioma is described. Magnetic resonance imaging showed a huge tumor in the right cerebellar hemisphere, distant to the cerebello-pontine cistern. The facial-vestibulocochlear nerve complex was stretched by the shift of the brainstem and the right cerebello-pontine cistern was effaced. After removing the tumor, the hemifacial spasm resolved completely. We review our case with the pertinent literature regarding the etiological mechanism.

**KEY WORDS :** Hemifacial spasm · Posterior fossa tumor · Meningioma.

## INTRODUCTION

Hemifacial spasm (HFS) is characterized by unilateral, intermittent contractions of the muscles of facial expression, which typically begin in the orbicularis oculi and spread to the other muscles of facial expression over several years<sup>7,8</sup>. In most cases, mechanical compression of the facial nerve at the root entry zone (REZ) by blood vessels is the main pathophysiological mechanism, and surgical treatment using microvascular decompression (MVD) is performed for the majority of patients. HFS can also develop as a result of other pathological conditions around the cerebello-pontine angle (CPA), such as tumors, aneurysms, or arteriovenous malformations involving the REZ of the affected facial nerve<sup>6,7,9,11,15,18,19</sup>.

Lesions distant to the CPA are very rare causes of HFS<sup>1,3,5,14,17</sup>. We report the unique case of a huge tentorial meningioma, which did not occupy the CPA. The patient presented with HFS, which resolved completely after microsurgical resection of the tumor.

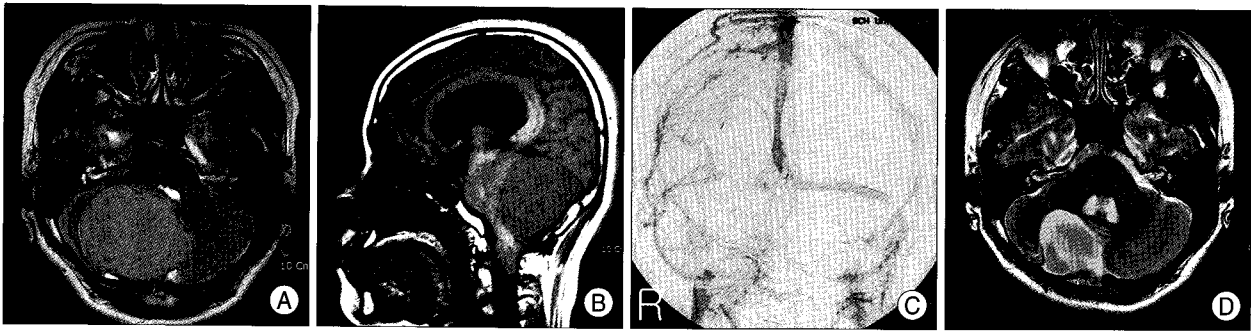
## CASE REPORT

A 34-year-old woman presented with involuntary twitches affecting her right face. The initial symptoms involved the right periorbital area and began 3 years earlier. Initially, she visited an oriental medicine clinic and was treated with acupuncture, but her condition was not improved. Her periorbital spasm worsened gradually in frequency and intensity and spread to the ipsilateral perioral region 5 months before admission. She complained of dizziness but had no hearing difficulties or dysphagia.

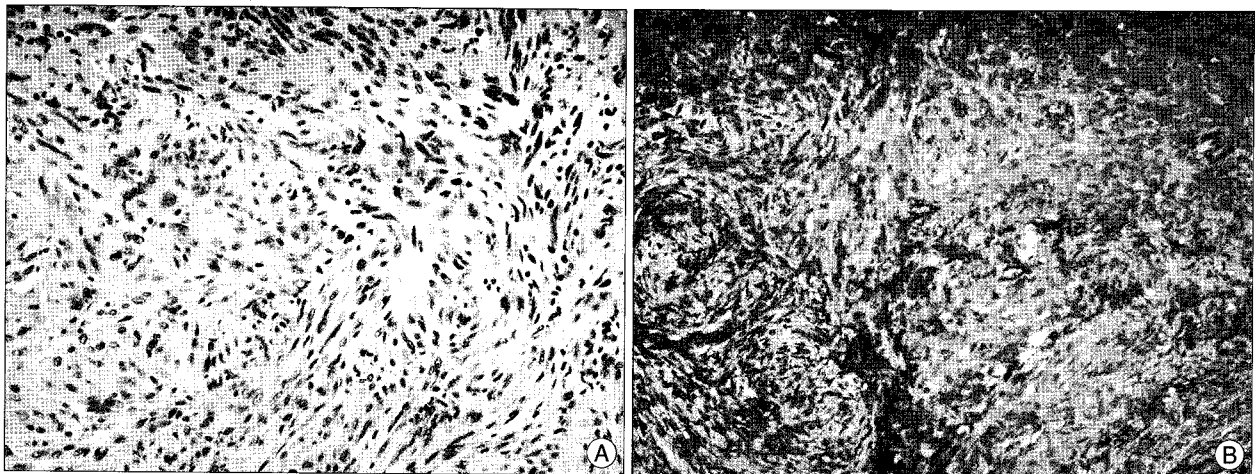
The neurological examination on admission was unremarkable, except for the right hemifacial spasm. The spasm started in the right periocular area and spread over the right perioral area. The spasm was aggravated by emotional stress or forced closure of the eye.

Preoperative brain magnetic resonance imaging (MRI) showed a 65 × 55 × 58-mm mass in the right posterior fossa with homogeneous high signal intensity in T2-weighted images and low signal intensity in T1-weighted images (Fig. 1A, B). The mass enhanced moderately. The mass displaced the brainstem and fourth ventricle ventrally, resulting in hydrocephalus. As the cerebellum and pons were displaced anteroinferiorly, the prepontine and cerebello-pontine cisterns were obliterated. The mass was not in direct contact with the CPA or brainstem. The right facial-vestibulocochlear nerve complex was kinked over the

• Received : December 23, 2008 • Revised : January 20, 2009  
• Accepted : August 17, 2009  
• Address for reprints : Sun-Chul Hwang, M.D.  
Department of Neurosurgery, Soonchunhyang University College of  
Medicine, Bucheon Hospital, 1174 Jung-dong, Wonmi-gu, Bucheon  
420-767, Korea  
Tel : +82-32-621-5291, Fax : +82-32-621-5016  
E-mail : sunchulh@sch.ac.kr



**Fig. 1.** Pre- and postoperative brain magnetic resonance images and catheter angiogram. A : Axial T2-weighted image shows a huge homogenous hyperintense mass in the right cerebellar hemisphere, distant to the cerebello-pontine cistern. The right facial-vestibulocochlear nerve complex is kinked and stretched over the internal acoustic meatus. B : The tumor displaced the cerebellum and brainstem anteroinferiorly in the sagittal image. C : Catheter angiogram showing the obstruction of the right transverse sinus. D : The axial T2-weighted image at 3 months after operation showing complete tumor removal and restoration of the displaced facial-vestibulocochlear nerve complex and obliterated cerebello-pontine angle.



**Fig. 2.** Pathology photomicrograph. A : Typical features of a fibrous meningioma with spindle cells in a collagen matrix (H&E; ×200). B : Immunohistochemical staining is positive for epithelial membrane antigen (EMA; ×200).

internal acoustic meatus compared with the left one (Fig. 1A). The right cerebello-pontine cistern was definitely separated from the tumor by the interposed cerebellar hemisphere and peduncle. On catheter angiography, the tumor blushed slightly when the right meningeal branches of the occipital artery were injected and the right transverse sinus was obliterated (Fig. 1C). The image features were compatible with a tentorial meningioma compressing the cerebellum and pons anteroinferiorly.

We planned only resection of tumor via a right suboccipital craniotomy. The tumor was partially exposed on the cerebellar hemisphere, from which it was well demarcated, and it was heavily vascularized. Repeated internal decompression of the tumor and dissection between the tumor and cerebellar hemisphere were performed. After resecting the hemispheric part of the tumor, the right transverse sinus, which was already occluded by the tumor, was ligated and divided. Most of the tumor was removed, although some were left around the straight sinus and confluence of sinuses to avoid injury to critical structures

that might result in massive bleeding and venous infarction. The histopathology revealed the typical findings of a fibrous meningioma with psammomatous calcification (Fig. 2).

Immediately after the operation, the frequency and intensity of the right hemifacial spasm were much improved, although spasm developed on forced grinning or wrinkling. Three weeks later, the patient was free from her facial spasms. MRI three months after the surgery showed a small residual mass around the straight sinus, and the right CPA was clearly visualized (Fig. 1D). The kinked facial-vestibulocochlear nerve complex had straightened compared with the preoperative images.

## DISCUSSION

Hemifacial spasm commonly results from unilateral vascular compression<sup>7,8)</sup> whereas it is rarely caused by ipsilateral pathology adjacent to the REZ of the facial nerve other than vascular compression<sup>2,4,6,10,11,15)</sup>. This unilateral hyperac-

tive dysfunction of facial nerve is manifested by spasm of the orbicularis oculi that slowly spreads to involve the orbicularis oris and all of the muscles of facial expression, including the platysma. Ectopic excitation and ephaptic transmission are important pathophysiological factors in idiopathic HFS<sup>12</sup>. It is generally accepted that the underlying cause in the majority of patients with idiopathic HFS is microvascular compression of the facial nerve at the site where the nerve exits the brainstem.

In 0.3 to 0.6% of reported cases, masses adjacent or close to the REZ of the facial nerve cause HFS, including epidermoid tumors, schwannomas, meningiomas, and cysts<sup>7,11</sup>. The pathophysiological mechanism is unclear. An electrophysiological study of four patients with HFS due to extra-axial tumors failed to differentiate between idiopathic and symptomatic HFS<sup>5</sup>. The authors recommended a neuroradiological work-up including MRI in all patients with HFS. Unfortunately, many CPA tumors presenting with HFS are treated with MVD in addition to tumor resection<sup>9,11,15</sup>. Therefore, it remains unclear whether the tumor results in demyelination of the facial nerve directly. A possible mechanism of the HFS caused by CPA tumors involves the tumor wrapping around or compressing the facial nerve as it grows, displacing the nerve away from the tumor, resulting in its being pinched between the tumor and artery. When the artery is located between the tumor and facial nerve, the artery may be trapped and begin to compress the nerve as the tumor grows. The standard surgical treatment for this tumor and the associated HFS is microsurgical removal of the tumor first, with MVD added selectively according to the anatomy around the CPA<sup>6,11,19</sup>.

Tumors remote to the CPA causing HFS are rarely reported and the pathogenic mechanism is not clear. In adults, reported lesions include tentorial meningiomas<sup>3,14</sup>, tumors in the fourth ventricle<sup>16,20</sup>, occipital falcine meningioma<sup>1</sup>, and contralateral CPA meningioma<sup>17</sup> and acoustic neuroma<sup>13</sup>. Fourth ventricle tumors may induce HFS as a result of direct compression of the facial colliculus and intramedullary facial nerve fibers<sup>4,20</sup>. Cancelli et al.<sup>3</sup> reported HFS due to a tentorial paramedian meningioma and suggested four mechanisms: 1) distortion and/or compression of the seventh nerve root; 2) accentuation of the pre-existing subclinical neurovascular conflict; 3) compression of the facial nucleus; and 4) venous outflow obstruction due to the dislocation of anatomical structures by the tumor mass or transverse sinus invasion. Ogasawara et al.<sup>14</sup> experienced a case of tentorial meningioma resulting in trigeminal neuralgia and HFS. They thought that the painful tic convulsif was probably produced by the tumor's compressing and displacing the brainstem directly, with

secondary neurovascular compression of the fifth and seventh cranial nerves.

The huge meningioma in our case arose at the tentorium and was not in direct contact with the brainstem or facial nerve. Nevertheless, it caused marked displacement of the brainstem and effacement of the CPA. In addition, the facial-vestibulocochlear nerve complex was distorted markedly by the shift of the brainstem. After removing the tumor, the HFS resolved completely without MVD, and the displaced brainstem and nerve complex returned to normal on postoperative brain MRI. The transverse sinus was ligated and divided during the operation, so that venous outflow obstruction was an unlikely cause of her HFS, as the symptoms recovered postoperatively. Two etiologic mechanisms can be inferred from the radiological findings and clinical result in our case. First, the crowding of the CPA caused by the huge mass may have brought the facial nerve into contact with vascular structures. Second, the stretched facial nerve may be sensitive to vascular stimulation. As the HFS resolved completely after removing the tumor, the HFS caused by distant tumors that do not involve the ipsilateral CPA can be observed and evaluated after resecting the tumors.

## CONCLUSION

A posterior fossa tumor that does not involve the CPA may induce HFS. Although the precise mechanism is not clear, simple removal of the tumor can relieve the HFS.

## References

1. Bhayani R, Goel A : Occipital falcine meningioma presenting with ipsilateral hemifacial spasm: a case report. *Br J Neurosurg* 10 : 603-605, 1996
2. Brodsky JR, Smith TW, Litofsky S, Lee DJ : Lipoma of the cerebellopontine angle. *Am J Otolaryngol* 27 : 271-274, 2006
3. Cancelli I, Cecotti L, Valentini L, Bergonzi P, Gigli GL : Hemifacial spasm due to a tentorial paramedian meningioma : a case report. *Neurol Sci* 26 : 46-49, 2005
4. Glocker FX, Krauss JK, Deuschl G, Seeger W, Lücking CH : Hemifacial spasm due to posterior fossa tumors : the impact of tumor location on electrophysiological findings. *Clin Neurol Neurosurg* 100 : 104-111, 1998
5. Harrison GS, Chovan P, Lee JH : Hemifacial spasm due to a large distant ipsilateral posterior fossa meningioma. *Skull Base Surg* 10 : 43-45, 2000
6. Iwai Y, Yamanaka K, Nakajima H : Hemifacial spasm due to cerebellopontine angle meningiomas-two case reports. *Neurol Med Chir (Tokyo)* 41 : 87-89, 2001
7. Jannetta PJ, Abbasy M, Maroon JC, Ramos FM, Albin MS : Etiology and definitive microsurgical treatment of hemifacial spasm. Operative techniques and results in 47 patients. *J Neurosurg* 47 : 321-328, 1977
8. Kim P, Fukushima T : Observations on synkinesis in patients with hemifacial spasm. Effect of microvascular decompression and etiological considerations. *J Neurosurg* 60 : 821-827, 1984

9. Kobata H, Kondo A, Iwasaki K : Cerebellopontine angle epidermoids presenting with cranial nerve hyperactive dysfunction : pathogenesis and long-term surgical results in 30 patients. *Neurosurgery* 50 : 276-285; discussion 285-286, 2002
10. Matsumoto K, Sakurai M, Asari S, Nishimoto A : Hemifacial spasm due to cerebellopontine angle epidermoid tumor-case report. *Neurol Med Chir (Tokyo)* 31 : 410-413, 1991
11. Nagata S, Matsushima T, Fujii K, Fukui M, Kuromatsu C : Hemifacial spasm due to tumor, aneurysm, or arteriovenous malformation. *Surg Neurol* 38 : 204-209, 1992
12. Nielsen VK : Pathophysiology of hemifacial spasm : I. Ephaptic transmission and ectopic excitation. *Neurology* 34 : 418-426, 1984
13. Nishi T, Matsukado Y, Nagahiro S, Fukushima M, Koga K : Hemifacial spasm due to contralateral acoustic neuroma : case report. *Neurology* 37 : 339-342, 1987
14. Ogasawara H, Oki S, Kohno H, Hibino S, Ito Y : Tentorial meningioma and painful tic convulsif. Case report. *J Neurosurg* 82 : 895-897, 1995
15. Park CF, Rhee BA, Park JT, Lim YJ, Kim TS, Leem W, et al : Hemifacial spasm associated with benign cyst. *J Korean Neurosurg Soc* 28 : 363-367, 1999
16. Rapanà A, Guida F, Conti C, Rizzo G, Trincia G : Ependymoma of the fourth ventricle presenting with hemifacial spasm. Report of a case. *Rev Neurol (Paris)* 155 : 309-311, 1999
17. Rhee BA, Kim TS, Kim GK, Leem WL : Hemifacial spasm caused by contralateral cerebellopontine angle meningioma : case report. *Neurosurgery* 36 : 393-395, 1995
18. Sato K, Ezura M, Takahashi A, Yoshimoto T : Fusiform aneurysm of the vertebral artery presenting hemifacial spasm treated by intravascular embolization : case report. *Surg Neurol* 56 : 52-55, 2001
19. Shenouda EF, Moss TH, Coakham HB : Cryptic cerebellopontine angle neuroglial cyst presenting with hemifacial spasm. *Acta Neurochir (Wien)* 147 : 787-789; discussion 789, 2005
20. Weiner HL, Zagzag D, Babu R, Weinreb HJ, Ransohoff J : Schwannoma of the fourth ventricle presenting with hemifacial spasm. A report of two cases. *J Neurooncol* 15 : 37-43, 1993