

## Clinical Article

# Types of Thromboembolic Complications in Coil Embolization for Intracerebral Aneurysms and Management

Hong-Ki Kim, M.D., Sung-Kyun Hwang, M.D., Sung-Hak Kim M.D.

Department of Neurosurgery, School of Medicine, Ewha Womans University, Seoul, Korea

**Objective :** We describe our clinical experiences and outcomes in patients who had thromboembolic complications occurring during endovascular treatment of intracerebral aneurysms with a review of the literature. The types of thromboembolic complications were divided and the treatment modalities for each type were described.

**Methods :** Between August 2004 and March 2009 we performed endovascular embolization with Guglielmi detachable coils for 173 patients with 189 cerebral aneurysms, including ruptured and unruptured aneurysms at our hospital. Sixty-eight patients were males and 105 patients were females. The age of patients ranged from 22-82 years (average, 58.8 years). We retrospectively evaluated this group with regard to complication rates and outcomes. The types of thromboembolic complications were classified into the following three categories: mechanical obstruction, distal embolic stroke, and stent-induced complications, which corresponded to types I, II, and III, respectively. A comparison of the clinical results was made for each type of complication.

**Results :** Only eight patients had a thromboembolic complication during or after a procedure (4.6%). Of the eight patients, two had a mechanical obstruction as the causative factor; the other three patients had distal embolic stroke as the causative factor. The remaining three patients had stent-induced complications. In cases of mechanical obstruction, recanalization occurred due to the use of intra-arterial thrombolytic agents in one of two patients. Nevertheless, a poor prognosis was seen. In the cases of stent-induced complications, in one of three patients in whom a thrombus developed following stent insertion, a middle cerebral artery territory infarct developed with a poor prognosis despite the use of wiring and an intra-arterial thrombolytic agent. In the cases of distal embolic stroke, all three patients achieved good results following the use of antiplatelet agents.

**Conclusion :** Treatment for thromboembolic complications due to mechanical obstruction and stent-induced complications include antiplatelet and intra-arterial thrombolytic agents; however, this cannot guarantee a sufficient extent of effectiveness. Therefore, active treatments, such as balloon angioplasty, stent insertion, and clot extraction, are helpful.

**KEY WORDS :** Thromboembolism · Coil embolization · Mechanical obstruction · Distal embolic stroke · Stent-induced complication.

## INTRODUCTION

The endovascular treatment of an intracranial aneurysm using Guglielmi detachable coils (GDCs) was first introduced by Guglielmi et al. in 1991<sup>10</sup>. Since then, GDC treatment has undergone rapid change, and recent advanced techniques make it possible to improve anatomic and

clinical outcomes<sup>15,18,23</sup>. Although this treatment has become an accepted alternative to surgery, thromboembolic events still constitute the main complication<sup>16,20</sup>.

The development of new materials and advances of vascular catheterization techniques have made it possible to treat various diseases via an endovascular approach in the last decade. With the growing use of endovascular procedures in neurosurgical practice, adequate knowledge of basic pathophysiologic principles is important.

The types of thromboembolic complications have been divided and the treatment modalities for each type are described. Our clinical experiences and outcomes in patients who had thromboembolic complications during endo-

• Received : May 13, 2009 • Revised : August 8, 2009

• Accepted : August 8, 2009

• Address for reprints : Sung-Kyun Hwang, M.D.

Department of Neurosurgery, School of Medicine, Ewha Womans University, Mok-dong Hospital, 911-1 Mok-dong, Yangcheon-gu, Seoul, Korea

Tel : +82-2-2650-2658, Fax : +82-2-2655-0948

E-mail : nshsg@ewha.ac.kr

vascular treatment of intracerebral aneurysms are described with a review of the literature.

## MATERIALS AND METHODS

Between August 2004 and March 2009, we performed endovascular embolization with GDCs for 173 patients with 189 cerebral aneurysms including ruptured and unruptured aneurysms at our hospital. Sixty-eight patients were males and 105 patients were females. The age of patients ranged from 22-82 years (average, 58.8 years). All ruptured aneurysms were treated within 2 weeks. In this study, we retrospectively evaluated this group of patients with regard to complication rates and outcomes.

Thromboembolic complications were classified into three types. Type I was defined as a thromboembolic complication due to mechanical obstruction. Type II was defined as a thromboembolic complication due to a distal embolic stroke. Type III was defined as stent-induced complications.

The locations of the aneurysms are summarized in Table 1. One-hundred-seventy aneurysms were small (diameter, < 10 mm), 17 aneurysms were large (diameter, 10-25 mm), and 2 aneurysms were giant (diameter, > 25 mm). One-hundred-fifty aneurysms had small necks (diameter, 4 mm), and 39 aneurysms had wide necks (diameter, 4 mm). The method used for such measurements has been pub-

lished previously<sup>2,5,9,10,14,15,21,23</sup>.

## RESULTS

In patients who were included in the analysis, there were neurologic symptoms which developed after coiling. In cases in which the symptoms were confirmed on imaging studies, such as CT or MRI scans, these symptoms were included in the category. A blockage of the blood flow was confirmed on angiography. Clots were noted during angiography, but if there was no clinical evidence of cerebral ischemia, such events were not recorded as complications. Of 173 patients, only 8 (4.6%) had thromboembolic complications during or after the procedure (Table 2). Of eight patients, two had a mechanical obstruction as the causative factor; the other three patients had distal embolic stroke as the causative factor. The remaining three patients had stent-induced complications. In cases of mechanical obstruction, recanalization occurred due to the use of intra-arterial thrombolytic agents in one of two patients; nevertheless, a poor prognosis was achieved. In cases of stent-induced complications, in one of three patients in whom a thrombus developed following stent insertion, a middle cerebral artery (MCA) territory infarct developed with poor prognosis despite the use of wiring and an intra-arterial thrombolytic agent. In the remaining two patients, recanalization was achieved due to the use of wiring and an intra-arterial thrombolytic agent. One patient developed transient dysphasia; however, a good prognosis was achieved. In cases of distal embolic stroke, all three patients achieved good results following the use of antiplatelet agents. All of these three patients had MCA bifurcation aneurysms. Following the onset of a MCA branch infarct, a hemorrhagic transformation was shown. In two patients, a surgical hematoma evacuation was performed and good clinical results were obtained.

**Table 1.** Locations of aneurysms (n = 189)

Locations	No
Internal carotid artery	26
Anterior communicating artery	40
Distal anterior cerebral artery	8
Anterior choroidal artery	7
Middle cerebral artery	40
Posterior communicating artery	48
Basilar tip	9
Vertebral and Basilar artery	11

**Table 2.** Patients with thromboembolic complications

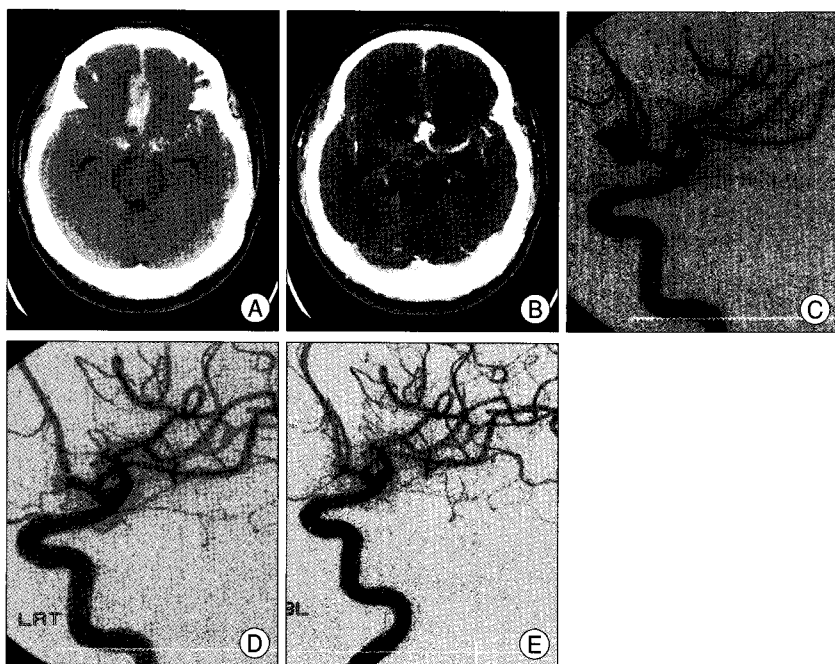
No	Age (years)/ Gender	Site	Size (mm)	Hunt and Hess grade at presentation	Type	Comment	GOS
1	48/M	ACOM	8 × 3.5	4	Mechanical obstructio	Recanalization by intraarterial thrombolysis	2
2	50/F	ICA	2 × 3	Unruptured	Stent-induced complication	Recanalization	5
3	45/F	MCA	4 × 5	Unruptured	Embolic stroke	Hemorrhagic transformation	5
4	44/F	MCA	6.5 × 7	Unruptured	Embolic stroke	Hemorrhagic transformation	5
5	41/F	MCA	15 × 10	2	Embolic stroke	Hemorrhagic transformation	5
6	65/F	PCOM	2 × 4	2	Stent-induced complication	Infarction	2
7	57/F	ICA	10 × 10	3	Mechanical obstruction	Recanalization by stent	5
8	69/F	PCOM	11 × 9	Unruptured	Stent-induced complication	Transient dysphasia	5

ACOM : anterior communicating artery aneurysm, GOS : Glasgow outcome scale, ICA: internal carotid artery aneurysm, MCA : middle cerebral artery aneurysm, PCOM : posterior communicating artery aneurysm.

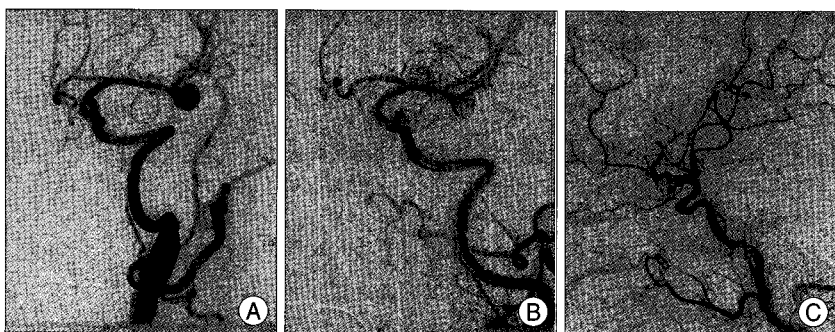
**Case presentation**

**Case 1**

A 48-year-old male presented for evaluation with a ruptured anterior communicating artery aneurysm (Fig. 1A, B) with a subarachnoid hemorrhage (Hunt-Hess grade 4). His mental status was stuporous. During coil embolization, (Fig. 1C) a right anterior cerebral artery (A2) was occluded after coil embolization of the aneurysm (Fig. 1D). The patient was then given 10 mg of Reopro and 200,000 U of Urokinase intra-arterially for recanalization. Following the procedure, an angiogram showed patency of a right anterior cerebral artery (Fig. 1E). Although 3-H therapy and intensive care was given, the patient's neurologic symptoms had not recovered.



**Fig. 1.** Presentation of case 1. A and B : Brain computed tomography scan shows subarachnoid hemorrhage with anterior communication artery aneurysm. C : Digital subtraction angiogram shows saccular aneurysmal sac at anterior communicating artery aneurysm, which is embolized with detachable coils. D and E : During coil embolization, thromboembolic clot occlude ipsilateral anterior cerebral artery (A2). With thrombolysis with urokinase (200,000 unit) and Reopro (10 mg), occluded artery is successfully recanalized.



**Fig. 2.** Angiogram for case 4. A and B : Digital subtraction angiogram shows saccular aneurysmal sac at middle cerebral artery aneurysm, which is embolized with detachable coils. C : Angiogram shows occlusion of left M2.

**Case 4**

A 44-year-old female presented for evaluation with an unruptured left MCA bifurcation aneurysm on MRA. The patient did not suffer from any underlying disease, and no neurologic symptoms existed. During coil embolization, a flow of the left MCA (M2) was suddenly diminished after coil embolization of the aneurysm. The patient was then given 100,000 U of Urokinase intra-arterially for recanalization; however, cerebral blood flow was not recovered (Fig. 2). After the procedure, the patient was sent to the neurosurgery intensive care unit and given aspirin and Plavix. The patient did not have any neurologic deterioration although a follow-up CT image showed a low density lesion in the left MCA territory. The patient suddenly developed dysarthria after 8 days. A follow-up CT image showed a high density lesion in the left frontal lobe with surrounding edema (Fig. 3A). Hematoma evacuation was immediately performed (Fig. 3B). The patient's neurologic symptoms were recovered after 7 days and discharged without any neurologic deficits.

**Case 6**

A 65-year-old female presented for evaluation of a ruptured left posterior communicating cerebral artery aneurysm with a subarachnoid hemorrhage (Hunt-Hess grade 2)(Fig. 4A, B). Digital subtraction angiogram showed another aneurysm involving the left anterior choroidal artery (Fig. 4C). During coil embolization, flow in the left internal cerebral artery was suddenly diminished after stent insertion (Fig. 4D). The patient was then given 100,000 U of Urokinase intra-arterially for recanalization and wiring was performed for removal of the thrombus in the stented vessel. The patient presented with severe neurologic symptoms, such as mental changes, hemiplegia, and global aphasia. The patient was sent to the neurology intensive care unit and 3-H therapy was performed. The CT image showed a low density lesion involving the left MCA territory (Fig. 4E). The patient's mental status was recovered after 7 days and global ap-

hasia was recovered after 14 days. The patient was transferred to the Department of Rehabilitation Medicine with hemiplegia.

## DISCUSSION

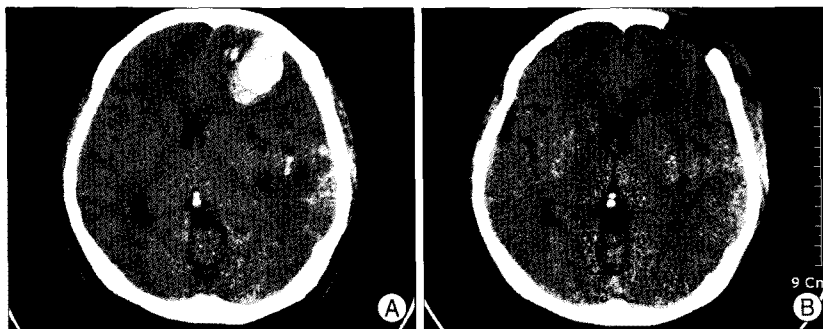
Thromboembolic complications are reported in 5-10% of patients treated endovascularly<sup>2,12,14,16,17,23</sup>, though permanent deficit are less frequent with rates of 1-5%<sup>5,8,9</sup>. Associations between the development of thrombosis, the size of the catheter/introducer, and the duration of the procedure have been established. Thromboembolic complications of coiling are most commonly recognized as distal emboli<sup>5,16</sup> on angiography and less commonly occur with a filling defect at the coil-ball/parent-artery junction<sup>22</sup>,

however, we experienced an increased prevalence of local thromboses. An aneurysm with a large diameter and coil protrusion are independent risk factors for post-procedural thromboembolic events<sup>8</sup>. Stroke, usually from a thrombus in the parent vessel with downstream embolization, remains a significant problem. The actuarial risk of stroke associated with aneurysm coiling has been found by one group in a retrospective study that only studied at good-grade patients to equal 3.8%<sup>8,11</sup>. In addition to clinically recognizable clots and strokes, silent infarcts are often detected on post-procedure diffusion-weighted magnetic resonance imaging. There is evidence that these events are quite common<sup>13,19,21</sup>. The outcome of the International Subarachnoid Aneurysm Trial was encouraging. There are no prospective published data pertaining to neuroendovascular technical problems. It

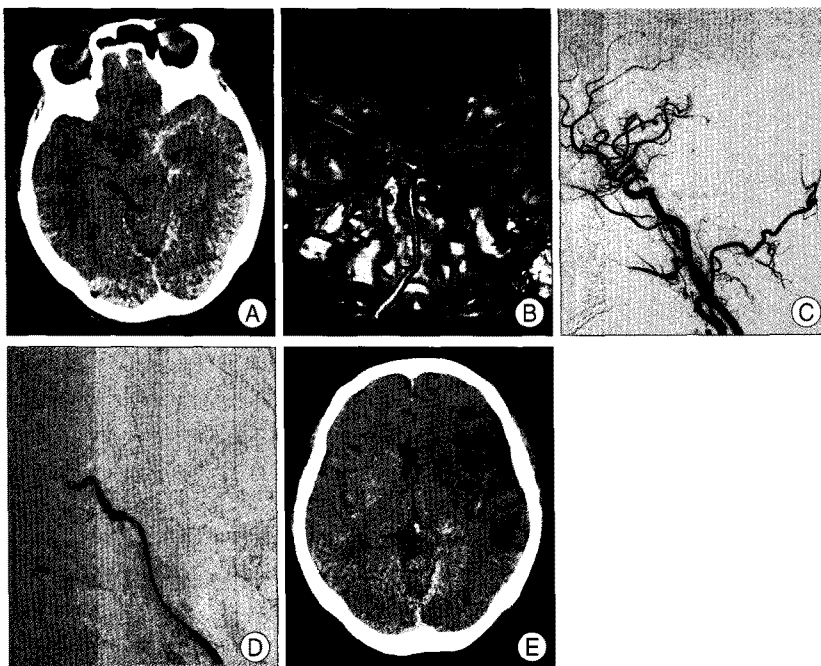
is important that endovascular specialists share their poor outcome data, not only to educate their colleagues on the pitfalls of endovascular treatment, but also to improve the level of care.

There are many possible sources for embolic events during GDC treatment of cerebral aneurysms, including friable plaques and iatrogenic dissection in the parent vessels, air bubbles, and thrombus or fresh clots within aneurysms and catheters<sup>1,19</sup>. On the other hand, the location of the lesion depends on both the flow patterns in the patient's brain and other unresolved factors. The brain border zone is a favored destination for microemboli because this area has an inadequate blood supply, and once the blood supply is disturbed by microemboli, this area might be at risk for infarction<sup>20</sup>. Thromboembolic complications can be silent initially, becoming symptomatic only when the infarct enlarges.

Treatment of thrombus formation may be local (mechanical clot extraction and/or disruption)<sup>6,24</sup>, and abciximab<sup>24</sup>, or a combination. Treatment of thrombotic complications in ruptured aneurysms requires a fine balance between maintaining intra-aneurysmal occlusion (to which coil packing and thrombosis contribute)<sup>3</sup> and lysis



**Fig. 3.** Brain computed tomography for case 4, brain CT shows hemorrhagic. A : Brain CT scan shows hemorrhagic transformation on left frontal lobe. B : Post-operation CT scan shows total evacuation of hemorrhagic transformation.



**Fig. 4.** Presentation of case 6. A and B : Brain computed tomography (CT) scan and 3-D CT angiogram shows subarachnoid hemorrhage and two aneurysms at left posterior communicating and anterior choroidal artery. C and D : Digital subtraction 3-D angiogram shows two aneurysms and occlusion of intracerebral artery after stent insertion. E : Brain CT scan shows infarction of middle cerebral artery territory.

of the thrombus in the parent artery. Its action is prolonged and, though reduced, it may persist as long as a week after administration. In contrast to heparin, abciximab is not easily reversed. Despite these theoretic effects, abciximab has been used for carotid and vertebrobasilar rescue and for the treatment of acute stroke, without a substantial increase in intracerebral hemorrhage. Therefore, abciximab does not appear to have intracranial risk on par with that of thrombolytic agents; this was observed at the time of diagnostic angiography immediately before emergency coiling. Abciximab immediately cleared the soft basilar thrombus, but the focal thrombus persisted at the origin of the superior cerebellar artery. This clot did not respond to attempted mechanical disruption using a guidewire, leading us to conclude that this was hard, atheroembolic material which dislodged from the vertebral artery dissection. We suggest that an infusion may potentially confer an additional and unnecessary risk of hemorrhage. Post-procedural anticoagulation can be effectively maintained with heparin followed by aspirin and/or clopidogrel. Technical complications associated with the use of GDCs include aneurysmal perforation and rupture, parent artery occlusion, cerebral embolism, coil migration, vasospasm, and hemodynamic ischemia with inadequate collateral reserve. The largest contributor to complications of GDC treatments is iatrogenic brain ischemia caused by thromboembolic events<sup>7,15,20</sup>. This may be caused by thrombolysis in the aneurysm sac, or herniation of the coils into the parent vessel. Although clinical thromboembolic complications have been reported to occur in a range of 1.0-28%, the complications in these studies are defined as new focal deficits, a change in mental status, or abnormalities on post-procedural computed tomography or conventional magnetic resonance imaging<sup>10,15</sup>. Rordorf et al.<sup>19</sup> suggested that thromboembolic events related to GDC techniques may be more common than what have been reported; in fact, silent embolism occurred in 61% of the 14 cases in their study. In a more extensive prospective study, Chung et al.<sup>4</sup> suggested that silent embolism occurred in 60% of 163 cases. GDC treatment is effective with an acceptable morbidity rate for small aneurysms with a small neck owing to the high initial success rate and low mortality and morbidity rates<sup>10,15</sup>. In wide-neck and large aneurysms, however, the combined use of the balloon-assisted technique enables a denser packing of aneurysms and markedly improves the anatomic results after the treatment. Some authors reported that the occurrence of thromboembolic events with the use of the balloon-assisted technique was not different from that of the conventional GDC technique. However, this technique requires sophisticated hand-

ing, frequent use of guidewires and microcatheters, temporary occlusion of the parent vessel, and repeated inflation and deflation of the balloon. Use of the balloon-assisted technique is theoretically a risk factor for thromboembolic complications because the risk of significant emboli will likely increase with increasing procedural complexity, potential sites for the generation of microemboli increase, and the procedure time is longer. On the other hand, the process of intra-aneurysmal clot organization in large aneurysms is delayed and incomplete, and it may cause delayed post-procedure ischemic events. Derdeyn et al.<sup>8</sup> reported that a larger aneurysm diameter and protruding loops of coils are risk factors for post-procedure ischemic events after GDC treatment. The current results showed that the occurrence of thromboembolic events depends on the procedural complexity, such as larger aneurysms, and the use of balloon-assisted techniques. Therefore, in the case of wide-neck or large aneurysms, we have to balance the risk of thromboembolic events and the better anatomic outcome associated with the balloon-assisted technique.

Bendszus et al.<sup>11</sup> reported that a silent embolism related to diagnostic angiography occurred in 26% of their cases. Their embolic lesions were located in the distal vascular territory of small cortical, subcortical, or perforating vessels. Whenever possible, clot disruption by fragmentation is carried out before and in combination with chemical thrombolysis; clot fragmentation alone is never used as the sole solution. The purpose of fragmentation is two-fold : to establish flow beyond the thrombus, permitting passage of the fibrinolytic drug, the heparin, and the intrinsic fibrinolytic factors into the occluded area, and to increase the surface of the clot accessible to the drug. The results of combination of clot fragmentation and fibrinolysis suggest that fragmentation and super-selective drug infusion may improve the rate of recanalization. The rate of recanalization indicates that the early administration of a fibrinolytic drug increases the chances of favorable clot dissolution. Spontaneous thrombolysis has been estimated to be 20% during the first 24 hours and 80% within the first week after ictus.

We believe that fibrin or thrombus formation was induced at the tip of the catheter or around the coil. However, on some occasions, the occlusive material may have been an embolus from a pre-existing thrombosis within the aneurysmal sac that was dislodged during coil maneuvering. These emboli originate from thrombotic material a long time before anticoagulant therapy is given, resulting in clots with different characteristics. Another factor that must be considered is the different vulnerability to ischemia found in different regions of the brain. It is our recommen-

ation that the risks of clotting do not correlate with the size of the aneurysm, but rather with its location and with the extent of experience of the physician in charge.

## CONCLUSION

This study revealed that the incidence of symptomatic thromboembolic events after coil embolization was similar to previously reported studies. In the current study, the number of cases was too small for a statistical analysis. There were differences in the treatment effects on thromboembolic complications between the cases, which restricted the objective assessments. Based on the current study, however, the treatments for thromboembolic complication due to mechanical obstruction and stent-induced complications include antiplatelet and intra-arterial thrombolytic agents. But, more active treatments, such as balloon angioplasty with stent insertion and clot extraction, are also needed. In contrast, in cases of distal embolic stroke, with the use of an antiplatelet agent, blood flow was improved and a good prognosis was achieved. Therefore, the use of an antiplatelet and intra-arterial thrombolytic agent could lead to the improvement of symptoms. Moreover, the technical expertise and experience could also be helpful for reducing these complications to a considerable extent. Interventionists should make every effort to achieve this.

## References

- Bendszus M, Koltzenburg M, Burger R, Warmuth-Metz M, Hofmann E, Solymosi L : Silent embolism in diagnostic cerebral angiography an neurointerventional procedures : a prospective study. *Lancet* 354 : 1594-1597, 1999
- Brilstra EH, Rinkel GJ, van der Graaf Y, van Rooij WJ, Algra A : Treatment of intracranial aneurysms with embolization with coils : a systematic review. *Stroke* 30 : 470-476, 1999
- Byrne JV, Hope JK, Hubbard N, Morris JH : The nature of thrombosis induced by platinum and tungsten coils in saccular aneurysms. *AJNR Am J Neuroradiol* 18 : 29-33, 1997
- Chung SW, Baik SK, Kim Y, Park J : Thromboembolic events after coil embolization of cerebral aneurysms : Prospective study with diffusion-weighted magnetic resonance imaging follow-up. *J Korean Neurosurg Soc* 43 : 275-280, 2008
- Cognard C, Weill A, Castaings L, Rey A, Moret J : Intracranial berry aneurysms : angiographic and clinical results after endovascular treatment. *Radiology* 206 : 499-510, 1998
- Cronqvist M, Pierot L, Boulin A, Cognard C, Castaings L, Moret J : Local intraarterial fibrinolysis of thromboemboli occurring during endovascular treatment of intracerebral aneurysm : a comparison of anatomic results and clinical outcome. *AJNR Am J Neuroradiol* 19 : 157-165, 1998
- Debrun GM, Viñuela FV, Fox AJ : Aspirin and systemic heparinization in diagnostic and interventional neuroradiology. *AJR Am J Roentgenol* 139 : 139-142, 1982
- Derdeyn CP, Cross DT 3rd, Moran CJ, Brown GW, Pilgram TK, Diringner MN, et al. : Postprocedure ischemic events after treatment of intracranial aneurysms with Guglielmi detachable coils. *J Neurosurg* 96 : 837-843, 2002
- Eskridge JM, Song JK : Endovascular embolization of 150 basilar tip aneurysms with Guglielmi detachable coils : results of the Food and Drug multicenter clinical trial. *J Neurosurg* 89 : 81-86, 1998
- Guglielmi G, Viñuela F, Dion J, Duckwiler G : Electrothrombosis of saccular aneurysms via endovascular approach. Part 2 : Preliminary clinical experience. *J Neurosurg* 75 : 8-14, 1991
- Henkes H, Fischer S, Weber W, Miloslavski E, Felber S, Brew S, et al. : Endovascular coil occlusion of 1811 intracranial aneurysms : early angiographic and clinical results. *Neurosurgery* 54 : 268-280; discussion 280-285, 2004
- Horowitz M, Samson D, Purdy P : Does electrothrombosis occur immediately after embolization of an aneurysm with Guglielmi detachable coils? *AJNR Am J Neuroradiol* 18 : 510-513, 1997
- Klötzsch C, Nahser HC, Henkes H, Kühne D, Berlir P : Detection of microemboli distal to cerebral aneurysms before and after therapeutic embolization. *AJNR Am J Neuroradiol* 19 : 1315-1318, 1998
- McDougall CG, Halbach VV, Dowd CF, Higashida RT, Larsen DW, Hieshima GB : Endovascular treatment of basilar tip aneurysms using electrolytically detachable coils. *J Neurosurg* 84 : 393-399, 1996
- Murayama Y, Viñuela F, Duckwiler GR, Gobin YP, Guglielmi G : Embolization of incidental cerebral aneurysms by using the Guglielmi detachable coil system. *J Neurosurg* 90 : 207-214, 1999
- Pelz DM, Lownie SP, Fox AJ : Thromboembolic events associated with the treatment of cerebral aneurysms with Guglielmi detachable coils. *AJNR Am J Neuroradiol* 19 : 1541-1547, 1998
- Pruvo JP, Leclerc X, Ares GS, Lejeune JP, Leys D : Endovascular treatment of ruptured intracranial aneurysms. *J Neurol* 246 : 244-249, 1999
- Qureshi AI, Suri MF, Khan J, Kim SH, Fessler RD, Ringer AJ, et al. : Endovascular treatment of intracranial aneurysms by using Guglielmi detachable coils in awake patients: safety and feasibility. *J Neurosurg* 94 : 880-885, 2001
- Rordorf G, Bellon RJ, Budzik RE Jr, Farkas J, Reinking GF, Pergolizzi RS, et al. : Silent thromboembolic events associated with the treatment of unruptured cerebral aneurysms by use of Guglielmi detachable coils : prospective study applying diffusion-weighted imaging. *AJNR Am J Neuroradiol* 22 : 5-10, 2001
- Sakai H, Sakai N, Higashi T : Embolic complications of endovascular surgery for cerebrovascular diseases : evaluation with diffusion-weighted MR imaging. *Intervent Neuroradiol* 6 (Suppl) : 223-226, 2000
- Soeda A, Sakai N, Sakai H, Iihara K, Yamada N, Imakita S, et al. : Thromboembolic events associated with Guglielmi detachable coil embolization of asymptomatic cerebral aneurysms : evaluation of 66 consecutive cases with use of diffusion-weighted MR imaging. *AJNR Am J Neuroradiol* 24 : 127-132, 2003
- Song JK, Niimi Y, Fernandez PM, Brisman JL, Buciu R, Kuper-Smith MJ, et al. : Thrombus formation during intracranial aneurysm coil placement : treatment with intraarterial abciximab. *AJNR Am J Neuroradiol* 25 : 1147-1153, 2004
- Viñuela F, Duckwiler G, Mawad M : Guglielmi detachable coil embolization of acute intracranial aneurysm : perioperative anatomical and clinical outcome in 403 patients. *J Neurosurg* 86 : 475-482, 1997
- Workman MJ, Cloft HJ, Tong FC, Dion JE, Jensen ME, Marx WF, et al. : Thrombus formation at the neck of cerebral aneurysms during treatment with Guglielmi detachable coils. *AJNR Am J Neuroradiol* 23 : 1568-1576, 2002