

Clinical Article

Detachable Coil Embolization for Saccular Posterior Inferior Cerebellar Artery Aneurysms

Su-Gi Jeon, M.D.,¹ Do Hoon Kwon, M.D.,¹ Jae Sung Ahn, M.D.,¹ Byung Duk Kwun, M.D.,¹ Choong-Gon, Choi, M.D.,² Sung-Chul Jin, M.D.³

Departments of Neurological Surgery,¹ Radiology,² University of Ulsan College of Medicine, Asan Medical Center, Seoul, Korea

Department of Neurosurgery,³ Seoul National University Bundang Hospital, Seongnam, Korea

Objective : Surgical treatment of posterior inferior cerebellar artery (PICA) aneurysms is challenging due to limited surgical accessibility. Endovascular approach has a benefit of avoiding direct injury to the brainstem or lower cranial nerves. Therefore, it has recently been considered an alternative or primary modality for PICA aneurysms. We retrospectively assessed outcomes following detachable coil embolization of saccular PICA aneurysms.

Methods : From February 1997 to December 2007, we performed endovascular procedures to treat 15 patients with 15 PICA aneurysms. Fourteen patients with 14 PICA aneurysms morphology of which was saccular were reviewed retrospectively. Twelve patients had ruptured aneurysms. The aneurysms arose from the PICA origin site (n = 12), the PICA lateral medullary segment (n = 1), or the PICA tonsilomedullary segment (n = 1).

Results : Complete aneurysm occlusion was achieved in 10 patients, residual neck in 3, and residual sac in one. Radiological follow-up was performed in 7 patients with mean duration of 34.7 months (range, 1-97 months) and showed stable or complete occlusion in 6 patients. There were no rebleeding or retreatment after endovascular treatment. Thromboembolism was the only procedure-related complication (n = 4 ; 28.6%). Asymptomatic PICA infarction occurred in two patients and symptomatic PICA infarction in two elderly patients with poor clinical grade. Of these procedural PICA infarction cases, 1 symptomatic PICA infarction patient developed ventriculitis and septic shock leading to death. The clinical outcome was good in 10 patients (71.4%).

Conclusions : In the present study, detachable coil embolization has shown as an efficient modality for PICA saccular aneurysms challenging indications of microsurgery. However, thromboembolic complications should be considered, especially in poor clinical elderly patients with ruptured aneurysms.

KEY WORDS : Posterior inferior cerebellar artery · Endovascular · Microsurgery · Thromboembolism.

INTRODUCTION

Posterior inferior cerebellar artery (PICA) aneurysms are rare, accounting for 0.5-3.0% of all intracranial aneurysms^{8,16,25}. Most PICA aneurysms occur in the proximal segment or at the PICA origin^{6,8,9}. Direct surgical treatment is challenging because the intimate relationship between the proximal PICA, the brainstem and the lower cranial nerve makes access difficult^{5,18}. This limited surgical access, toge-

ther with the success rates associated with endovascular treatment for these aneurysms has resulted in endovascular treatment being considered an alternative and even primary treatment modality for PICA aneurysms. The present study describes our clinical experience treating saccular PICA aneurysm patients using detachable coil embolization.

MATERIALS AND METHODS

Between February 1997 and December 2007, 41 patients with PICA aneurysms underwent surgical or endovascular treatment in our institution. Of those 41 patients, 15 patients underwent endovascular treatment. Fourteen saccular PICA aneurysms in 14 patients included in our study. The study excluded patients with vertebral artery (VA) trunk aneurysms which were positioned at the PICA

• Received : June 12, 2009 • Revised : July 22, 2009
• Accepted : September 3, 2009
• Address for reprints : Do Hoon Kwon, M.D.
Department of Neurological Surgery, University of Ulsan College of Medicine, Asan Medical Center, 388-1 Pungnap-dong, Songpa-gu, Seoul 138-736, Korea
Tel : +82-2-3010-3555, Fax : +82-2-476-6738
E-mail : ykwon@amc.seoul.kr

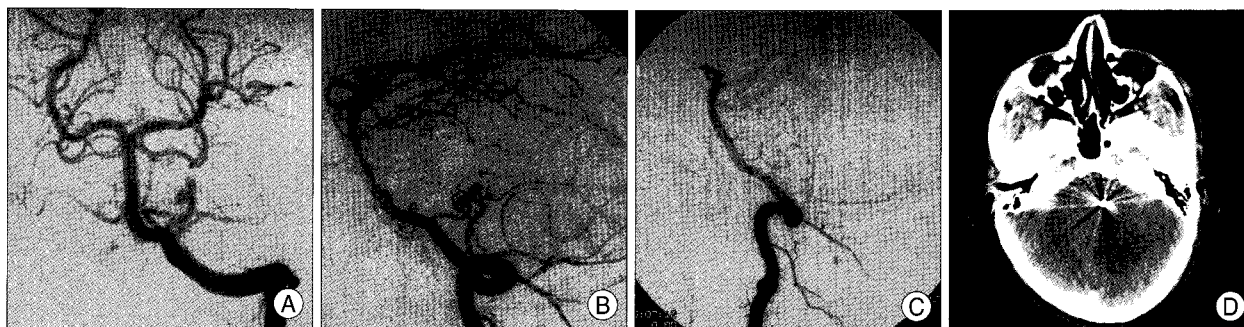


Fig. 1. Case 7. A 27 year-old male presented with ruptured posterior inferior cerebellar artery (PICA) aneurysm in the lateral medullary segment. A and B : Anteroposterior and working projection view of left vertebral artery reveals the bilobulated saccular aneurysm in the left lateral medullary segment of PICA. C : Working projection view of left vertebral artery after Guglielmi detachable coil embolization shows main PICA trunk occlusion with no contrast filling of aneurysm sac. D : Brain computed tomography reveals low density in left cerebellum correlating with PICA territory four day after coil embolization. However, the patient had no neurological deficit but mild headache after detachable coil embolization.

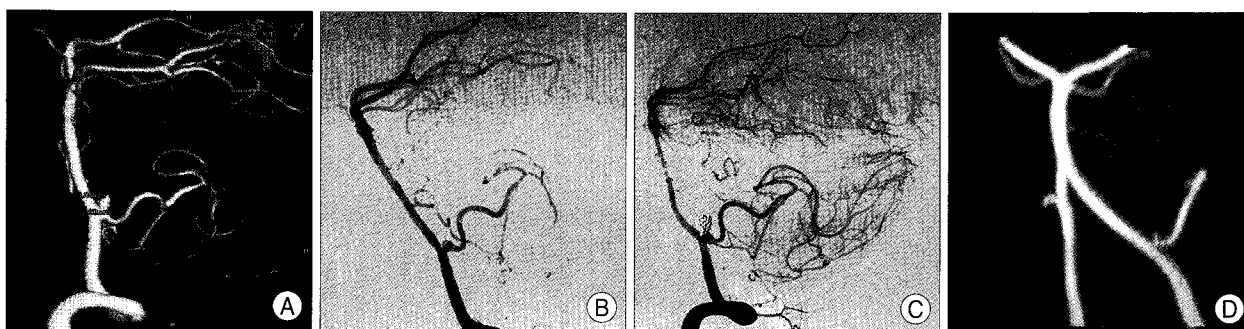


Fig. 2. Case 1. A 28 year-old female presented with subarachnoid hemorrhage. A : 3D reconstruction working projection view on the left vertebral artery revealed a saccular aneurysm at the vertebral artery- posterior inferior cerebellar artery junction. B : Working projection view on the left vertebral artery immediately after coil embolization demonstrates complete occlusion of the aneurysm. C : Lateral angiogram on left vertebral artery 9 days after coil embolization shows minimal coil compaction and contrast filling of the aneurysm neck. D : Compared with previous follow-up angiography, magnetic resonance DSA 9 month after coil embolization reveals no further progression of coil compaction.

level and dissecting cortical PICA aneurysms. Medical records, radiological images and readings, and procedural reports were retrospectively reviewed. Initial clinical status was assessed using the Hunt and Hess scale, and clinical outcomes were assessed using the Glasgow Outcome Scale (GOS). Twelve of the 14 aneurysms were detected based on subarachnoid hemorrhage and one, which was ruptured and treated by wrapping 10 years prior, was detected during follow-up due to a morphological change in the aneurysm. The other aneurysm was found incidentally on a magnetic resonance image. Aneurysms were classified according to the PICA definition by Lister et al.¹⁵⁾ as being anterior medullary segment, lateral medullary segment, tonsillomedullary segment, televelotonsillar segment, and cortical segment aneurysms. Radiologic outcomes for each aneurysm were graded as : class 1, complete obliteration; class 2, residual neck; or class 3, residual aneurysm^{23,24)}. Neurosurgeons (B.D. and J.A.) and neurointerventionists (D.K. and C.C.) discussed about the treatment modality for each patient with PICA aneurysms. The indications for PICA aneurysm embolization included the followings : 1) elderly patients (n = 3), 2) poor clinical grade (n = 3), 3) relative difficulty for

microsurgery (n = 2), and 4) easy access to the aneurysm for embolization [dome to neck ration > 1 (n = 6)].

RESULTS

Fourteen patients (2 men and 12 women) had a mean age of 53.5 years (range, 27-80 years). The location of the PICA aneurysm was the VA-PICA junction in 12 patients, the lateral medullary segment in 1 (Fig. 1), and the tonsillo-medullary segment in 1 patient. Immediate post-procedural angiograms showed complete occlusion in 10 (71.4%) cases, residual neck in 3, and residual sac in 1. No aneurysms were treated with additional procedures due to coil compaction or regrowth. Glasgow Outcome Scale (GOS) assessment showed GOS 5 in 10 patients (71.4%), GOS 3 in two, GOS 2 in one, and GOS 1 in one. A patient with irreversible clinical vasospasm resulted in GOS 2. One patient with GOS 3 were attributable to had symptomatic PICA infarctions. The other patient with GOS 3 resulted from thromboembolism leading to persistent hemiparesis and did not improve the clinical status. One patient with symptomatic PICA infarction died from septic shock caused

Table 1. Characteristics of fourteen patients with posterior inferior cerebellar artery

Patient No.	Sex/Age	H-H grade	Location	Maximal diameter (mm)	Neck diameter (mm)	Parent artery incorporation	Radiological outcome	Aneurysm progression	GOS
1	F/28	4	VA-PICA	3.8	2.5	No	Complete	Yes [†]	5
2	F/46	4	VA-PICA	4.0	2.4	No	Complete	No	5
3	F/68	3	VA-PICA	2.9	2.0	No	Complete	N/A [*]	2
4	F/45	2	VA-PICA	3.6	2.5	No	Residual neck	N/A [†]	5
5	M/75	4	VA-PICA	2.6	2.4	No	Residual neck	N/A [*]	3
6	F/57	Unruptured	VA-PICA	4.6	3.9	No	Complete	No	5
7	M/27	2	Lat. medullary	4.0	2.3	-	Complete	No	5
8	F/53	unruptured	Tonsilomedullary	4.0	2.5	-	Complete	N/A [†]	5
9	F/62	4	VA-PICA	3.1	2.9	No	Complete	N/A [†]	3
10	F/36	3	VA-PICA	4.5	3.0	Yes	Complete	No	5
11	F/77	4	VA-PICA	7.9	4.9	Yes	Residual sac	-	1
12	F/80	3	VA-PICA	7.0	4.0	Yes	Complete	N/A [§]	5
13	F/57	3	VA-PICA	4.2	1.3	Yes	Complete	No	5
14	F/39	2	VA-PICA	5.0	2.5	Yes	Residual neck	No	5

*Follow-up was not checked due to poor neurological status after embolization, [†]Radiologic follow-up was not assessed because of transfer to other hospitals, [‡]No further progression of coil compaction was demonstrated on follow-up images, [§]Radiologic follow-up was not performed due to no beneficial gain. GOS: Glasgow Outcome Scale, N/A: not available, VA-PICA: vertebral artery-posterior inferior cerebral artery

by ventriculitis, which might have been caused by multiple external ventricular procedures. Follow-up imaging was available for 7 of 14 patients, and the mean follow-up period was 34.7 months (range 1-97 months). These images showed that stable or complete occlusion was achieved in six aneurysms. One aneurysm showed a recurrence of aneurysm neck at 2 months after the procedure, but then showed no further progression at 9 or 14 months (Fig. 2). Two patients showing complete radiologic occlusion and one patient showing residual neck were transferred to other institutions closer to their homes. Two elderly patients were not willing to undergo any further intervention and imaging follow-up due to poor clinical outcomes. One elderly patient showing complete occlusion was not offered follow-up imaging because the patient and her family considered it clinically inappropriate to offer any further intervention. However, she maintained out-patient clinical follow-up for 22 months after treatment. Procedure-related complications occurred in 4 of 14 (28.6%) patients; all 4 patients experienced thromboembolism. Asymptomatic PICA infarction occurred in two patients. Symptomatic PICA infarction led to persistent hemiparesis in one patient who underwent decompressive craniectomy resulting in ventriculitis and death in 1 patient. Clinical follow-up was possible in 8 patients for a mean period of 35.8 months (range, 6-97 months). These patients showed no clinical changes during this follow-up period.

DISCUSSION

The majority of PICA aneurysms arise at the VA-PICA

junction. Distal PICA aneurysms are rare and account for 0.28-1.4%^{5,8,13,19)} of all intracranial aneurysms. The PICA has the most complex and variable course of the major cerebral arteries¹⁵⁾. After it originates near the inferior olive, the vessel course may be divided into five segments based on its relationship to near anatomical structures^{7,17)}. Some perforating arteries supplying the brainstem originate from the two proximal medullary segments, and there is a close relationship between the PICA proximal segment and the lower cranial nerves. There is considerable variation in the PICA origin from the VA^{2,4,15)}. The infrequency of PICA aneurysms, complexity of PICA anatomy, and relatively difficult surgical access make treatment of PICA aneurysms a challenge¹⁰⁾. Thorough analysis of the relevant anatomical details for each patient with a PICA aneurysm is crucial for successful treatment by surgical or endovascular approaches.

The majority of PICA aneurysms at the VA-PICA junction have a typical saccular appearance. However, distal PICA aneurysms occasionally have no associated branching artery adjacent to the aneurysm neck,^{8,13,15,20,26)} and have diverse dissecting, fusiform, and saccular morphologies. We previously reported dissecting or fusiform morphologies in six of seven patients who had distal PICA aneurysms²⁷⁾. Patients with fusiform or dissecting PICA aneurysms were excluded from the present study as its focus was the efficacy of detachable coil embolization in the treatment of saccular PICA aneurysms.

The diameter of ruptured PICA saccular aneurysms does not reflect on treatment timing for similar diameter of unruptured aneurysms. Therefore, the decision to treat an unruptured PICA aneurysm should not be based on the

diameter itself. However, the rare incidence of saccular PICA aneurysms meditates that there is limited knowledge of the natural history of unruptured PICA aneurysms. Treatment of unruptured PICA aneurysms will be unavoidably dependent on the experience of ruptured PICA aneurysms. In the present series, 10 of 12 ruptured PICA saccular aneurysms had maximal diameter < 5 mm. This result reminds us of the need to treat small (< 10 mm) unruptured PICA aneurysms. Furthermore, the present findings indicate that treatment should be considered for unruptured PICA aneurysms as small as 3 mm in diameter. Procedure risks and treatment benefits should be carefully considered even in such patients with diameter of aneurysms about 3 mm.

Endovascular treatment has been generally regarded as the primary modality for posterior circulation aneurysms, including PICA aneurysms. Microsurgery is difficult due to the limited surgical access. One result showed that, although postoperative lower cranial nerve palsies occurred in about half of patients most resolved gradually during follow-up¹⁾. PICA aneurysm patients treated using microsurgery generally show good outcomes^{1,3,6,10-12,14,21)}. Treatment modality should be considered on a case-by-case basis, without bias.

While PICA originated from the aneurysm sac not from neck, coil occlusion including the PICA origin should be considered because the outcome is usually good²²⁾. In the present study, four of five aneurysms into which the PICA was incorporated showed good clinical outcomes, with three showing complete occlusion. These outcomes might reflect that PICA incorporation was juxta-neck of the aneurysms rather than an aneurysm sac itself, and this might probably result in more conformability of the coil mesh into the aneurysm sac.

Peluso et al.²²⁾ reported a markedly high rate of procedural rupture (21%, 9 of 43 cases) for PICA aneurysms treated with coil embolization. This might be explained by the small aneurysm size and the geometric relationship between the aneurysm and the VA; most PICA aneurysms project upwards and the redundant segment of the microcatheter caused by a V3 loop in the VA can easily cause an upward catheter jump during pushing, resulting in rupture of the aneurysm dome. Thus, meticulous tension control of the microcatheter is required during navigation of PICA aneurysms.

In the present series, there were no cases of rupture or rebleeding of the aneurysms during the procedure or follow-up period. However, only approximately half of the patients were available for follow-up evaluation. Although these findings do not necessarily indicate the long-term durability of embolization for PICA aneurysms, they indicate that embolization has a role in immediate prevention

of rupture or rebleeding.

Procedure-related PICA infarction occurred in four patients with ruptured PICA aneurysms. These procedural complications may have been resulted with insufficient heparinization due to fear of rebleeding. Of these four PICA infarctions, symptomatic PICA infarction influencing clinical outcome developed in two patients, one of whom developed ventriculitis and died. The other patient had a neurological deficit of hemiparesis. Despite no statistical analysis, symptomatic PICA infarction might be associated with advanced age, ruptured aneurysms, poor clinical grade, aneurysms at the VA-PICA junction, and patent PICA during the procedure in our study. Coil embolization in patients with these characteristics requires careful attention to the risk of thromboembolic complication during and after the procedure.

CONCLUSION

The present study indicates that endovascular treatment might be effective in preventing early rebleeding in PICA aneurysm challenging for microsurgery. Symptomatic thromboembolism of our series developed particularly in elderly patients with poor clinical condition in ruptured PICA aneurysms at the VA-PICA junction mainly due to insufficient heparinization. Unruptured PICA saccular aneurysms with smaller than 10 mm might be probably considered for treatment based on our experiences of ruptured aneurysms.

References

1. Al-khayat H, Al-Khayat H, Beshay J, Manner D, White J : Vertebral artery-posteroinferior cerebellar artery aneurysms: clinical and lower cranial nerve outcomes in 52 patients. *Neurosurgery* 56 : 2-10; discussion 11, 2005
2. Ban M, Ueta H, Nakagawa Y, Matsumoto K : A case of basilar artery occlusion associated with unilateral low origin of the posterior inferior cerebellar artery. *Surg Neurol* 26 : 501-504, 1986
3. D'Ambrosio AL, Kreiter KT, Bush CA, Sciacca RR, Mayer SA, Solomon RA, et al. : Far lateral suboccipital approach for the treatment of proximal posteroinferior cerebellar artery aneurysms : surgical results and long-term outcome. *Neurosurgery* 55 : 39-50; discussion 50-54, 2004
4. Fine AD, Cardoso A, Rhoton AL Jr : Microsurgical anatomy of the extracranial-extradural origin of the posterior inferior cerebellar artery. *J Neurosurg* 91 : 645-652, 1999
5. Horiuchi T, Tanaka Y, Hongo K, Nitta J, Kusano Y, Kobayashi S : Characteristics of distal posteroinferior cerebellar artery aneurysms. *Neurosurgery* 53 : 589-595; discussion 595-596, 2003
6. Horowitz M, Kopitnik T, Landreneau F, Krummerman J, Batjer HH, Thomas G, et al. : Posteroinferior cerebellar artery aneurysms : surgical results for 38 patients. *Neurosurgery* 43 : 1026-1032, 1998
7. Huang YP, Wolf BS : Angiographic features of fourth ventricle tumors with special reference to the posterior inferior cerebellar artery. *Am J Roentgenol Radium Ther Nucl Med* 107 : 543-564, 1969
8. Hudgins RJ, Day AL, Quisling RG, Rhoton AL Jr, Spert GW,

- Garcia-Bengochea F : Aneurysms of the posterior inferior cerebellar artery. A clinical and anatomical analysis. *J Neurosurg* 58 : 381-387, 1983
9. Ishikawa T, Suzuki A, Yasui N : Distal posterior inferior cerebellar aneurysms-report of 12 cases. *Neurol Med Chir (Tokyo)* 30 : 100-108, 1990
 10. Kleinpeter G : Why are aneurysms of the posterior inferior cerebellar artery so unique? Clinical experience and review of the literature. *Minim Invasive Neurosurg* 47 : 93-101, 2004
 11. Krayenbuhl N, Guerrero C, Krisht AF : Technical strategies to approach aneurysms of the vertebral and posterior inferior cerebellar arteries. *Neurosurg Focus* 19 : E4, 2005
 12. Lemole GM Jr, Henn J, Javedan S, Deshmukh V, Spetzler RF : Cerebral revascularization performed using posterior inferior cerebellar artery-posterior inferior cerebellar artery bypass. Report of four cases and literature review. *J Neurosurg* 97 : 219-223, 2002
 13. Lewis SB, Chang DJ, Peace DA, Lafrentz PJ, Day AL : Distal posterior inferior cerebellar artery aneurysms : clinical features and management. *J Neurosurg* 97 : 756-766, 2002
 14. Liew D, Ng PY, Ng I : Surgical management of ruptured and unruptured symptomatic posterior inferior cerebellar artery aneurysms. *Br J Neurosurg* 18 : 608-612, 2004
 15. Lister JR, Rhoton AL Jr, Matsushima T, Peace DA : Microsurgical anatomy of the posterior inferior cerebellar artery. *Neurosurgery* 10 : 170-199, 1982
 16. Locksley HB : Natural history of subarachnoid hemorrhage, intracranial aneurysms and arteriovenous malformations. Based on 6368 cases in the cooperative study. *J Neurosurg* 25 : 219-239, 1966
 17. Margolis MT, Newton TH : Borderlands of the normal and abnormal posterior inferior cerebellar artery. *Acta Radiol Diagn (Stockh)* 13 : 163-176, 1972
 18. Matsushima T, Matsukado K, Natori Y, Inamura T, Hitotsumatsu T, Fukui M : Surgery on a saccular vertebral artery-posterior inferior cerebellar artery aneurysm via the transcondylar fossa (supracondylar transjugular tubercle) approach or the transcondylar approach : surgical results and indications for using two different lateral skull base approaches. *J Neurosurg* 95 : 268-274, 2001
 19. Meisel HJ, Mansmann U, Alvarez H, Rodesch G, Brock M, Lasjaunias P : Cerebral arteriovenous malformations and associated aneurysms : analysis of 305 cases from a series of 662 patients. *Neurosurgery* 46 : 793-800; discussion 800-802, 2000
 20. Nishizaki T, Tamaki N, Nishida Y, Fujita K, Matsumoto S : Aneurysms of the distal posterior inferior cerebellar artery : experience with three cases and review of the literature. *Neurosurgery* 16 : 829-832, 1985
 21. Ogilvy CS, Quinones-Hinojosa A : Surgical treatment of vertebral and posterior inferior cerebellar artery aneurysms. *Neurosurg Clin N Am* 9 : 851-860, 1998
 22. Peluso JP, van Rooij WJ, Sluzewski M, Beute GN, Majoie CB : Posterior inferior cerebellar artery aneurysms : incidence, clinical presentation, and outcome of endovascular treatment. *AJNR Am J Neuroradiol* 29 : 86-90, 2008
 23. Raymond J, Guilbert F, Weill A, Georganos SA, Juravsky L, Lambert A, et al. : Long-term angiographic recurrences after selective endovascular treatment of aneurysms with detachable coils. *Stroke* 34 : 1398-1403, 2003
 24. Raymond J, Roy D : Safety and efficacy of endovascular treatment of acutely ruptured aneurysms. *Neurosurgery* 41 : 1235-1245; discussion 1245-1246, 1997
 25. Salcman M, Rigamonti D, Numaguchi Y, Sadato N : Aneurysms of the posterior inferior cerebellar artery-vertebral artery complex : variations on a theme. *Neurosurgery* 27 : 12-20; discussion 20-21, 1990
 26. Todaka T, Hamada J, Yano S, Kai Y, Morioka M, Ushio Y : Successful clipping of a distal posterior inferior cerebellar artery aneurysm located on the anterior surface of the medulla oblongata-case report. *Neurol Med Chir (Tokyo)* 42 : 158-161, 2002
 27. Yeo SK, Kwon DH, Ahn JS, Jin SC, Kim HJ, Kwun BD : Management of posterior inferior cerebellar artery aneurysms : a single institution retrospective analysis (1989 - 2007). *Korean J Cerebrovasc Surg* 10 : 358-363, 2008