

Trichuris trichiura Infection Diagnosed by Colonoscopy: Case Reports and Review of Literature

Kyung-Sun Ok¹, You-Sun Kim^{1,*}, Jung-Hoon Song¹, Jin-Ho Lee¹, Soo-Hyung Ryu¹, Jung-Hwan Lee¹, Jeong-Seop Moon¹, Dong-Hee Whang² and Hye-Kyung Lee³

Departments of ¹Internal Medicine, ²Laboratory Medicine, and ³Pathology, Seoul Paik Hospital, Inje University College of Medicine, Seoul 100-032, Korea

Abstract: *Trichuris trichiura*, commonly referred to as a whipworm, has a worldwide distribution, particularly among countries with warm, humid climates. In Korea, trichuriasis was a highly prevalent soil-transmitted helminthiasis until the 1970s. However, the nationwide prevalence decreased to 0.02% in 2004 as a result of national control activities and improvement in the socioeconomic status of Koreans. Most infected individuals have no distinct symptoms, if lightly infected. The diagnosis is typically confirmed by detection of *T. trichiura* eggs on examination of a stool sample; few reports have described detection of the parasite during colonoscopy. Recently, we managed 4 patients with trichuriasis who were diagnosed by detection of the parasite on colonoscopy, and we reviewed the literature on the colonoscopic diagnosis of *T. trichiura* in Korea. We suggest that colonoscopy might be a useful diagnostic tool, especially when infected by only a few male worms with no eggs in the stool.

Key words: *Trichuris trichiura*, trichuriasis, colonoscopy, literature review

INTRODUCTION

Trichuris trichiura infection is endemic in tropical and subtropical countries, but few sporadic cases have occurred in non-endemic areas, mainly as a result of immigration. In the Republic of Korea (= South Korea), *T. trichiura* was one of the highly prevalent soil-transmitted helminths (STH) until the 1970s. In the 1960s, the Korean government began parasite control activities which targeted schoolchildren through a nationwide examination and mass chemotherapy between 1969 and 1995. The prevalence of *T. trichiura* infection nationwide was 65.4% in 1971, but decreased to 0.02% in 2004 as a result of the national control activities, improvement in the socioeconomic status, and significant supplies of agricultural chemicals [1]. South Korea is one of the Asian countries which have successfully controlled STH. The decreasing pattern of national *T. trichiura* infection was monitored until 2004; however, a more recent report has not been published. Most *T. trichiura* infections lack symptoms; only patients with heavy infections are symptomatic. The diagnosis is made by identifying *T. trichiura* eggs in stool specimens. However, the diagnosis of parasite infections by stool examination may be difficult in cases of infection only with a few male

parasites. Several reports have described the detection of *T. trichiura* during colonoscopy, both domestically and internationally [2-15]. Recently, we managed 4 patients with trichuriasis diagnosed incidentally by detection of adult worms on colonoscopy and reviewed the previously reported 9 such cases of trichuriasis in Korea [2,3].

CASE REPORTS

Case 1

A 56-year-old man was admitted for post-polypectomy surveillance. Three years previously, he was shown to have a polyp 1 cm in size during a screening colonoscopy. A polypectomy was performed and the microscopic examination revealed a tubular adenoma with high grade atypia. He did relatively well without abdominal pain, diarrhea, tenesmus, or hematochezia. His physical examination was unremarkable. The laboratory values were as follows: Hb, 13.7 g/dl; WBC, 5,940/mm³ without eosinophilia (absolute eosinophils, 297/mm³); and a normal platelet count. Electrolytes, and liver and renal biochemical tests were normal. The stool examination for parasites or eggs was negative.

Colonoscopy revealed no abnormalities except for a small, white, worm-like object attached to the cecum. One end was embedded in the hyperemic edematous mucosa and the other

* Received 2 March 2009, revised 22 April 2009, accepted 16 May 2009.

* Corresponding author (yousunk69@korea.com)

end was coiled and movable within the lumen (Fig. 1A). Histologic examination of the cecal mucosa revealed a moderately dense eosinophilic infiltration in the lamina propria (Fig. 1B). Microscopic sectional evaluation of the retrieved parasite was consistent with *T. trichiura* (a male worm including a testis). He was treated with albendazole.

Case 2

A 46-year-old man was admitted for lower abdominal discomfort and tenesmus. The physical examination was unremarkable except for mild hyperemic spots in the perianal area. Laboratory values were as follows: Hb, 14.1 g/dl; WBC, 4,960/mm³ without eosinophilia (absolute eosinophils, 84/mm³), and normal platelet count. Electrolytes, and liver and renal biochemical tests were normal. The stool examination for parasites or eggs was negative.

He was found to have a small, white worm on the proximal ascending colon during colonoscopy. One end of the parasite was embedded in relatively normal colonic mucosa and the other end was coiled and movable (Fig. 2). The parasite was removed by forceps. Microscopic examination of the retrieved parasite was consistent with *T. trichiura*, which was thought to be a male worm. It had a thread-like head portion and a coiled thicker portion. He was treated with albendazole.

Case 3

A 55-year-old man was admitted for epigastric discomfort and intermittent diarrhea for 1 month. He had an unremarkable

medical history. The physical examination on admission was normal. The laboratory values were as follows: Hb, 13.9 g/dl; WBC, 5,600/mm³ with mild eosinophilia (absolute eosinophils, 480/mm³), and normal platelet count. Other biochemical tests were normal, except amylase (286 U/L; normal value < 220 U/L). The stool examination showed football-shaped eggs with bipolar prominences which demonstrated *T. trichiura* eggs by microscopy.

He was found to have a small, white worm within the ileocecal valve with relatively normal colonic mucosa during colonoscopy. The free end of the parasite within the lumen was not coiled (Fig. 3). The microscopic evaluation of the retrieved parasite was consistent with *T. trichiura*, and thought to be a female worm with a non-coiled thicker posterior portion. The patient was treated with albendazole and was symptom-free. Repeated stool examinations revealed no parasites or eggs.

Case 4

A 49-year-old man underwent a routine outpatient colonoscopy. His medical history was unremarkable and the laboratory findings were normal. Colonoscopy showed a long, slender, white worm in the cecum against the ileocecal valve. One end of the parasite was embedded in relatively normal mucosa (Fig. 4A). The parasite was carefully retrieved by forceps. Microscopically, the parasite was consistent with a *T. trichiura* female adult worm with a prominent uterus (Fig. 4B). Numerous barrel-shaped eggs with mucoïd plugs at both ends were detected in the uterus (Fig. 4C). A microscopic evaluation revealed a

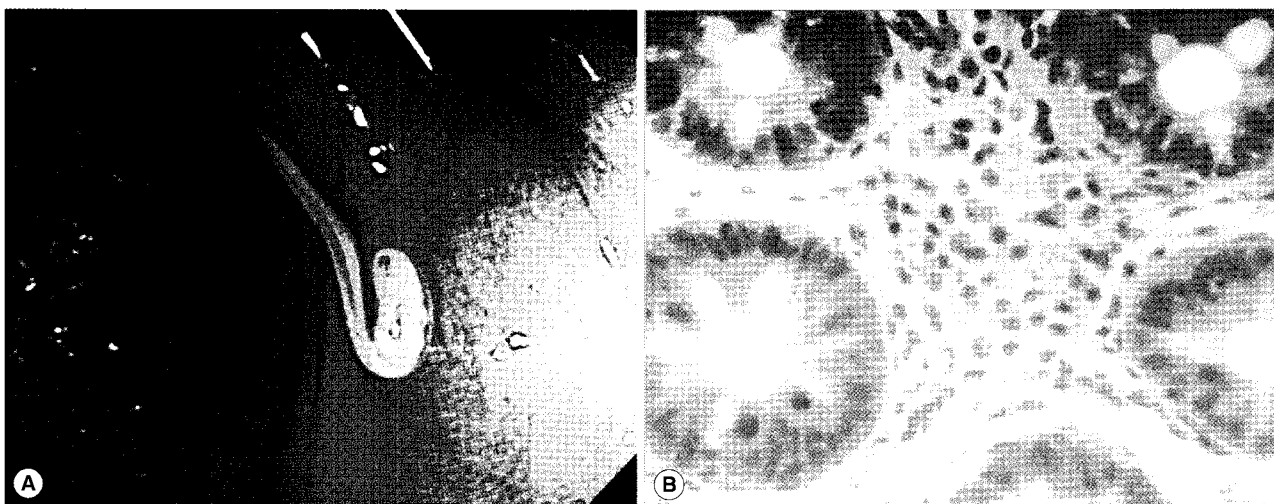


Fig. 1. (A) Colonoscopic finding of case 1 showing a whitish worm, *Trichuris trichiura*, with coiled posterior end embedded in the wall of the cecum. (B) Histologic finding of the cecal mucosa of case 1 which reveals eosinophilic infiltration in the lamina propria (H-E stain, original magnification, $\times 400$).

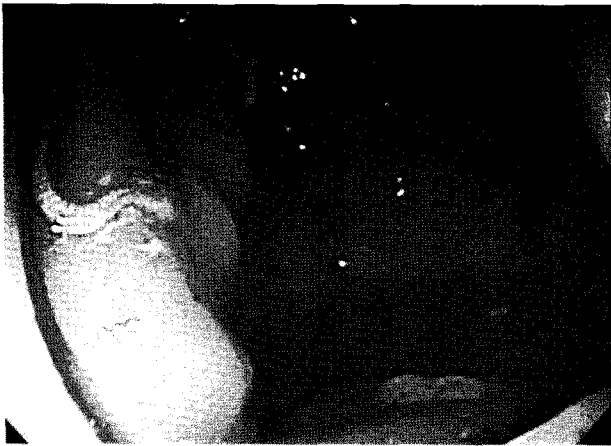

Fig. 2. Colonoscopic finding of case 2 showing a whitish worm, *T. trichiura*, with coiled posterior end embedded in the wall of the proximal ascending colon.

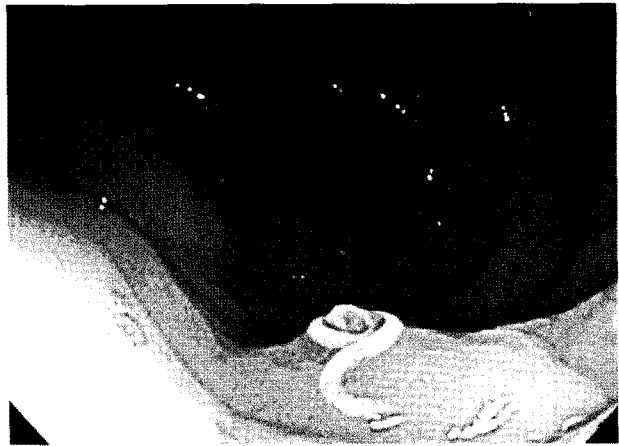
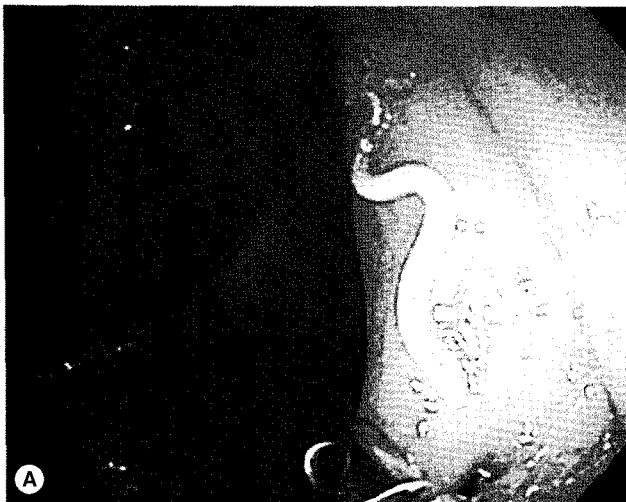


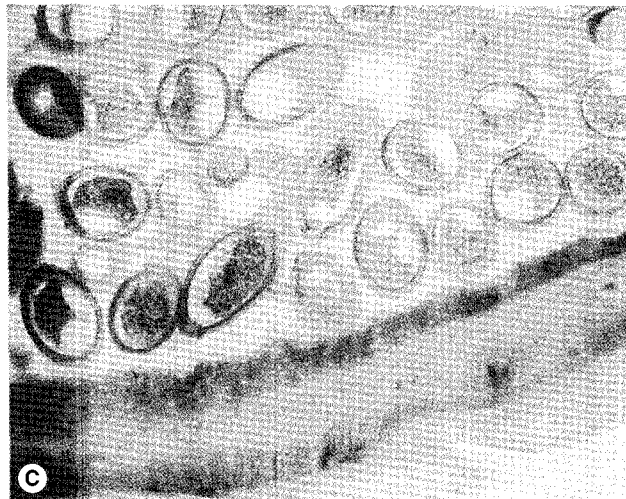
Fig. 3. Colonoscopic finding of case 3 showing a movable whitish worm, *T. trichiura*, in the ileocecal valve.



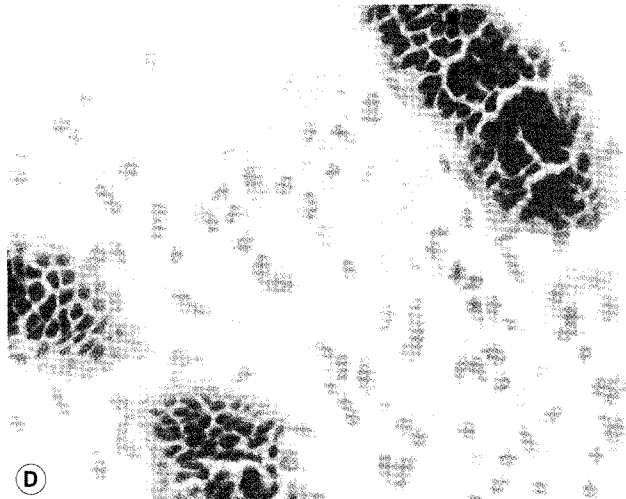
A



B



C



D

Fig. 4. (A) Colonoscopic finding of case 4 showing a long slender whitish *T. trichiura* worm in the cecum. (B) A female adult *T. trichiura* recovered from case 4, showing the intestine and uterine tubules (H-E stain, original magnification, $\times 40$). (C) Barrel-shaped eggs of *T. trichiura* from case 4 and the body wall consisting of the cuticle, epicuticle, and muscle layer (H-E stain, original magnification, $\times 400$). (D) Moderate eosinophilic infiltration in lamina propria of case 4 (H-E stain, original magnification, $\times 400$).

moderate eosinophilic infiltration in the lamina propria of the adjacent colonic mucosa (Fig. 4D). On the stool examination subsequently performed, *T. trichiura* eggs were detected. He was treated with albendazole for 3 days.

DISCUSSION

Trichuriasis is an intestinal infection of human beings caused by ingesting embryonated eggs from the environment. Colonized eggs hatch and enter the crypts of the small intestine as larvae. After 1-3 months of maturation, the parasite migrates to the cecum. In the cecum, the parasite matures, mates, and lays eggs. Adult worms are 3-4 cm in length and have thin, tapered anterior regions, and are thus commonly referred to as whipworms [16,17]. The adult *T. trichiura* invade the mucosa and produce minor inflammatory changes at localized sites. In endemic areas,

most people are colonized by small numbers of worms and have no symptoms. Some people harbor hundreds or even thousands of worms, and they present with anemia, diarrhea, abdominal pain, weight loss, malnutrition, appendicitis, colonic obstruction, perforation, or intestinal bleeding [16]. *Trichuris* dysentery syndrome (TDS) is a combination of symptoms, such as mucoid diarrhea and occasional bleeding. Rectal prolapse can occur in children with extremely high numbers of *T. trichiura* worms. Treatment recommendations are as follows: albendazole (400 mg once daily for 3 days) or mebendazole (100 mg twice daily for 3 days) [18].

To our knowledge, 12 cases of colonoscopic diagnosis of *T. trichiura* have been reported in the literature of other countries, which included 4 cases in USA [4-7], 3 cases in Japan [8-10], 2 cases in Italy [11,12], 2 cases in Taiwan [13,14], and 1 case in Canada [15]. In developed countries, detection of *T. trichiura*

Table 1. *Trichuris trichiura* diagnosis at colonoscopic examination in Korea

Reported cases	Sex	Age year	Symptoms	Stool exam	WBC/mm ³ (eosinophil%)	Colonoscopic finding	Microscopic finding	Treatment
1 Joo et al. (1998)	M	31	Abdominal pain & diarrhea	N	9,600 (4%)	Cecum/Erosion	NA	Mebendazole 200 mg 3 days, Colonoscopic extraction
2 Joo et al. (1998)	M	48	Abdominal pain	OB (+)	11,600 (2.4%)	Cecum/Hyperemia Ulcer	NA	Mebendazole 200 mg 3 days, Colonoscopic extraction
3 Joo et al. (1998)	F	34	Abdominal pain & diarrhea	OB (+)	8,900 (2%)	S-colon/Hyperemia, multiple erosions	NA	Mebendazole 200 mg 3 days, Colonoscopic extraction
4 Joo et al. (1998)	M	70	Abdominal pain & diarrhea	N	N	S-colon/Hyperemia, multiple erosions	NA	Mebendazole 200 mg 3 days, Colonoscopic extraction
5 Joo et al. (1998)	M	55	Abdominal pain	N	N	Cecum/Normal mucosa	NA	Mebendazole 200 mg 3 days, Colonoscopic extraction
6 Kim et al. (2003)	M	45	Decreased stool caliber	NA	N	Cecum/Normal mucosa	NA	Colonoscopic extraction only
7 Kim et al. (2003)	M	52	Lower abdomen discomfort	NA	12,500 (N)	Cecum/Normal mucosa	NA	Colonoscopic extraction only
8 Kim et al. (2003)	M	48	None	NA	8,700 (N)	Cecum/Hyperemia	NA	Colonoscopic extraction only
9 Kim et al. (2003)	M	56	None	NA	5,900 (N)	Cecum/Normal mucosa	NA	Colonoscopic extraction only
10 This report	M	56	None	N	5,940 (5.1%)	Cecum/Hyperemic edematous mucosa	Eosinophilic infiltration, male worm	Albendazole 400 mg 3 days, Colonoscopic extraction
11 This report	M	46	Lower abdomen discomfort tenesmus	NA	5,750 (1.7%)	A-colon/Normal mucosa	Male worm	Albendazole 400 mg 3 days, Colonoscopic extraction
12 This report	M	55	Diarrhea	Egg (+)	5,600 (8.0%)	IC valve/Normal mucosa	Female worm	Albendazole 400 mg 3 days, Colonoscopic extraction
13 This report	M	49	None	Egg (+)	6,590 (NA)	Cecum/Normal mucosa	Eosinophilic infiltration, female worm	Albendazole 400 mg 3 days, Colonoscopic extraction

N, normal; NA, not available; OB, occult blood; S-colon, sigmoid colon; A-colon, ascending colon.

during colonoscopic examination is unusual. They were developed sporadically in western countries and mostly immigrants from endemic areas. Colonoscopy was performed for evaluation of their non-specific gastrointestinal symptoms, such as abdominal pain, diarrhea, and anemia. Moreover, stool examination was all negative for both eggs and parasites in these cases. In Korea, 9 cases of *T. trichiura* infection diagnosed by colonoscopy have been reported; 5 cases were reported in 1998 by Joo et al. [2] and 4 cases were reported in 2003 by Kim et al. [3] (Table 1). Seven patients had non-specific symptoms, such as abdominal pain and diarrhea, and 2 were asymptomatic. The laboratory findings were normal without definite eosinophilia. Stool examinations showed occult blood in 2 patients and revealed no other pathogens in all patients. On colonoscopy, parasites were incidentally found in 7 patients in the cecum and 2 in the sigmoid colon.

We have managed 4 patients with *T. trichiura* during the past year. Two patients were asymptomatic and the others had non-specific symptoms, such as abdominal discomfort, diarrhea, and tenesmus. Colonoscopy revealed no abnormalities except for a small, white, mobile whip-like worm attached to the cecum in all patients. With careful inspection, we found that the thin head portion of the worm was embedded in the mucosa, while the thicker portion was visible within the lumen. In 2 cases, histologic examination of the adjacent mucosa revealed eosinophilic colitis. It was possible to differentiate the sex of the parasites in the cases described herein by microscopic examination of sections of the worms. The 2 patients infected by male worms presented negative findings on the stool examination and the other 2 infected by female worms were accompanied by characteristic barrel-shaped eggs on the stool examination. Even though our number of cases was small, the sexual differences in *T. trichiura* make the stool examination the most useful tool for diagnosing such infections. The microscopic evaluation was performed on the adjacent mucosa, and showed that localized eosinophilic infiltrations with no definite eosinophilia may be helpful for diagnosis.

In all 13 patients reported in Korea, they were relatively healthy city dwellers and the detection of parasites was unexpected and the diagnosis was made incidentally. Endoscopic parasite extraction and medical treatment was performed. In recent years, direct inspection of whipworms at colonoscopy is increasing, presumably because of an increase in both the prevalence of STH and the use of colonoscopy. We can also presume that the intake of organic vegetables, the end of national control activities, and

the immigration from endemic areas increase the prevalence of STH. Korean people have similar interests in health and well-being as people in other developed countries. People worry about pesticides in food which can be linked to many diseases and there is a growing tendency to prefer organic foods, despite the high cost. We think that the use of organic fertilizers or the discontinued use of pesticides can increase the prevalence of STH.

In Korea, colon cancer is the major cause of cancer-related deaths. To prevent and detect of colon cancers, it is important to do screening by colonoscopies. With the concern about colon cancer and the feasibility of colonoscopy, the use of colonoscopy as a primary screening tool for colorectal cancer is increasing in Korea. In addition, physicians tend to choose colonoscopy easily as a diagnostic tool for evaluation of non-specific gastrointestinal symptoms, thus skipping the stool examination. Ironically, the more we try to diagnose significant diseases, the more we often overlook insignificant diseases, such as parasitic infections. We have to keep in mind that the stool examination is the method of choice for parasitic diagnoses, such as STH and intestinal schistosomiasis. However, we also suggest that colonoscopy might be a useful diagnostic tool, especially when infected with only a few male worms with no eggs in the stool examination. In conclusion, STH, such as trichuriasis, may show an increasing tendency in Korea and should be monitored by national surveys. As colonoscopy becomes widespread, it would become remarkably important in the diagnosis and treatment of colorectal disease, but also in epidemiologic studies of parasite infections.

REFERENCES

1. Hong ST, Chai JY, Choi MH, Huh S, Rim HJ, Lee SH. A successful experience of soil-transmitted helminth control in the Republic of Korea. *Korean J Parasitol* 2006; 44: 177-185.
2. Joo JH, Ryu KH, Lee YH, Park CW, Cho JY, Kim YS, Lee JS, Lee MS, Hwang SG, Shim CS. Colonoscopic diagnosis of whipworm infection. *Hepatogastroenterology* 1998; 45: 2105-2109.
3. Kim JS, Park JS, Kim YW, Suk JH, Choi J, Kwak CH, Park SK, Park HU, Kim HS. Four cases of *Trichuris trichiura* infection in the colon. *Korean J Gastroint Endosc* 2003; 27: 158-161.
4. Davis M, Matteson R, Williams WC. Radiographic and endoscopic findings in human whipworm infection (*Trichuris trichiura*). *J Clin Gastroenterol* 1986; 8: 700-701.
5. Zachary PE, Cooke AR. Endoscopic diagnosis of whipworm. *Am J Gastroenterol* 1994; 89: 461.
6. Chandra B, Long JD. Diagnosis of *Trichuris trichiura* (whipworm) by colonoscopic extraction. *J Clin Gastroenterol* 1998; 27: 152-

- 157.
7. Herman MA, Ukawa K, Sugawa C. Diagnosis and removal of cecal whipworm infection. Case report and review. *Dig Dis Sci* 2000; 45: 1639-1643.
 8. Yoshida M, Kutsumi H, Ogawa M, Soga T, Nishimura K, Tomita S, Kawabata K, Kinoshita Y, Chiba T, Fujimoto S. A case of *Trichuris trichiura* infection diagnosed by colonoscopy. *Am J Gastroenterol* 1996; 91: 161-162.
 9. Okamura S, Washida Y, Iesaki K, Hayashi S. Colonoscopic diagnosis of whipworm infection. *Gastrointest Endosc* 1993; 39: 215-216.
 10. Taguchi H, Yamamoto H, Miyata T, Hayashi Y, Sunada K, Sugano K. In vivo diagnosis of whipworm (*Trichuris trichiura*) with high-definition magnifying colonoscope (with video). *Gastrointest Endosc* 2008; 68: 37.
 11. Pampiglione S, Rivasi F, Rubbiani C. Cryptic infection by whipworm mimicking a sessile polyp of the colon. *Ital J Gastroenterol Hepatol* 1997; 29: 365-366.
 12. Lorenzetti R, Campo SM, Stella F, Hassan C, Zullo A, Morini S. An unusual endoscopic finding: *Trichuris trichiura*. Case report and review of the literature. *Dig Liver Dis* 2003; 35: 811-813.
 13. Lin AT, Lin HH, Chen CL. Colonoscopic diagnosis of whipworm infection. *J Gastroenterol Hepatol* 2005; 20: 965-967.
 14. Chang CW, Chang WH, Shih SC, Wang TE, Lin SC, Bair MJ. Accidental diagnosis of *Trichuris trichiura* by colonoscopy. *Gastrointest Endosc* 2008; 68: 154.
 15. Elsayed S, Yilmaz A, Hershfield N. *Trichuris trichiura* worm infection. *Gastrointest Endosc* 2004; 60: 990-991.
 16. Elliott DE. Intestinal worms. In Feldman M, Friedman LS, Brandt LJ eds, *Sleisenger & Fordtran's Gastrointestinal and Liver Disease* (8th ed.). Philadelphia, USA. Saunders. 2006, p 2441-2442.
 17. Lee SH, Chai JY, Hong ST. *Synopsis of Medical Parasitology* (1st ed.). Seoul, Korea. Korea Medical Book. 1996, p 62-66.
 18. Keiser J, Utzinger J. Efficacy of current drugs against soil-transmitted helminth Infections: systemic review and meta-analysis. *JAMA* 2008; 299: 1937-1948.