

Cerebellar Activation Related to Various Tasks Using fMRI

Seung Bae Hwang, Hyo Sung Kwak, Sang Yong Lee, Gong Yong Jin,
Young Min Han, Young Kon Kim, Gyung Ho Chung

Purpose : Although it's been known for half a century that unique structures have evolved in the cerebellum and they then became greatly enlarged in the human brain, the function of these structures still remains unknown. The purpose of this study was to assess cerebellar activation during motor, sensory, word generation, listening comprehension, and working memory tasks with using functional magnetic resonance imaging (fMRI).

Materials and Methods : Eleven healthy right-handed subjects (Male: female, 6:5, mean age: 27.4years) were imaged on a Siemens 1.5T scanner. Whole brain functional maps were acquired using BOLD EPI sequences in the axial plane. Each paradigm consisted of five epochs of activation vs. the control condition. The activation tasks consisted of left finger complex movement, sensory stimulation of the left hand, word generation, listening comprehension, and working memory tasks. The reference function was a boxcar waveform. The activation maps were thresholded at $p = 0.001$. SPM 5 evaluated the activated areas and responses within the cerebellum.

Results : Cerebellar activation was observed on motor task, word generation task, and working memory task. There were 949 activated areas and the mean fitted and adjusted response was 0.68 during the motor task. There were 319 activated areas and the mean fitted and adjusted response was 0.15 during the word generation task. There were 330 activated areas and the mean fitted and adjusted response was 0.26 during the working memory task.

Conclusion : Our results suggest that the cerebellum is involved in a variety of functional tasks, including motor, word generation, and working memory tasks. However, during the motor task, the cerebellum showed a large activated area and a high response. Cerebellar function can be evaluated by fMRI.

Index words : Brain

Magnetic resonance (MR)

Cerebellar activation

fMRI

JKSMRM 13:47-53(2009)

¹Department of Radiology, Chonbuk National University Medical School, Jeonju, Jeonbuk, Korea

This paper was supported by funds from Chonbuk National University Research Institute.

Received; February 20, 2009, revised; March 3, 2009, accepted; March 25, 2009

Corresponding author : Gyung Ho Chung, M.D., Department of Radiology, Chonbuk National University Medical School
638-18, Keumam-dong, Dukjin-ku, Jeonju, Jeonbuk 561-712, South Korea
Tel. 82-63-250-1177, Fax. 82-63-272-0481 E-mail: chunggh@chonbuk.ac.kr

Introduction

The traditional preoccupation considered the role of the cerebellum is related with the motor functions of the cerebellum, and these motor functions of the cerebellum have been widely observed in other vertebrates as well (1).

The cerebellum is a potential structure involved by a large number of diseases, which bring ataxia characterized by dysarthria and a lack of coordination of balance, gait, extremity and eye movements. However, all lesions involved the cerebellum do not constantly cause the ataxic motor symptoms. Some publications demonstrated that the cerebellar lesions were associated with the cognitive and psychiatric impairment such as cerebellar cognitive affective syndrome or attention deficit in autism (2–4).

Anatomical and behavioral studies have combined to suggest that this extended cerebellum contributes to some sensory, a variety of cognitive process, language, and emotional aspects of behavior as well as to motor function (1, 5, 6).

However, the topographic relationships and responses among the cerebellar areas activated by different functional tasks are unclear. The purpose of this study was to assess cerebellar activation during motor, sensory, word generation, listening comprehension, and working memory tasks by performing functional magnetic resonance imaging (fMRI).

Materials and Methods

Eleven healthy right-handed volunteers (6 men and 5 women, 22–35 years old, mean age: 27.4years) were the subjects of this study. They had no history of neurological disorder, and at least a college level education. Scanning was performed with a 1.5 T whole-body MRI scanner (Symphony, Siemens, Erlangen, Germany) and using a standard head coil. The participants were instructed to hold their heads still. Sponges and straps were used to stabilize the head.

Anatomic 2-mm-thick reference axial images were acquired with a magnetization prepared-rapid acquisition gradient echo (MPRAGE) pulse sequence with parameters of 1600 msec / 3.9 msec / 15° (repetition time/echo time/flip angle), FOV: 240×240,

and a 256×256 matrix. Functional MR imaging studies with 36 axial sections covering the whole brain were performed using a multisection gradient recalled echo single shot echo planar imaging (EPI) pulse sequence. During the acquisition of the echo planar images, five rest periods were alternated with five task periods. Each period was 21.9 seconds in duration. EPI scan was acquired with parameters of 3000 msec / 40 msec (repetition time/echo time), FOV: 240×240 mm, a 64×64 matrix, and a 4 mm section thickness (36 slices).

The activation tasks consisted of left finger movement, sensory stimulation of the left hand, word generation, listening comprehension, and tasks involving the working memory. For the motor task, the left thumb was apposed against each of the other fingers a different number of times, twice against the index finger, three times against the middle finger, once against the ring finger, and twice against the little finger (7). For the sensory stimulation task, the investigator alternately brushed and removed a toothbrush on the left palm of each subject. For the word generation task, the subject silently generated as many words as possible beginning with a presented letter for each task period. For the listening comprehension task, materials were sampled from a simple essay. The essay was divided into five blocks, and the five blocks had story continuity. The same set of language materials was used in all the studies. The volunteers were instructed to pay attention to the story, to understand the contents of the hearing blocks, to relax, and to make an effort to not recall or think about the contents of the sentences, that had been presented (8). The two back memory task was used to activate working memory. The stimuli consisted of numbers shown as a random sequence and they were displayed at the center of a screen. "2-back" refers to how far back in the sequence of stimuli the subject had to recall. The two back working memory task required subjects to continually update their mental set while responding to stimuli that were presented two sequences earlier. The remainder of the working memory paradigm was conducted with the subjects at rest with their eyes-open (9–11).

The time course of the signal intensity in each pixel over 219 seconds was plotted and compared with a reference function via cross-correlation analysis. The time series images were motion corrected using a

realignment program. The images were normalized to a standard space using SPM 5 (Wellcome Department of Cognitive Neurology, London, UK) (12). The normalized images were smoothed using SPM 5. The fMRI SPM statistical program was used to estimate the effects of conditions at each voxel according to the general linear model. The analysis was entered as an epoch design of the fixed response/box car form. Activation maps were thresholded at $p = 0.001$, and cluster size = 30. Activated areas on the functional images were overlaid on to the corresponding anatomic reference images with using SPM 5. The resulting activation-maps for each subject were then standardized into MNI (Montreal Neurological Institute) stereotactic coordinates using SPM 5. The axial, sagittal, and volume rendered activation maps were generated with the group analysis tools in SPM 5.

The activated areas and the fitted and adjusted responses of those volunteers who demonstrated any

activation of the cerebellum were tabulated and compared across the various tasks. The Wilcoxon signed rank test was used to test that the fitted and adjusted responses within the cerebellum differed among the motor, word generation, and working memory tasks for each subject.

Results

The motor, word generation, and working memory tasks produced cerebellar activation, according to group analysis. There was no activation in the cerebellum during the sensory and listening comprehension tasks. The local maxima of the activation clusters inside the cerebellum are shown in Fig. 1~3 (arrowhead). As would be expected predominantly left (ipsilateral) cerebellar activation was observed on the motor task. There were 949 activated areas and the mean fitted and adjusted response was

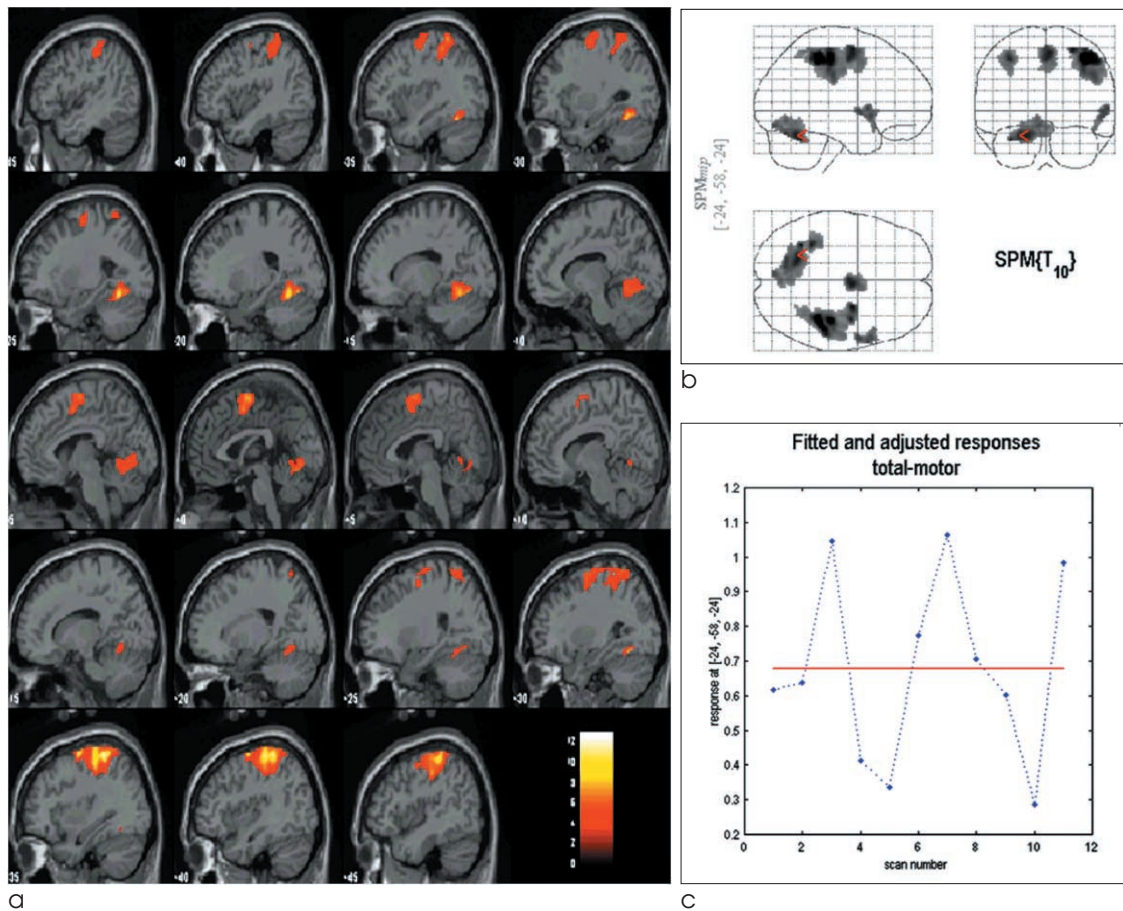


Fig. 1. Sagittal MPRAGE with overlapped activation shows ipsilateral cerebellar activation during the complex left motor tasks (a). Maximum intensity projection (MIP) of the SPM shows the left cerebellar activation (arrow) (b). The mean fitted and adjusted response of the motor task group was 0.68 (c).

0.68 during the motor task (Fig. 1). The central aspect of the cerebellum tended to be activated during the word generation tasks. There were 319 activated areas and the mean fitted and adjusted response was 0.15

during the word generation task (Fig. 2). Coronal MPRAGE with overlapped activation showed both cerebellar activations (left predominance) during the working memory tasks. There were 330 activated areas

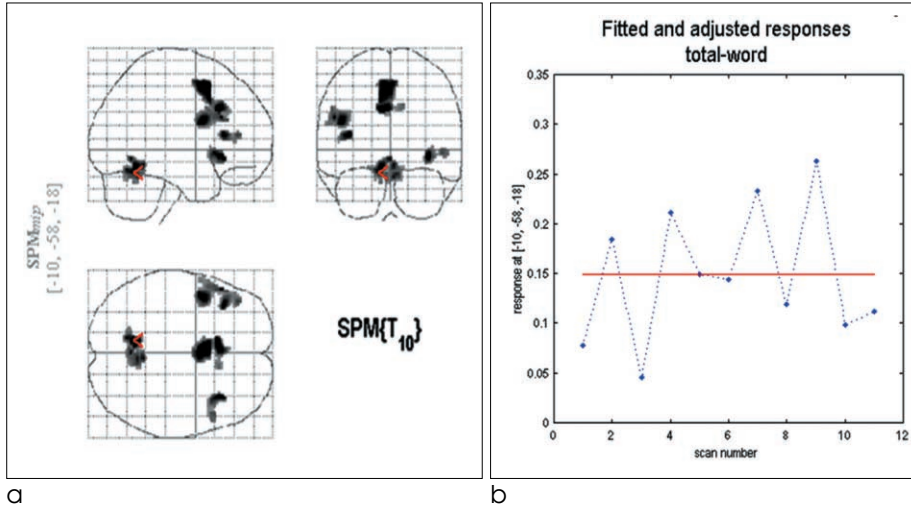


Fig. 2. Maximum intensity projection (MIP) of the SPM shows central cerebellar activation during the word generation tasks. The arrow marks the activation detected by all the analyses (a). The mean fitted and adjusted response of the word generation task group was 0.15 (b).

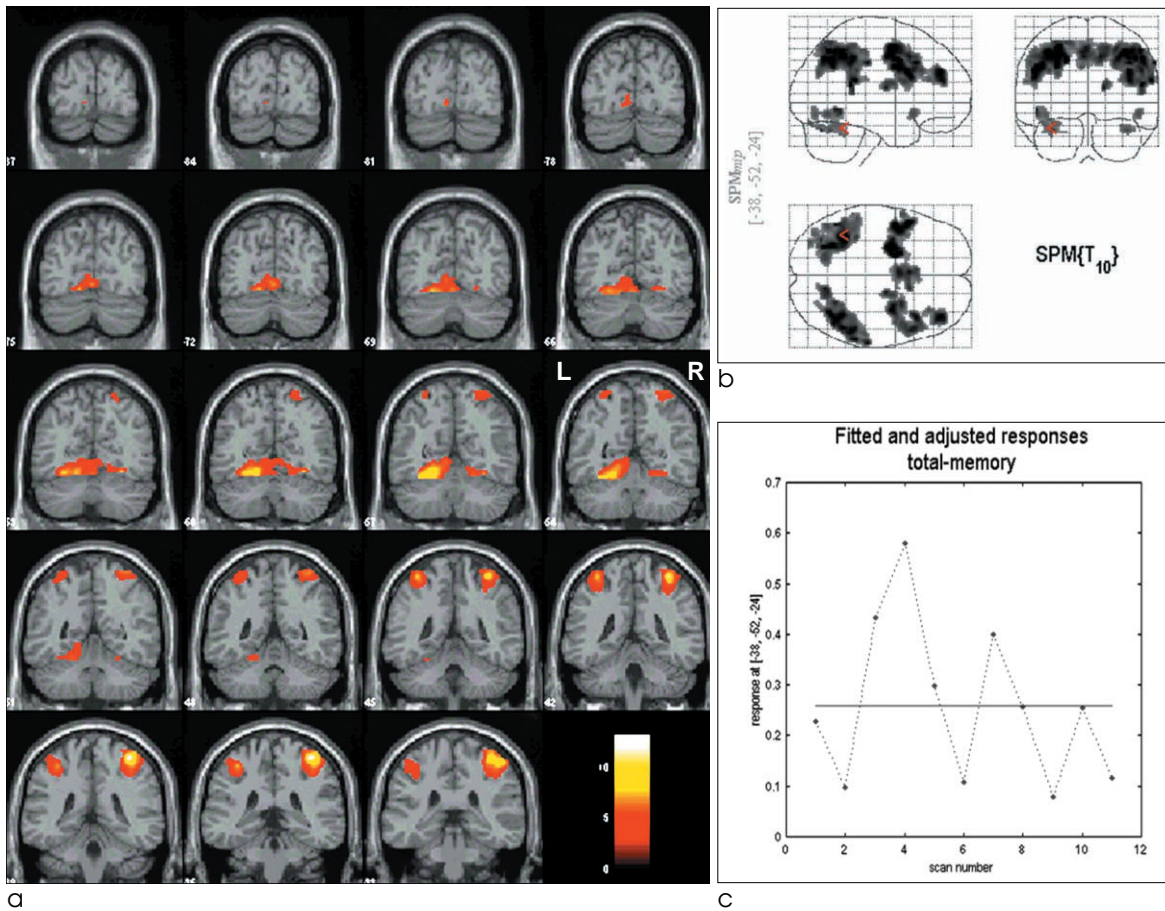


Fig. 3. Coronal MPRAGE with overlapped activation shows both cerebellar activations (left predominance) during the working memory tasks (a). The arrow marks the activation detected by all the analyses (b). The mean fitted and adjusted response of the working memory task group was 0.26 (c).

Table 1. The Mean Fitted and Adjusted Responses of the Motor, Word, and Working Memory Task

	Motor	Word	Memory
1	0.62	0.08	0.22
2	0.64	0.18	0.10
3	1.05	0.05	0.43
4	0.41	0.22	0.58
5	0.33	0.15	0.30
6	0.77	0.14	0.11
7	1.06	0.24	0.41
8	0.71	0.12	0.26
9	0.61	0.27	0.09
10	0.27	0.10	0.26
11	0.99	0.11	0.13
Mean	0.68	0.15	0.26

and the mean fitted and adjusted response was 0.26 during the working memory task (Fig. 3).

The mean fitted and adjusted response during the motor task was larger than that during the word generation and working memory tasks ($p < 0.05$). The differences of the mean fitted and adjusted response during the word generation and working memory tasks did not achieve statistical significance ($p > 0.05$) (Table 1).

Discussion

The control of movement has been considered as the role of the cerebellum, partly through link with the cerebral cortex. These cerebro-cerebellar connections were thought to combine inputs from widespread regions of the cerebral cortex (13). The cerebellum has been considered as motor functions, this view of its function, however, is being questioned by a data related to the non-motor functions of the cerebellum. Several data introduced in an article that, reviewed the anatomical, imaging and behavioral reports of cerebellar involvement in functioning of cognitive, language, and emotional aspects of behavior (1, 3, 5, 14). In our study, cerebellar activation was observed on the complex motor, word generation and, working memory tasks. There was no activation in the cerebellum on the sensory and listening comprehension tasks.

The phylogenetically older structures in the cerebellum are helpful in skilled motor functions. In the same way, phylogenetically new structures of the cerebellum may contribute to skilled mental

performance. The skilled motor functions such as skilled manipulation of muscles are assisted by signals from the older part of the dentate nucleus, which definitely help the cerebral motor cortex. Therefore, signals from the new part of the dentate nucleus may assist the cerebral association cortex to effect skilled manipulation of information or ideas (15).

Recent studies, including ours, have shown that the cerebellum should no longer be regarded as a functionally homogenous area, but rather, as one composed of subregions with distinct functional roles (1, 5, 13). During complex motor tasks, activation tended to occur in the ipsilateral portion of the cerebellum. In contrast, the word generation task tended to produce activation in the central portion of the cerebellum. The working memory task produced significant activation in both sides (left predominance) of the cerebellum.

The survey of cerebellar activation that is taken during the motor task is worthwhile to evaluate the restoration of cerebrovascular accidents. The cerebellar activation is clearly changed in the cerebellar hemisphere contralateral to the injured corticospinal tract for stroke patients having good recovery. Also, the cerebellar activation in the cerebellar hemisphere ipsilateral to the injury interestingly increases in a transient fashion after cerebrovascular accidents, but this is independent of the success of recovery (16).

Motor tasks were increased in cerebral blood flow in the contralateral sensorimotor and premotor areas and in the ipsilateral cerebellum (17). In our study, the left finger complex movement task produced right primary motor cortical and left cerebellar activation. The cerebellar activation was significantly greater for the motor tasks than for the word generation and working memory tasks. There was a 2.5 and 4.5 times higher mean fitted and adjusted response during the motor task than that during the working memory and word generation tasks, respectively.

The anatomy of the human cerebro-cerebellar system suggests that the cerebellum can contribute to learning some cognitive and language skills as well as motor skills (4, 14). Such cerebellar capabilities can be used in other areas of the cerebral cortex to which the cerebellum sends its signals and the cerebellar output connections transmit the signals through the thalamus to the cerebral cortex. The lateral cerebellum can send

the signals through these route to new cognitive and language areas of the cerebral cortex, such as Broca's area in the prefrontal cortex (1, 5, 14).

In our study, the word generation task produced Broca's area activation and the central aspect of the cerebellar activation. The cerebellar activation volume and the mean fitted and adjusted responses were smaller for the word generation tasks than for the motor generation and working memory tasks.

Cerebellar activation was also observed on the working memory task. Prior n-back memory studies that specifically examined the relationship between the working memory load and the cerebellum have demonstrated that increasing the working memory load produces increased cerebellar activation (10, 14, 18–20).

Supporting this anatomical evidence is the mounting behavioral evidence, obtained both in normal brains and in clinical studies, which indicates that the lateral cerebellum is indeed involved in some cognitive functions (1, 3, 5, 18, 21, 22).

In our study, the working memory task produced frontoparietal cortical and bilateral cerebellar activation (left predominance). The cerebellar activation volume and the mean fitted and adjusted response were smaller for the working memory task than that for the motor task.

Conclusion

Our results suggest that the cerebellum is involved in a variety of functional tasks, including motor, word generation, and working memory. However, during the motor task, the cerebellum showed a large activated area and a high response. Cerebellar function can be evaluated using fMRI.

References

1. Leiner HC, Leiner AL, Dow RS. The human cerebro-cerebellar system: its computing, cognitive, and language skills. *Behav Brain Res* 1991;44:113-128.
2. Schmahmann JD. Disorders of the cerebellum: ataxia, dysmetria of thought, and the cerebellar cognitive affective syndrome. *J Neuropsychiatry Clin Neurosci* 2004;16:367-378.
3. Allen G, Courchesne E. Differential effects of developmental cerebellar abnormality on cognitive and motor functions in the cerebellum: an fMRI study of autism. *Am J Psychiatry* 2003;160:262-273.
4. Ackermann H, Mathiak K, Riecker A. The contribution of the

- cerebellum to speech production and speech perception: clinical and functional imaging data. *Cerebellum* 2007;6:202-213.
5. Leiner HC, Leiner AL, Dow RS. Cognitive and language functions of the human cerebellum. *Trends Neurosci* 1993;16:444-447.
6. Leiner HC, Leiner AL, Dow RS. Cerebro-cerebellar learning loops in apes and humans. *Ital J Neurol Sci* 1987;8:425-436.
7. Roland PE, Larsen B, Lassen NA, Skinhoj E. Supplementary motor area and other cortical areas in organization of voluntary movements in man. *J Neurophysiol* 1980;43:118-136.
8. Nakai T, Matsuo K, Kato C, Matsuzawa M, Okada T, Glover GH, et al. A functional magnetic resonance imaging study of listening comprehension of languages in human at 3 tesla comprehension level and activation of the language areas. *Neurosci Lett* 1999;263:33-36.
9. Callicott JH, Mattay VS, Bertolino A, Finn K, Coppola R, Frank JA, et al. Physiological characteristics of capacity constraints in working memory as revealed by functional MRI. *Cereb Cortex* 1999;9:20-26.
10. Jonides J, Schumacher EH, Smith EE, Koeppel RA, Awh E, Reuter-Lorenz PA, et al. The role of parietal cortex in verbal working memory. *J Neurosci* 1998;18:5026-5034.
11. Thomas KM, King SW, Franzen PL, Welsh TF, Berkowitz AL, Noll DC, et al. A developmental functional MRI study of spatial working memory. *Neuroimage* 1999;10:327-338.
12. Friston KJ. Commentary and opinion: II. Statistical parametric mapping: ontology and current issues. *J Cereb Blood Flow Metab* 1995;15:361-370.
13. Middleton FA, Strick PL. Cerebellar output channels. *Int Rev Neurobiol* 1997;41:61-82.
14. Timmann D, Daum I. Cerebellar contributions to cognitive functions: a progress report after two decades of research. *Cerebellum* 2007;6:159-162.
15. Leiner HC, Leiner AL, Dow RS. Does the cerebellum contribute to mental skills? *Behav Neurosci* 1986;100:443-454.
16. Small SL, Hlustik P, Noll DC, Genovese C, Solodkin A. Cerebellar hemispheric activation ipsilateral to the paretic hand correlates with functional recovery after stroke. *Brain* 2002;125:1544-1557.
17. Colebatch JG, Deiber MP, Passingham RE, Friston KJ, Frackowiak RS. Regional cerebral blood flow during voluntary arm and hand movements in human subjects. *J Neurophysiol* 1991;65:1392-1401.
18. Ben-Yehudah G, Guediche S, Fiez JA. Cerebellar contributions to verbal working memory: beyond cognitive theory. *Cerebellum* 2007;6:193-201.
19. Fliessbach K, Trautner P, Quesada CM, Elger CE, Weber B. Cerebellar contributions to episodic memory encoding as revealed by fMRI. *Neuroimage* 2007;35:1330-1337.
20. Hayter AL, Langdon DW, Ramnani N. Cerebellar contributions to working memory. *Neuroimage* 2007;36:943-954.
21. Middleton FA, Strick PL. Basal ganglia and cerebellar loops: motor and cognitive circuits. *Brain Res Brain Res Rev*

다양한 임무 부여시 기능적 자기공명영상에서 관찰된 소뇌의 활성화

전북대학교 의학전문대학원 영상의학과

황승배 · 박효성 · 이상용 · 진공용 · 한영민 · 김영근 · 정경호

목적: 기능적 자기 공명 영상을 이용하여 운동, 감각, 단어만들기, 듣고이해하기, 그리고 기억하기 등의 자극을 주어 소뇌 활성화를 평가하는 것이다.

대상 및 방법: 11명의 건강한 오른손잡이 지원자 (남: 여, 6:5, mean age: 27.4세)를 대상으로 1.5T 자기공명영상기기의 BOLD기법을 이용하여 뇌 전체를 축상면으로 기능적 자기공명영상을 얻었고 패러다임은 5번의 자극과 휴식을 반복 사용하였다. 왼쪽 손가락의 복잡한 운동, 감각 자극, 단어만들기, 듣고이해하기, 그리고 기억하기를 활성화 자극으로 사용하였고, 한계치는 $p = 0.001$ 를 사용하여, 소뇌 내 활성화를 SPM 5를 이용하여 활성화된 영역의 부위와 활성화정도를 평가하였다.

결과: 소뇌 활성화는 운동, 단어만들기, 그리고 기억하기에서 관찰되었다. 운동 자극에서는 949 영역이 활성화되었고 평균반응정도는 0.68이었고 단어만들기 자극에서는 319 영역이 활성화되었고 평균반응정도는 0.15이었으며 기억자극에서는 330의 영역이 활성화되었고 평균반응정도는 0.26이었다.

결론: 소뇌는 운동, 단어만들기, 그리고 기억하기등 다양한 기능적 자극에 관련이 되어 있으며, 이중에서도 운동기능에 가장 연관이 있었다. 기능적 자기 공명 영상은 소뇌 기능 연구하는 방법으로 이용이 가능할 것이다.

통신저자 : 정경호, (561-712) 전주시 덕진구 금암동 638-18, 전북대학교 의학전문대학원 영상의학과
Tel. 82-63-250-1177 Fax. 82-63-272-0481 E-mail: chunggh@chonbuk.ac.kr