

## IN VITRO EVALUATION OF CLEANING EFFICACY OF VARIOUS IRRIGATION METHODS IN MANDIBULAR MOLARS

So-Young Lee · Won-Jun Son · WooCheol Lee · Kee-Yeon Kum · Kwang-Shik Bae · Seung-Ho Baek\*

*Department of Conservative Dentistry, School of Dentistry, Seoul National University*

### ABSTRACT

The aim of this in vitro study was to evaluate the cleaning efficacy of various irrigation methods in the mandibular mesial roots. The forty five mesial root canals were shaped by Profile .06 instruments to apical size #30 and irrigated with 5 ml of 3.5% NaOCl. The teeth were divided into 3 groups and irrigated finally for 1 minute: Group 1: syringe irrigation, Group 2: ultrasonic irrigation, Group 3: RinsEndo irrigation.

After histological processing, the cross sections of apical 1, 3, and 5 mm level were examined with an optical microscope. The cleanliness values of canals and isthmuses were calculated and analyzed by Mann-Whitney U test.

1. There were no significant differences in both canal and isthmus cleanliness between syringe irrigation and ultrasonic irrigation except 5 mm level of isthmus.
2. RinsEndo irrigation had significantly higher canal cleanliness values than syringe irrigation at 1 mm and 3 mm levels ( $p < 0.05$ ). Also, RinsEndo irrigation had significantly higher isthmus cleanliness values than syringe irrigation at all levels evaluated ( $p < 0.05$ ).
3. There were no statistical differences in both canal and isthmus cleanliness between ultrasonic irrigation and RinsEndo irrigation except 3 mm level of canal.

From this study, RinsEndo irrigation can be useful as an additional irrigation procedure. [J Kor Acad Cons Dent 34(3):215-222, 2009]

**Key words:** canal irrigation, cleanliness, mesial canal

-Received 2009.4.6., revised 2009.4.24., accepted 2009.4.29.-

### 1. Introduction

The most important objective of root canal therapy is to minimize the number of microorganisms and pathologic debris in root canal systems to prevent or treat apical periodontitis<sup>1)</sup>. Root canal preparation was considered as the foundation for successful endodontic therapy<sup>2,3)</sup>. This process is accomplished using a combination of mechanical instrumentation and chemical irrigation. As the root canal anatomy is

complex, some portions of the root canal were routinely left untouched following root canal preparation<sup>4-7)</sup>. Given the limitation of instrumentation methods, it is necessary to develop the additional methods to clean the whole complex root canal spaces, like an isthmus or a fin. These anatomical structures can act as bacterial reservoirs and may reduce the success rate of conventional endodontic procedures<sup>8)</sup>.

To achieve better cleaning of the complex root canals, several irrigation methods were introduced. Traditionally irrigants are delivered by syringe and needle. The mechanical action of conventional syringe irrigation is influenced by variables such as volume of irrigant, penetration depth of the needle, and design and size of the irrigation needle<sup>9)</sup>. Previous studies

---

\* Corresponding Author: **Seung-Ho Baek**  
Dept of Conservative Dentistry, School of Dentistry,  
Seoul National University  
28 Yeongon-dong, Jongno-gu, Seoul, Korea  
Tel: 82-2-2072-3820 Fax: 82-2-747-0958  
E-mail: shbaek@snu.ac.kr

have shown that the efficacy of syringe irrigation to remove dentin debris is not sufficient<sup>4,10-12</sup>.

Enhancing the action of irrigant by ultrasonics is well documented<sup>10,13-16</sup>. The ultrasonic device is designed to allow the irrigant to pass along the ultrasonic files. Cunningham et al.<sup>14</sup> compared the efficacy of hand irrigation and ultrasonic irrigation to remove debris and found that after ultrasonic irrigation the canal wall was cleaner than hand irrigation. The outstanding cleaning by ultrasonic irrigation was confirmed in mandibular mesial roots, which contained isthmuses frequently<sup>17-20</sup>.

More recently RinsEndo (Dürr Dental, Bittigheim-Bissingen, Germany), which is a new irrigation system based on hydrodynamic activation, has been introduced. RinsEndo system was designed to overcome the limitations of syringe irrigation and ultrasonic irrigation, so more exchange of irrigating solution was possible. 65  $\mu$ l of irrigating solution oscillating at a frequency of 1.6 Hz are automatically drawn from the attached syringe. During the suction phase, the used solution and air are aspirated back and automatically merged with fresh irrigating solution. However, there is still lack of scientific data regarding the cleaning ability of this new irrigation system to remove debris or necrotic tissue in mechanically inaccessible areas during instrumentation.

Therefore, the aim of this in vitro study was to evaluate the cleaning efficacy of RinsEndo system compared to ultrasonic or syringe irrigation method in human mandibular mesial roots.

## II . Materials and Methods

Extracted human mandibular molars with fully formed apices were stored in 10% formalin at room temperature. Radiographs were taken in both mesiodistal and buccolingual views. Root canal curvatures were measured on both buccolingual and proximal views according to Schneider<sup>21</sup>. Forty five mandibular molars were finally selected using the following criteria: (a) curvature of canal in mesiodistal plane was between 10 and 30 degrees; (b) mesial roots displaying unidirectional curvature in both buccolingual and proximal view radiographs; (c) only mesial root canals having a snug fit with either #10

or #15 K-file after coronal flaring; and (d) mesial root canals without internal calcification and apical root resorption. Access cavities were prepared using No. 4 round burs (SS White Burs, Inc., Lakewood, NJ, USA) while size 2 to 4 Gates-Glidden burs (Mani Inc., Utsunomiya, Japan) were used for coronal flaring. A #10 stainless steel K-file (Mani Inc., Utsunomiya, Japan) was introduced into each canal until it just protruded through the apical foramen. The working lengths were established by subtracting 1 mm from the lengths of the files when they extruded just beyond the apical foramen. Canals were shaped by Profile .06 instruments (Dentsply Maillefer, Ballaigues, Switzerland) with crown-down technique. All mesial root canals were instrumented to apical size #30, .06 taper. Each rotary file was used with Rc-Prep (Premier Dental Products Co., Plymouth Meeting, PA, USA) during instrumentation. Canals were irrigated with approximately 5ml of 3.5% sodium hypochlorite after each instrumentation (total 10ml). Irrigants were delivered using a 30G Maxi-Probe needle (Dentsply MPL Technologies Inc., Franklin Park, IL, USA), which was inserted as far into the prepared root as possible without binding.

After canal preparation, the instrumented teeth were randomly divided into 3 groups. Group 1 consisted of 15 teeth irrigated with 3.5% NaOCl using a 30G Maxi-Probe needle for 1 minute per canal. Group 2 consisted of 15 teeth irrigated with leaving aliquots of NaOCl energized by ultrasound for 1 minute per canal. Suprasson P-Max ultrasonic device (Satelec, Paris, France) was used at the endodontic power setting, and an ultrasonic file mounted on piezoelectric handpiece was activated. A #15 ultrasonic file was used because this file would not touch the root canal walls, and perform passive agitation of irrigating solution. The file was inserted in the canal, and then slowly withdrawn without exerting any pressure apically. Group 3 consisted of 15 teeth irrigated with RinsEndo system (Dürr Dental, Bittigheim-Bissingen, Germany) for 1 minute per canal.

After biomechanical preparation, the mesial roots were separated from the teeth. The specimens were immersed in 10% formalin for 7 days and decalcified

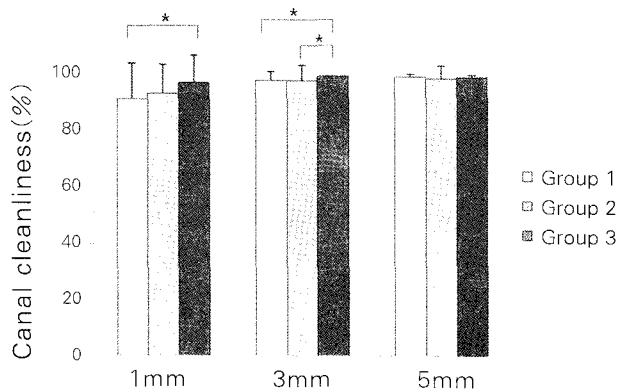
in 5% nitric acid for 3 days. The roots were then dehydrated and mounted in paraffin blocks. 4  $\mu$ m sections were obtained using a Leica RM 2145 microtome (Leica Microsystems, Nussloch, Germany) at 1, 3, and 5 mm levels from the apex. Slides were stained with hematoxylin and eosin.

The cross section images were acquired on an Olympus IX-70 microscope (Olympus Electric Industry Co., Tokyo, Japan) at 40X magnification using a spot RT-KE digital camera. Spot imaging software (version 4.6, Diagnostic instruments, Sterling Heights, MI, USA) was used to measure the total area of the canals and isthmuses and the area of the debris within these canals and isthmuses. The area of canal space was calculated ( $\mu$ m<sup>2</sup>) by tracing the outline of the root canal. By designating dots in the remaining debris, the area with same color level was automatically captured. By repeating this

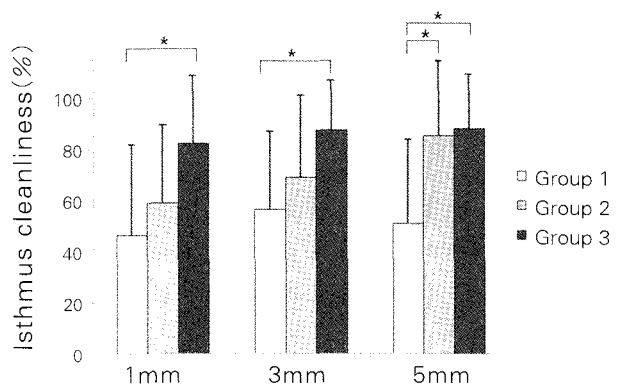
process, the total debris in the canal space was identified and calculated. Canal cleanliness was determined by subtracting the total area of debris from the canal space and the final value was expressed as a percentage. The isthmuses between canals were traced separately from the primary root canals and cleanliness values for the isthmuses were calculated in the same manner as described above. These data were submitted for statistical analysis by Mann-Whitney U test through SPSS 12.0 (SPSS Inc, Chicago, IL, USA). The significance level was set at  $p < 0.05$ .

### III. Results

Mean cleanliness values of the canal and isthmus at the 1, 3, and 5 mm apical levels are shown in Table 1 and 2. A comparison of the canal and isthmus cleanliness is shown in Figure 1 and 2.



**Figure 1.** Graph of mean percentage of canal cleanliness at 1, 3, and 5 mm levels  
\* Statistically significant ( $p < 0.05$ ).



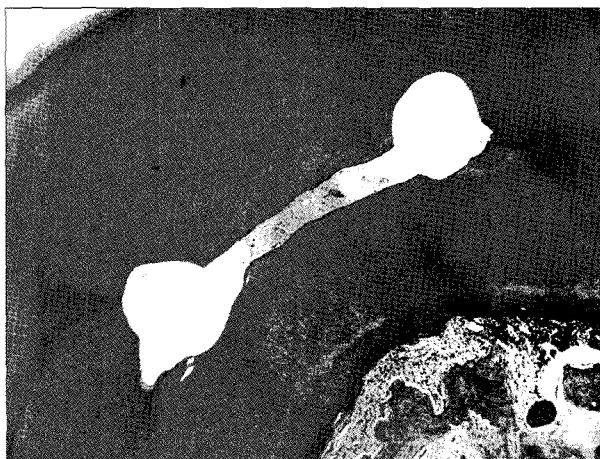
**Figure 2.** Graph of mean percentage of isthmus cleanliness at 1, 3, and 5 mm levels  
\* Statistically significant ( $p < 0.05$ ).

**Table 1.** Mean percentage of canal cleanliness at 1, 3, and 5 mm levels

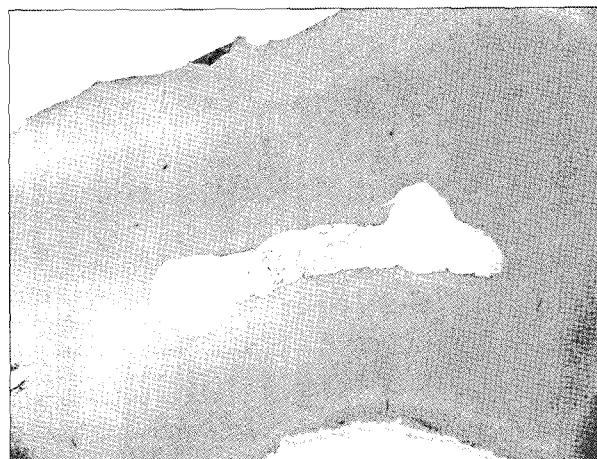Level	n	Group 1 (%)	n	Group 2 (%)	n	Group 3 (%)
1 mm	25	91.7±12.7	29	93.5±10.2	21	97.3±9.9
3 mm	30	98.5± 3.0	30	98.4± 5.3	28	100.0±0.0
5 mm	30	99.7± 1.0	28	99.1±14.6	30	99.8±0.7

**Table 2.** Mean percentage of isthmus cleanliness at 1, 3, and 5 mm levels

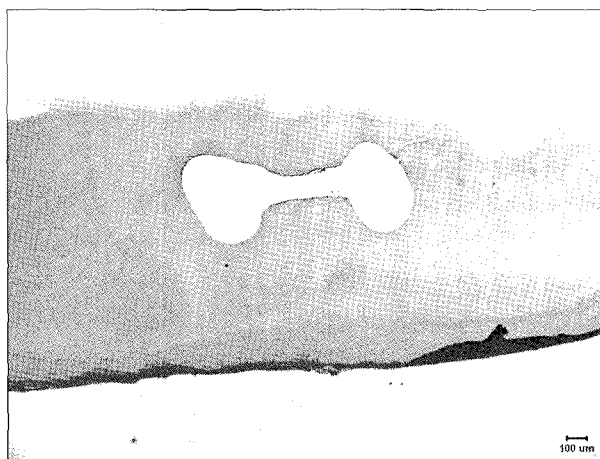
Level	n	Group 1 (%)	n	Group 2 (%)	n	Group 3 (%)
1 mm	8	46.3±35.6	10	59.0±30.5	8	82.5±26.4
3 mm	11	56.6±30.5	11	69.3±32.0	13	87.6±19.5
5 mm	10	51.0±33.2	15	85.4±29.6	13	88.1±21.5



**Figure 3.** Photomicrograph of cross section of the mesial root at the 5 mm level (group 1): 100% mesiobuccal canal (right) and 100% mesiolingual canal (left) cleanliness, with 41.1% isthmus cleanliness (40 $\times$ , H&E stain)



**Figure 4.** Photomicrograph of cross section of the mesial root at the 1 mm level (group 2): 100% mesiobuccal canal (right) and 100% mesiolingual canal (left) cleanliness, with 89.2% isthmus cleanliness (40 $\times$ , H&E stain)



**Figure 5.** Photomicrograph of cross section of the mesial root at the 1 mm level (group 3): 100% mesiobuccal canal (right) and 100% mesiolingual canal (left) cleanliness, with 100% isthmus cleanliness (40 $\times$ , H&E stain)

Examples of canal preparation with three different methods are shown in Figure 3, 4, and 5.

There were no statistical differences in both canal and isthmus cleanliness between syringe irrigation and ultrasonic irrigation except 5 mm level of isthmus ( $p = 0.019$ ).

RinsEndo irrigation had significantly higher canal values than syringe irrigation at 1 mm and 3 mm levels ( $p < 0.05$ ). Also, RinsEndo irrigation had significantly higher isthmus cleanliness values than syringe irrigation at all levels evaluated ( $p < 0.05$ ).

There were no statistical differences in both canal and isthmus cleanliness between ultrasonic irrigation and RinsEndo irrigation except 3 mm level of canal ( $p = 0.047$ ).

#### IV. Discussion

An isthmus is a narrow, ribbon-shaped communication between two root canals which contains pulp tissues<sup>22</sup>. Isthmus have been found in the mesial roots of maxillary and mandibular molars, the distal root of mandibular molars, the maxillary and mandibular first and second premolars and mandibular incisors. The incidence of an isthmus was higher in the apical 3-5 mm than other area<sup>8,23</sup>. The prevalence of isthmuses in the mesial root of mandibular molars has been reported from 44 to 80% in previous studies<sup>8,24</sup>.

In our study, the prevalence of isthmuses was found according the following: 61.9% (1 mm level), 79.5% (3 mm level), 84.4% (5 mm level). Higher prevalence of isthmuses was found at the 3 mm and 5 mm levels compared to the 1 mm level. This result was similar to those of previous studies<sup>8,23</sup>. In some areas, partial isthmuses were observed. A partial isthmus was classified as a narrow projection of one root canal opening toward the second in the same root section but not merging<sup>8</sup>. Furthermore cross

sections containing multiple canals were observed in 2 cases.

The presence of debris in isthmuses has important clinical implications. Isthmuses may be poorly accessible with root canal instruments, act as bacterial reservoirs and may reduce success rate of endodontic treatment<sup>25,26</sup>. Therefore, the cleaning of isthmuses is clinically important.

The effectiveness for irrigation depends on the ability of irrigating solution to contact the entire root canal system. The flushing action created by syringe irrigation is relatively weak. Ram<sup>27</sup> reported that during syringe irrigation, the irrigating solution passes only 1 mm deeper than the tip of the needle.

The flushing action of irrigants may be enhanced by ultrasonics. Greater contact area to the canal wall is possible with the activated streaming of the irrigant. Passive ultrasonic irrigation was first described by Weller et al.<sup>28</sup>. The term 'passive' related to the 'noncutting' action of the ultrasonically activated file. Acoustic streaming created by vibrating instrument is more important mechanism than cavitation in canal debridement<sup>29</sup>. As the root canal has already been shaped, the file can move freely with minimum cutting effect and the irrigant can penetrate more deeply into the apical portion of the root canal. From the studies where passive ultrasonic irrigation and syringe irrigation were compared, it was reported that passive ultrasonic irrigation is effective for removal of dentin debris microorganisms (planktonic or in biofilm) and organic tissue from the root canal<sup>29,30</sup>.

In this study, ultrasonic irrigation had significantly higher isthmus cleanliness value than syringe irrigation only at 5 mm apical level. This finding was different from those reported by previous studies<sup>17-20</sup>, which show that ultrasonically activated files were effective at all levels. A factor which might have account for low effectiveness of ultrasonic irrigation at levels relatively close to apex was the inability to insert the ultrasonic needle deeply into the apex. Because canal irregularities or curvatures may prevent further apical penetration of ultrasonic needle. Furthermore, a number of experimental variables (application time of ultrasonics, concentration and volume of irrigating solution, etc) may have account-

ed for the differences. If longer time of ultrasonic irrigation was applied or irrigating solution was continuously delivered, the results would show improved cleanliness values<sup>20</sup>.

This study showed that RinsEndo irrigation had significantly higher canal cleanliness values than syringe irrigation at 1 mm and 3 mm apical levels. Furthermore, it had significantly higher isthmus cleanliness values than syringe irrigation at all levels. Clinically, it may be important that RinsEndo irrigation is effective at isthmuses related to endodontic failure. RinsEndo system may allow greater volume, exchange of irrigant than syringe irrigation. The volume of irrigant delivered with RinsEndo system was preset 6.2 ml during 1 minute. Mean 4.18 ml of irrigant was applied during 1 minute of syringe irrigation with 30G Maxi-Probe needle and it was less than the volume delivered with RinsEndo over the same amount of time. In addition, constant replacement of fresh irrigant was possible during RinsEndo irrigation. According to Moorer and Wesselink<sup>31</sup>, chlorine, which is responsible for the dissolution of organic tissue, is consumed rapidly, probably within 2 minute. Therefore regular replenishment of irrigant is essential and this may explain the improved cleanliness values following irrigation with RinsEndo system in the present study.

Although cleanliness was increased significantly, complete removal of debris was not always obtained. Some debris was observed in the narrow isthmuses. However, RinsEndo irrigation had significantly cleaner isthmuses than syringe irrigation.

Although it seems that RinsEndo system is more effective than conventional syringe irrigation, extrusion of irrigant out of the apex is a concern in using RinsEndo system. Extrusion of NaOCl often results in severe periapical tissue damage<sup>32,33</sup>. According the manufacturer, it was shown that the pressure created by RinsEndo is lower than the pressure created by syringe irrigation. However, Bauser et al.<sup>34</sup> reported that the high risk of apical extrusion of irrigating solution with RinsEndo irrigation device. Therefore, clinicians should be careful to avoid NaOCl accident, especially in immature permanent teeth with wide apex.

From this study, there were no statistical differences in both canal and isthmus cleanliness between ultrasonic irrigation and RinsEndo irrigation except 3 mm apical level of canal. As previously mentioned, the effectiveness of irrigation is related to the contact surface between the irrigant and the canal wall. RinsEndo irrigation and ultrasonic irrigation have different mechanisms, but these two methods allow greater contact to the canal wall than syringe irrigation, thus showing higher cleanliness values. There was a statistical difference between two groups at 3 mm apical level of canal ( $p = 0.047$ ). The mean percentage of canal cleanliness following ultrasonic irrigation and RinsEndo irrigation were 98.4% and 100%, respectively. Further investigation with more samples will be necessary in order to find out the statistical difference.

## V. Conclusion

This in vitro study evaluated the cleaning efficacy of various irrigation methods in the mesial root canals of extracted mandibular molars, focusing on the isthmuses.

From the results of this study, it can be concluded that the additional RinsEndo irrigation after canal preparation leads to better debris removal than syringe irrigation in mesial root canals in mandibular molars. Clinically, RinsEndo irrigation can be useful as an additional irrigation procedure.

## References

- Baugh D, Wallace J. The role of apical instrumentation in root canal treatment: A review of the literature. *J Endod* 31(5):333-340, 2005.
- Grossman LI. Endodontic practice, 7<sup>th</sup> ed. Philadelphia: Lea & Febiger, 1970.
- Schilder H. Cleaning and shaping the root canal. *Dent Clin North Am* 18(2): 269-290, 1974.
- Wu MK, Wesselink PR. A primary observation on the preparation and obturation of oval canals. *Int Endod J* 34(2): 137-141, 2001.
- Peters OA. Current challenges and concepts in the preparation of root canal systems: a review. *J Endod* 30(8): 559-567, 2004.
- Wu MK, van der Sluis LWM, Wesselink PR. The capability of two hand instrumentation techniques to remove the inner layer of dentin in oval canals. *Int Endod J* 36(3): 218-224, 2003.
- Meyer BE, Peters OA, Barbakow F. Effects of rotary instruments and ultrasonic irrigation on debris and smear layer score: a scanning electron microscopic study. *Int Endod J* 35(7): 582-589, 2002.
- Teixeira FB, Sano CL, Gomes BPFA, Zaia AA, Ferraz CCR, Souza Filho FJ. A preliminary in vitro study of the incidence and position of the root canal isthmus in maxillary and mandibular first molars. *Int Endod J* 36(4): 276-280, 2003.
- Hwang HK, Bae SC, Cho YL. The irrigating effect before and after coronal flaring. *J Kor Acad Cons Dent* 28(1): 72-79, 2003.
- Cunningham WT, Martin H, Forrest WR. Evaluation of root canal debridement by the endosonic ultrasonic synergistic system. *Oral Surg Oral Med Oral Pathol* 53(5): 401-404, 1982.
- Walters MJ, Baumgatter JC, Marshall JG. Efficacy of irrigation with rotary instrumentation. *J Endod* 28(12): 837-839, 2002.
- Lee SJ, Wu MK, Wesselink PR. The efficacy of ultrasonic irrigation to remove artificially placed dentin debris from different sized simulated plastic root canals. *Int Endod J* 37(9): 607-612, 2004.
- Lee SJ, Wu MK, Wesselink PR. The ability of using syringe irrigation and ultrasound irrigation to remove dentin debris from simulated extensions and irregularities in root canals. *J Kor Acad Cons Dent* 28(3):289, 2003.
- Cunningham WT, Martin H. A scanning electron microscope evaluation of root canal debridement with the endosonic ultrasonic synergistic system. *Oral Surg Oral Med Oral Pathol* 53(5): 527-531, 1982.
- Lumley PJ, Walmsley AD, Walton RE, Rippin JW. Cleaning oval canals using ultrasonic and sonic instrumentation. *J Endod* 19(9): 453-457, 1993.
- Lee SJ, Wu MK, Wesselink PR. The effectiveness of syringe irrigation and ultrasonics to remove debris from simulated irregularities within prepared root canal walls. *Int Endod J* 37(10): 672-678, 2004.
- Goodman A, Reader A, Beck M, Melfi R, Meyers W. An in vitro comparison of the efficacy of the step-back technique versus a step-back/ultrasonic technique in human mandibular molars. *J Endod* 11(6): 249-256, 1985.
- Haidet J, Reader A, Beck M, Meyers W. An in vivo comparison of the step-back technique versus a step-back/ultrasonic technique in human mandibular molars. *J Endod* 15(5): 195-199, 1989.
- Archer R, Reader A, Nist R, Beck M, Meyers W. An in vivo evaluation of the efficacy of ultrasound after step-back preparation in mandibular molars. *J Endod* 18(11): 549-552, 1992.
- Gutarts R, Nusstein J, Reader A, Beck M. In vivo debridement efficacy of ultrasonic irrigation following hand-rotary instrumentation in human mandibular molars. *J Endod* 31(3): 166-170, 2005.
- Schneider SW. A comparison of canal preparations in straight and curved root canals. *Oral Surg Oral Med Oral Pathol* 32(2): 271-275, 1971.
- Weller NR, Niemczyk SP, Kim S. Incidence and position of the canal isthmus. Part 1. Mesiobuccal root of maxillary first molar. *J Endod* 21(7): 380-383, 1995.
- Hwang HK, Shin YG. The effectiveness of obturating techniques in sealing isthmuses. *J Kor Acad Cons Dent* 26(6): 499-506, 2001.
- Hsu Y, Kim S. The resected root surface: the issue of canal isthmuses. *Dent Clin North Am* 41(3): 529-540,

- 1997.
25. Nair PNR. Pathogenesis of apical periodontitis and the causes of endodontic failures. *Crit Rev Oral Biol Med* 15(6): 348-381, 2004.
  26. Mannocei F, Peru M, Sherriff M, Cook R, Pitt Ford TR. The isthmuses of the mesial root of mandibular molars: a micro-computered tomographic study. *Int Endod J* 38(8): 558-563, 2005.
  27. Ram Z. Effectiveness of root canal irrigation. *Oral Surg Oral Med Oral Pathol* 44(2): 306-312, 1977.
  28. Weller RN, Brady JM, Bernier WE. Efficacy of ultrasonic cleaning. *J Endod* 6(9): 740-743, 1980.
  29. Ahmad M, Pitt Ford TR, Crum LA. Ultrasonic debridement of root canals: acoustic streaming and its possible role. *J Endod* 13(10): 490-499, 1987.
  30. van der Sluis LWM, Versluis M, Wu MK, Wesselink PR. Passive ultrasonic irrigation of the root canal: a review of the literature. *Int Endod J* 40(6): 415-426, 2007.
  31. Moorer WR, Wesselink PR. Factors promoting the tissue dissolving capacity of sodium hypochlorite. *Int Endod J* 15(4): 187-196, 1982.
  32. Hulsmann M, Hahn W. Complications during root canal irrigation - literature review and case reports. *Int Endod J* 33(3): 186-193, 2000.
  33. Gernhardt CR, Eppendorf K, Kozlowski A, Brandt M. Toxicity of concentrated sodium hypochlorite used as endodontic irrigant. *Int Endod J* 37(4): 272-280, 2004.
  34. Hauser V, Braun A, Frentzen. Penetration depth of a dye marker into dentine using a novel hydrodynamic system (RinsEndo). *Int Endod J* 40(8):644-652, 2007.

국문초록

하악 대구치에서 근관세척방법에 따른 잔사제거효과에 대한 평가

이소영 · 손원준 · 이우철 · 금기연 · 배광식 · 백승호\*

서울대학교 치과대학 치과보존학 교실

본 연구의 목적은 isthmus가 존재하는 하악 대구치의 근심 근관에서 근관세척방법에 따른 잔사제거효과를 평가하는 것이다. 45개의 하악 대구치의 근심근관을 #30 Profile .06까지 확대하였다. 각 근관을 3개의 군으로 나누고 conventional irrigation syringe와 초음파, RinsEndo를 사용하여 1분간 최종 세척하였다. 조직표본을 제작한 후, 광학현미경으로 치근단 1, 3, 5 mm 부위의 단면을 관찰하였다. 근관과 isthmus의 잔사 양으로 청결도를 계산하고 Mann-Whitney U test로 검정하였다.

1. 초음파 군과 syringe 군은 5 mm 부위의 isthmus를 제외한 나머지 부위에서 청결도의 유의한 차이가 없었다.
2. RinsEndo 군은 syringe 군에 비해 1 mm, 3 mm 부위의 근관과, 모든 부위의 isthmus에서 유의하게 높은 청결도를 나타내었다 ( $p < 0.05$ ).
3. 초음파 군과 RinsEndo 군은 3 mm 부위의 근관을 제외한 나머지 부위에서 청결도의 유의한 차이가 없었다.

임상적으로 RinsEndo를 이용한 근관세척방법의 추가적인 적용이 하악 대구치의 근심근관의 잔사제거에 효과가 있을 것으로 사료된다.

**주요단어:** 근관세척, 청결도, 근심근관