

## Case Report

# Cervical Disc Herniation Producing Acute Brown-Sequard Syndrome

Jong-Tae Kim, M.D., Ho-Jin Bong, M.D., \*Dong-Sup Chung, M.D., Young-Sup Park, M.D.

Department of Neurosurgery, Our Lady of Mercy Hospital, The Catholic University of Korea College of Medicine, Incheon, Korea

Brown-Sequard syndrome may be the result of penetrating injury to the spine, but many other etiologies have been described. This syndrome is most commonly seen with spinal trauma and extramedullary spinal neoplasm. A herniated cervical disc has been rarely reported as a cause of this syndrome. We present a case of a 28-year-old male patient diagnosed as large C3-C4 disc herniation with spinal cord compression. He presented with left hemiparesis and diminished sensation to pain and temperature in the right side below the C4 dermatome. Microdiscectomy and anterior cervical fusion with carbon fiber cage containing a core of granulated coralline hydroxyapatite was performed. After the surgery, rapid improvement of the neurologic deficits was noticed. We present a case of cervical disc herniation producing acute Brown-Sequard syndrome with review of pertinent literature.

**KEY WORDS :** Brown-Sequard syndrome · Cervical disc herniation · Microdiscectomy · Anterior cervical fusion.

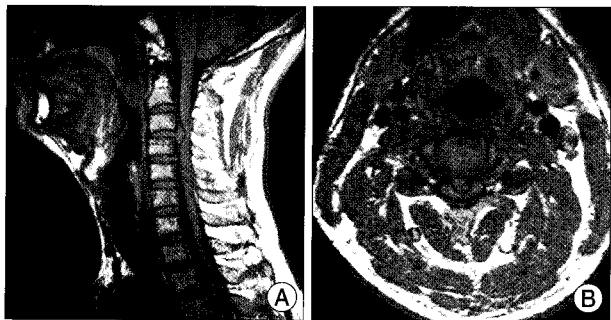
## INTRODUCTION

The Brown-Sequard syndrome involves ipsilateral motor weakness, proprioceptive and vibratory sensation loss, in association with contralateral pain and temperature sensation loss. The most frequent causes of this syndrome are traumatic injuries to the spinal cord and spinal cord tumors (metastatic or intrinsic)<sup>2,14,15,17</sup>. In addition, it has been reported in patients with various spinal pathologies, including ischemia, epidural hematoma, inflammatory causes including multiple sclerosis, and degenerative disease such as disc herniation and cervical spondylosis<sup>11,12,20,21</sup>. In particular, a herniated cervical disc has been rarely reported as a cause of this syndrome<sup>1,7,8,13,18</sup>. There were only the 4 report cases of Brown-Sequard syndrome due to a herniated C3-C4 disc. We report a case of C3-C4 herniated cervical disc causing a severe spinal cord compression, resulting in an acute Brown-Sequard syndrome.

## CASE REPORT

A 28-year-old man with a one week history of posterior neck pain had sudden left hemiparesis and disruption of pain and temperature sensation developed on the right side of his body. There was no history of trauma, arthritis, or collagen vascular disease.

Neurologic evaluation revealed motor weakness and spasticity in the left side, more pronounced in the upper extremity (MRC Grade 2/5). There was hypesthesia over the right side of the chest and abdomen and diminished sensation to pain and temperature in the right side below the C4 dermatome. There was an ipsilateral hyperreflexia



**Fig. 1.** Sagittal and axial magnetic resonance images of the cervical spine showing a large C3-C4 disc herniation with severe spinal cord compression.

• Received : June 27, 2008 • Accepted : April 22, 2009  
 • Address for reprints : Ho-Jin Bong, M.D.  
 Department of Neurosurgery, Our Lady of Mercy Hospital, The Catholic University of Korea, 665, Bupyeong-dong, Bupyeong-gu, Incheon 403-720, Korea  
 Tel : +82-32-510-5668, Fax : +82-32-511-2370  
 E-mail : loverrealbong@hanmail.net  
 \*Dr. Ho-Jin Bong move to Department of Neurosurgery, New Korea Hospital during the Processing of Manuscript.

**Table 1.** Summary of cases of Brown-Sequard syndrome due to a herniated C3-4 disc reported in the literature

Authors	Sex, Age	Initial symptoms	Surgery	Disc Nature	Outcome
Stookey (1928)	M, 44	Left leg weakness, neck pain	Laminectomy	Extradural	?
Kohno et al. (2000)	M, 34	?	ADF	Extradural	Improved
Clatterbuck et al. (2000)	F, 52	Right leg weakness	ADF	Intradural	CR
Sayer et al. (2008)	M, 46	Left arm weakness, neck pain	ADF	Extradural	Improved
Present case	M, 28	Left hemiparesis	ADF	Extradural	CR

ADF : anterior discectomy and fusion, CR : complete recovery

on the right side. He had reduced neck mobility.

Magnetic resonance imaging of the cervical spine showed a large C3-4 disc herniation with severe spinal cord compression (Fig. 1). The underlying cord showed normal signal intensity on T2 weighted images.

A standard microsurgical anterior approach to the C3-4 interspace was used, followed by a discectomy and anterior cervical fusion with carbon fiber cage containing a core of granulated coralline hydroxyapatite. A large amount of disc material was had herniated posteriorly, compressing the spinal cord. A complete decompression of the spinal cord was obtained.

After the operation, the patient remained in a rigid cervical collar (Philadelphia collar) for 8 weeks. Postoperatively, his motor power and sensation recovered dramatically within 5 days. A follow-up examination at 4 weeks revealed normal motor power in the left upper and lower extremities. The numbness had completely resolved, and pain and temperature sensation were normal.

## DISCUSSION

In 1849, Brown-Sequard first described a constellation of symptoms as a consequence of a knife injury causing hemisection of the spinal cord<sup>2</sup>. This is a syndrome classically characterized by ipsilateral hemiplegia and loss of tactile and proprioceptive sensation and contralateral loss of pain and temperature sensation (dissociated sensory loss) inferior to the lesion, beginning 1-2 segments below. This syndrome has been reported in patients with various spinal pathologies, including spinal cord tumors, ischemia, epidural hematoma, inflammatory causes including multiple sclerosis, and degenerative disease such as disc herniation and cervical spondylosis<sup>11,13,20,21</sup>. A herniated cervical disc is a rare cause of Brown-Sequard syndrome and only 25 cases have been reported in the international literature<sup>18</sup>. The first person to identify a herniated disc as the etiology of Brown-Sequard syndrome was Stookey, in 1928<sup>20</sup>.

The frequency of this syndrome produced by herniated cervical discs has been reported at 2.6% by Jomin et al.<sup>9</sup> In the literature, the age ranged from 25 to 73 years (mean 48 years). In 67% of the cases, the involved level was C5-C6

or C6-C7 and incidence of disc herniation between C2-C3 was less than 1%. And the Brown-Sequard syndrome due to a herniated C3-C4 disc is very rare (Table 1)<sup>12,18,21</sup>. The time from initial symptoms to diagnosis ranged from 1 day to 18 months (mean 4.9 months)<sup>13</sup>. In our patients, the interval between the onset of symptoms and the diagnosis was 1 week.

All patients were surgically treated with laminectomy<sup>4,5</sup> or hemilaminectomy<sup>16</sup>, with anterior discectomy without interbody fusion<sup>6,19</sup>, and with anterior discectomy or corpectomy followed by interbody fusion<sup>3</sup>. In our case, the largest portion of the disc herniation was central, and we performed an anterior C3-C4 discectomy with microsurgical decompression of dura covering roots and spinal cord. In the interspace, we applied a carbon fiber cage containing a core of granulated coralline hydroxyapatite for obtaining interbody fusion.

According to Mastronardi and Ruggeri<sup>13</sup>, the postoperative recovery of motor deficits was complete or almost complete in 10 cases and incomplete in 9 cases. The postoperative recovery of sensory deficits was complete or almost complete in 8 cases and incomplete in 11 cases. The presence of an area of spinal cord hyperintensity in the preoperative MRI, its persistence on postoperative MRI, and the severity of spinal cord compression detected by neuroradiological investigations did not affect the neurologic recovery. Outcomes are generally more favorable in those cases where rapid diagnosis by MRI is provided followed by spinal cord decompression using an anterior approach<sup>10</sup>.

## CONCLUSION

We report a case of C3-C4 herniated cervical disc causing a severe spinal cord compression, resulting in a Brown-Sequard syndrome. For the favorable outcomes, we recommend rapid diagnosis and early surgical intervention.

## References

1. Börm W, Bohnstedt T : Intradural cervical disc herniation. Case report and review of the literature. *J Neurosurg* 92 : 221-224, 2000
2. Brown-Sequard CE : De la transmission des impressions sensitives par la moelle epiniere. *C R Soc Biol* 1 : 192-194, 1849
3. Clatterbuck RE, Belzberg AJ, Ducker TB : Intradural cervical disc

- herniation and Brown-Séguard's syndrome. Report of three cases and review of the literature. *J Neurosurg* 92 : 236-240, 2000
4. Dürig M, Zdrojewski B : [Intrathecal herniation of a cervical disc. A case report (author's transl).] *Arch Orthop Unfallchir* 87 : 151-157, 1977
  5. Eisenberg RA, Bremer AM, Northup HM : Intradural herniated cervical disk : a case report and review of the literature. *AJNR Am J Neuroradiol* 7 : 492-494, 1986
  6. Finelli PF, Leopold N, Tarras S : Brown-Sequard syndrome and herniated cervical disc. *Spine* 17 : 598-600, 1992
  7. Fujimoto A, Matsumura A, Maruno T, Yasuda S, Nose T : Cervical spondylosis with thoracic level Brown-Séguard syndrome. *J Clin Neurosci* 11 : 898-900, 2004
  8. Jabbari B, Pierce JF, Boston S, Echols DM : Brown-Séquard syndrome and cervical spondylosis. *J Neurosurg* 47 : 556-560, 1977
  9. Jomin M, Lesoin F, Lozes G, Thomas CE 3rd, Rousseaux M, Clarisse J : Herniated cervical discs. Analysis of a series of 230 cases. *Acta Neurochir Wien* 79 : 107-113, 1986
  10. Kobayashi N, Asamoto S, Doi H, Sugiyama H : Brown-Séquard syndrome produced by cervical disc herniation : report of two cases and review of the literature. *Spine J* 3 : 530-533, 2003
  11. Kraus JA, Stüper BK, Berlit P : Multiple sclerosis presenting with a Brown-Séquard syndrome. *J Neurol Sci* 156 : 112-113, 1998
  12. Lee JK, Kim YS, Kim SH : Brown-Sequard syndrome produced by cervical disc herniation with complete neurologic recovery : report of three cases and review of the literature. *Spinal Cord* 45 : 744-748, 2007
  13. Mastronardi L, Ruggeri A : Cervical disc herniation producing Brown-Sequard syndrome : case report. *Spine* 29 : E28-E31, 2004
  14. Oller DW, Boone S : Blunt cervical spine Brown-Séquard injury. A report of three cases. *Am Surg* 57 : 361-365, 1991
  15. Peacock WJ, Shrosbree RD, Key AG : A review of 450 stabwounds of the spinal cord. *S Afr Med J* 51 : 961-964, 1977
  16. Roda JM, Gonzalez C, Blázquez MG, Alvarez MP, Argüello C : Intradural herniated cervical disc. Case report. *J Neurosurg* 52 : 278-280, 1982
  17. Roth EJ, Park T, Pang T, Yarkony GM, Lee MY : Traumatic cervical Brown-Sequard and Brown-Sequard-plus syndromes : the spectrum of presentations and outcomes. *Paraplegia* 29 : 582-589, 1991
  18. Sayer FT, Vitali AM, Low HL, Paquette S, Honey CR : Brown-Séquard syndrome produced by C3-C4 cervical disc herniation : a case report and review of the literature. *Spine* 33 : E279-E282, 2008
  19. Schneider SJ, Grossman RG, Bryan RN : Magnetic resonance imaging of transdural herniation of a cervical disk. *Surg Neurol* 30 : 216-219, 1988
  20. Stookey B : Compression of the spinal cord due to ventral extradural cervical chondromas. Diagnosis and surgical treatment. *Arch Neurol Psychiatry* 20 : 275-291, 1928
  21. Zupruk GM, Mehta Z : Brown-Séquard syndrome associated with posttraumatic cervical epidural hematoma : case report and review of the literature. *Neurosurgery* 25 : 278-280, 1989