

Case Report

Intraventricular Malignant Meningioma with CSF-Disseminated Spinal Metastasis : Case Report and Literature Review

Ki Seong Eom, M.D.,¹ Hun Soo Kim, M.D.,² Tae Young Kim, M.D.,¹ Jong Moon Kim, M.D.¹

Departments of Neurosurgery,¹ Pathology,² Wonkwang University School of Medicine, Iksan, Korea

The authors report a case of 42-year-old woman with an intraventricular tumor in the trigone of the left lateral ventricle. The first operation achieved a microscopically complete resection. The tumor was histologically atypical meningioma. After 26 months, there were recurrences of intraventricular meningioma. Complete resection of the tumor and adjuvant radiation therapy were performed, and the histological diagnosis was malignant meningioma. Sixteen months after the second operation, spinal metastasis in cervicolumbar lesion was diagnosed and a subtotal removal of cervical intradural extramedullary mass was performed. We describe an unusual case of intraventricular malignant meningioma with cerebrospinal fluid-disseminated spinal metastases with review of the clinical courses of previous reports.

KEY WORDS: Malignant meningioma · Intraventricular neoplasms · Spinal metastases.

INTRODUCTION

Malignant meningiomas are relatively rare neoplasms in the central nervous system, accounting for only 1-7% of intracranial meningiomas¹. Furthermore, intraventricular meningiomas account for only 0.5-3% of all meningiomas, according to the literature². Thus, malignant meningiomas in the ventricles can be considered even rarer. Malignant meningiomas have a higher recurrent and metastatic rate than benign ones², and to the best of our knowledge, only four cases of spinal metastases from intraventricular malignant meningiomas have been reported in the English literature^{3,4,6,8}. We describe one case of intraventricular malignant meningioma with spinal metastases with review of the clinical courses of previous reports.

CASE REPORT

In January 2003, we examined a 42-year-old woman

who presented with a two-month history of headache and gait disturbance. A neurological examination revealed mild right hemiparesis. A cranial magnetic resonance imaging (MRI) revealed a 43 × 49 × 62 mm sized mass in the trigone of the left lateral ventricle that was isointense and hypointense on the T1-weighted image (T1WI) and hyperintense on the T2-weighted image (T2WI). Moreover, it revealed a strong heterogeneous contrast enhancement following the administration of a contrast agent (Fig. 1A). Cystic or necrotic portions within the tumor were noted. A left temporoparietal

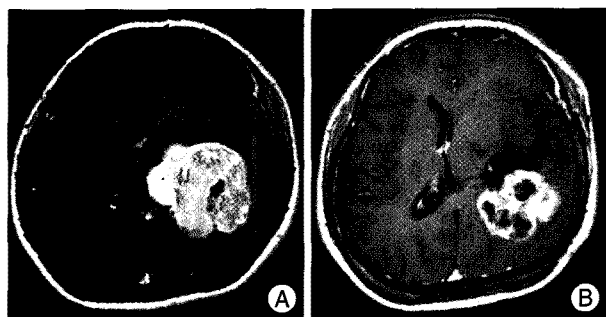

Fig. 1. A : Gadolinium-enhanced cranial magnetic resonance imaging (MRI) on January 2003 reveals a large tumor with strong homogenous enhancement in the trigone of the left lateral ventricle. B : Gadolinium-enhanced cranial MRI on March 2006 reveals recurrent tumor with strong heterogeneous enhancement, with an irregular tumor outline.

• Received : August 21, 2008 • Accepted : April 2, 2009
 • Address for reprints : Tae Young Kim, M.D.
 Department of Neurosurgery, Wonkwang University School of Medicine, 344-2 Sinyong-dong, Iksan 570-749, Korea
 Tel : +82-63-859-1462, Fax : +82-63-852-2606
 E-mail : tykim@wonkwang.ac.kr

craniotomy with a transcortical approach was performed, and the tumor in the left trigone was completely removed. The patient showed no postoperative complications and was discharged from the hospital on the 24th postoperative day. The histological diagnosis was atypical meningioma. Ki-67 labeling index was about 7% and mitotic index ranged from 6 to 7 mitoses/10HPF. The clinical condition

of the patient was satisfactory until March 2006, when she exhibited headache, dysarthria, and visual disturbances. A neurological examination revealed right homonymous hemianopia. A cranial MRI revealed a recurrent large multilobulated mass in the trigone of the left lateral ventricle that was hypointense on T1WI and isointense with prominent peritumoral edema on T2WI. Following administration of contrast material, a strong heterogeneous enhancement with an irregular tumor outline was found (Fig. 1B). The second operation was done using a left temporoparietal craniotomy. The tumor was approached transcortically and completely removed. The postoperative status of the patient was stable and she was discharged on the 14th postoperative day. The postoperative MRI revealed a total removal of the tumor, and a histological examination revealed round to polygonal meningioma cells with increased cellularity, geographic necrosis, and mitosis (Fig. 2). Immunohistochemical findings were positive for a cytoplasmic reaction to vimentin and epithelial membrane antigen. The staining reactions for pancytokeratin, glial fibrillary acidic protein, and S-100 were negative. Ki-67 labeling index was about 25% and mitotic index ranged from 25 to 26 mitoses/10HPF. The histological diagnosis was malignant meningioma. The patient received postoperative radiotherapy of the surgical bed with 5040 cGy.

In July 2007, the patient developed progressive weakness of the right upper limbs and an unsteady gait. On physical examination, she was noted to have hypoesthesia below the C4 level. A cranial MRI revealed no tumor recurrence (Fig. 3A), and a spinal MRI revealed an intradural extramedullary mass measuring about 26 mm in diameter from the C4 to C5 vertebral levels and a small nodular tumor in cauda equina (Fig. 3B, C). A laminotomy was performed at the C3-C6 vertebral levels for the largest tumor, but only a subtotal removal was possible, because of spinal cord infiltration (Fig. 3D). The specimens obtained from tumor

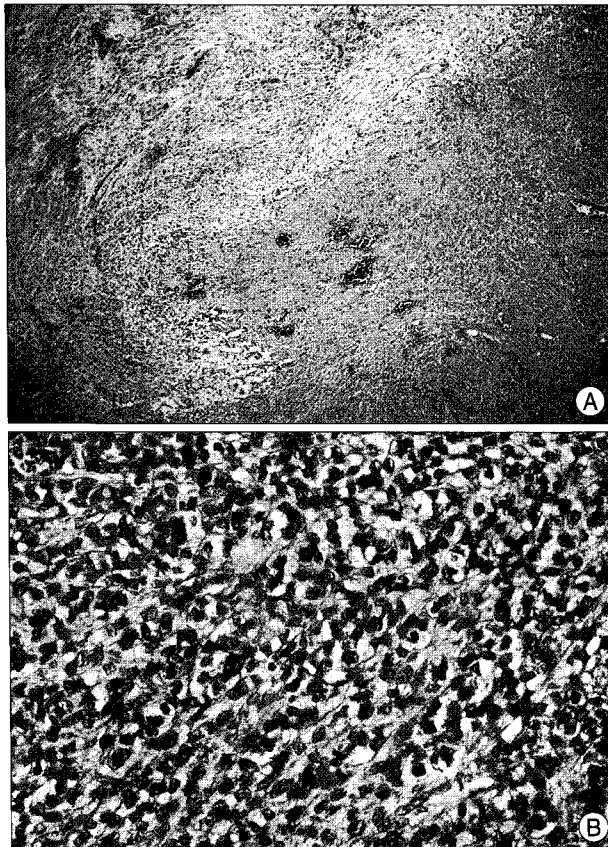


Fig. 2. A : Photomicrograph of brain specimen obtained during the second surgery reveals meningioma cells with increased cellularity and geographic necrosis (H&E, $\times 40$). B : Higher magnification reveals round to polygonal meningioma cells with increased mitosis ($>20/10$ HPF)(H&E, $\times 400$).

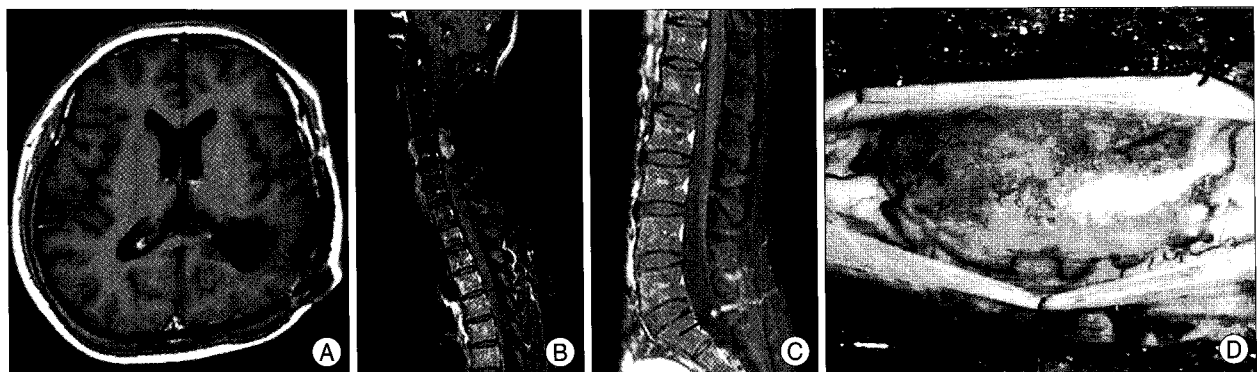


Fig. 3. A, B, and C : Gadolinium-enhanced magnetic resonance imaging (MRI) on July 2007. Cranial MRI (A) reveals no tumor recurrence. Spinal MRI of the cervical (B) and lumbar (C) reveals an intradural extramedullary mass from the C4 to C5 vertebral levels and a small nodular tumor in cauda equina (arrow). D : An intraoperative photograph reveals the intradural extramedullary tumor located at dorsal surface of the spinal cord of the C3-C6 vertebral levels.

in the spinal subarachnoidal space revealed the same hypercellular and high mitotic features, indicating that the tumor had metastasized to the spinal cord (Fig. 4). The results of the histological study of the tumor revealed

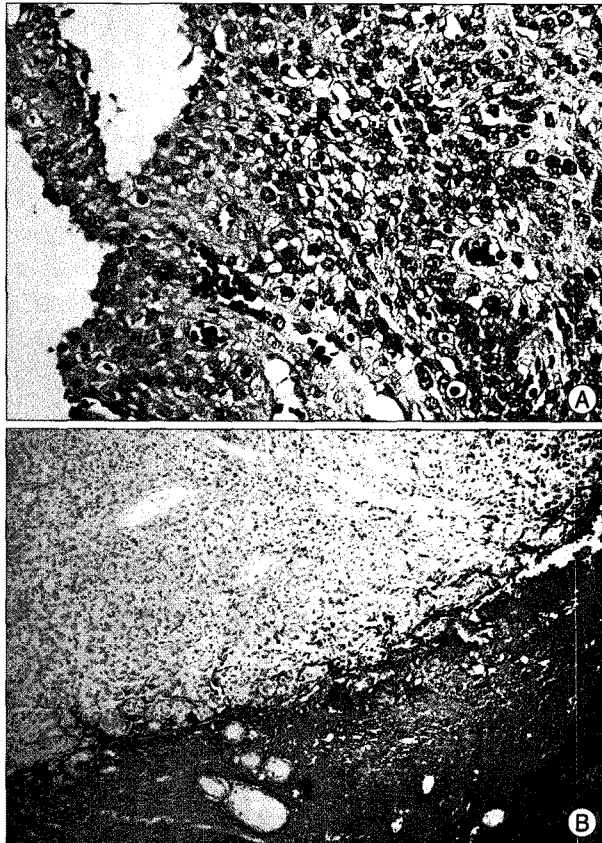


Fig. 4. A : Photomicrograph of a spinal specimen also reveals the same hypercellular and high mitotic features, indicating that the intraventricular tumor has metastasized to the spinal cord (H&E, $\times 40$). B : Immunohistochemical staining with glial fibrillary acidic protein shows the borders of the tumor infiltration ($\times 200$).

malignant meningioma. The postoperative course was uneventful, and the patient received local irradiation of the cervicolumbar lesion with 3,750 cGy in 15 fractions. The patient was referred to another hospital, and she thereafter deteriorated and died of pneumonia five months after the spinal operation.

DISCUSSION

According to the guidelines provided by the World Health Organization (WHO)⁷, the malignant (anaplastic) meningioma exhibiting histological features of frank malignancy far in excess of the abnormalities present in atypical meningioma. These include either obvious malignant cytology resembling that of carcinoma, melanoma or high-grade sarcoma, or a markedly elevated mitotic index (≥ 20 mitoses/10 HPF). These features may occur in any of the ventricles, but lateral ventricles are the most common sites⁷. The pathway of spread to the spine used by all intracranial malignancies is through the spinal subarachnoid space. Meningiomas associated with spreading via cerebrospinal fluid (CSF) and metastasis formation tend to be more malignant, and malignant meningiomas have higher metastatic rates than benign ones¹¹. In view of the physiologic pathways of CSF, the risk of intraventricular malignant meningiomas metastasizing should be high; however, malignant meningioma of the lateral ventricle with CSF-disseminated spinal metastasis is rare, of which only a few cases have been reported (Table 1). There were two male and three female patients with an age range of 34-67 years (mean: 47.6 years) and all tumors were located in the trigone of the lateral ventricle. Of these, Shintaku et al.⁸ reported that transitional meningioma of the lateral

Table 1. Literature review of cases of intraventricular malignant meningioma with spinal metastasis

Authors, year	Age/Sex	Primary site	Site of spinal metastases	Interval (months)		Spinal treatment
				From confirmation of IVMM to SM	From confirmation of SM to death	
Kleinschmidt-DeMasters BK & Avakian JJ, 1985	34/male	Trigone of left lateral ventricle	Thoracolumbar	NA	NA	No
Kamiya K et al., 1989	67/male	Trigone of right lateral ventricle	T9-T10	6	6	Total removal, local irradiation (40 Gy)
Peh WCG & Fan YW, 1995	34/female	Trigone of left lateral ventricle	L1-L5	10	4	Subtotal removal, No RT
Shintaku M et al., 2007	61/female	Trigone of right lateral ventricle	T11, upper cervical	6	NA	Total removal, No RT
Present case, 2008	42/female	Trigone of left lateral ventricle	C4-C5, Cauda equina	16	5	Subtotal removal, Local irradiation (56 Gy)

IVMM : intraventricular malignant meningioma, SM : spinal metastasis, NA : non available, RT : radiotherapy

ventricle recurred locally a long time after total removal and showed metastasis to the fourth ventricle and spinal cord and the metastatic tumors were malignant meningiomas. The outcome of patients with intraventricular malignant meningioma with spinal metastases seems to be very poor. For two patients who had received local spinal irradiation, the interval between confirmation of spinal metastases and death was six and seven months; for one patient who did not receive local spinal irradiation, that interval was four months.

CONCLUSION

Although spinal metastasis of intraventricular malignant meningiomas via CSF is rare, regular spinal MRI follow-ups of a patient with intraventricular malignant meningioma are recommended for detection of early distant metastasis, especially when spinal symptoms and signs are present. Although radiation therapy seems not to affect survival rate, the early operation and irradiation of metastatic lesions can provide substantial symptomatic relief.

• Acknowledgements

This paper was supported by Wonkwang University in 2009.

References

1. Chuang HC, Lee HC, Cho DY : Intracranial malignant meningioma with multiple spinal metastases. A case report and literature review. *Spine* 31 : E1006-1010, 2006
2. Enam SA, Abdulrauf S, Mehta B, Malik GM, Mahmood A : Metastasis in meningioma. *Acta Neurochir (Wien)* 138 : 1172-1177; discussion 1177-1178, 1996
3. Kamiya K, Inagawa T, Nagasako R : Malignant intraventricular meningioma with spinal metastasis through the cerebrospinal fluid. *Surg Neurol* 32 : 213-218, 1989
4. Kleinschmidt-DeMasters BK, Avakian JJ : Wallenberg syndrome caused by CSF metastasis from malignant intraventricular meningioma. *Clin Neuropathol* 4 : 214-219, 1985
5. McConachie NS, Worthington BS, Cornford EJ, Balsitis M, Kerslake RW, Jaspan T : Review article : computed tomography and magnetic resonance in the diagnosis of intraventricular cerebral masses. *Br J Radiol* 67 : 223-243, 1994
6. Peh WC, Fan YW : Case report : intraventricular meningioma with cerebellopontine angle and drop metastases. *Br J Radiol* 68 : 428-430, 1995
7. Perry A, Louis DN, Scheithauer BW, Budka H, Deimling von A : Meningiomas. In Louis DN, Ohgaki H, Wiestler OD, Cavenee WK (eds) : **WHO Classification of Tumours of the Central Nervous System**. International Agency for Research on Cancer (IARC) : Lyon, 2007, pp164-172
8. Shintaku M, Hashimoto K, Okamoto S : Intraventricular meningioma with anaplastic transformation and metastasis via the cerebrospinal fluid. *Neuropathology* 27 : 448-452, 2007