

## Clinical Article

# Analysis of Results Using Percutaneous Vertebroplasty for the Treatment of Avascular Necrosis of the Vertebral Body

Han Woong Kim, M.D., Austin Kwon, M.D., Min Cheol Lee, M.D., Jae Wook Song, M.D., Sang Kyu Kim, M.D., In Hwan Kim, M.D.

Department of Neurosurgery, Gwangju Saewoori Spine Hospital, Gwangju, Korea

**Objective :** Avascular necrosis (AVN) of the vertebral body is known as a relatively uncommon phenomenon in a vertebral compression fracture (VCF). The outstanding radiologic findings of AVN are intravertebral vacuum phenomenon with or without fluid collection. Several reports revealed that PVP or balloon kyphoplasty might be the effective treatment modalities for AVN. We also experienced excellent results when using PVP for the treatment of AVN of the vertebral body, and intend to describe the treatment's efficacy in this report.

**Methods :** Thirty-two patients diagnosed with AVN of the vertebral body were treated with PVP. We measured the pre- and post-operative anterior body height and kyphotic angulation. The visual analogue scale (VAS) was used to determine the relief of back pain.

**Results :** The anterior body height (pre-operative : 1.49 cm, post-operative : 2.22 cm) and kyphotic angulation (pre-operative : 14.47 degrees, post-operative : 6.57 degrees) were significantly restored ( $p < 0.001$ ). VAS was improved from 8.9 to 3.7. Pseudoarthrosis was corrected in all cases, which was confirmed by dynamic radiographs. Fluid collection was found in sixteen cases and was aspirated with serous nature. No organism and tumor cell were noted.

**Conclusion :** PVP proved to be an effective procedure for the treatment of AVN of the vertebral body, which corrected dynamic instability and significantly restored the anterior body height and kyphotic angulation.

**KEY WORDS :** Avascular necrosis of the vertebral body · Vertebral compression fracture · Percutaneous vertebroplasty.

## INTRODUCTION

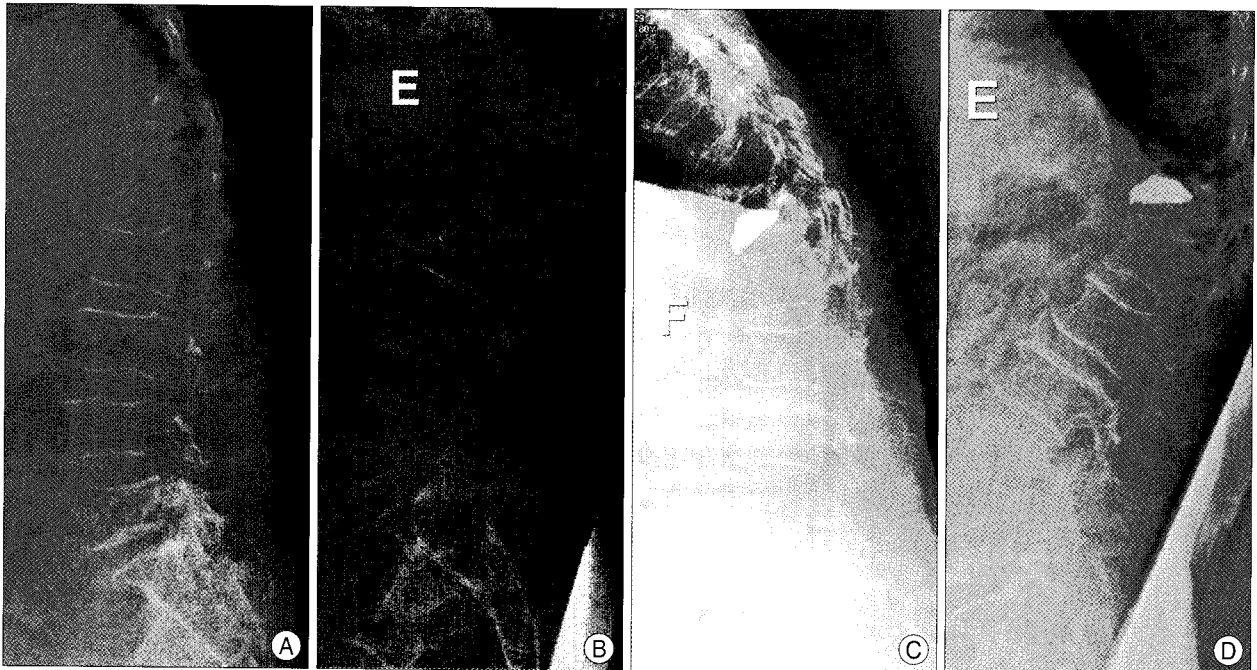
Avascular necrosis (AVN) of the vertebral body is known as a relatively uncommon phenomenon in a vertebral compression fracture, which is reported by using various terms such as "intravertebral vacuum cleft, intravertebral pseudoarthrosis, vertebral osteonecrosis, vertebral fluid collection associated with vertebral collapse, delayed post-traumatic vertebral collapse, and Kümmell's disease"<sup>1,3,5,6</sup>. Known factors related to this phenomenon include malignancy, alcohol abuse, infection, radiation therapy, steroid treatment, etc. Outstanding radiologic findings of AVN consist of intravertebral vacuum phenomenon with or

without fluid collection, and pseudoarthrosis, which are seen in the dynamic radiographs and collapsed bodies<sup>1,6</sup>. Several reports revealed percutaneous vertebroplasty (PVP) or balloon kyphoplasty may be the effective treatment modalities for AVN<sup>2,3</sup>. We also experienced excellent results when using PVP for the treatment of AVN of the vertebral body and intend to further describe the efficacy of this treatment.

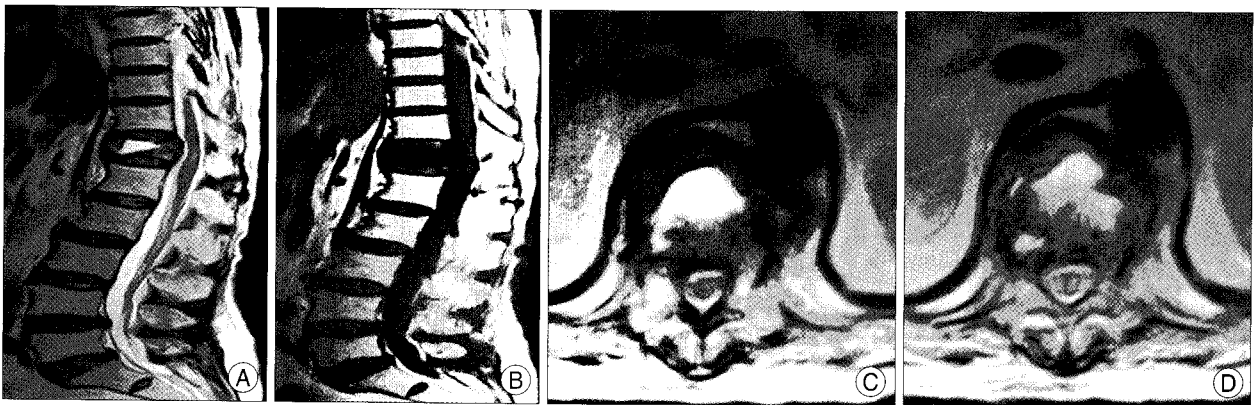
## MATERIALS AND METHODS

We investigated 32 cases of AVN of the vertebral body that were treated with PVP from December 2006 to March 2008 (male : female=8 : 24, mean age=75 years, range 63-86 years). During the same period, 584 cases of PVP were evaluated. Mean bone mineral density was -4.85. Of all the investigated patients, fourteen patients had hypertension, two diabetes, three heart problems, while three patients had histories of hepatic cellular carcinoma, liver cirrhosis,


• Received : December 11, 2008 • Accepted : April 3, 2009  
• Address for reprints : Han Woong Kim, M.D.  
Department of Neurosurgery, Gwangju Saewoori Spine Hospital,  
180-28 Hwajeong-dong, Seo-gu, Gwangju 502-240, Korea  
Tel : +82-62-603-8000, Fax : +82-62-364-7500  
E-mail : rhohw@hanmail.net



**Fig. 1.** A and B : The lateral radiographs in flexion and extension, showing the dynamic instability and fluid collection in T12 body. C and D : The postoperative radiographs showing filling of the cement without dynamic instability.



**Fig. 2.** The sagittal (A and B) and axial (C and D) images of magnetic resonance image showing the fluid collection of T12 body.



**Fig. 3.** Serous natured fluid collection which is aspirated with syringe during percutaneous vertebroplasty.

cerebrovascular attack, respectively. Five patients underwent a retrieval of PVP on the same level due to persistent pain after the initial PVP. All patients had osteoporosis, but none of them were being treated with steroid or radiation therapy. Almost all patients had a minor history of trauma, such as slipping down. Three patients of these patients showed trauma related to traffic accidents.

All patients underwent simple dynamic radiographs, CT, and MRI. By conducting simple radiographs or CT, we were able to confirm intravertebral vacuum phenomena. The treatment of some patients was combined with fluid collection, which was confirmed by MRI. Sixteen patients showed high signal intensity on T2 weighted image on sagittal MRI, which was suggestive of fluid collection. In some cases, we were able to aspirate the fluid during the

procedure, but no tumor cells, cultures including the Gram's stain, acid-fast stain, and bacterial culturing were noted. (Fig. 1, 2, 3)

PVP was done by unilateral or bilateral transpedicular approach which was determined based on the symptoms and MRI findings, by using fluoroscopic guidance under local anesthesia. PMMA cement (DePuy International Ltd, England) was mixed with barium sulfate powder, which was allowed to polymerize to a toothpaste-like density. The PMMA was loaded into several 1 cc syringes and then injected carefully while monitoring the procedure with a C-arm fluoroscope to check for PMMA leaks into the neural canal or venous channel. The majority of this procedure was performed at the thoracolumbar junction, and the levels treated ranged from T11 to L4 (T11 : 1, T12 : 15, L1 : 12, L2 : 2, L3 : 1, L4 : 1).

Dynamic instability was noted by changes of the anterior body height on flexion and extension radiographs. We checked and compared the preoperative and immediate postoperative anterior body height and kyphotic angle to show the correction of instability and kyphotic deformity exhibited by the patients. The values were statistically compared using the paired T-test. The degree of pain was assessed before and after of PVP with the visual analogue scale (VAS).

## RESULTS

The anterior vertebral body height (pre-operative : 1.49 cm, post-operative : 2.22 cm) and kyphotic angulation (pre-operative : 14.47 degrees, post-operative : 6.57 degrees) were restored significantly ( $p < 0.001$ ). VAS was improved from 8.9 to 3.7 with substantial relief of back pain. Pseudoarthrosis was corrected in all cases, which was confirmed by dynamic radiographs. The mean amount of bone cement injected was 7 mL (range 3-9 mL). Three patients showed the discal cement leakages, while one patient showed the venous leakage. However, no clinical symptoms were noted. All patients tolerated the procedure well without other complications.

The mean hospitalized period was 2.3 days (range 0-11 days). All patients were administered osteoporotic drugs, which included riserdrionate, vitamin D derivative and calcium. On follow up, 19 patients didn't require any pain medications except for drugs of osteoporosis. However, thirteen patients needed NSAIDs and nerve block procedures such as facet or caudal blocks for remnant pain. Three of them were identified for subsequent VCFs on follow up, and underwent PVP at that level; one case was on the adjacent level, others non-adjacent level. No case was related to infections or tumors.

## DISCUSSION

AVN of the vertebral body is known as an uncommon phenomenon of VCF, which is reported by using various terms such as "avascular necrosis of the vertebral body, intravertebral vacuum cleft, intravertebral pseudoarthrosis, vertebral osteonecrosis, vertebral fluid collection associated with vertebral collapse, delayed post-traumatic vertebral collapse, and Kummell's disease<sup>1,5</sup>).

Maldague et al.<sup>6</sup> first described an intravertebral vacuum cleft phenomenon as the accumulation of gas within a vertebral body, which was defined as a pathognomonic sign of AVN<sup>1,3,5</sup>. Others explained this phenomenon as an ischemia of the vertebral body<sup>6</sup>. Pierre suggested the possibility of migration of intervertebral discal air into the adjacent body via a fractured end-plate. However, in our study, adjacent intervertebral discal air was not noted<sup>4</sup>.

The cause of this disease is not yet clarified, but several clinical conditions are related to this phenomenon, such as malignancy, infection, radiation therapy, systemic steroid treatment, and trauma; in rare cases, vasculitis, pancreatitis and liver cirrhosis can be seen<sup>1,3,5,6</sup>. In our cases, there was no past or present history of any condition mentioned above except trauma.

Several reports demonstrated that PVP or balloon kyphoplasty can be more effective and less invasive than fusion for the treatment of AVN of the vertebral body<sup>2,3</sup>. Because most of our patients were old and had severe osteoporosis, open fusion surgery was inappropriate. Jang et al. reported satisfactory results on AVN of the vertebral body by using PVP. Results indicated a reduction in kyphotic angle, increased body height and higher stability<sup>3</sup>. Grohs et al.<sup>2</sup> introduced balloon kyphoplasty as a good treatment modality for AVN of the vertebral body. After the procedure, postoperative X-ray revealed that body height was restored; stability and central filling by bone cement improved the patient's conditions and eased their symptoms. Nowadays, many PVPs and balloon kyphoplastys are widely carried out for VCFs because the procedure is relatively safer and more effective, compared to fusion surgery. PVP also provided stability and pain relief for the treatment of AVN of the vertebral body<sup>7,8</sup>. In our study, the anterior body height and kyphosis were corrected significantly through this procedure. Therefore, PVP proves to be an effective procedure for the treatment of spinal instability and kyphosis caused by AVN of the vertebral body.

## CONCLUSION

PVP could be an effective procedure for the treatment of

AVN of the vertebral body, and it provides restoration of the anterior body height and kyphotic angulation.

### References

1. Chou LH, Knight RQ : Idiopathic avascular necrosis of a vertebral body : case report and literature review. *Spine* 22 : 1928-1932, 1997
2. Grohs JG, Matzner M, Trieb K, Krepler P : Treatment of intravertebral pseudoarthrosis by balloon kyphoplasty. *J Spinal Disord Tech* 19 : 560-565, 2006
3. Jang JS, Kim DY, Lee SH : Efficacy of percutaneous vertebroplasty in the treatment of intravertebral pseudoarthrosis associated with noninfected avascular necrosis of the vertebral body. *Spine* 28 : 1588-1592, 2003
4. Lafforgue P, Chagnaud C, Daumen-Legré V, Daver L, Kasbarian M, Acquaviva PC : The intravertebral vacuum phenomenon ("vertebral osteonecrosis"). Migration of intradiscal gas in a fractured vertebral body? *Spine* 22 : 1885-1891, 1997
5. Maheshwari PR, Nagar AM, Prasad SS, Shah JR, Patkar DP : Avascular necrosis of spine. *Spine* 29 : E119-E122, 2004
6. Maldague BE, Noel HM, Malghem J : The intravertebral vacuum cleft : a sign of ischemic vertebral collapse. *Radiology* 129 : 23-29, 1978
7. Noh CH, Yi JS, Lee HJ, Yang JH, Lee IW, Kim MC : Effect of percutaneous vertebroplasty with polymethylmethacrylate to osteoporotic spinal compression fractures and bursting fractures. *J Korean Neurosurg Soc* 35 : 365-371, 2004
8. Polikeit A, Nolte LP, Ferguson SJ : The effect of cement augmentation on the load transfer in an osteoporotic functional spinal unit. *Spine* 28 : 991-996, 2003