

Case Report

Sacral Perineural Cyst Accompanying Disc Herniation

Chang Il Ju, M.D.,¹ Ho Shin, M.D.,¹ Seok Won Kim, M.D.,¹ Hyeun Sung Kim, M.D.²

Department of Neurosurgery,¹ School of Medicine, Chosun University, Gwangju, Korea

Department of Neurosurgery,² Mokpo Han Kook Hospital, Mokpo, Korea

Although most of sacral perineural cysts are asymptomatic, some may produce symptoms. Specific radicular pain may be due to distortion, compression, or stretching of nerve root by a space occupying cyst. We report a rare case of S1 radiculopathy caused by sacral perineural cyst accompanying disc herniation. The patient underwent a microscopic discectomy at L5-S1 level. However, the patient's symptoms did not improve. The hypesthesia persisted, as did the right leg pain. Cyst-subarachnoid shunt was set to decompress nerve root and to equalize the cerebrospinal fluid pressure between the cephalad thecal sac and cyst. Immediately after surgery, the patient had no leg pain. After 6 months, the patient still remained free of leg pain.

KEY WORDS : Sacral perineural cyst · Disc herniation.

INTRODUCTION

Sacral perineural cysts, also called Tarlov cysts, were first described by Tarlov in 1938 as an incidental finding at autopsy and were later classified as Type II meningeal cysts by Nabors et al.^{12,16} They are lesions of the nerve root on the extradural components in the sacral region. The cysts arise at the junction of the dorsal ganglion and the posterior nerve root and develop between the endoneurium and perineurium. Most of the cysts are asymptomatic and are found incidentally during computed tomographic (CT) or magnetic resonance imaging (MRI) examination for other reasons. Approximately below 1% of sacral perineural cysts become large and cause symptoms related to local compression⁶. We report a rare case of radiculopathy caused by sacral perineural cyst accompanying disc herniation.

CASE REPORT

A 31-year-old woman presented with a 3 year history of low back pain and right lower extremity pain. Walking,

standing, sitting, coughing, and sneezing worsened the symptoms, whereas the recumbent position relieved the symptoms. Neurologic examination revealed hypesthesia on the right leg from the buttock to sole of the foot. The straight leg raising test was positive (60°/free). MRI indicated marked disc herniation at L5-S1 level and space-occupying lesion in the sacrum at S1-S3 (Fig. 1A, B). Myelography showed large filling defect at L5-S1 disc level and filling of the cyst on the right side that was clearly seen 7 minutes after intrathecal injection of omnipaque (Fig. 1C). After neuroradiologic investigation, it was determined that the space occupying lesion was an asymptomatic sacral perineural cyst and the symptoms were rather caused by disc herniation. Therefore, the patient underwent a microscopic discectomy at L5-S1 level. During surgery, sacral perineural cyst left untreated. However, the patient's symptoms were not improved. The hypesthesia persisted, as did the right leg pain. The pain was severe while sitting, whereas, in the recumbent position, the patient was comfortable. Bilateral L5-S1 interlaminar spaces were fenestrated by excising the yellow ligament. The L5 lamina connecting the L4-L5 supraspinous and interspinous ligaments was reflected cephalad, and the S1 lamina was removed more caudally. The cephalad thecal sac and sacral cyst were exposed. The thecal sac was opened at L5 and the cyst wall at S1 with minimal incision. After drainage of cystic fluid, a cyst-

• Received : March 31, 2008 • Accepted : February 22, 2009
• Address for reprints : Seok Won Kim, M.D.
Department of Neurosurgery, School of Medicine, Chosun University,
588 Seoseok-dong, Dong-gu, Gwangju 501-717, Korea
Tel : +82-62-220-3120, +82-62-220-3126, Fax : +82-62-227-4575
E-mail : chosunns@hanmail.net

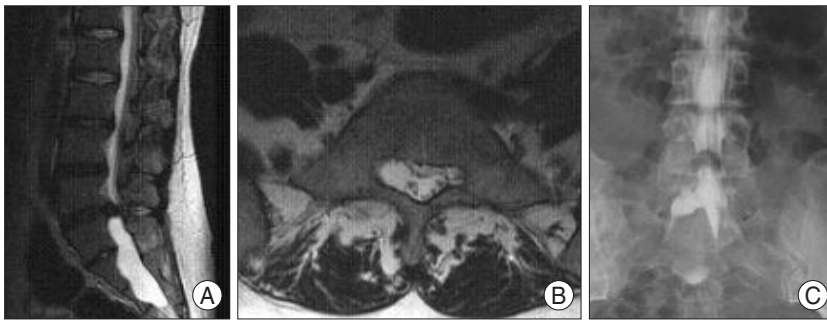


Fig. 1. A : Preoperative T2 weighted sagittal magnetic resonance imaging (MRI) indicates the disc herniation at L5-S1 level and space-occupying lesion in the sacrum. B : T2 weighted axial MRI shows cystic lesion compressing the right S1 root. C : Lumbosacral myelogram reveals marked filling defect at L5-S1 level and filling of the cyst with contrast material.

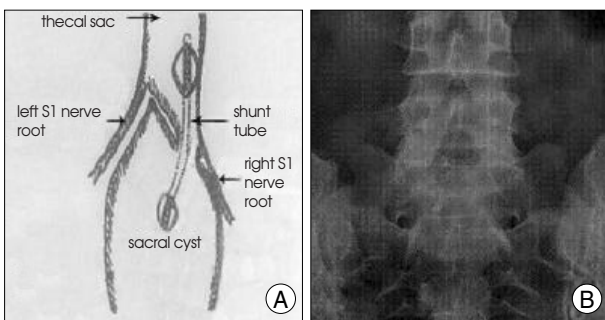


Fig. 2. Illustration of the operative procedure (A) and postoperative simple radiograph (B). A cyst-subarachnoid space shunt tube was inserted to equalize the cerebrospinal fluid pressure between the cephalad thecal sac and the sacral cyst.

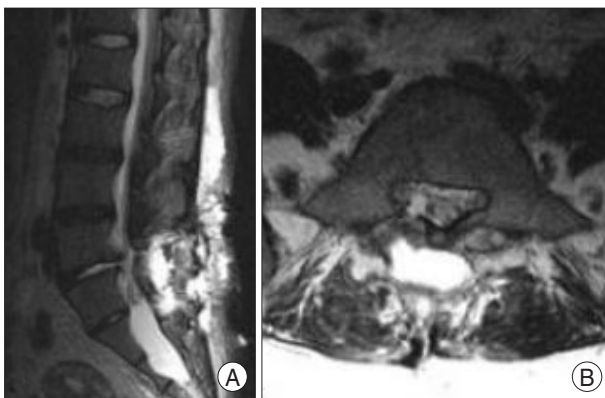


Fig. 3. T2 weighted sagittal (A) and axial (B) magnetic resonance images taken 3 months after surgery show decrease in size of the cyst and decompressed right S1 root.

subarachnoid shunt tube (ventricular catheter 14 cm Codman® USA) was inserted to equalize the cerebrospinal fluid (CSF) pressure between the cephalad thecal sac and the cyst. The shunt tube was fixed to the inner aspect of the cyst wall by an 8-0 nylon suture (Fig. 2). Immediately after the operation, the patient had no pain in his right leg and hypesthesia decreased in severity. An MRI 3 months after the surgery showed a radiologically detectable decrease in the size of the cyst (Fig. 3). Six months after surgery, she remained free of right leg pain.

DISCUSSION

Perineural cysts occur most frequently at the sacral level. Sacral perineural cyst, so-called Tarlov cyst, was first described by Tarlov in 1938¹⁶. Sacral perineural cysts usually occur on the extradural components of sacrococcygeal nerve roots at the junction of dorsal root ganglion and posterior nerve roots and arise between the endoneurium and perineurium. Sacral perineural cysts seldom become symptomatic^{1,5,6}. Irrespective of the exact causes of the sacral cyst, the hydrostatic and pulsatile forces of CSF are considered to be responsible for the growth of the cysts and their symptoms^{1,2}. It has been postulated that pressure on the adjacent sensitive tissue, such as the periosteum and the joint capsule, may cause local pain. Specific radicular pain may be the result of distortion, compression, or stretching of the nerve root by the space-occupying character of cyst⁴. When the cysts are large enough to compress the ventral root, motor deficits may occur. Symptoms of sacral perineural cysts include local low back pain, sacral nerve root pain (sciatic pain), leg numbness, leg weakness, neurogenic claudication, and bladder dysfunction^{5,13}. Symptoms can be exacerbated by changes of the posture, coughing, valsalva maneuvers, standing, lifting, and climbing stairs, all of which tend to increase the CSF pressure. The symptoms can be relieved by recumbence. These phenomenon can be explained by the ball-valve mechanism. Because of the rarity and unclear pathogenesis and pathophysiology of these cysts, there has been no definite consensus on the optimal treatment of symptomatic sacral perineural cysts. Surgical options include only simple decompressive laminectomy, both cyst and nerve root resection, incision and drainage of the cyst with imbrication of the redundant nerve root sheath, lumboperitoneal CSF shunting, and closure of the communication of the cyst with the dural sac^{6-9,12,14}. However, simple decompression alone has proven not to be successful and cyst and nerve root resection may result in a neurological aggravation, and it is difficult to obtain watertight closure of the nerve root sleeve⁸⁻¹⁰. In 2001, Morio et al.¹¹ reported favorable result of the surgical placement of a cyst-subarachnoid shunt to equalize pressure within the spinal subarachnoid space and the cystic cavity. Assuming there is a slit-like aperture functioning as a check-valve, pressure waves would enhance the enlargement of the cyst. Surgical strategies that include decreasing the CSF pressure of the cephalad thecal sac using a lumboperitoneal shunt¹⁵, closing the cyst-subarachnoid communication³ and equalizing the CSF pressure between the

cephalad thecal sac and the cyst are considered to be appropriate. We performed cyst-subarachnoid shunt and obtained satisfactory result. The cyst-subarachnoid shunt may be a valuable alternative. During the follow-up, no complications were encountered, such as a shunt malfunction, infection, or CSF leakage. However, careful long term follow-up will be necessary.

CONCLUSION

Sacral perineural cyst may be a rare cause, but should be considered in the differential diagnosis of radiculopathy especially in case of accompanying lumbar disc herniation. Careful history taking is essential to choose appropriate treatment.

• Acknowledgements

This study supported by research funds from Chosun University 2008.

References

1. Acosta FL Jr, Quinones-Hinojosa A, Schmidt MH, Weinstein PR : Diagnosis and management of sacral Tarlov cysts. Case report and review of the literature. *Neurosurg Focus* 15 : E15, 2003
2. ArunKumar MJ, Selvapandian S, Chandu MJ : Sacral nerve root cysts : a review on pathophysiology. *Neurol India* 47 : 61-64, 1999
3. Gortvai P : Extradural cysts of the spinal canal. *J Neurol Neurosurg Psychiatry* 26 : 223-230, 1963
4. Goyal RN, Russell NA, Benoit BG, Belanger JM : Intraspinal cysts : a classification and literature review. *Spine* 12 : 209-213, 1987
5. Jain SK, Chopra S, Bagaria H, Mathur PP : Sacral perineural cyst presenting as chronic perineal pain : a case report. *Neurol India* 50 : 514-515, 2002
6. Kayali H, Duz b, Gonul E : Symptomatic sacral Tarlov cyst : Case report. *Jankara Medical School* 25 : 103-106, 2003
7. Kunz U, Mauer UM, Waldbaur H : Lumbosacral extradural arachnoid cysts : diagnostic and indication for surgery. *Eur Spine J* 8 : 218-222, 1999
8. Langdown AJ, Grundy JR, Birch NC : The clinical relevance of Tarlov cysts. *J Spinal Disord Tech* 18 : 29-33, 2005
9. Lee JY, Impekoven P, Stenzel W, Löhr M, Ernestus RI, Klug N : CT-guided percutaneous aspiration of Tarlov cyst as a useful diagnostic procedure prior to operative intervention. *Acta Neurochir (Wien)* 146 : 667-670, 2004
10. Lim KT, Cho BM, Shin DI, Park SH, Oh SM : Symptomatic Tarlov's Cyst (Sacral Meningeal Cyst).-Case Report-. *J Korean Neurosurg Soc* 29 : 569-573, 2000
11. Morio Y, Nanjo Y, Nagashima H, Minamizaki T, Teshima R : Sacral cyst managed with cyst-subarachnoid shunt : a technical case report. *Spine* 26 : 451-453, 2001
12. Nabors MW, Pait TG, Byrd EB, Karim NO, Davis DO, Kobrine AI, et al : Updated assessment and current classification of spinal meningeal cysts. *J Neurosurg* 68 : 366-377, 1988
13. Nishiura I, Koyama T, Handa J : Intracanalicular perineural cyst. *Surg Neurol* 23 : 265-269, 1985
14. Patel MR, Louie W, Rachlin J : Percutaneous fibrin glue therapy of meningeal cysts of the sacral spine. *AJR Am J Roentgenol* 168 : 367-370, 1997
15. Raftopoulos C, Pierard GE, Rétif C, Braude P, Brotchi J : Endoscopic cure of a giant sacral meningocele associated with Marfan's syndrome : case report. *Neurosurgery* 30 : 765-768, 1992
16. Tarlov IM : Perineural cysts of the spinal nerve roots. *AMA Arch Neurol Psychiatry* 40 : 1607-1074, 1938