

Evaluation for Protective Effect of Rutin, a Natural Flavonoid, against HCl/Ethanol-Induced Gastric Lesions

Choon Sik JEONG*

Department of Pharmacy, Duksung Women's University, Seoul 132-714, Korea

(Received March 30, 2009; Revised April 20, 2009; Accepted April 22, 2009)

Abstract – In this study we investigated the protective effects of rutin, a natural plant flavonoid, on HCl/ethanol-induced gastric lesions in rats. Rutin showed the antioxidant activities, the acid-neutralizing capacities, and the inhibitory effects on the growth of *Helicobacter pylori* (*H. pylori*), which are equivalent to control compounds. In addition, rutin significantly inhibited HCl/ethanol-induced gastric lesions. Antigastric action of rutin may be associated with the antioxidant activities, acid-neutralizing capacities, anti-*H. pylori* action, and the stimulation of mucus secretion. From these results, we could suggest that rutin may be useful for the treatment and/or protection of gastritis.

Keywords: Rutin, Anti-gastric activity, Antioxidant, Anti-*Helicobacter pylori*, HCl/ethanol-induced gastric lesion

INTRODUCTION

Rutin, also called rutoside, quercetin-3-rutinoside and sophorin, is a citrus flavonoid glycoside found in buckwheat and fruits of many plants (Kreft *et al.*, 1999), and is the glycoside between the flavonol quercetin and the disaccharide rutinose. Rutin has been reported to possess strong antioxidant activity. According to the recent report, rutin has the potent activities for Fe²⁺-induced linoleate peroxidation (Fe²⁺-ILP) and auto-oxidation of rat cerebral membranes (ARCM) (Saija *et al.*, 1995). Also, the antilipoperoxidant activity of rutin is superior to that of hesperetin, quercetin, naringenin, which have the similar chemical structural base (Saija *et al.*, 1995; Hong *et al.*, 2008). Based on potent antioxidant activity, rutin plays a role in exertion for several diseases. In humans, rutin also strengthens the capillaries, and, therefore, can reduce the symptoms of haemophilia. It also may help to prevent a common unpleasant-looking venous edema of the legs. Rutin, as ferulic acid, can reduce the cytotoxicity of oxidized LDL cholesterol and lower the risk of heart disease. In addition, the antioxidant activity of rutin is associated with its anti-inflammatory activity (Afanas'eva *et al.*, 2001) and anti-cancer activity (Kuntz *et al.*, 1999). However, little is

known of reports of anti-gastric disease of rutin.

The pathogenesis of gastric ulcer appears to be multifactorial, involving an imbalance between "aggressive" (e.g., gastric acid and pepsin) and "defensive" (e.g., prostaglandin production, mucus/mucosal barrier, bicarbonate production, blood flow, and cell regeneration) factors. In recent years, it has also been recognized that chronic infections of the gastric mucosa by *Helicobacter pylori* (*H. pylori*) plays a pivotal role in gastric carcinogenesis (International Agency for Research on Cancer, 1994). Infection of the gastric mucosa with *H. pylori* usually causes both an acute and chronic inflammation cell infiltrate, leading to an increase of reactive oxygen species (ROS), which are highly reactive compounds capable of combining with DNA in a number of potentially genotoxic ways, and are accumulated in *H. pylori* gastritis (Drake *et al.*, 1998). These processes could lead to alterations in the structure of DNA facilitating mutations and carcinogenesis. Additionally, ROS can react with lipid bilayer releasing peroxidation products, such as malondialdehyde (MDA) (Troll and Wiesner, 1985). The gastrointestinal lesions, such as gastric ulcers, and gastric cancers are strongly associated with *H. pylori* infection. Moreover, *H. pylori* infection was demonstrated to enhance gastric carcinogenesis treated with chemical carcinogens such as N-methyl-N-nitrosourea and N-methyl-N-nitrosoguanidine. One way in which it may be possible to prevent carcinogenesis would be to reduce ROS damage to

*Corresponding author

Tel: +82-2-901-8382 Fax: +82-2-901-8386
E-mail: choonsik@duksung.ac.kr.

cellular constituents, especially DNA. It was demonstrated that the eradication of *H. pylori* leads to a reduction in ROS activity in the gastric mucosa (Drake *et al.*, 1998).

The present work was carried out to investigate the possible anti-ulcerogenic effects of extract and several constituents isolated from natural plants on gastritis in rats. The aim of this study is therefore, to investigate the potential activities of rutin for anti-gastritis through antioxidant activities, anti-*H. pylori* activity, cytotoxicity for cancer cells, and inhibition of gastric lesions.

MATERIALS AND METHODS

Reagents

Rutin, dimethyl sulfoxide (DMSO), 1,1-diphenyl-2-picrylhydrazyl radical (DPPH), 3-(4,5-dimethylthiazol-2-yl)-2,5-diphenyltetrazolium bromide (MTT), cimetidine, hydrotalcite, and ampicillin were obtained from Sigma (Sigma-Aldrich Inc., MO, USA). Cell culture medium and reagents, such as RPMI-1640, fetal bovine serum (FBS), penicillin/streptomycin, and trypsin-EDTA were obtained from GIBCO (Invitrogen Inc., NY, USA). HCl, ethanol, and other solvents were purchased from Duksan Pure Chemical Co. Ltd. (Kyunggi-do, Korea). All other reagents were the pharmaceutical or analytical grade.

Antioxidants assays

Scavenging activity of samples on DPPH free radical were monitored according to the method described by Lee *et al.* (2005), and the reducing power of samples was determined according to the method of Oyaizu (1986). Inhibition of lipid peroxidation using linoleic acid was measured according to the thiocyanate method (Tomohiro *et al.*, 1994). 0.2 ml of methanolic solution containing sample was mixed with 4 ml of methanol, and a methanolic solution of DPPH (1 mM, 0.5 ml) was added. The mixture was left to stand at room temperature for 30 min, and the absorbance was read at 517 nm using UV-spectrophotometry (Agilent Technologies Inc., CA, USA). The reducing power was determined according to the method of Oyaizu. Rutin was mixed with 2.5 ml of 0.2 M phosphate buffer (pH 6.6) and 2.5 ml of 1% $K_3Fe(CN)_6$. The mixture was incubated at 50°C for 20 min. After that, 2.5 ml of 10% trichloroacetic acid was added and centrifuged at 2,090×g for 10 min. A 2.5 ml of supernatant layer was added to 2.5 ml of distilled water and 0.5 ml of 0.1% $FeCl_3$. The absorbance of the mixture was measured at 700 nm using UV-spectrophotometry. For lipid peroxidation, an aliquot of 0.4 ml of methanolic extract (5:1 v/v) was added to a solution mixture of 0.02 M linoleic acid (0.4 ml), 0.2 M phosphate buffer at pH 7 (0.8 ml), and the

distilled water (0.4 ml). The solution was homogenized and incubated at 40°C for 24 h, and the degree of oxidation was measured at 500 nm according to the thiocyanate method.

Anti-*H. pylori* activity

The inhibitory effect of rutin on the growth of *H. pylori* (ATCC 43504, Rockville, MD, USA) was investigated. Six hundred microliter of samples was mixed to 5.4 ml of brucella agar medium containing 7% horse serum in the petri dish. *H. pylori* (5×10^5 CFU) was seeded in this media and then incubated for 3 days at 37°C incubator (AnaeroPak Campylo: 85% N_2 , 10% CO_2 , 5% O_2). Viability of *H. pylori* was determined by colony counts after 3 days incubation. Ampicillin was used as a positive control.

Cytotoxicity assay for gastric cancer cell lines

SNU638 (KCLB, Seoul, Korea) and AGS (ATCC, Rockville, MD, USA) gastric cancer cells were cultured in RPMI-1640 containing 10% FBS, penicillin (100 units/ml), and streptomycin (100 μ g/ml) in a 5% CO_2 humidified incubator at 37°C. The *in vitro* cytotoxicity was determined using an MTT assay described by Pieters *et al.* (2002)

Acid-neutralizing capacity (ANC)

Rutin (1 g) was added to 100 ml of 0.1N HCl and then incubated for 1 h at 37°C with a shaking. Acid-neutralizing capacity was determined by titrating with 0.1N NaOH using methyl orange as an indicator. Hydrotalcite was used as a positive control.

Animals

Male Sprague-Dawley rats, weighing 180-200 g, were purchased from Samyook Animal Laboratories, Kyunggi-do, Korea, and were acclimatized to standard laboratory conditions ($24 \pm 2^\circ C$, $55 \pm 5\%$ humidity and 12 h light/dark cycle) for 14 days in the animal facility in Duksung Women's University. The samples dissolved in saline were administered in a volume of 0.5 ml per 100 g body weight. Saline was given to the control group. The experimental procedures for rats were conducted in accordance with the Guidelines of the Care and Use of Laboratory Animals, Duksung Women's University.

HCl/ethanol-induced mucosal membrane lesions

After 24 h fasting with free access to water prior to the experiment, rutin was administered orally to the rats. Thirty minutes after, 1 ml of HCl/ethanol solution (150 mM HCl in 60% ethanol) was administered orally. After 1 h fasting, each animal was killed by ether, and the stomach was excised, inflated by injecting 2 ml of normal saline and then

fixed for 30 min in 2% formalin solution. After opening along the greater curvature, HCl-induced gastric damage was observed in the gastric mucosa as elongated black-red lines parallel to the long axis of the stomach of the rats. The lesion index was determined as the sum of erosion length per rat. Cimetidine was used as a positive control drug.

Gastric secretion

The rats were immediately administered rutin or cimetidine intraduodenally after the pyloric ligation (Shay *et al.*, 1945). Four hours after the pyloric ligation, the animals were sacrificed, and the contents of the stomach were collected and centrifuged at $1,050\times g$ for 10 min. The total volume of gastric juice and pH were measured, and an acid output was determined by titrating the gastric juice with 0.05 N NaOH using phenolphthalein as an indicator.

Mucus secretion

Rutin in saline was administered orally to the rats. After 30 min, an absolute ethanol (1 ml/100 g) was given orally to induce the gastric lesions. One hour later, the animals were sacrificed and the secreted mucus was determined (Kitagawa *et al.*, 1986). The glandular portion separated from the excised stomach was opened along the lesser curvature and everted. The stomach was soaked in 0.1% alcian blue 8GX dissolved in 0.16 M sucrose buffered with 0.05 M CH_3COONa (adjusted to pH 5.8 with HCl) for 2 h. The mucus combined with the alcian blue was extracted with 20 ml of 70% ethanol containing 30% dioctyl sodium sulfosuccinate and centrifuged for 10 min at $500\times g$. The optical density of the supernatant was measured at 620 nm using by UV-spectrophotometer (Agilent Technologies Inc., Santa Clara, CA, USA).

Statistical analysis

All experiments were performed three times. Data were expressed as mean \pm standard error of the mean (SEM), and were analyzed using one way analysis of variance, followed by Dunnett's pairwise multiple comparison t-test with SigmaPlot software for individual comparisons. p -values less than 0.05 are considered statistically significant.

RESULTS AND DISCUSSION

Rutin had the hydrogen-donating activity to DPPH radical in concentration-dependent manner (Fig. 1), and showed a significant free radical scavenging activity with an IC_{50} of $9.62 \mu\text{g/ml}$. IC_{50} value of the reference antioxidant ascorbic acid and BHT were found experimentally to be < 0.156 and $1.758 \mu\text{g/ml}$, respectively. However, rutin showed a relative

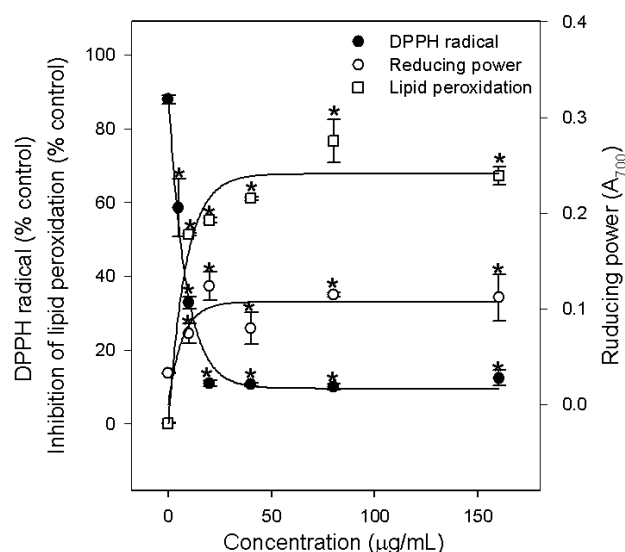


Fig. 1. Antioxidant activities of rutin. Scavenging activity of rutin on DPPH free radical were monitored according to the method described by Lee *et al.* (2005), and the reducing power of samples was determined according to the method of Oyaizu (1986). Inhibition of lipid peroxidation using linoleic acid was measured according to the thiocyanate method (Tomohiro *et al.*, 1994). ● DPPH radical ○ Reducing power □ Lipid peroxidation. Significant difference, * $p < 0.05$ compared with control.

low reducing power capacity, determined by Fe^{3+} reduction (Fig. 1), whereas pyrogallol (100 $\mu\text{g/ml}$) had a high reducing power, 1.851 ± 0.056 , as a control. In addition, rutin showed approximately 40-70% inhibition of lipid peroxidation with an IC_{50} of $9.8 \mu\text{g/ml}$. Gastric cell and tissue injury associated with acute and chronic inflammation is due to the toxicity of ROS generated in stomach (Leirisalo-Repo *et al.*, 1993). It is widely accepted that lipid peroxidation and free radicals were the pathogen of gastric lesions in rats. In addition, the involvement of oxygen derived free radicals are well established in the pathogenesis of ischemic injury of gastrointestinal mucosa and in other models of mucosal damage induced by non-steroidal anti-inflammatory drugs, ethanol, and *H. pylori* (Drake *et al.*, 1998). Also, the gastric cancer risk is reduced by ascorbic acid (AA) intake in a dose-dependent way, and in *H. pylori*-infected patients, the ascorbic acid levels are lower than in the normal population. Decreases of AA and the increases of the oxidized form of AA, dehydroascorbic acid (DHAA), were detected in the acute and chronic inflammation, peptic ulcer, gastritis, and *H. pylori* infection in stomach. Low reducing capacity of rutin implies the rescue of AA from DHAA at low level *in vivo*. In addition, the cellular tissue damage by free radicals involves lipid peroxidation, which destroys cell membranes with the

release of intracellular components, such as lysosomal enzymes, leading to further tissue damage. The radicals also promote mucosal damage caused by degradation of the epithelial basement membrane components, complete alteration of the cell metabolism and DNA damage. The levels of malondialdehyde (MDA), a final product of lipid peroxidation by oxidants, are thought to reflect free radical mediated cell membrane damage in patients with peptic ulcer and gastritis. From this report, we may speculate that rutin, a natural flavonoid, had inhibitory effect on lipid peroxidation and protective effects against radical scavengers.

Rutin was used to run *in vitro* experiments on *H. pylori* survival (Table I). Rutin completely inhibited the colonization of *H. pylori* at the dose of 50 μM , and this effect was equivalent in that of ampicillin (10 $\mu\text{g/ml}$). *H. pylori* is believed to be a major cause of peptic ulcer and gastric cancer as well as bacterial gastrointestinal infections. Antibiotic therapy has been widely used to eradicate these infections. However, the drug resistant bacteria need the new sources of drugs, and so plants seem to be the ideal sources of new antibacterial compounds. Indeed, the medicinal plants and their chemical components have been reported to have a potential benefit in eradicating such problems (Nostro *et al.*, 2005). Phenolic flavonoids from wine and many natural plants have the high anti-*H. pylori* activity (Bae *et al.*, 1999). So far, there is a paucity of report on the suppressive activity of rutin for colonization of *H. pylori*. It is worthy of notice that rutin killed the *H. pylori* cells *in vitro*. The concentration of the antibiotics ampicillin required to kill the bacteria is lower, but anti-*H. pylori* activity of rutin should be considered to be effective in use, because rutin is a food and not a medicine. *H. pylori* infection increases the free radical production, and a delicate balance between the generation of free radicals and endogenous as well as exogenous antioxidants like superoxide dismutase (SOD) and ascorbic acid is the critical important for physiological functions of the cells. When produced excessively or during deficient antioxidant defenses, free radicals can initiate lipid peroxidation and DNA dam-

age, which leads to the cellular destruction, chromosomal aberration, and finally cancer.

Gastric cancer is a leading cause of cancer-related deaths, worldwide being second only to lung cancer as a cause of death (Neugut *et al.*, 1996). For the prevention of gastric cancer disease, it is very important to develop the natural herbal medicine to act to the cancer cells directly. Herbal medicines as substitutes for cancer remedies have attracted a great deal of interest, because of their low toxicity and costs. However, rutin had a mild cytotoxic action on human gastric cancer cells (data not shown).

Rutin inhibited approximately 10.6% of NaOH consumption, compared to the control (Table II). ANC of rutin was found to be relatively low, whereas hydrotalcite showed approximately 91.7% of ANC as a positive control. Antacids are effective in accelerating healing of duodenal and gastric ulcers. The ulcer healing action of antacids was thought to be due to the neutralization of gastric luminal acid (Tarnawski *et al.*, 1995). In present study, the ANC of rutin implies the slight increase of pH in gastric content *in vitro*, and its potential gastroprotective effect. Additionally, this function is involved in the healing of ulcer, and accelerating healing of duodenal and gastric ulcers. Although rutin had less acid neutralizing capacity than hydrotalcite, it is expected it might be helped for the gastroprotective effect as nutraceuticals.

As shown in Table III, the intragastric administration of HCl/ethanol (60% in 150 mM HCl) caused multiple band-like lesions (87.0 ± 13.51 mm of the lesion index) in the gastric mucosa, whereas the normal mice were not observed any gastric lesions (data not shown). The severity of these lesions was dose-dependently reduced by p.o. administration of rutin (50 and 100 mg/kg). Rutin (100 mg/kg) inhibited approximately 67.5% of HCl/ethanol-induced gastric lesions, and was superior to cimetidine (100 mg/kg), a positive control (approximately 47.5% inhibition). The HCl/ethanol-induced gastric lesions appear to be produced by the direct irritation of a gastric mucosal barrier (Seiki *et al.*, 1990). Ethanol induced both long ulcers and petechial lesions within a relatively short time, which makes this technique suit-

Table I. Effects of rutin on the colonization of *H. pylori*

Materials	Dose ($\mu\text{g/ml}$)	Colonization
Control	—	+ + + ^a
Rutin	10	+ + ^b
	50	— ^c
	100	—
Ampicillin	1	+ +
	10	—

^a + + +: colonies (4.5×10^5 CFU), ^b + +: colonies (2.4×10^5 CFU), ^c —: none.

Table II. Effects of rutin on the acid-neutralizing capacity

Materials	Dose (g/ml)	NaOH consumption volume (μl)	Inhibition (%)
Control	1	120.0 ± 1.00	—
Rutin	1	$107.3 \pm 2.50^*$	10.6
Hydrotalcite	1	$10.0 \pm 0.77^{**}$	91.7

Significant difference, * $p < 0.05$ compared with control, ** $p < 0.001$ compared with control.

Table III. Effects of rutin on HCl/ethanol-induced gastric lesions

Materials	Dose (mg/kg)	Lesion index (mm)	Inhibition (%)
Control		87.0 ± 13.51	—
Rutin	50	69.3 ± 7.50*	20.3
	100	28.3 ± 8.78***	67.5
Cimetidine	100	45.7 ± 0.30**	47.5

Each value represents the mean ± S.E.M. of mice (n=6). Significant difference, * $p < 0.05$ compared with control, ** $p < 0.01$ compared with control, *** $p < 0.001$ compared with control.

able for screening the anti-ulcer drugs. The oral administration of rutin diminished HCl-induced gastric lesions in rats. This may be related to an antacid effects or cytoprotective properties in gastric mucus. The cytoprotective action against ethanol-induced lesions might be caused by both a simple acid neutralizing activity and a cytoprotective effects against the gastric mucosa in ethanol-induced gastric lesion in rats. The mechanism of ethanol-induced gastric lesions includes the depletion of gastric mucus content, damaged mucosal blood flow, and mucosal cell injury. In addition, the ethanol-induced gastric mucosal damage is associated with overproduction of free radicals, which lead to an increased lipid peroxidation (Kahraman *et al.*, 2003). This suppressive effect of rutin is suggested to be due to the activation of cellular protection, the reduction of mucosal prostaglandins metabolism-cytoprotective action, and the reduction of gastric vascular permeability (Sertié *et al.*, 2000).

We measured the gastric-juice parameters, such as gastric volume and pH, after submitting the rats to pylorus ligation with or without rutin intraduodenally, as shown in Table IV. Rutin (100 mg/kg) increased slightly pH, as compared to control, but did not affect the gastric secretion and acid output. Gastric ulcer seems to be caused from over-secretion of gastric juice and imbalance of defensive, and aggressive factors involved in maintaining gastric mucosal integrity (McQuaid and Isenberg, 1992). The formation of gastric mucosal lesions by necrotizing agents such as HCl and ethanol has been known to be associated with the depression of gastric defensive mechanisms (Kinoshita *et al.*, 1995). Therefore, the regulators such as proton pump inhibitors for the acid production accelerate the healing of gastric ulcers and gastritis by potent and long-lasting anti-secretory actions (Welage, 2003), and are widely used in clinic (Pisegna, 2002). However, this result suggests that the mechanism of rutin to inhibit gastric ulcer and gastritis may not be involved in the suppression of aggressive factors such as the inhibition of gastric acid secretion.

Table IV. Effects of rutin on gastric secretion in pylorus- ligated rats

Materials	Dose (mg/kg)	Volume (ml)	pH	Total acid output (mEq/4h)
Control		4.2 ± 1.2	1.38 ± 0.8	0.38 ± 0.16
Rutin	100	4.5 ± 1.9	1.70 ± 2.2*	0.48 ± 0.15
Cimetidine	100	1.7 ± 0.5**	3.50 ± 0.8**	0.22 ± 0.13*

Each value represents the mean ± S.E.M. of mice (n=6). Significant difference, * $p < 0.05$ compared with control, ** $p < 0.01$ compared with control.

Table V. Effects of rutin on absolute ethanol-induced mucus secretion in rats

Materials	Dose (mg/kg)	Mucus content (g as alcian blue)
Control		122.80 ± 7.91
Rutin	100	192.49 ± 5.17*
Sucralfate	375	155.60 ± 8.23*

Each value represents the mean ± S.E.M. of mice (n=6). Significant difference, * $p < 0.05$ compared with control.

Effect of rutin on mucus secretion *in vivo* was examined at 100 mg/kg dose, showing the superior inhibitory activity to HCl/ethanol-induced gastric lesions. In the mucus secretion model, even though ethanol induces to reduce the amount of mucus secretion in the rats, rutin (100 mg/kg) enhanced the mucus content to 192.49 ± 5.17 µg as alcian blue (Table V), which was better than that of sucralfate, a positive control. The amount of mucus secretion by sucralfate was similar to control group. The reason might be by a protective action for stomach damage through sucralfate-coating than by the increase of mucus secretion in response to ethanol irritation. Therefore, the gastro-protective activity of rutin was expected to be caused by the stimulation of mucus secretion.

In conclusion in present study, rutin showed the potent antioxidant, anti-*H. pylori* activity, and the acid-neutralizing capacity. In addition, rutin had the protective effect against HCl/ethanol-induced gastric mucosal lesion, and this effect might be associated with the suppression of aggressive factors (i.e., inhibition of gastric acid secretion) and in turn, the augmentation of defensive factors (i.e., stimulation of mucus secretion) and antioxidative activity. Therefore, the protective effect of rutin against ethanol-induced gastric mucosal lesion was expected to be due to mechanisms including stimulation of mucus secretion and antioxidant property.

ACKNOWLEDGMENTS

This research was supported by the Duksung Women's University research grants 2008.

REFERENCES

- Afanas'eva, I. B., Ostrakhovitch, E. A., Mikhail'chik, E. V., Ibragimova, G.A. and Korkina, L.G. (2001). Enhancement of antioxidant and anti-inflammatory activities of bioflavonoid rutin by complexation with transition metals. *Biochem. Pharmacol.* **61**, 677-684.
- Bae, E. A., Han, M. J. and Kim, D. H. (1999). *In vitro* anti-*Helicobacter pylori* activity of some flavonoids and their metabolites. *Planta Med.* **65**, 442-443.
- Drake, I. M., Mapstone, N. P., Schorah, C. J., White, K. L., Chalmers, D. M., Dixon, M. F. and Axon, A. T. (1998). Reactive oxygen species activity and lipid peroxidation in *Helicobacter pylori* associated gastritis: relation to gastric mucosal ascorbic acid concentrations and effect of *H. pylori* eradication. *Gut* **42**, 768-771.
- International Agency for Research on Cancer (1994). Schistosomes, liver fluke s and *Helicobacter pylori*. IARC Working Group on the Evaluation of Carcinogenic Risks to Humans. *IARC Monogr Eval Carcinog Risks Hum.* **61**, 1-241.
- Hong, J. Y., Pyee, J. H., Lee, S. K., Cho, Y. J., Song, S. H. and Park, H. J. (1998). Antioxidant, antiinflammatory, and anti-proliferative activities of strawberry extracts. *Biomol. Ther.* **16**, 286-292.
- Kahraman, A., Erkasap, N., Koken, T., Serteser, M., Aktepe, F. and Erkasap, S. (2003). The antioxidative and antihistaminic properties of quercetin in ethanol-induced gastric lesions. *Toxicology* **183**, 133-142.
- Kinoshita, M., Noto, T. and Tamaki, H. (1995). Effect of a combination of ecabet sodium and cimetidine on experimentally induced gastric lesions and gastric mucosal resistance to ulcerogenic agents in rats. *Biol. Pharm. Bull.* **18**, 223-226.
- Kitagawa, H., Takeda, F. and Kohei, H. (1986). A simple method for estimation of gastric mucus and effects of antiulcerogenic agents on the decrease in mucus during water-immersion stress in rats. *Arzneimittel Forschung* **36**, 1240-1244.
- Kreft, S., Knapp, M. and Kreft, I. (1999). Extraction of rutin from buckwheat (*Fagopyrum esculentum* Moench) seeds and determination by capillary electrophoresis. *J. Agric Food Chem.* **47**, 4649-4652.
- Kuntz, S., Wenzel, U. and Daniel, H. (1999). Comparative analysis of the effects of flavonoids on proliferation, cytotoxicity, and apoptosis in human colon cancer cell lines. *Eu.r J. Nutr.* **38**, 133-142.
- Lee, E. J., Kim, K. S., Jung, H. Y., Kim, D. H. and Jang, H. D. (2005). Antioxidant activities of garlic (*Allium sativum* L.) with growing districts. *Food. Sci. Biotechnol.* **14**, 123-130.
- Leirisalo-Repo, M., Paimela, L., Koskimies, S. and Repo, H. (1993). Functions of polymorphonuclear leukocytes in early rheumatoid arthritis. *Inflammation* **17**, 427-442.
- McQuaid, K. R. and Isenberg, J. I. (1992). Medical therapy of peptic ulcer disease. *Surg Clin. North Am.* **72**, 285-316.
- Neugut, A. I., Hayek, M. and Howe, G. (1996). Epidemiology of gastric cancer. *Semin. Oncol.* **3**, 281-291.
- Nostro, A., Cellini, L., Di Bartolomeo, S., Di Campli, E., Grande, R., Cannatelli, M. A., Marzio, L. and Alonzo, V. (2005). Antibacterial effect of plant extracts against *Helicobacter pylori*. *Phytother. Res.* **19**, 198-202.
- Oyaizu, M. (1986). Studies on product of browning reaction: antioxidative activities of products of browning reaction prepared from glucosamine. *Jap. J. Nutr.* **44**, 307-315.
- Pisegna, J. R. (2002). Pharmacology of acid suppression in the hospital setting: focus on proton pump inhibition. *Crit. Care Med.* **30**, S356-S361.
- Saija, A., Scalese, M., Lanza, M., Marzullo, D., Bonina, F. and Castelli, F. (1995). Flavonoids as antioxidant agents: importance of their interaction with biomembranes. *Free Radic. Biol. Med.* **19**, 481-486.
- Seiki, M., Ukei, S., Tanaka, Y. and Soeda, M. (1990). Studies of anti-ulcer effects of a new compound, zinc L-carnosine (Z-103). *Nippon Yakurigaku Zasshi* **95**, 257-269.
- Sertié, J. A. A., Carvalho, J. C. T. and Panizza, S. (2000). Antiulcer activity of the crude extract from the leaves of *Casearia sylvestris*. *Le Pharmacien Biologiste* **38**, 112-119.
- Shay, H., Komarov, S. A., Fels, S. S. and Meranze, D. (1945). A simple method for the uniform production of gastric ulceration in the rat. *Gastroenterology* **4**, 43-61.
- Tarnawski, A., Tanoue, K., Santos, A. M. and Sarfeh, I. J. (1995). Cellular and molecular mechanisms of gastric ulcer healings. *Scand. J. Gastroenterol.* **210(Suppl)**, 9-14.
- Tomohiro, T., Futoshi, K., Naoharu, W., Akihito, Y. and Kanzo, S. (1994). A simple screening method for antioxidants and isolation of several antioxidants produced by marine bacteria from fish and shellfish. *Biosci. Biotechnol. Biochem.* **58**, 1780-1783.
- Troll, W. and Wiesner, R. (1985). The role of oxygen radicals as a possible mechanism of tumor promotion. *Annu. Rev. Pharmacol. Toxicol.* **25**, 509-528.
- Welage, L. S. (2003). Pharmacologic properties of proton pump inhibitors. *Pharmacotherapy* **23**, 74S-80S.