

A case of newly developed pulmonary lesion during the antitubercular agents in tuberculous pleurisy : A paradoxical response

Jee Min Park, M.D., Youn Ho Shin, M.D.*, Gyu Rak Chon, M.D.[†]
Hyun Joon Shin, M.D.[‡] and Young Chil Choi, M.D.[‡]

Department of Pediatrics, Ajou University School of Medicine, Suwon, Korea

Department of Pediatrics*, Pochon CHA University, College of Medicine, Seoul, Korea

Department of Internal Medicine[†], Division of Pulmonary and Critical Care Medicine

Konkuk University College of Medicine, Chungju, Chungbuk, Korea

Department of Radiology[‡], Konkuk University College of Medicine, Chungju, Chungbuk, Korea

= Abstract =

Paradoxical response refers to the enlargement of old lesions or unexpected appearance of new lesions after initial improvement following treatment with antitubercular agents. Various types of paradoxical responses have been reported in the world, but they are rarely reported in Korean children. We report the case of a 17-year-old boy who was diagnosed with tuberculous pleurisy and was treated appropriately. Although the tuberculous pleurisy initially responded to medication with resolution of the pleural fluid, a new pulmonary lesion subsequently developed 3 weeks after the initiation of treatment that eventually cleared with continuation of the original drug regimen. (**Korean J Pediatr 2009;52:717-720**)

Key Words : Paradoxical response, Tuberculous pleurisy, Antitubercular agents

Introduction

Paradoxical response refers to the enlargement of old lesions or unexpected appearance of new lesions during an adequate antitubercular agents after initial improvement¹. Various types of paradoxical responses have been reported². Paradoxical response generally occurs 3–12 weeks after the beginning of antitubercular agents that includes rapid bactericidal drugs such as isoniazid and rifampin, and it usually regresses without changing the initial choice of drug regimen^{3,4}. There are rare report in Korean children, with some cases with adults^{5,6}. In our patient, paradoxical response to antitubercular agents for tuberculous pleurisy manifested as a newly developed pulmonary lesion after resolution of the pleural effusion. The lesion subsequently decreased in size

without changing the original choice of medications and it eventually disappeared 10 months after the disease onset.

Case report

A 17-year-old male was admitted to our hospital because of fever and cough for 2 weeks. Two days earlier, the cough progressed in severity and he started having severe dyspnea. He had been otherwise healthy and the family history was unremarkable. At admission, he was acutely ill looking and severely dyspneic.

Physical examination showed a body temperature of 38.4 °C, pulse rate of 108 beats/min, respiration rate of 20 breaths/minute, and blood pressure of 120/70 mmHg. Initial laboratory data were as follows: hemoglobin 12.3 g/dL, hematocrit 36.8%, white cell count 13,200/mm³ (neutrophils 68%), platelet count 252,000/mm³. Erythrocyte sedimentation rate and C-reactive protein were 20 mm/hr and 21.5 mg/dL, respectively. Serum electrolytes and blood chemistries were within normal range. Initial chest radiography showed severe left pleural effusion (Fig. 1) and patch consolidation in left lower lung field. Thoracentesis was done and the pleural fluid exa-

Received : 20 March 2009, Revised : 7 April 2009

Accepted : 19 May 2009

Address for correspondence : Jee Min Park, M.D.

Department of Pediatrics, Ajou University School of Medicine, 5 san, Woncheon-dong, Yeongtong-gu, Suwon-si, Gyeonggi-do, 443-721, Korea

Tel : +82,31-219-5160, Fax : +82,31-219-5169

E-mail : cpr1@medigate.net

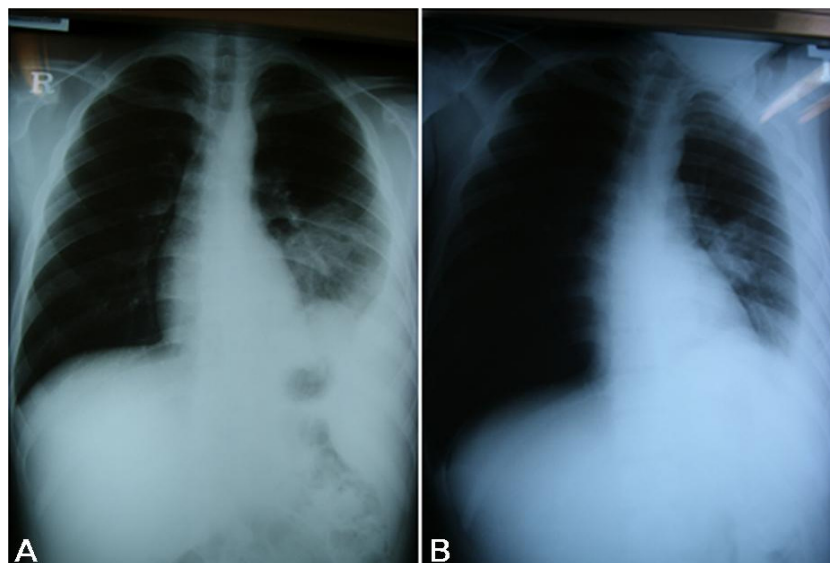


Fig. 1. (A) Chest PA shows a lateral meniscus sign and patchy consolidation on the lower left lung fields adjacent to the cardiac border. (B) Left decubitus view shows left pleural fluid shifting.

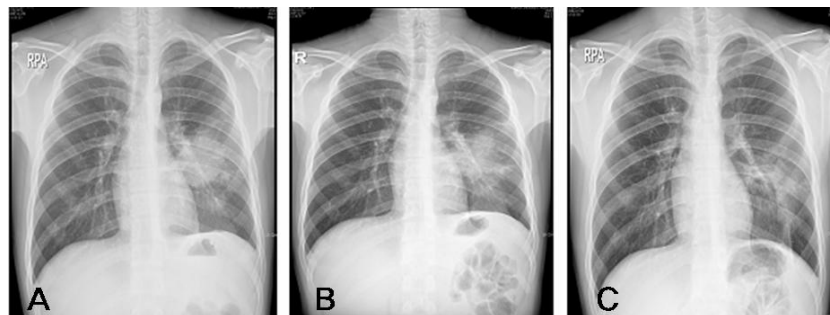


Fig. 2. (A) Chest PA shows a large, round mass-like consolidation on the lower left lung fields adjacent to the cardiac border at 2 months after initiation of antitubercular agents. (B) Chest PA shows irregular margin and saccular change of the round consolidation in the superior segment of the lower left lobe at 4 months after initiation of antitubercular agents. (C) Chest PA shows improvement of the consolidation 10 months after the disease onset.

mination showed a pH of 7.2, RBC 12,000/mm³, WBC 1,300/mm³ (neutrophil 30%, lymphocyte 70%), glucose 50 mg/dL, protein 4.0 g/dL, chloride 107 mmol/L. Pleural fluid examination for tuberculosis polymerase chain reaction (PCR) was negative, but PCR for tuberculosis on the sputum sample was positive. Sputum for acid fast bacilli culture grew 3 colonies of *Mycobacterium tuberculosis* after 2 month incubation. The acid fast bacilli were sensitive for all the drugs against tuberculosis. Purified protein derivative (PPD) skin test was strongly positive with erythematous induration of 20 mm in transverse diameter. After establishing the diagnosis of tuberculous pleurisy, we started treatment with quadruple antitubercular agents (isoniazid, rifampin, etham-

butol, pyrazinamide). The patient showed good response and normal chest x-ray finding with the treatment. However, 3 weeks after initiation of the antitubercular agents, the chest PA showed a large round mass like consolidation on left lower lung fields without any symptom. At the 2nd month of antitubercular agents, this round opacity reached its maximal size (Fig. 2A). Chest computed tomography showed alveolar consolidation of 6 cm in diameter with small nodules (Fig. 3). We performed a PCR test for *Mycobacterium avium-intracellulae* complex, but it was negative. We also performed the human immunodeficiency virus (HIV) infection, but it was negative. At the 4th month of antitubercular agents, the round mass like consolidation decreased in size

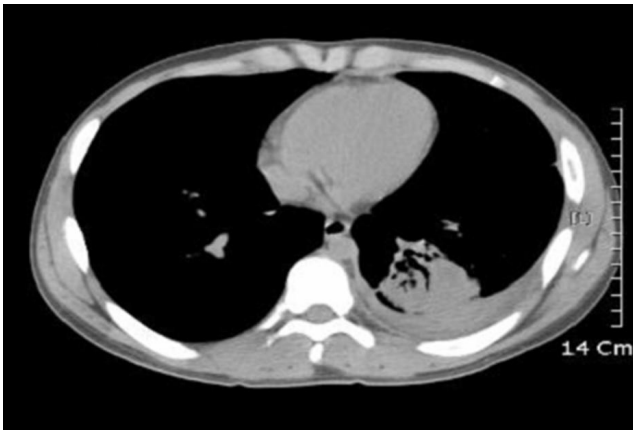

Fig. 3. Transverse contrast-enhanced chest CT scan (10-mm collimation) of the 17-year-old male patient obtained after initial detection of pleural effusion shows a 6-cm diameter of alveolar consolidation with small nodules.

and showed irregular margin with saccular changes (Fig. 2B). We concluded that this consolidation was due to a paradoxical response to antitubercular agents for pleural effusion and decided to continue the original drug regimen. The treatment was completed after 6 months from the initiation of therapy and the newly developed pulmonary lesion gradually disappeared gradually 10 months after the disease onset (Fig. 2C).

Discussion

Paradoxical response (worsening) during antitubercular agents is defined as the clinical or radiological worsening of pre-existing tuberculous lesions, or the development of new lesions, in a patient who initially improved with treatment. This phenomenon has recently gained renewed interest because of its greater frequency in HIV-infected population, but it is rare in non-HIV patients⁷. Paradoxical response generally occurs 3 to 12 weeks after the beginning of antitubercular agents including rapid bactericidal drugs such as isoniazid and rifampin and it usually regresses without a change in the initial drug regimen.

The mechanism for this unusual phenomenon remains unclear. In our patient, the paradoxical response to antitubercular agents for non-HIV-related tuberculous pleurisy was manifested as a newly developed pulmonary lesion after resolution of pleural effusion. According to Choi et al.⁸, the paradoxical response usually evolved within 3 months after the initiation of antitubercular agents, and the lesions subsequently decreased in size when the same medication was

continued, finally disappearing or leaving some residual lesions 3–18 months later. Another study by Cheng et al.⁹, defined as a clinical or radiological worsening of pre-existing tuberculous lesions or the development of new lesions not attributable to the normal course of the disease in a patient who initially improves with antitubercular agents and in whom the onset of paradoxical response is at least 2 weeks after the initiation of treatment. Patients who presented with progressive tuberculosis without initial clinical improvement, whose compliance to antitubercular agents could not be ascertained, or in whom an alternative diagnosis was made were excluded. The diagnosis of paradoxical response was made in our patient because he responded well with the antitubercular agents and the new large mass like consolidation started to show at the 3rd week of treatment. We could rule out an intrapulmonary malignancy or round atelectasis by computed tomography. Multiple drug resistance by an atypical mycobacterial infection could also rule out. Percutaneous needle aspiration and biopsy of the newly developed lesion was not performed because we thought there was a low possibility of malignancy based on the patients age and his good response to antitubercular agents.

In Korea, paradoxical response in tuberculosis, although there are a few reports in adults, but it is rarely reported in children. Song et al.⁵ reported that paradoxical responses in tuberculous pleurisy appeared in sixteen patients (21%) among the 77 patients. But among these patients, only two patients showed radiologically worsening or newly developed lesion. In our patient, he didn't have any symptom with newly developed pulmonary lesion. Song et al.⁵ also reported that paradoxical responses in patients with tuberculous pleurisy are more common in young patients because they are strong to recover the immunity. So far, in Korea, it has been rarely reported about paradoxical response with tuberculosis in children or adolescent, but there might have been so many patient with paradoxical response after tuberculous pleurisy or tuberculosis, and so it is needed more studies about it in the future.

It is speculated that the nature of this paradoxical response after tuberculous pleurisy is thought to result from rupture of a subpleural pulmonary tuberculous focus into the pleural space, which allows for tuberculo-proteins to enter the pleural space and generate the hypersensitivity reaction responsible for most of the clinical manifestations^{8,10}.

In summary, we reported a patient who developed new pulmonary lesions during medication for a tuberculous pleu-

risys that was not due to a failure of the current therapeutic regimen but rather a transient paradoxical worsening of tuberculosis that subsequently disappeared with continuation of the same medication. It is important to recognize this clinically impressive but benign paradoxical pulmonary response in order to avoid unnecessary invasive procedures or changes in the current, already appropriate therapy.

한 글 요약

**결핵흉막염 치료중에 새로이 발생한 폐병변 1예 :
역설적 반응**

아주대학교 의과대학 소아과학교실
포천중문의과대학 소아과학교실[†]
건국대학교 충주병원 내과학교실[‡]
건국대학교 충주병원 방사선과교실[‡]

박지민 · 신운호* · 전규락[†] · 신현준[‡] · 최영철[‡]

결핵 환자들에서 역설적반응이란 항결핵제 치료 중 초기에 병변의 호전 이후 방사선학적, 임상적으로 이전의 병변이 악화되거나 새로운 병변이 발생하는 경우로 정의될 수 있다. 전세계적으로 지금까지 다양한 종류의 역설적 반응이 보고되어 왔다. 그러나 국내 소아에서의 보고는 거의 드물다. 이에 저자들은 17세 남아에서 결핵성 흉막삼출로 진단되어 결핵약물에 좋은 반응을 보여 적절한 치료 후 흉수가 호전된 후에, 첫 치료 3주 후에 새로이 발생한 폐병변이 기존의 항결핵제를 계속하면서 결국에는 호전된 케이스를 경험하였기에 보고하는 바이다.

References

- 1) Smith H. Paradoxical responses during the chemotherapy of tuberculosis. *J Infect* 1987;15:1-3.
- 2) Hung SC, Chang SC. New pulmonary lesions during therapy for extrapulmonary tuberculosis. *Chest* 1999;116:1794-7.
- 3) Hiraoka K, Nagata N, Kawajiri T, Suzuki K, Kurokawa S, Kido M, et al. Paradoxical pleural response to antituberculous chemotherapy and isoniazid-induced lupus: review and report of two cases. *Respiration* 1998;65:152-5.
- 4) Al-Majed SA. Study of paradoxical response to chemotherapy in tuberculous pleural effusion. *Respir Med* 1996;90:211-4.
- 5) Song EJ, Baek DH, Jung JY, Lee SR, Lee MH, Lee SH, et al. Paradoxical response developed during the antituberculous treatment in tuberculous pleurisy. *Tuberc Respir Dis* 2008;64:427-32.
- 6) Kim SH, Chung HY, Lee GD, Shin MG, Jung TS, Jin BC, et al. Clinical characteristics of paradoxical response to chemotherapy in pulmonary tuberculosis. *Tuberc Respir Dis* 2002;53:27-35.
- 7) Breen RA, Smith CJ, Bettinson H, Dart S, Bannister B, Johnson MA, et al. Paradoxical reaction during tuberculosis treatment in patient with and without HIV co-infection. *Thorax* 2004;59:704-7.
- 8) Choi YW, Jeon SC, Seo HS, Park CK, Park SS, Hahm CK, et al. Tuberculous pleural effusion: new pulmonary lesions during treatment. *Radiology* 2002;224:493-502.
- 9) Cheng VC, Ho PL, Lee RA, Chan KS, Chan KK, Woo PC, et al. Clinical spectrum of paradoxical deterioration during antituberculosis therapy in non-HIV-infected patients. *Eur J Clin Microbiol Infect Dis* 2002;21:803-9.
- 10) Onwubalili JK, Scott GM, Smith H. Acute respiratory distress related to chemotherapy of advanced pulmonary tuberculosis: a study of two cases and review of the literature. *Q J Med* 1986;59:599-610.