

# A case of adolescent Kawasaki disease with Epstein-Barr virus-associated infectious mononucleosis complicated by splenic infarction

Byeong Sam Choi, M.D., Bo Sang Kwon, M.D., Gi Beom Kim, M.D., Yoon Kyung Jeon, M.D.\*, Jung-Eun Cheon, M.D.<sup>†</sup>, Eun Jung Bae, M.D., Chung Il Noh, M.D., Jung Yun Choi, M.D., and Yong Soo Yun, M.D.

Departments of Pediatrics, Pathology\* and Radiology<sup>†</sup>, Seoul National University Children's Hospital, Seoul National University College of Medicine, Seoul, Korea

## = Abstract =

Kawasaki disease (KD) is an acute systemic vasculitis of unknown etiology that affects children. There are few reports that describe the Epstein-Barr virus (EBV) as the possible infectious agent of KD. Here, we describe a case of KD in a 15-year-old boy complicated with giant coronary artery aneurysms, pericardial effusion, and splenic infarction. The clinical course of KD was refractory to intravenous gamma globulin and aspirin. Our patient also showed typical findings of concomitant EBV-associated infectious mononucleosis, such as hepatosplenomegaly and generalized lymphadenopathy, with EBV-positive atypical lymphoid hyperplasia. He improved dramatically after receiving intravenous methylprednisolone followed by oral prednisolone. Ultimately, the coronary artery aneurysms remained as the only sequelae. We report a rare case of adolescent KD with EBV-associated infectious mononucleosis and splenic infarction. (*Korean J Pediatr* 2009; 52:1029-1034)

**Key Words :** Mucocutaneous lymph node syndrome, Epstein-Barr virus infection, Coronary artery disease, Splenic infarction, Corticosteroids

## Introduction

Kawasaki disease (KD) is an acute systemic vasculitis, predominantly affecting children aged less than 5 years. KD is characterized by high fever, bilateral conjunctivitis, erythema of the lips and oral mucosa, edema, erythema or desquamation of the hands and feet, rash, and cervical lymphadenopathy. The etiology of KD remains unknown, although clinical and epidemiologic data suggest that it is infectious in nature. Treatment with high-dose intravenous gamma globulin (IVIG) and aspirin is standard, and in most patients, this treatment prevents the development of coronary artery aneurysms (CAAs), a major complication of

KD<sup>1)</sup>. However, approximately 20% of patients have persistent or recurrent fever despite IVIG treatment, and hence, additional therapies such as retreatment with IVIG or steroids are required<sup>2)</sup>. Adolescent-onset KD is rare<sup>3)</sup>, and reports of non-coronary vascular involvement in adolescent-onset KD are even rarer.

Here, we describe a case of refractory KD with Epstein-Barr virus (EBV)-associated infectious mononucleosis (IM) in a 15-year-old boy complicated by giant CAAs, pericardial effusion, and splenic infarction. To our knowledge, a case with this combination of complications has not yet been reported.

## Case report

A 15-year-old Korean boy was admitted to a local hospital because of fever for 8 days, skin rash, red eyes and lips, dizziness, and vomiting. Lumbar puncture was performed to rule out meningitis, and analysis of the cerebrospinal fluid revealed mild lymphocytic pleocytosis (13

Received : 14 June 2009, Revised : 27 July 2009,

Accepted : 14 August 2009

Address for correspondence : Eun Jung Bae, M.D.

Department of Pediatrics, Seoul National University Children's Hospital, Seoul National University College of Medicine, 101 Daehangno, Jongno-gu, Seoul, 110-744, Korea

Tel : +82.2-2072-3097, Fax : +82.2-743-3455

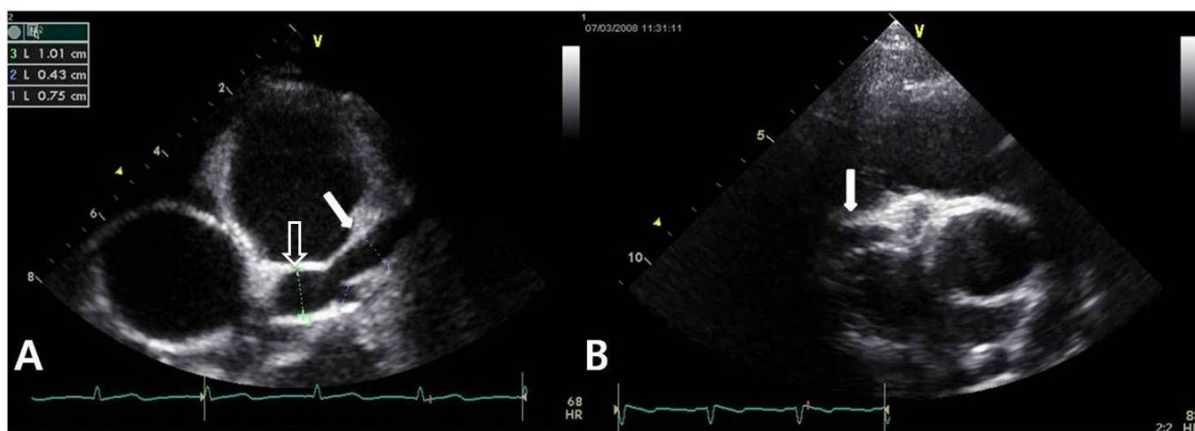
E-mail : eunjbaek@snu.ac.kr

cells/ $\mu\text{L}$ ), slightly increased protein levels (34 mg/dL), and normal glucose levels. Despite empirical antibiotic treatment with ampicillin and sulbactam, ceftriaxone, and clarithromycin, the fever persisted. On the 11th day of illness, oliguria, generalized edema, and pleural effusion developed. An echocardiogram revealed mild coronary artery dilatation. The patient then received a single dose of IVIG (1 g/kg) since KD was suspected.

On the 14th day of illness, the patient was transferred to our hospital because of persistent fever and the above-described other symptoms that persisted despite treatment with IVIG. At the time of referral, the patient complained of fever, cough, dyspnea, and left flank pain. His vital signs were as follows: blood pressure, 99/44 mmHg; pulse rate, 100 beats/min; respiration rate, 40 breaths/min; and body temperature, 39.7°C. Physical examination revealed bilateral nonexudative conjunctival injection, red cracked lips, strawberry tongue, and erythematous maculopapular skin rash on the trunk and extremities. Cervical lymph node enlargement, audible inspiratory rales on both lung fields, hepatosplenomegaly 2 fingerbreadths below the costal margin, and pretibial pitting edema were also found. The laboratory results were as follows: white blood cell count, 14,700/ $\mu\text{L}$ ; hematocrit, 31%; platelet count, 189,000/ $\mu\text{L}$ ; sodium level, 130 mEq/L; albumin level, 1.8 g/dL; blood urea nitrogen level, 18 mg/dL; creatinine level, 1.3 mg/dL; erythrocyte sedimentation rate, 51 mm/h; C-reactive protein level, 14.3 mg/dL; prothrombin time, 20.4 sec (international normalized ratio: 1.80); and activated partial thromboplastin time, 62.3 sec. An echocardiogram revealed diffuse dila-

tation of 3 main coronary arteries and the maximum diameters of the left main coronary artery and left anterior descending (LAD) coronary artery were 10.1 and 7.5 mm, respectively (Fig. 1). These findings fulfilled the diagnostic criteria for KD.

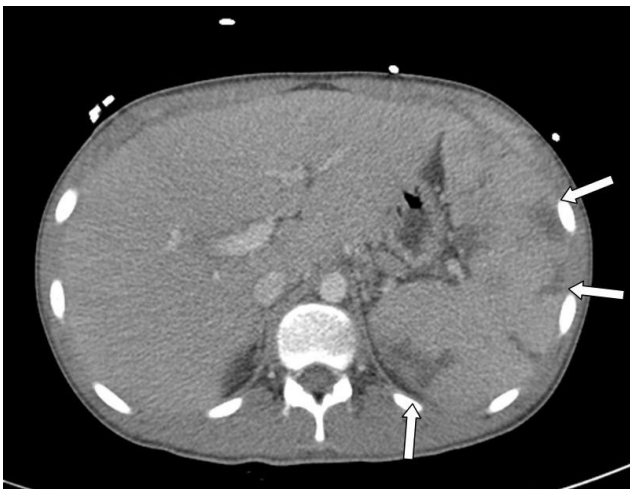The patient was treated with additional 2 doses of IVIG (2 g/kg/day for 2 days) on the 15th and 17th days of illness because of persistent fever. On the 18th day of illness, abdominal ultrasonography and computed tomography (CT) were performed to assist in diagnosing why there was left upper quadrant abdominal pain and tenderness. The scans showed a multifocal peripheral wedge-shaped splenic infarction (Fig. 2). The laboratory results from the work-up for vasculitis and thrombophilia showed significantly elevated levels of anticardiolipin IgG antibodies (42.8 GPL units; normal upper limit, 20 GPL units) and anticardiolipin IgM antibodies (108 MPL units; normal upper limit, 20 MPL units). The patient had borderline levels (16.4 IU/mL; normal upper limit, 10 IU/mL) of anti-double stranded DNA antibodies and very low titers of antinuclear antibodies (1:40). The lupus anticoagulant test, anti-neutrophil cytoplasmic antibodies, anti-RNP, and anti-Smith were all negative. There was no previous history suggesting antiphospholipid antibody syndrome or vasculitis such as systemic lupus erythematosus. So we reasoned that coronary artery dilatation and splenic infarction might be manifestations of the vasculitis of KD itself rather than other vasculitis. Remittent fever persisted even after the patient was given 3 doses of IVIG (total: 5 g/kg). The LAD coronary artery expanded progressively and reached a maximum diameter



**Fig. 1.** Echocardiogram showing diffuse dilatation of the coronary arteries. The maximum diameter of the left main coronary artery, left anterior descending coronary artery (A), and right coronary artery (B) were 10.1 mm (blank arrow), 7.5 mm (arrow), and 5 mm (arrow), respectively.

of 9.1 mm. Subsequently, lymphadenopathy extended to both the inguinal and axillary areas, and the rash became purpuric. Marked hepatosplenomegaly was also noted 4 fingerbreadths below costal margin. At this point, excisional biopsy of the inguinal lymph node (Fig. 3) and bone marrow biopsy were performed (21th day of illness). The lymph node biopsy revealed atypical lymphoid hyperplasia with marked follicular hyperplasia, some hemophagocytic histiocytes, and many EBV-positive lymphoid cells. The bone marrow was hypercellular, with approximately 90% cellularity, but it was otherwise unremarkable. Although significant atypical lymphocytosis on the peripheral smear and

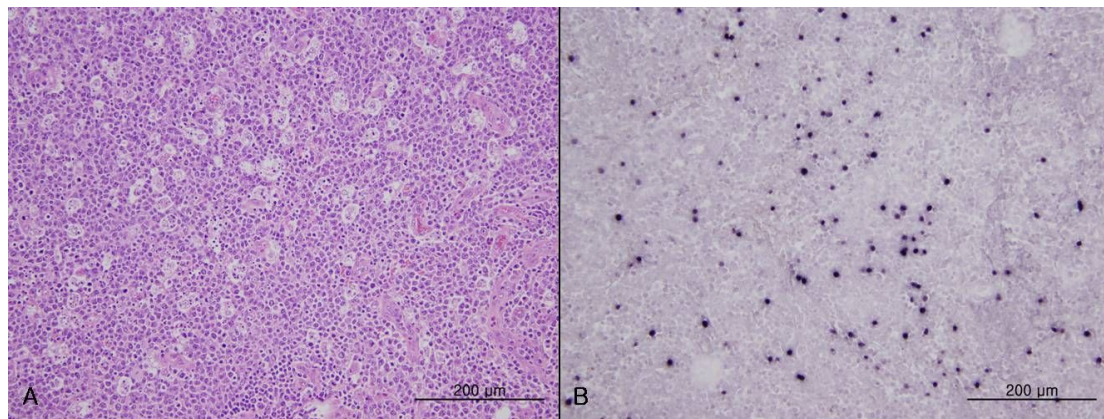
EBV viral capsid antigen IgM antibody were not present, the EBV load in the peripheral blood, as determined with real-time polymerase chain reaction (PCR) assay, was 1,170,000 copies/mL. Based on these findings, the patient was diagnosed with EBV-associated IM. Subsequently, he was treated with intravenous pulse methylprednisolone (30 mg/kg/day for 3 days). Not only did his fever begin to subside, but the skin rash and conjunctival injection also diminished dramatically the day after methylprednisolone was administered. However, 2 days later, after 3 doses of pulse methylprednisolone were given, a fever of 39.8°C returned along with cardiomegaly. An echocardiogram revealed massive pericardial effusion with impending cardiac tamponade. The patient was treated with a single infusion of 30 mg/kg of methylprednisolone and open pericardiotomy. He defervesced dramatically, and the next day, he was switched to oral prednisolone (Fig. 4A). Relatively long-term oral steroid therapy was used for 3 months because of quick relapse after intravenous pulse methylprednisolone, and the hepatosplenomegaly gradually improved during the same period. With low-dose aspirin therapy, the patient has remained well and asymptomatic over 16 months of follow-up. All abnormal laboratory findings have normalized (Fig 4B), but the giant CAAs remain unresolved (Fig. 5).



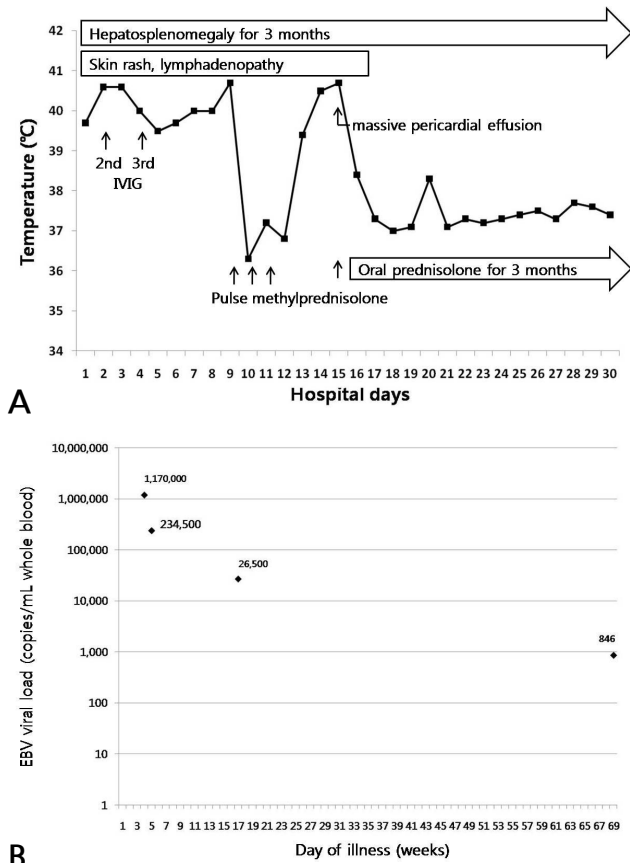
**Fig. 2.** Contrast-enhanced CT scan showing hepatosplenomegaly and multifocal inhomogeneous attenuation of the spleen (arrows) suggestive of splenic infarction.

## Discussion

According to a recent nationwide epidemiological study of KD in Korea, almost 90% of KD cases are of children aged

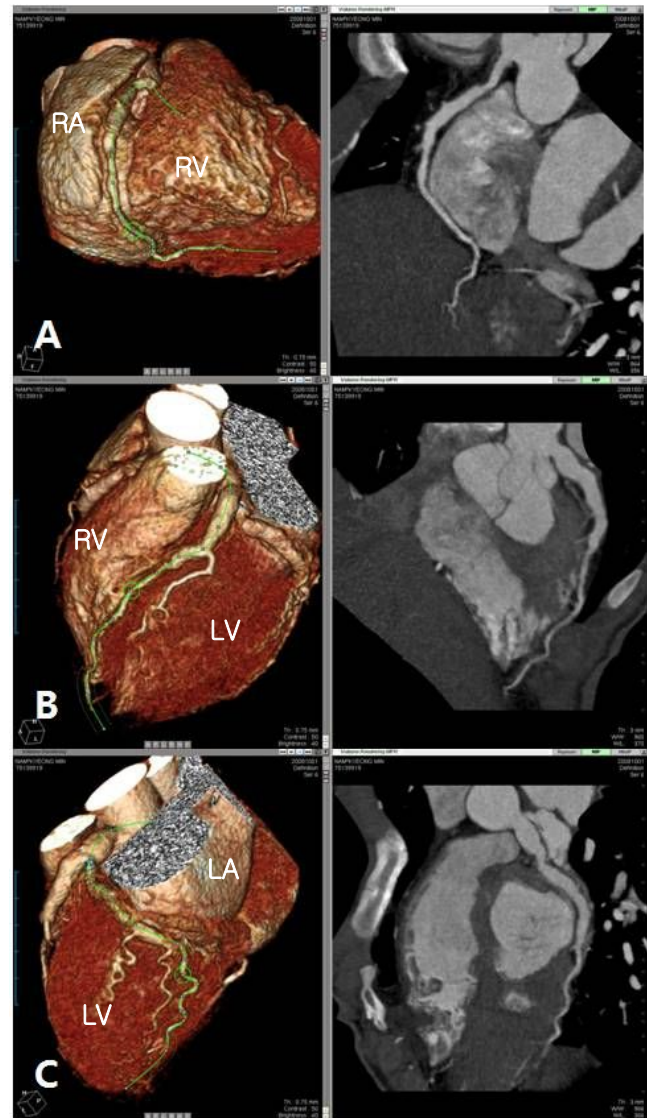


**Fig. 3.** Excisional biopsy of the inguinal lymph nodes revealed atypical lymphoid hyperplasia with marked follicular hyperplasia, some hemophagocytic histiocytes [hematoxylin and eosin stain, ×200 (A)], and many EBV-positive lymphoid cells [EBV in situ hybridization (ISH), ×200 (B)]. ISH was performed using a fluorescein-conjugated EBV probe to detect EBV-encoded ribonucleic acid transcripts (EBV probe ISH kit; Novocastra Laboratories Ltd.). This finding is consistent with EBV-associated IM.



**Fig. 4.** (A) This graph shows the response of fever to the intravenous gamma globulin and corticosteroid therapy and the duration for which skin rash, lymphadenopathy, and hepatosplenomegaly persisted. After methylprednisolone pulse therapy (30 mg/kg/day for 3 days), the patient had a dramatic positive response and his fever resolved. However, the fever recurred and relatively long-term (3 month) treatment with oral prednisolone was required. (B) The high EBV load decreased steadily in parallel with the clinical symptoms and reached normal levels at the 16-month follow-up.

less than 5 years. Occurrence of KD after late childhood is extremely rare<sup>3)</sup>. Therefore, arriving at a diagnosis of KD in adolescents is challenging and can be delayed because of the low index of suspicion for KD. Delayed diagnosis leads a delay in timely treatment with IVIG. According to the updated American Heart Association guidelines<sup>1)</sup>, it is preferable that a single dose of IVIG (2 g/kg) be administered together with aspirin within the first 10 days of illness, which is before aneurysms develop. In our case, both delayed treatment due to late diagnosis and treatment with half the recommended dose of IVIG may have contributed in part to the development of giant CAAs. In addition, our patient had many risk factors for CAAs, such



**Fig. 5.** Electrocardiographically gated 64-multidetector-row coronary CT angiography performed 10 months later revealed diffuse fusiform dilation of the coronary arteries (A, right coronary artery; B, left anterior descending coronary artery; C, left circumflex coronary artery). The maximum diameter of the left main coronary artery, left anterior descending coronary artery, left circumflex coronary artery, and right coronary artery were 10.5, 7.3, 10.6, and 6.0 mm, respectively. There was no evidence of thrombus on this CT scan. RA: right atrium; RV: right ventricle; LA: left atrium; LV: left ventricle.

as prolonged fever, older age, hyponatremia, hypoalbuminemia, high C-reactive protein levels, anemia, and leukocytosis<sup>4-6)</sup>.

Although KD mainly involves the coronary arteries, medium-sized arteries in the body can be involved. These non-coronary vascular complications are rare and include peripheral gangrene<sup>7)</sup>, cerebrovascular accident<sup>8)</sup>, ischemic



small-bowel strictures<sup>9)</sup>, and ischemic colitis<sup>10)</sup>. To our knowledge, splenic infarction associated with KD is extremely rare, and only 2 such cases have been reported to date<sup>11, 12)</sup>. There are also reports of a few cases of splenic infarction associated with IM or the presence of anticardiolipin antibodies<sup>13, 14)</sup>. Anticardiolipin antibodies are antiphospholipid antibodies that often increase transiently in various infectious diseases and in acute KD<sup>15)</sup>. Our patient did not have a history of venous or arterial thrombosis, except splenic infarction, and his anticardiolipin antibodies titers normalized after steroid treatment, as observed during 3 months of follow-up. Based on these findings, we speculate that splenic infarction is an unusual vasculitis manifestation of KD rather than an antiphospholipid syndrome.

There have been several studies on the relationship between EBV and KD. Kikuta et al.<sup>16)</sup> presented serological evidence of primary EBV infection in 86% of KD patients and 68% of recurrent KD patients; these conclusions are based on the results of the presence of the antibody to the viral capsid antigen. Kikuta et al.<sup>16)</sup> also found that by using a PCR assay, EBV sequences could be identified in 60% of KD patients but in only 12% of control cases. A few case reports suggest that EBV is the possible etiologic agent of KD. Kanegane et al.<sup>17)</sup> reported a case of KD with concomitant primary EBV infection. Muso et al.<sup>18)</sup> reported a necropsy case of EBV genome-positive tubulointerstitial nephritis associated with KD-like CAAs. However, the influence of EBV infection on coronary complication in KD patients remains unclear. In the present case, since specific antibody tests for EBV were performed after IVIG (total: 5 g/kg) therapy, the data were not reliable for interpreting whether the EBV infection was current, recent, in the past, or reactivated. However, we deduced that EBV reactivation was much more likely in this case because of the following reasons: (a) EBV PCR was positive. A positive EBV PCR implies primary EBV infection or EBV reactivation<sup>19)</sup>. (b) The majority of adolescents are EBV-seropositive because of prior exposure.

Although corticosteroids are the treatment of choice in other forms of vasculitis, their use has been limited in children with KD or EBV-associated IM. However, corticosteroids have been reported to be useful in patients with KD who fail to respond to IVIG<sup>20)</sup>. Furthermore, there is case report that steroid treatment of cardiac tamponade during KD was effective<sup>21)</sup>. Although the ideal treatment

regimen for complicated KD remains to be established, we suggest steroids may be an effective therapy in patients with IVIG-resistant KD accompanied by EBV-associated IM or a large amount of pericardial effusion.

## 한글 요약

### 전염성 단핵구증과 비경색증이 동반된 청소년 난치성 가와사키병 1예

서울대학교 의과대학 소아과학교실, 병리학교실\*, 영상의학교실†

최병삼 · 권보상 · 김기범 · 전윤경\* · 천정은†  
배은정 · 노정일 · 최정연 · 윤용수

가와사키병은 주로 소아기에 발생하는 급성 전신 혈관염으로, 원인은 아직 명확히 알려져 있지 않다. EBV는 전염성 단핵구증의 원인으로 잘 알려져 있으며, 또한 가와사키병의 원인으로도 보고된 바 있다. 가와사키병으로 인한 합병증은 관상동맥류를 포함한 심혈관계 합병증이 주를 이루지만, 다양한 종류의 합병증들이 보고되고 있다. 저자들은 EBV 감염과 연관된 전염성 단핵구증, 거대 관상동맥류, 심낭삼출, 비경색증이 동반된 난치성 가와사키병 환자 1예를 경험하였기에 보고하는 바이다. 환자는 3번의 면역글로불린 치료에도 반응이 없었지만, pulse methylprednisolone 치료 후에 임상 증상은 급격히 호전되었고, 거대 관상동맥류만 지금까지 지속되고 있다.

## References

- 1) Newburger JW, Takahashi M, Gerber MA, Gewitz MH, Tani LY, Burns JC, et al. Diagnosis, treatment, and long-term management of Kawasaki disease: a statement for health professionals from the Committee on Rheumatic Fever, Endocarditis, and Kawasaki Disease, Council on Cardiovascular Disease in the Young, American Heart Association. *Pediatrics* 2004;114:1708-33.
- 2) Wallace CA, French JW, Kahn SJ, Sherry DD. Initial intravenous gammaglobulin treatment failure in Kawasaki disease. *Pediatrics* 2000;105:E78.
- 3) Park YW, Han JW, Park IS, Kim CH, Cha SH, Ma JS, et al. Kawasaki disease in Korea, 2003-2005. *Pediatr Infect Dis J* 2007;26:821-3.
- 4) Muta H, Ishii M, Sakaue T, Egami K, Furui J, Sugahara Y, et al. Older age is a risk factor for the development of cardiovascular sequelae in Kawasaki disease. *Pediatrics* 2004; 114:751-4.
- 5) Nakamura Y, Yashiro M, Uehara R, Watanabe M, Tajimi M, Oki I, et al. Use of laboratory data to identify risk factors of giant coronary aneurysms due to Kawasaki disease. *Pediatr Int* 2004;46:33-8.
- 6) Song D, Yeo Y, Ha K, Jang G, Lee J, Lee K, et al. Risk factors for Kawasaki disease-associated coronary abnormalities differ depending on age. *Eur J Pediatr* [Epub ahead

- of print] 2009 Jan 22. Available from: URL://http://www.springerlink.com/content/100415/
- 7) Kim NY, Choi DY, Jung MJ, Jeon IS. A case of refractory Kawasaki disease complicated by peripheral ischemia. *Pediatr Cardiol* 2008;29:1110-4.
  - 8) Tabarki B, Mahdhaoui A, Selmi H, Yacoub M, Essoussi AS. Kawasaki disease with predominant central nervous system involvement. *Pediatr Neurol* 2001;25:239-41.
  - 9) Beiler HA, Schmidt KG, von Herbay A, Loffler W, Daum R. Ischemic small bowel strictures in a case of incomplete Kawasaki disease. *J Pediatr Surg* 2001;36:648-50.
  - 10) Thabet F, Bellara I, Tabarki B, Kchaou H, Selmi H, Yacoub M, et al. Ischemic colitis and hemophagocytosis complicating Kawasaki disease. *Arch Pediatr* 2004;11:226-8.
  - 11) Huong DL, Gafosse M, Papo T, Barjonet G, Lacombe P, Godeau P. Symptomatic splenic infarction complicating adult Kawasaki disease. *Br J Rheumatol* 1995;34:579-80.
  - 12) Cho BK, Kwon SR, Yoon SJ, Chung MH, Lee SN, Lee SH. Adult-onset Kawasaki disease complicated by splenic infarction and coronary aneurysm. *Korean J Infect Dis* 2000;32:388-92.
  - 13) Uthman I, Khamashta M. The abdominal manifestations of the antiphospholipid syndrome. *Rheumatology (Oxford)* 2007;46:1641-7.
  - 14) van Hal S, Senanayake S, Hardiman R. Splenic infarction due to transient antiphospholipid antibodies induced by acute Epstein-Barr virus infection. *J Clin Virol* 2005;32:245-7.
  - 15) Gupta M, Johann-Liang R, Bussel JB, Gersony WM, Lehman TJ. Elevated IgA and IgM anticardiolipin antibodies in acute Kawasaki disease. *Cardiology* 2002;97:180-2.
  - 16) Kikuta H, Nakanishi M, Ishikawa N, Konno M, Matsumoto S. Detection of Epstein-Barr virus sequences in patients with Kawasaki disease by means of the polymerase chain reaction. *Intervirology* 1992;33:1-5.
  - 17) Kanegane H, Tsuji T, Seki H, Yachie A, Yokoi T, Miyawaki T, et al. Kawasaki disease with a concomitant primary Epstein-Barr virus infection. *Acta Paediatr Jpn* 1994;36:713-6.
  - 18) Muso E, Fujiwara H, Yoshida H, Hosokawa R, Yashiro M, Hongo Y, et al. Epstein-Barr virus genome-positive tubulointerstitial nephritis associated with Kawasaki disease-like coronary aneurysms. *Clin Nephrol* 1993;40:7-15.
  - 19) Pitetti RD, Laus S, Wadowsky RM. Clinical evaluation of a quantitative real time polymerase chain reaction assay for diagnosis of primary Epstein-Barr virus infection in children. *Pediatr Infect Dis J* 2003;22:736-9.
  - 20) Shulman ST. Is there a role for corticosteroids in Kawasaki disease? *J Pediatr* 2003;142:601-3.
  - 21) Dahlem PG, von Rosenstiel IA, Lam J, Kuijpers TW. Pulse methylprednisolone therapy for impending cardiac tamponade in immunoglobulin-resistant Kawasaki disease. *Intensive Care Med* 1999;25:1137-9.