

Late adverse reactions to iopromide (Ultravist[®]) diagnosed by the patch test: a case report

Soon Joo Lee, M.D., Eun Mi Yang, M.D., Woo Yeon Choi, M.D.
Eun Song Song, M.D., Dong Kyun Han, M.D.
Young Kuk Cho, M.D. and Jae Sook Ma, M.D.

Department of Pediatrics, Chonnam National University Medical School,
Chonnam National University Hospital, Gwang-Ju, Korea

= Abstract =

Iodinated contrast media (CM) can cause immediate and late reactions. We treated a patient with a recurrent generalized maculopapular rash and a fever that occurred within two days of exposure to iodinated CM iopromide (Ultravist[®]) computed tomography. We performed skin testing including prick tests, intradermal tests, and patch tests. Q indicated a late skin reaction to Ultravist[®] in addition to cross-reactions to other iodinated CMs such as ioversol (Iobrix[®]), and iobitridol (Xenetix[®]). In this study, we report the case of a patient diagnosed with a late reaction to Ultravist[®] in addition to cross-reactions to other iodinated CM (Korean J Pediatr 2009; 52: 499-503)

Key Words : Iopromide, Late Adverse Reaction, Patch Test, Cross-reaction

Introduction

Iodinated X-ray contrast media (CM) have been on the market for approximately 70 years; they are among the most frequently used pharmaceuticals for intravascular injection, with 40-50 million applications per year world wide¹⁾. The iodinated X-ray CM are highly concentrated solutions. They are divided into four groups depending on the molecular properties of the active ingredients: (1) ionic monomers, (2) ionic dimmers, (3) nonionic monomers, and (4) nonionic dimmers. All have the same tri-iodinated benzene ring, but differ in the structure of the side chain in the 1, 3 and 5 positions and in the number of benzene rings^{1,2)}. Among these compounds, iopromide (Ultravist[®], Berlin, Germany) is a water soluble, low osmolar, nonionic, and tri-iodinated CM.

Generally, adverse reactions to CM are divided into immediate, those that occur within one hour after contrast administration, and late, for those cases that occur more than one

hour but less than seven days following CM administration¹⁾. The late adverse reactions mainly manifest with, headaches, rashes, itching, limited urticaria, nausea, and dizziness. The most common type of late skin reaction is a generalized maculopapular exanthema (more than 50% of the cases), although there are other types of reactions such as pruritus, urticaria, angioedema, and less commonly, severe forms of erythema multiforme, vasculitis, Stevens-Johnson syndrome, and hypersensitivity syndrome¹⁾.

hypersensitivity

Here in, we report a patient with a generalized maculopapular rash and a fever that occurred within two days, following the use of X-ray CM (Ultravist[®]). The skin patch testing results were consistent with a late skin reaction to Ultravist[®] with concomitant cross-reactivity to other contrast compounds including ioversol (Optiray[®], Hennef, Germany), iohexol (Iobrix[®], Seoul, Korea) and iobitridol (Xenetix[®], Bloomington, USA). This report is first recorded case of a late adverse reaction to Ultravist[®] diagnosed by patch testing in Korea.

Case report

A 4-year-old boy was admitted for the clinical evaluation

Received : 2 September 2008, Revised : 12 December 2008,

Accepted : 13 February 2008

Address for correspondence : Jae-Sook Ma, MD

Department of Pediatrics, College of Medicine, Chonnam National University
8 Hakdong, Dong-gu, 501-757, Gwangju, Korea

Tel : +82. 62-220-6646, Fax : +82. 62-222-6103

E-mail : cardiol@nu.ac.kr

and treatment of swelling and tenderness in the neck in addition to a fever. The symptoms developed two days prior to admission and were worsening. On presentation, the body temperature was 38.0°C with a pulse rate of 142 beats/minute, the respiratory rate was 30 breaths/minute and the blood pressure 90/60 mm/Hg. On physical examination, the patient had a rash, was warm and had tenderness and swelling from the lower chin to the upper anterior chest. The laboratory data were as follows: a total white blood cell count of 15,000/ μ L that was neutrophil dominant (93.5%), hemoglobin (Hgb) of 12.7 g/dL and the C-reactive protein (CRP) was increased to 40.2 mg/dL. The renal function and liver function tests were within the normal range. The chest roentgenogram showed bilateral pleural effusions, more marked on the right side. A chest computed tomography was performed using about 30 mL of the CM, Ultravist[®]. The results showed a cellulitis of the neck and mediastinum, reactive lymphadenitis and bilateral pleural effusions. The patient was diagnosed with cellulitis and reactive lymphadenitis. The fever resolved after three days of treatment with antibiotics (ceftriaxon,

ampicillin, clindamycin). On the seventh hospital day, a second chest CT using Ultravist[®] was performed. The results showed progression with worsening of the inflammatory lesions and abscess formation. Despite these findings, the clinical tenderness, swelling and fever were improved. Therefore, the treatment was not changed. Three days after the CT examination using CM, infiltrated erythema was noted from the neck and face, spreading to the trunk and lower limbs with fever (Fig. 1). To evaluate the etiology of the skin lesions, additional blood tests were obtained. The laboratory findings were as follows: a WBC of 7,000/ μ L with 59.3% neutrophils, 1.8 % eosinophils, Hgb 11.7 g/dL, and IgE 63.30 IU/mL. The CRP decreased to 14.9 mg/dL. The laboratory and clinical findings were consistent with decreased inflammation. Consequently, the skin lesions and fever were considered to be an allergic reaction to the CM. Treatment with antihistamines and corticosteroids were started. The skin lesions receded within five days with this treatment. The neck swelling continued to improve, and on the eighteenth hospital day, a chest CT was performed. This showed significant improvement of the cellulitis and abscess. Two days later a generalized maculopapular rash developed that receded within four days with intravenous methylprednisolone treatment. The recurrent rash was thought to be due to a hypersensitivity reaction to the CM. Thereafter, ultrasonography (US) was used to follow the inflammatory lesions. An US was performed on the twenty-fifth hospital day. The neck abscess was nearly completely resolved and the laboratory findings normalized. The patient was discharged on the

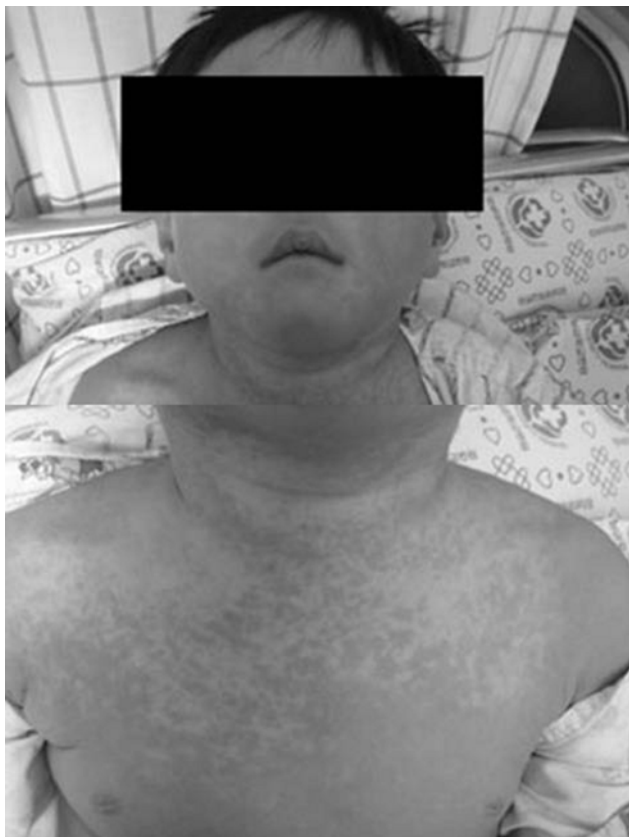

Fig. 1. Maculopapular rash on the face, neck, and trunk at three days after exposure to the contrast media Ultravist[®] (iopromid).

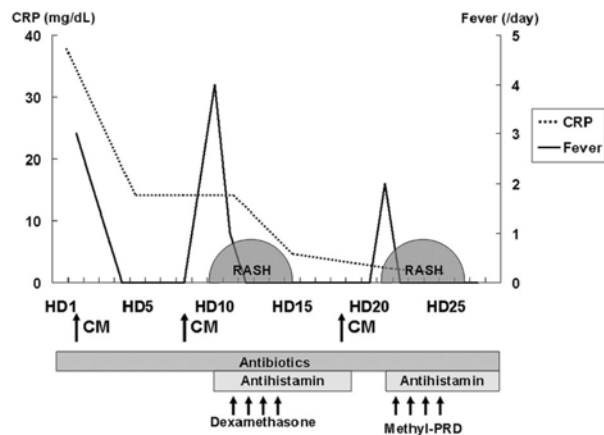


Fig. 2. Serial values of the frequency of fever, serum CRP, timing of administration of the contrast media, antibiotics, steroid regimen, and progression of rash during hospitalization. CM contrast media (Ultravist[®]); Methyl-PRD: methylprednisolone.

twenty-seventh hospital day (Fig. 2).

Two months later, the patient visited the out-patient department and appeared well. The allergy testing performed included skin prick tests, intradermal tests and patch tests with a CM series that was used at our hospital that included Ultravist®, Optiray®, Iobrix®, and Xenetix®. The prick tests were performed on the forearm skin with undiluted CM, and results were obtained 20 minutes after testing. The intradermal tests were performed with a 1:10 diluted drug, and results were obtained after 20 minutes. The patch tests were performed on the upper back using the Finn chamber® on Scanpor® (Epitest Ltd Oy, Tuusula, Finland) with Ultravist® at 0.1%, 1%, 10%, and Optiray®, Iobrix® and Xenetix® at 10%. After two days, the Finn chamber® was removed and after 30 minutes, the results were obtained. A second reading of the patch tests was done 48 hours after the first reading. The results of the patch tests were reported according to the International Contact Dermatitis Research Group Criteria for patch test reading³⁾.

During the skin testing using the CM series, the patient complained of mild pruritus; the symptoms subsided after

Table 1. The Allergy Tests with the Contrast Medium Series

Contrast media Iobrix®	Prick test	Intradermal test	Patch test		
			Conc.*	48hrs	96hrs
Xenetix®	-	-	10%	+	-
Optiray®	-	-	10%	+	-
Ultravist®	-	-	10%	++	-
			10%	++	-
			1%	++	-
			0.1%	++	-

awhile. The prick tests and intradermal tests with the CM series did not induce positive results to any of the tested CM. However, the first reading at 48 hours was positive for the CM series on the patch test (Ultravist® at 0.1%, 1%, 10%, and Optiray®, Iobrix® and Xenetix® at 10%) (Fig. 3, Table. 1). The results for Iobrix® and Xenetix® at 10% were weak positive (erythema) and that of Ultravist® at 0.1%, 1%, 10%, and Optiray® at 10% were strong positive (erythema and tiny vesicles). The second reading at 96 hours was negative for the CM series on the patch test, and left a mark.

Discussion

Intravascular CM for x-ray studies is required for use in many diagnostic radiological procedures. Patient tolerance to CM media has improved over the past few years with the use of compounds more widely tolerated. Late adverse reactions to iodinated CM are defined as reactions occurring between one hour and seven days after CM administration. Such reactions were first recognized in the mid-1980s⁴⁾ and since then have been widely studied, particularly the reactions to low-osmolality CM. Review of the medical literature revealed a frequency of late adverse reactions to CM to range from 0.5% to 23%⁵⁾. However, the true frequency is difficult to determine due to variations in the patients studied and the methodologies used.

The reports on late reactions to CM commonly include symptoms such as headaches, skin rashes, itching, nausea, dizziness, urticaria, fever, arm pain, and gastrointestinal disturbances. The majority of late skin reactions to CM present as a mild to moderate generalized maculopapular exanthema that usually involves the trunk and proximal aspects of the

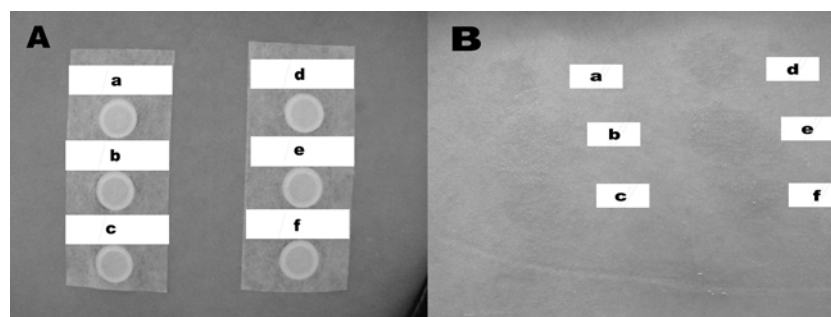


Fig. 3. A) Patch tests were performed on the upper back using Finn chamber® with Ultravist® at (a) 0.1%, (b) 1%, (c) 10% and with (d) Optiray®, (e) Iobrix®, (f) Xenetix® at 10%. B) At 48 h after the patch test, the results of Iobrix® and Xenetix® at 10% were weak positive (erythema) and those for Ultravist® at 0.1%, 1%, and 10% and for Optiray® at 10% were strong positive (erythema and tiny vesicles).

upper and lower limbs although, as in our series, can present with facial and distal limb involvement⁶.

The pathophysiological mechanism of CM-Induced late reactions remains unclear¹. However, most of late skin eruptions appear to be T-cell mediated allergic reactions. This is supported by the frequently of reported positive patch tests, delayed intradermal tests to the CM previously exposed to, the presence of dermal infiltrates of T cells in affected skin, positive skin test sites, the reappearance of the eruption after provocation testing, and the ability of CM to stimulate proliferation of peripheral T cells from patients with CM-induced skin eruptions⁷.

Skin tests are very important diagnostic tools in patients with late skin reactions to CM¹. Three types of tests are commonly used: the skin prick test, the intradermal test and the patch test. The former two tests are used for the diagnosis of both IgE-mediated and T-cell mediated reactions, whereas the patch test is used to diagnose T-cell mediated reactions only. Patch tests with undiluted CM on the back and readings after two and three to four days, and intradermal tests with diluted CM and late readings after one to three days appear to be specific and useful in the clinical setting. Both the patch test and intradermal test should be read after one week, if previously negative⁸. To avoid a severe immediate anaphylactic reaction, a prick test with undiluted CM read after 15-20 min should be conducted before performing an intradermal test. However, the role of skin testing continues to be debated; some studies report a greater sensitivity with intradermal tests⁶, while others, report that the patch test is more frequently positive⁹.

In patients with late skin eruptions in response to CM, other organs may be involved¹⁰. Thus, during the acute phase of more severe reactions, laboratory tests such as liver and renal function tests as well as differential blood cell counts should be performed to evaluate for other systemic effects. However, currently there is no data available regarding the frequency of laboratory test abnormalities in these patients⁷.

Certain risk factors have been associated with the development of late skin reactions to CM. These include a history of previous reactions to CM, female gender, cardiac disease, diabetes mellitus, renal failure, and concomitant treatment with interleukin-2 or beta-blockers^{7, 11, 12}. A seasonal variation in the incidence of late skin reactions has been described with 45% of the reactions occurring during the period from April to June in Finland¹³.

When late skin reactions to CM occur they usually develop within one to seven days with the majority occurring within the first three days¹⁴. Most reactions are self-limiting and resolve within seven days, with up to three-quarters resolving within three days¹⁴. The patient management is symptomatic and similar to the management of other drug-induced skin reactions⁵.

Patients with late skin reactions to CM are at risk for developing new eruptions if exposed again to the same CM. Therefore, this should be avoided by using a different class of CM. However, the frequency of cross-sensitivity to different CM is a problem⁶; up to 75% of cases have cross-sensitivity to other CM. Cross-sensitivity occurs among the ionic and nonionic, monomeric and dimeric agents. Therefore, change of CM is no guarantee against a repeat reaction¹². Therefore, avoidance of the causative agent is the safest course. Some have recommended premedication with oral corticosteroids and antihistamines as prophylaxis; however, there is no evidence to support the efficacy of these measures¹². A novel pretreatment protocol was recently described by Romano *et al.*¹⁵. They reported the successful use of intramuscular 6-methyl-prednisolone (40 mg daily) and oral cyclosporine (100 mg twice daily) one week before and two weeks after each of four angiograms in a patient with two previous episodes of maculopapular reaction to CM administration, the last reaction occurred despite steroid premedication. Further investigations are needed in order to establish a practical and effective pretreatment protocols for the prevention of new reactions in patients with previous late-skin reactions to CM.

In the patient reported here infiltrated erythema of the face and generalized maculopapular rashes with fever occurred on two occasions, within three days, following the use of Ultravist[®] for the chest CT for evaluation of the cellulites of the neck and mediastinum. The allergy investigations included the skin prick test and intradermal testing with a series of CM, as well as the patch test. The findings of these studies were consistent with a late skin reaction to the active substance iopromid contained in Ultravist[®]. In addition, cross-reaction to Optiray[®], Iobrix[®] and Xenetix[®] was also identified.

한 글 요약

첩포검사로 진단된 Iopromide (Ultravist®)의
지연성 부작용 1예

전남대학교 의과대학 소아과학교실

이순주 · 양은미 · 최우연 · 송은송
한동균 · 조영국 · 마제숙

요오드성 조영제는 즉각적인 부작용과 지연성 부작용을 일으킬 수 있다. 저자들은 컴퓨터 단층 촬영을 위해 요오드성 조영제인 iopromide (Ultravist®)를 사용하고 2일 뒤에 전신에 반점 구진성 반점과 발열이 반복적으로 발생한 환아를 경험하였다. 이 환아에서 피부단자시험, 피내반응검사, 첩포검사를 포함한 피부반응검사를 시행하여 Ultravist®에 지연성 반응임을 확인하고 다른 조영제인 ioversol (Optiray®), iohexol (Iobrix®), iobitridol (Xenetix®)에도 교차반응이 있음을 확인하였기에 보고하는 바이다.

References

- 1) Christiansen C, Pichler WJ, Skotland T. Delayed allergy-like reactions to X-ray contrast media: mechanistic considerations. *Eur Radiol* 2000;10:1965-75.
- 2) Delgado-Jimenez Y, Perez-Gala S, Aragüés M, Sanchez-Perez J, Garcia-Diez A. Late skin reaction to iodixanol (Visipaque): clinical manifestations, patch test study, and histopathological evaluation. *Contact Dermatitis* 2006;55:348-53.
- 3) Calnan CD, Fregert S, Magnusson B. The International Contact Dermatitis Research Group. *Cutis*. 1976;18:708-10.
- 4) Panto PN, Davies P. Delayed reactions to urographic contrast media. *Br J Radiol* 1986;59:41-4.
- 5) Webb JA, Stacul F, Thomsen HS, Morcos SK. Late adverse reactions to intravascular iodinated contrast media. *Eur*

Radiol 2003;13:181-4.

- 6) Vernassiere C, Trechot P, Comu'n N, Schmutz JL, Barbaud A. Low negative predictive value of skin tests in investigating late reactions to radio-contrast media. *Contact Dermatitis* 2004;50:359-66.
- 7) Brockow K, Christiansen C, Kanny G, Clément O, Barbaud A, Bircher A, et al. Management of hypersensitivity reactions to iodinated contrast media. *Allergy* 2005;60:150-8.
- 8) Barbaud A, Goncalo M, Bruynzeel D, Bircher A. Guidelines for performing skin tests with drugs in the investigation of cutaneous adverse drug reactions. *Contact Dermatitis* 2001; 45:321-8.
- 9) Barbaud A, Reichert-Penetrat S, Trechot P, Jacquin-Petit MA, Ehlinger A, Noirez V, et al. The use of skin testing in the investigation of cutaneous adverse drug reactions. *Br J Dermatol* 1998;139:49-58.
- 10) Schick E, Weber L, Gall H. Delayed hypersensitivity reaction to the non-ionic contrast medium iopromid. *Contact Dermatitis* 1996;35:312.
- 11) Kanny G, Marie B, Hoen B, Trechot P, Moneret-Vautrin DA. Delayed adverse reaction to sodium ioxaglic acid-meglumine. *Eur J Dermatol* 2001;11:134-7.
- 12) Idee J M, Pines EM, Prigent P, Corot C. Allergy-like reactions to iodinated contrast agents. A critical analysis. *Fund Clin Pharmacol* 2005;19:263-81.
- 13) Mikkonen R, Vehmas T, Granlund H, Kivisaari L. Seasonal variation in the occurrence of late adverse skin reactions to iodine-based contrast media. *Acta Radiol* 2000;41:390-3.
- 14) Hosoya T, Yamaguchi K, Akutzu T, Mitsuhashi Y, Kondo S, Sugai Y, et al. Delayed adverse reactions to iodinated contrast media and their risk factors. *Radiat Med* 2000; 18: 39-45.
- 15) Romano A, Artesani MC, Andriolo M, Viola M, Pettinato R, Vecchioli-Scaldazza A. Effective prophylactic protocol in delayed hypersensitivity to contrast media: report of a case involving lymphocyte transformation studies with different compounds. *Radiology* 2002;225:466-70.