

Attenuation of Ischemia-Reperfusion Injury by Antioxidant Vitamins in a Pig Model of Renal Auto-Transplantation

Myung-Jin Kim, Jae-Yon Lee, Sung-Whan Cho, Chang-Sik Park*, Moo-Hyung Jun,
Seong-Mok Jeong and Myung-Cheol Kim¹

College of Veterinary Medicine, Chungnam National University, Daejeon 305-764, Korea, *Division of Animal Science & Resources, Research Center for Transgenic Cloned Pigs, Chungnam National University, Daejeon 305-764, Korea

(Accepted : January 29, 2009)

Abstract : This study was to determine the effects of ascorbic acid and alpha-tocopherol on the attenuation of an ischemia-reperfusion injury (IRI) after renal auto-transplantation in a pig model. In the treatment group, three pigs were subjected to a renal auto-transplantation followed by the administration of ascorbic acid and alpha-tocopherol and the flushing of ascorbic acid plus hepa-saline solution. Otherwise, the control group used only flushing of hepa-saline solution. Blood samples were collected from these pigs for measurement of serum blood urea nitrogen (BUN) and creatinine values on the day before surgery and day 1, 3, 5 and 7 after surgery. The kidneys were taken for histopathological evaluation following euthanasia on day 14 after surgery. Serum creatinine and BUN values showed a significantly difference between control and treatment group on day 1, 3 and 5 ($P < 0.05$). In histopathologic findings, treatment group showed less damage than that of the control group on the basis of renal tubular damage. As a result, this study suggests that the exogenous ascorbic acid and alpha-tocopherol pretreatment therapy with ascorbic acid irrigation-aspiration has a role of attenuation of renal I/R injury and recovery of renal function in a pig transplantation model.

Key words : ascorbic acid, alpha-tocopherol, pig, renal transplantation, antioxidant.

Introduction

Renal allografts represent an established treatment modality for patients with end-stage renal disease (25). Ischemic injury of the renal allograft before implantation is an important cause of delayed graft function (6). The protection of cells from anoxic cell death could have important clinical applications in the kidney. The viability of the transplanted organ depends on the tolerance of the graft to cold and warm ischemia and reperfusion during surgery (6,13). Therefore, ischemia-reperfusion injury (IRI) was a great role of acute renal failure and renal graft rejection. Renal warm IRI occurs in clinical practice and is a consequence of systemic hypoperfusion with subsequent circulatory resuscitation. Local renal hypoperfusion after aortic cross-clamping or renal transplantation also cause IRI to the kidney (17).

Pigs are commonly used as an animal model of research project in human kidney transplantation. They are very useful experimental animals for renal allograft model study. Oxidative stress is involved in kidney injury induced by IRI. Increased renal oxidative stress (ROS) generation occurs after reperfusion, leading to oxidative damage and dysfunction (31). Renal IRI leads to production of excessive amounts

of ROS and reactive nitrogen species (RNS), causing oxidative stress which results in alterations in mitochondrial oxidative phosphorylation, depletion of ATP, an increase in intracellular calcium and activation of protein kinases, phosphatases, proteases, lipases and nucleases leading to loss of cellular function and integrity (28). The expression of proinflammatory cytokines during IRI result in the upregulation of inducible NO synthase (iNOS), thereby producing large amounts of NO for a longer period (3-5 days). Under oxidative stress conditions, NO reacts with superoxide to generate peroxynitrite, which is capable of nitrating tyrosine residues of proteins and enzymes leading to tissue injury (24). Oxidative stress has been shown to induce apoptosis of proximal tubular cells of kidney in culture. Schumer *et al.* (26) has demonstrated apoptosis as a result of warm ischemia and reperfusion of rat kidneys. Furthermore, in a study of biopsy specimens from human renal allografts, Matsuno *et al.* (21) has demonstrated a correlation between significant levels of apoptosis in post reperfusion biopsy specimens and delayed graft function. A recent study has shown that apoptosis is a crucial event during IRI which can initiate reperfusion-induced inflammation and subsequent tissue injury (9,21,26).

Evidence of oxygen radical-mediated injury in kidney includes demonstration of renal injury being accentuated by oxidants and the observation that deficiency of antioxidants exacerbates renal injury and that free radical-mediated lipid

¹Corresponding author.
E-mail : mckim@cnu.ac.kr

peroxidation occurs as a manifestation of IRI also implicate oxidants in the pathophysiology of acute renal failure (20,22). Therefore, a renal transplanted patient may not have better outcome if these hazardous metabolites like oxygen radical-mediated and IRI were not reduced.

In order to decrease these metabolites, many researchers have tried the variety of scavenger for the free radical oxygen. To reduce these metabolites, many investigators have examined the variety of scavenger for the free radical oxygen (12,20,22).

Although reperfusion is crucial for oxygen delivery to ischemically injured tissues, the reoxygenation is known to be detrimental because it allows the generation of reactive oxygen metabolites (ROMs) such as superoxide anions, hydroxyl radicals, and hydrogen peroxides. ROMs are able to damage cells through chemical interactions with key cellular constituents, including proteins, lipids, and DNA (12,14).

Nonenzymatic antioxidant, ascorbic acid is the primary water-soluble antioxidant in human plasma, capable of scavenging oxygen-derived free radicals and sparing other endogenous antioxidants from consumption (11). It improves renal hemodynamics and decreases oxidative stress, inflammation, and fibrosis in the ischemic kidney. These observations underscore the involvement of oxidative stress in renal injury in renal artery stenosis and support a role for antioxidant vitamins in preserving the ischemic kidney in pigs (7).

In many studies, compound form of ascorbic acid and E and other antioxidants were used for attenuation of renal IRI. However, ascorbic acid and E pre-treatment combination therapy before 2 days and 1 day of surgery and ascorbic acid flushing have not been reported in experiment related with IRI.

The purpose of this study is to determine effect of administration of ascorbic acid and alpha-tocopherol as scavenger of free radical oxygen, against attenuation of ischemia-reperfusion injury and recovery of renal function in pig renal autograft model.

Materials and Methods

Animals

Six pigs, 3-4 month-old, Landrace and Yorkshire mixed breed pigs of both genders weighing 36.17 ± 3.66 kg were provided from the agriculture livestock farm, Chungnam National University. The Laboratory Animal Care Advisory Committee and Research Center for Transgenic Cloned Pigs Center, Chungnam National University approved the study protocol. These animals were acclimated and maintained on a standard diet for pigs, routine lighting cycle and room temperature, and normal renal function was demonstrated before the surgical procedure.

Experimental groups

The experimental model for this study involved renal autologous transplantation in the pigs. Renal autologous transplantation avoids immunological problems and a large-

size animal can stimulate human conditions of perfusion.

The pigs were assigned randomly into a control (non-treatment) group (n = 3) or a treatment (ascorbic acid and alpha-tocopherol pre-treatment) group (n = 3).

1) Control group (n = 3); the left kidney was exposed through a ventral midline incision. It was freed from the perirenal tissues and fat, and then the left renal artery and vein were clamped using an atraumatic bulldog clamp. They were dissected close beneath the aorta and caudal vena cava. After the removal of the left kidney, all arteries were perfused using cold hepa-saline solution [Heparin (Choongwae Pharm., Korea, 1,000 IU) + Saline 500 ml] administered through the renal artery (80 mmHg) and suck down the fluid from the renal vein during 60 minutes. And then right nephrectomy was performed.

2) Treatment group (n = 3); Ascorbic acid ((Guju Pharm., Korea) 1,000 mg/head/day, IM) and alpha-tocopherol ((Donga Pharm., Korea) 100 IU/head/day, PO) combination therapy were given for 2 days before surgery. The left kidney was freed from the perirenal tissue and fat, and then the left renal artery and vein were clamped with an atraumatic bulldog clamp. They were dissected from closed approach beneath aorta and caudal vena cava. After the left kidney was removed, all arteries were perfused using vitamin C and hepa-saline solution [Heparin (Choongwae Pharm., Korea, 1,000 IU) + saline 500 ml + Vitamin C 1000 mg] administered through the renal artery (80 mmHg) and suck down the fluid from the renal vein during 60 minutes. And then, right nephrectomy was performed. During 2 days of post-operation, ascorbic acid (1000 mg/head) is injected intramuscularly.

Surgical procedure

Water and feed were fasted for 24 hours before surgery, in order to prevent the possible adverse effects associated with anesthesia. The animals were premedicated with atropine sulfate (Atropine Sulfate[®], Huons Co., LTD., 0.04 mg/kg, IM). After 10 minutes, tiletamine/zolazepam (Zoletil[®], Virbac, France, 4.4 mg/kg, IM) was given for immobilization. Before tracheal intubation, thiopental sodium (Thionyl[®], Dai Han Pharm. Co., LTD., 15 mg/kg, IV) was administered and antibiotic prophylaxis with ampicillin sodium (Penbrook[®], Chong Kun Dang Co., 20 mg/kg, IV) and analgesia with meloxicam (Metacam[®], Boehringer Ingelheim Co., 0.2 mg/kg, IM) was performed.

The anesthesia was induced with thiopental sodium (12.5 mg/kg, IV) and then maintained during the procedure with 2% isoflurane and 100% oxygen supply. A balanced electrolyte solution (Lactated Ringer's Sol., 10 ml/kg/hr IV) was administered to all pigs. Mannitol (D-MANNITOL[®], Dai Han Pharm. Co., LTD., 1 g/kg IV) was administered to the animals 20 minutes before nephrectomy.

An exploratory celiotomy was performed. Kidneys were exposed through a midline incision, and the left renal artery, vein, and ureter were mobilized for transplantation. The kidneys were harvested, flushed with cold, heparinized saline /

heparinized saline with ascorbic acid solution, and placed in cold, sterile saline solution before anastomosis.

The abdominal aorta and caudal vena cava were isolated using a combination of sharp and blunt dissection. A surgi-loop was placed around the isolated vena cava to retract the vessel from the aorta. A portion of the aorta was likewise isolated. A dorsal branch extending from the aorta is also present in this region and can be preserved by temporary atraumatic occlusion with a microvascular clamp. The left and right sides of both the abdominal aorta and caudal vena cava were clamped with two couples of surgi-loop under tension as these would elevate the aorta to the surface of the incision and simplify the anastomosis. The abdominal aorta and caudal vena cava under the occluding microvascular clamp were cut by an arteriotomy clamp. After completion of the arteriotomy, blood was flushed from the lumen of the aorta.

The renal vein was anastomosed in an end-to-side fashion to the caudal vena cava using simple interrupted sutures with 5-0 polypropylene. The renal artery was anastomosed in an end-to-end fashion to the aorta using 6-0 polypropylene with simple interrupted suture pattern. If two renal arteries were present, double arteries were managed with a bridging of renal arteries modified technique reported by Sarin *et al.* (25).

The ureter was sutured to the bladder mucosa in a modified ureteroneocystostomy technique using 6-0 polypropylene with simple interrupted suture pattern. A nephropexy was performed by suturing the renal capsule to the abdominal wall with simple interrupted sutures using 2-0 polyglycolic acid. After implantation of the autograft, contralateral kidneys were removed. Postoperatively, the pigs were allowed free access to water and feed after 24 hours of surgery.

Renal function

BUN and creatinine levels were determined on serum samples taken on day 0 (pre-operative), 1, 3, 5 and 7 after procedure from the left jugular vein, using a commercially available kit (VetTest, IDEXX Co., Japan).

Blood Pressure

Invasive blood pressure was measured by using Pulsan-Component® (SCIONIC Co., LTD. USA) and monitoring-set® (B/BRAUN, Co., Germany) at the renal artery and aorta. Measurement of blood pressure was performed at pre-anastomosis, 10 and 60 minutes after anastomosis through the direct invasion using the 24G scalp vein set® (KOREA VACCINE, Co., LTD, Korea) in the lumen of artery.

Histopathological examination

The study protocol called for euthanizing surviving pigs after the third post-transplant week if the serum creatinine values normalized to <1.8 mg/dl. Tissue samples from the left kidney were taken for histopathological examination after euthanasia on postoperative day 14.

The kidneys were fixed in 10% neutral buffered formalin.

Samples were dehydrated in 70% to 100% alcohol, and xylene was used for clearing samples. Tissue were embedded in paraffin, sectioned (5 µm thick), stained with H&E, and examined with a light microscope.

Statistical analysis

All values are expressed as means ± SD of determinations for all pigs in the group. Data were analyzed using analysis of variance with two-way repeated measures analysis (ANOVA) followed by Student's *t*-test, and a *P* value below 0.05 or 0.01 was considered statistically significant.

Results

Renal function

Serum creatinine levels, measured as an index of kidney function, significantly increased ($P < 0.05$) to 6.85 ± 0.83 mg/dl in the control group by day 1 of reperfusion and then decreased gradually until day 7, while in the treatment group, these levels went up to 4.00 ± 0.28 mg/dl by day 1 of reperfusion and then decreased gradually by 7 days after reperfusion (Fig. 1).

It was also measured blood urea nitrogen (BUN) as a second index of kidney function in this study. Similar to serum creatinine, the levels of BUN in the control group significantly increased to 81.00 ± 5.57 mg/dl by 1 day after reperfusion ($P < 0.05$). The BUN levels in the treatment group increased to 54.00 ± 11.53 mg/dl by 1 day of reperfusion (Fig. 2).

Histopathological findings

On day 14 after the treatment, moderate cystic dilation of tubules with inflammatory cell infiltration, regeneration of tubules and congestion were demonstrated in the kidney of the control group (Fig. 3A & B). In contrast, only slight damage of tubules was demonstrated in the kidney of the treatment group. Tubular epithelium was essentially normal,

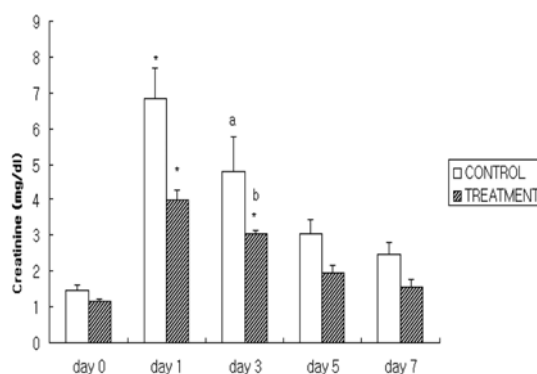


Fig 1. Serum creatinine levels in pigs after autologous renal transplantation. The values are expressed as mean ± SD for all groups (n=3). *Significant difference from baseline ($p < 0.05$). a,b: Values marked with different letters (a, b) represent significant different means ($p < 0.05$) at same time point.

although there were occasionally mild cystic dilation of tubules with mild peritubular inflammatory cell infiltration and regeneration of tubules (Fig. 4A & B).

Discussion

There are lots of studies about pig kidney transplantation until now. As pig kidneys have the best similarity to the human beings, many medical doctors have investigated renal

allograft experiment before human kidney transplantation although some risk factors have already been detected; rejection episodes, high age of organ donor, the cause of the donor's death anastomosis time, number of previous transplantations and sensitization (32). Many studies on renal function after pig transplantation started assessing serum creatinine values 24h after transplantation. Renal transplantation in the pig has been established for years and, as opposed to "isolated kidney" or "warm ischemia" models, seems the ideal way to study early organ function as closely as possible to clinical human renal transplantation (19,32).

When renal transplantation performed for the treatment of chronic renal failure, renal ischemia-reperfusion is invariably followed and of great clinical interest because of its role in acute renal failure and renal graft rejection. Therefore, a lot of studies have been performed to ameliorate this IRI (4,18). To improve not only IRI but also oxidative stress, many researchers has investigated renal IRI in rats (1,23), dogs (5), rabbits (10) and pigs (15).

Oxidative stress represents the imbalance between oxidants such as ROS and antioxidants (34,35), and antioxidant defenses in the cell can temper the negative influence of free radicals and associated reaction and keep them in check (4). Alpha-tocopherol is the major lipid-soluble antioxidant in cell membranes. It protects against lipid peroxidation by acting directly with a variety of oxygen radicals, including singlet oxygen, lipid peroxide products, and the superoxide

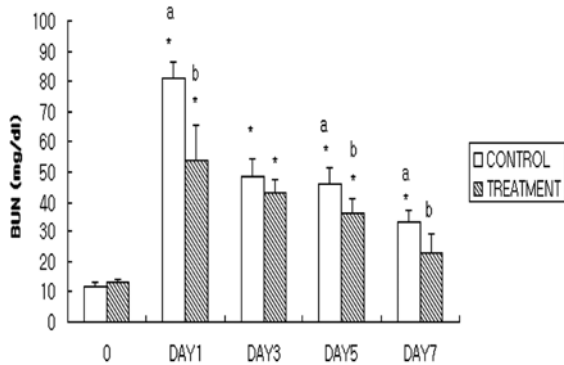


Fig 2. Blood urea nitrogen levels in pigs after autologous renal transplantation. The values are expressed as mean \pm SD for both groups (n=3). *Significant difference from baseline (p<0.05). a,b: Values marked with different letters (a, b) represent significant different means (p<0.05) at same time point.

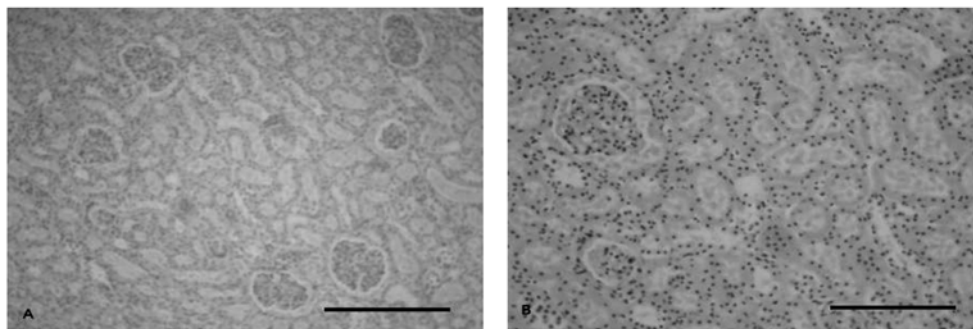


Fig 3. Histopathological findings in the kidney from the control group. Note inflammatory cell infiltration, severe degeneration and necrosis of the tubular epithelium. (H-E stain; Bar A= 50 μ m, B=100 μ m).

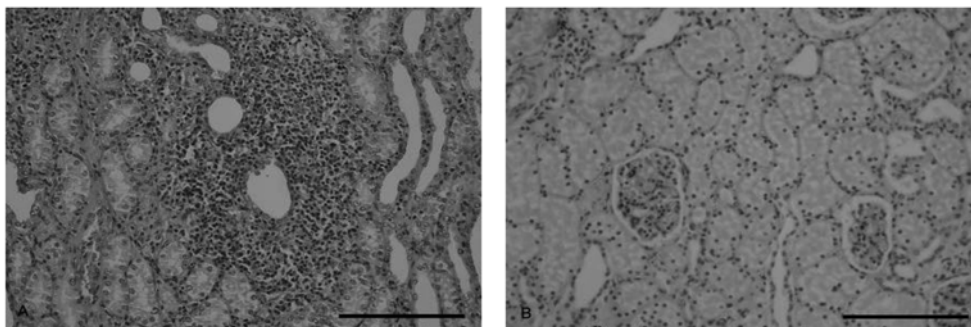


Fig 4. Histopathological findings in the kidney from the treatment group. Note vacuolar degeneration of the tubular epithelium infiltration of the lymphocyte in the interstitium. (H-E stain; Bar A= 50 μ m, B=100 μ m)

radical to form a relatively innocuous tocopherol radical. Ascorbic acid can interact with the tocopherol radical to regenerate reduced tocopherol. Ascorbic acid is water soluble and can directly react with superoxide, hydroxyl radicals, and singlet oxygen (8).

Ascorbic acid of variety antioxidants regenerates alpha-tocopherol, glutathione, and flavonoids (29). Therefore, it protects free radical mediated protein inactivation associated with the oxidative burst of neutrophils. Also, ascorbic acid reduces reactive oxidant species intracellular and extracellular, and maintains transition metals in reduced form, and may quench free radical intermediates of carcinogen metabolism. Ascorbic acid is an outstandingly powerful antioxidant that reacts rapidly with a variety of oxidants, including the rather poorly reactive superoxide anion radical (16).

In this study, invasive blood pressure levels of the control and treatment groups were nearly normalized by 60 minutes after transplantation.

During the operation, it has encountered bilateral renal arteries. According to the reports, about 15% of cases have bilateral multiple renal arteries in human beings (2,25). So the technique of bridging renal arteries were used. This technique is useful in those cases where both the arteries have adjacent origins from the aorta and run parallel to each other without a great disparity size. Using a 6-0 polypropylene continuous suture, one-third of the adjacent circumference of both the renal arteries is sutured together and the thread tied at both the ends (2).

However, multiple renal arteries no longer present a surgical dilemma and have been successfully used without increased intra-operative or post-operative complications (2). A number of techniques have been used for the safe and successful management of these variations (3).

Therefore, the technique of bridging of renal arteries has been used in this study, and complications were not observed after anastomosis of renal arteries. In one study, the authors determined whether the use of kidney allografts with multiple renal arteries adversely effects post-transplant graft and patient outcome or increases the incidence of vascular and urologic complications. Kidney transplants using allograft with multiple versus single arteries are similar (3).

In histopathological findings, the treatment group revealed less damage of tubules than the control group. In treatment group, cellular structure of tubular system showed rapidly recovery as well as preservation of normal cellular integrity. Many studies showed that an inflammatory response induced by ischemia followed by reperfusion was largely responsible for tissue damage (28,30). This may reduce subsequent host inflammatory responses after renal transplantation (30).

In this study, an inflammatory response demonstrated slight damage of tubules in the treatment group. Although irreversible damage of tubular system was showed in some pigs of both groups, it was thought that it was considerable whether it was due to surgical problems or intensive care unit condition about pig feeding area. It is confirmed these things

throughout serum renal function and histopathology of kidney. Therefore, it may be suggested that further study should be preformed with more samples. We used 6 pigs both of control and treatment groups, but if it has more samples for further study, it can get rid of samples due to surgical or aftercare problem. Then, it can take an accurate measurement of antioxidant activity such as SOD, GSPHx and CAT.

There was also a significant increase in BUN, creatinine revealed in control group, in which most of the pigs were oliguric or anuric and suffered from renal failure nearly 7 days ($P<0.05$). Moreover, the change in general patient conditions also significantly decreased from one week prior to euthanasia due to physiologic problem such as anorexia and reluctant to eat, while the pigs in treatment group were not particularly change prior to euthanasia after 1 week of operation ($P<0.05$). Generally, ascorbic acid and alpha-tocopherol therapy (treatment group) recovered more rapidly renal graft function than control group. These results of the functional parameters and histopathological changes suggest that the exogenous ascorbic acid and alpha-tocopherol pretreatment therapy with ascorbic acid irrigation-aspiration has a role of attenuation of renal IRI and recovery of renal function in pig transplantation model.

Acknowledgements

This work was supported by grant No. R11-2002-100-04006-0 from ERC program of the Korea Science & Engineering Foundation.

References

1. Aragno M, Cutrin JC, Mastrocola R, Perrelli MG, Restivo F, Poli G, Danni O, Boccuzzi G. Oxidative stress and kidney dysfunction due to ischemia/reperfusion in rat: attenuation by dehydroepiandrosterone. *Kidney Int* 2003; 64: 836-843.
2. Bartel M, Richter S, Wagner W, Clausner G. Surgical intervention in stenoses and aneurysms of the renal artery. *Zentralbl Chir* 1989; 19: 1259-1268.
3. Benedetti E, Troppmann C, Gillingham K, Sutherland DE, Payne WD, Dunn DL, Matas AJ, Najarian JS, Grussner RW. Short- and long-term outcomes of kidney transplants with multiple renal arteries. *Ann Surg* 1995; 221: 406-414.
4. Bieri JG. Vitamin E. In: Present knowledge in nutrition. International Life Sciences Institute: Washington DC. 1990: 117-121.
5. Brasile L, Stubenitsky BM, Booster MH, Lindell S, Araneda D, Buck C, Bradfield J, Haisch CE, Kootstra G. Overcoming severe renal ischemia: the role of ex vivo warm perfusion. *Transplantation* 2002; 73: 897-901.
6. Casanova D, Correas M, Moran JL, Salas E, Amado JA, Garcia Unzueta MT, Berrazueta JR. Nitric oxide in cold and warm ischemia reperfusion renal transplantation. *Transplant Proc* 2002; 34: 45-46.
7. Chade AR, Rodriguez-Porcel M, Herrmann J, Krier JD, Zhu X, Lerman A, Lerman LO. Beneficial effects of

- antioxidant vitamins on the stenotic kidney. *Hypertension* 2003; 42: 605-612.
8. Clarkson PM, Thompson HS. Antioxidant: what role do they play in physical activity and health? *Am J Clin Nutr* 2000; 72: 637-646.
 9. Daemen MA, van't Veer C, Denecker G, Heemskerk VH, Wolfs TG, Clauss M, Vandenameele P, Buurman WA. Inhibition of apoptosis induced by ischemia-reperfusion prevents inflammation. *J Clin Invest* 1999; 104: 541-549.
 10. Demirbas M, Samli M, Aksoy Y, Guler C, Kilinc A, Dincel C. Comparison of changes in tissue oxidative-stress markers in experimental model of open, laparoscopic, and retroperitoneoscopic donor nephrectomy. *J Endourol* 2004; 18: 105-108.
 11. Frei B, Stocker R, Ames BN. Antioxidant defenses and lipid peroxidation in human blood plasma. *Proc Natl Acad Sci* 1988; 85: 9748-9752.
 12. Gianello P, Saliez A, Bufkens X, Pettinger R, Misseleyn D, Hori S, Malfroy B. EUK-134, a synthetic superoxide dismutase and catalase mimetic, protects rat kidneys from ischemia-reperfusion-induced damage. *Transplantation* 1996; 62: 1664-1666.
 13. Goujon JM, Hauet T, Menet E, Levillain P, Babin Ph, Carretier M. Histological evaluation of proximal tubule cell injury in isolated perfused pig kidneys exposed to cold ischemia. *J Surg Res* 1999; 82: 228-233.
 14. Halliwell B. Free radicals, reactive oxygen species and human disease: a critical evaluation with special reference to atherosclerosis. *Br J Exp Pathol* 1989; 70: 737.
 15. Hauet T, Mothes D, Goujon JM, Caritez JC, Carretier M, Le Moyec L, Eugene M, Tillement JP. Trimetazidine prevents renal injury in the isolated perfused pig kidney exposed to prolonged cold ischemia. *Transplantation* 1997; 64: 1082-1086.
 16. Iheanacho EN, Stocker R, Hunt NH. Redox metabolism of vitamin C in blood of normal and malaria-infected mice. *Biochim Biophys Acta*. 1993; 1182: 15-21.
 17. Jefayri MK, Grace PA, Mathie RT. Attenuation of reperfusion injury by renal ischaemic preconditioning: the role of nitric oxide. *BJU Int* 2000; 85: 1007-1013.
 18. Kaczmarek M, Wojcicki J, Samochowiec L, Dutkiewicz T, Sych Z. The influence of exogenous antioxidants and physical exercise on some parameters associated with production and removal of free radicals. *Pharmazie* 1999; 54: 303-306.
 19. Kaneko H, Schweizer RT. Venous flushing with vasodilators aids recovery of vasoconstricted and warm ischemic injured pig kidneys. *Transplant Proc* 1989; 21: 1233-1235.
 20. Kehrer JP. Free radicals as mediators of tissue injury and disease. *Crit Rev Toxicol* 1993; 23: 21-48.
 21. Matsuno T, Sasaki H, Ishido N, Nakagawa K, Ishikawa T, Oishi A, Inagaki M, Saito S, Yagi T, Haisa M, Tanaka N, Orita K. Apoptosis in human kidney allograft. *Transplant Proc* 1996; 28: 1226-1227.
 22. Nath KA, Paller MS. Dietary deficiency of antioxidants exacerbates ischemic injury in the rat kidney. *Kidney Int* 1990; 38: 1109-1117.
 23. Nita DA, Nita V, Spulber S, Moldovan M, Popa DP, Zagrean AM, Zagrean L. Oxidative damage following cerebral ischemia depends on reperfusion – a biochemical study in rat. *J Cell Mol Med*. 2001; 5: 163-170.
 24. Noiri E, Peresleni T, Miller F, Goligorsky MS. In vivo targeting of inducible NO synthase with oligodeoxynucleotides protects rat kidney against ischemia. *J Clin Invest* 1996; 97: 2377-2383.
 25. Sarin PK, Dhanda R, Siwach V, Aggarwal B, Singh B, Kaur R, Jain PK. Bridging of renal arteries: a simple technique for the management of double arteries in living donor renal allograft transplantation. *Transplant Proc* 2003; 35: 35-36.
 26. Schumer M, Colombel MC, Sawczuk IS, Gobe G, Connor J, O'Toole KM, Olsson CA, Wise GJ, Buttyan R. Morphologic, biochemical, and molecular evidence of apoptosis during the reperfusion phase after brief periods of renal ischemia. *Am J Pathol* 1992; 140: 831-838.
 27. Sekhon CS, Sekhon BK, Singh I, Orak JK, Singh AK. Attenuation of renal ischemia/reperfusion injury by a triple drug combination therapy. *J Nephrol* 2003; 16: 63-74.
 28. Takada M, Nadeau KC, Shaw GD, Marquette KA, Tilney NL. The cytokine-adhesion molecule cascade in ischemia/reperfusion injury of the rat kidney. Inhibition by a soluble P-selectin ligand. *J Clin Invest*. 1997; 99: 2682-2690.
 29. Toll PW, Novotny BJ. Oxidative Stress and the Antioxidant Defense System: An Overview for Practicing Veterinarians. LLC Shawnee: Kansas. 2001: 2-14.
 30. Vedder NB, Winn RK, Rice CL, Chi EY, Arfors KE, Harlan JM. Inhibition of leukocyte adherence by anti-CD18 monoclonal antibody attenuates reperfusion injury in the rabbit ear. *Proc Natl Acad Sci USA* 1990; 87: 2643-2646.
 31. Walker LM, York JL, Imam SZ, Ali SF, Muldrew KL, Mayeux PR. Oxidative stress and reactive nitrogen species generation during renal ischemia. *Toxicol Sci* 2001; 63: 143-148.
 32. Wamser P, Asari R, Goetzinger P, Mayer G, Berlakovich G, Soliman T, Muehlbacher F, Steininger R. Detrimental effects of controlled reperfusion on renal function after porcine autotransplantation are fully compensated by the use of Carolina rinse solution. *Transpl Int* 2003; 16: 191-196. 2003.

돼지의 신장 자가이식에서 Ascorbic Acid와 Alpha-tocopherol 의한 허혈 및 재관류 손상의 감소

김명진 · 이재연 · 조성환 · 박창식* · 전무형 · 정성묵 · 김명철¹

충남대학교 수의과대학, *충남대학교 동물자원과학부 형질전환복제돼지연구센터

요 약 : 본 연구의 목적은 돼지의 신장 자가이식에서 항산화제에 의한 허혈 및 재관류 손상의 감소에 대하여 ascorbic acid와 alpha-tocopherol이 미치는 영향을 평가하는 데 있다. 6두의 어린 돼지에 자가 신장 이식을 실시하였으며, 처치군에서는 수술 2일전 비타민 C와 E를 이틀 동안 전처치 하고, 그 뒤에 수술 중 비타민 C와 heparin이 첨가된 생리 식염수를 절제되어 자가 이식할 신장에 관주하였다. 대조군에서는 수술 중 heparin이 첨가된 생리 식염수만을 절제되어 자가 이식할 신장에 관주하였다. 신장 기능을 평가하기 위하여 혈액 샘플을 채취하였으며, 수술 전, 수술 후 1, 3, 7, 14일에 혈청 creatinine과 BUN을 측정하였다. 그리고 병리조직 검사를 위해 14일 후 신장을 적출 보관하였다. 신장의 기능 검사에서 대조군과 처치군 사이에서 전체적인 유의성은 없었지만, 1일째, 3일째 또는 5일째에 두 그룹간의 유의적인 차이가 인정되었다 ($p < 0.05$). 병리조직 검사 결과 처치군이 대조군 보다 더 적은 조직 손상의 정도를 보였다. 이러한 결과는, 비타민 C와 heparin을 이용한 신장의 관주 및 흡인의 과정이 신장의 허혈 및 재관류 손상을 감소시키는 데에 효과가 있었음을 시사하며, 이는 돼지의 신장 자가 이식에서 허혈 및 재관류의 손상을 감소시키며 신기능의 회복에 효과가 있음을 시사하는 바이다.

주요어 : ascorbic acid, alpha-tocopherol, 돼지, 신장이식, 항산화제.