

Clinical Efficacy of Pimobendan on Dogs with Chronic Mitral Valvular Diseases

So-Jeong Nam, In-Chul Park* and Changbaig Hyun¹

Section of Small Animal Internal Medicine, School of Veterinary Medicine, Kangwon National University, Chuncheon 201-100, Korea

*Section of Diagnostic Imaging, School of Veterinary Medicine, Kangwon National University, Chuncheon 201-100, Korea

(Accepted : January 29, 2009)

Abstract : Pimobendan is a recently developed cardiac drug which is useful to control moderate to severe congestive heart failure (CHF) from chronic mitral valvular diseases (CMVI). Because of controversy related to the efficacy and safety of pimobendan in dogs, the optimal efficacy and safety of pimobendan was assessed in 20 dogs with CMVI in this study. Scores for quality of life, respiratory failure, circulatory failure and heart failure were evaluated along with radiographical and echocardiographical assessments for about 2 months period after the addition of pimobendan into the regular cardiac medications. This study proved clear evidence that pimobendan had beneficial therapeutic effects in dogs with advanced CMVI, without particular adverse effects. However, further studies are warranted to address the drug interaction with other cardiac therapeutics and to assess therapeutic effects in CHF from other type of heart diseases in dogs and other animals.

Key words : pimobendan, heart failure, mitral valvular disease, CMVI, dog.

Introduction

Chronic mitral valvular insufficiency (CMVI) is a type of aging related degenerative diseases in dogs which is characterized by a myxomatous degenerative change in the mitral valve leaflets and chordae tendineae in middle-aged to elderly dogs, although it is a inherited heart disease in a certain breed of dogs (e.g. King Charles Cavalier Spaniel) (1,10). CMVI is responsible for up to 75 % of the cardiovascular diseases in dogs and is more commonly occurred in smaller dog breeds (9,13). The regurgitant flow from the left ventricle (LV) to the left atrium (LA) due to incomplete closure of mitral valves results in eccentric hypertrophy in LA and LV, which leads to left-sided congestive heart failure often accompanied with life-threatening pulmonary edema (11).

Although mild mitral regurgitation may not require immediate treatment, the dog with CMVI is necessary to treat with diuretics, angiotensin converting enzyme inhibitors (ACEi) and inotropes depending on the severity of decompensation, if the dog shows overt clinical signs (e.g. dyspnea, coughing, exercise intolerance) related to congestive heart failure (CHF) secondary to CMVI. Recent canine drug trial studies found the use of ACEi was associated with a relative improvement of quality of life and prolongation of the time to death (16,18), compared to placebo. Several drug trial studies related to phosphodiesterase III inhibitor (e.g.

pimobendan) also found the use of pimobendan was associated with a significant improvement in both clinical signs and quality of life, and prolongation of the time to death (4,7,14,16,21). Furthermore, several studies comparing pimobendan with ACEi for therapeutic efficacy found that the better clinical outcome was achieved in dogs receiving pimobendan than in those receiving ACEi (7,16).

Due to debate related to the efficacy and safety of pimobendan in dogs with CMVI, the optimal efficacy and safety of pimobendan was assessed in this study, to clarify the debate.

Materials and Methods

Dogs

Twenty dogs (8 males and 12 females) with chronic mitral valvular disease (CMVI), weighed under 7 kg (4.25 ± 1.55 kg) were enrolled in this study. Inclusion criteria for being eligible for this study were 1) the dog must have been older than 5 years of age (12.2 ± 2.75 years), 2) had a characteristic heart murmur of moderate to high intensity with maximal intensity over the mitral area, 3) had echocardiographic evidence of advanced CMVI (e.g. $>1/2$ mitral regurgitation flow on color Doppler echocardiography, left atrial to aortic root [LA/Ao] ratio >1.59 on M-mode echocardiography), and > 1.5 fold increased *NCX-1* gene expression in real-time PCR (17,21). Dogs were excluded from the study if they had other cardiac diseases (e.g. congenital heart defects) or other systemic diseases evident on routine biochemistry.

¹Corresponding author.

E-mail : hyun5188@kangwon.ac.kr

Test treatments

Standard concomitant therapy for heart failure (such as diuretics, enalapril and digoxin) was permitted. Pimobendan (Vetmedin[®], Boehringer Ingelheim, Germany) was administered at a dose of 0.25-0.3 mg/kg, twice per day, approximately 30-60 min before feeding.

Schedule of events

Before enrolling this study, all dogs were reviewed for assessing suitability (e.g. case history, radiographs, and laboratory results). The dogs then underwent a physical examination, electrocardiography (ECG), echocardiography, thoracic radiography, and routine hematology and blood biochemis-

Table 1. Scoring protocol for clinical variables

| Variable | Score | Clinical Correlate |
|-------------------------------------|---------------|--|
| Exercise tolerance | 1 (Very good) | Dog moved around with ease, was able to fully exercise |
| | 2 (Good) | Dog moved around with ease, was not able to fully exercise; ability to run was reduced |
| | 3 (Moderate) | Dog was less active than normal, moved around a few times per day, avoided long walks |
| | 4 (Poor) | Dog was inactive and would only get up to eat, drink, or urinate |
| Demeanor | 1 | Alert, responsive |
| | 2 | Mildly lethargic |
| | 3 | Moderately lethargic |
| | 4 | Minimally responsive |
| | 5 | Unresponsive |
| Appetite | 1 | Increased |
| | 2 | Normal |
| | 3 | Decreased(2/3 normal) |
| | 4 | Markedly decreased(<2/3 normal) |
| Respiratory effort | 1 | Normal |
| | 2 | Mildly increase rate and effort |
| | 3 | Moderately labored |
| | 4 | Severe respiratory distress |
| Coughing | 1 | None |
| | 2 | Occasional (a few times a week) |
| | 3 | Frequent (a few times a day) |
| | 4 | Persistnet (frequently during the day) |
| Nocturnal dyspnea | 1 | None |
| | 2 | Dog coughed from time to time during the night, but no other clinical signs of dyspnea or restlessness were present |
| | 3 | Dog coughed consistently; increased respiratory effort or restlessness during the night |
| Pulmonary edema | 1 | None |
| | 2 | Mild interstitial opacity |
| | 3 | Moderate interstitial opacity |
| | 4 | Alveolar pattern, severe consolidation |
| ISACHC heart failure classification | 1 (IA) | Heart disease present; no clinical signs; no signs of compensation (no left ventricle volume overload) |
| | 2 (IB) | Heart disease present; no clinical signs; signs of compensation on echocardiography or radiography (e.g. left ventricle volume overload or left atrial enlargement) |
| | 3 (II) | Heart disease present, with mild or moderate signs of heart failure; clinical signs of backward failure on exertion or excitement; at rest, no clinical evidence of poor systolic function; treatment is indicated |
| | 4 (IIIA) | Heart disease present, with cliniclca signs of advanced heart failure; clinical signs even at rest; cardiomegaly apparent on echocardiography or radiography; death or severe debilitation likely without treatment; home treatment is possible |
| | 5 (IIIB) | Heart disease present, with clinical signs of advanced heart failure; clinical sings even at rest; cardiomegaly apparent on echocardiography or radiography; death or severe debilitation likely without treatment; hospitalisation and intensive care treatment is required |

ISACHC, International Small Animal Cardiac Health Council

try with a minimal database consisting of PCV and total protein, blood urea, creatinine, potassium, chloride and sodium concentrations. Scheduled reexaminations were at day 7, and 56 after inclusion.

Clinical evaluation

The time since onset of clinical signs and the duration, type, and efficacy of any pretreatment were recorded.

Quality of life and respiratory variables

After history taking and clinical examination, the following variables were scored according to the system outlined in Table 1.

Circulatory variables

The resting heart rate was measured during the physical examination. A 3-minute ECG recording was performed with the dogs lying in right lateral recumbency.

Diagnostic imaging

Echocardiography and thoracic radiography were used to evaluate the progression of CMVI. Right lateral and dorsoventral projections were used for thoracic radiography. Cardiomegaly was assessed with the vertebral heart scale method and the presence of pulmonary edema was scored (Table 1). For echocardiography, the diameter of left atrium, the LA/Ao ratio, the left ventricular internal diameter in diastole (LVIDd), left ventricular internal diameter in systole (LVIDs), end systolic volume index (ESVI), end diastolic volume index (EDVI) and the fractional shortening (%FS) were measured as described in elsewhere (2,20). The percent decrease in each cardiac index was calculated as follows: % decrease = [baseline value (day 0) – measured value (at day 7 and day 56) / baseline value] × 100.

Heart failure score

International Small Animal Cardiac Health Council (ISACHC) score was used to score the severity of heart failure (Table 1).

Assessment of potential adverse effects

Any side effects from pimobendan treatment including gastrointestinal signs (e.g. vomiting, diarrhea, anorexia), abnormal behavior (e.g. lethargy, confusion, uneasiness), neurological signs (e.g. seizure), and electrocardiological signs (e.g. QT prolongation, PR prolongation).

Statistical analysis

Statistical analysis was performed, using one-way ANOVA within treatment group as a between-animal factor and time as a within-animal, repeated-measures factor to determine whether significant differences existed in data for quality of life and respiratory failure score, circulatory failure score, diagnostic imaging study variables (LA:Ao ratio, LA diameter, LVIDd, LVIDs, % FS, ESVI, EDVI, VHS score) over time from the baseline values. When appropriate, a post hoc multiple comparisons *t*-test was applied within groups, using the Bonferroni correction to keep the experimental error rate at $p < 0.05$. Within-group comparison was done to the base-

line values (day 0, day 7, day 56) at each subsequent time point, respectively. All statistical analyses were performed by use of statistical computer software (SAS, USA).

Results

Clinical evaluation

Quality of life score

Overall score of quality of life was greatly improved after the addition of pimobendan into therapeutic regime (Fig 1). At day 7 after the addition of pimobendan, the appetite and demeanor scores were markedly improved ($p < 0.05$), although further improvement was not clearly evident at day 56. However, the exercise intolerance score persistently improved at day 7 and day 56 ($p < 0.05$), compared to the baseline score measured before the addition of pimobendan.

Respiratory failure score

Overall respiratory score was also markedly reduced after the addition of pimobendan into therapeutic regime (Fig 2). Improvement of respiratory failure signs (e.g. respiratory effort, cough, nocturnal dyspnea, restless) was clearly evident at day 7 and more obvious at day 56 after pimobendan treatment ($p < 0.05$). With improvement of clinical signs,

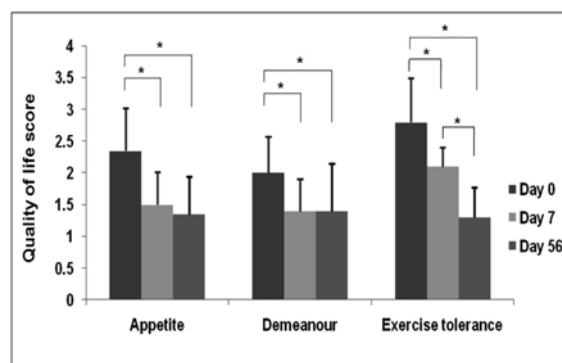


Fig 1. Changes in quality of life score after pimobendan treatment in dogs with chronic mitral valvular disease. * $p < 0.05$.

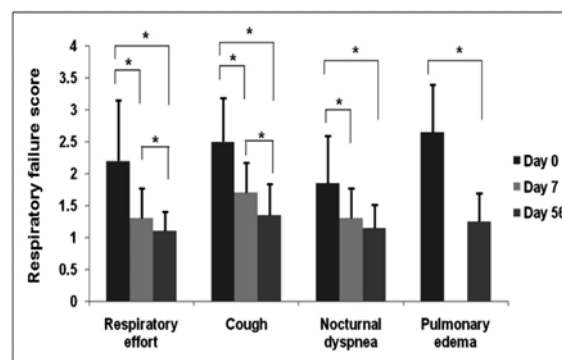


Fig 2. Changes in respiratory failure score after pimobendan treatment in dogs with chronic mitral valvular disease. Degree of pulmonary edema was assessed by thoracic radiography. * $p < 0.05$.

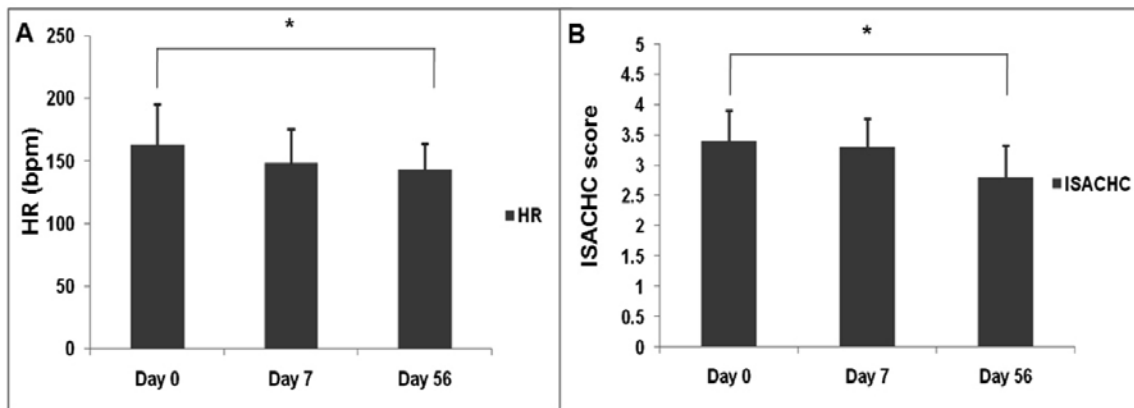


Fig 3. Changes in circulatory failure score after pimobendan treatment in dogs with chronic mitral valvular disease. * $p < 0.05$.

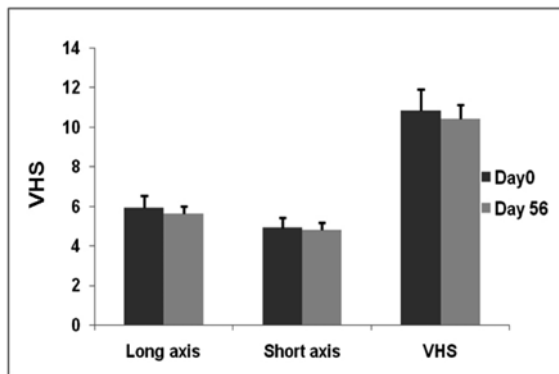


Fig 4. Changes in thoracic radiographical score (cardiomegaly) after pimobendan treatment in dogs with chronic mitral valvular disease. VHS= vertebral heart scale. * $p < 0.05$.

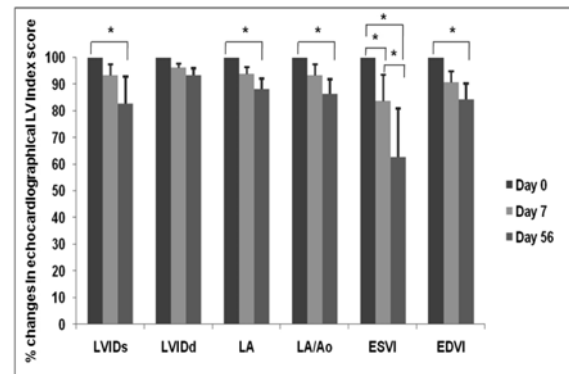


Fig 5. Percentile (%) changes in echocardiographical left ventricular performance score after pimobendan treatment in dogs with chronic mitral valvular disease. * $p < 0.05$.

radiographical evidence of pulmonary edema causing respiratory failure was remarkably reduced after pimobendan treatment.

Circulatory failure score

Heart rate variability (e.g increased heart rate) is a sign of decompensation of heart failure. Average of heart rate after pimobendan treatment was reduced at day 7 and 56 (Fig 3A). Although the reduction of heart failure scores (ISACHC score) was not clearly evident at day 7, the obvious reduction of ISACHC score was achieved at day 56 ($p < 0.05$; Fig 3B).

Diagnostic imaging study variables

No statistically significant improvement of VHS score, including long and short axis score, was observed in the thoracic radiography after pimobendan treatment (Fig 4). Overall improvement of echocardiographical left ventricular performance (except LVIDd and %FS) was clearly observed at day 56 after pimobendan treatment (Fig 5). At day 7, a statistically significant improvement of left ventricular performance was only noticed in ESVI ($p < 0.05$), although other indices were also improved.

Assessment of potential adverse effects

No dogs except one dog showed particular adverse effects

from pimobendan during the test period. One dog showed restless without evidence of neurological problems after the initiation of pimobendan treatment for the first week (day 7). However, the dog was returned to normal from the following weeks to the last week of evaluation (day 56). On the electrocardiographical examination before (day 0) and after pimobendan treatment (day 56), there was no significant changes in QT and PR interval. Furthermore no particular electrocardiographical abnormalities were found in association with pimobendan treatment.

Discussion

Pimobendan is a benzimidazole-pyridazinone derivatives which has two distinct properties in dogs: positive inotropic (through myocardial calcium sensitization) and vasodilator properties (through phosphodiesterase III and V inhibition in vascular smooth muscle) (3,5,6,15). Recent several pimobendan trial studies have proved beneficial effects in dogs with advanced dilated cardiomyopathy or mitral valve disease, in case that pimobendan was administered along with other cardiac drugs, such as ACE inhibitors, furosemide, or digoxin (4,7,14,16,21). Beneficial effects from pimobendan in dogs

with CMVI may obtain from increased left ventricular contractility from myocardial calcium sensitizing property and reduced ventricular preload and afterload from arterial dilation. Currently, pimobendan is approved for use in CHF dogs from CMVI or dilated cardiomyopathy (DCM) in some countries (e.g. Europe, Canada, Mexico, and Australia).

Our study design for the evaluation of pimobendan in dogs with CMVI was similar to VetSCOPE trial for pimobendan conducted by Lombard and colleagues and was published in 2006 (16), although we did not directly compare therapeutic effects from pimobendan with ACEi (e.g. enalapril or benazepril). In our study, we evaluated the quality of life, the severity of respiratory and circulatory failures, radiographical and echocardiographical parameters for CMVI after treatment of pimobendan along with other cardiac therapeutics. As noticed in earlier studies (7,16), detectable improvement of clinical scores (e.g. quality of life, respiratory and circulatory failure) was noticed at day 7 and day 56 after the addition of pimobendan into therapeutic regimes in dogs with CMVI. Furthermore, the improvement of clinical score was confirmed by radiographical and echocardiographical evaluation after pimobendan treatment. Although the degree of cardiomegaly was not significantly reduced after treatment, the degree of pulmonary edema was statistically significantly reduced ($p < 0.05$) after treatment in the radiographical evaluation. The echocardiographical studies also revealed the evident improvement in left ventricular systolic function (e.g. LVIDs and ESVI) and the reduction in left atrial and ventricular preload (e.g. LVIDd, EDVI, LA diameter and LA:Ao ratio) at day 7 and 56 after pimobendan treatment.

Known objective methods for evaluating the severity and progression of CHF from CMVI are heart rate augmentation, degree of mitral valvular prolapse, amount of mitral regurgitant jet flow, LA:Ao ratio, and more recently percentile increase of ESVI in dogs (8,20,22). Recent studies found that echocardiographical assessment (e.g. amount of mitral regurgitant jet flow, LA:Ao ratio, ESVI) was more accurate and sensitive index for evaluating the severity and progression of CMVI in dogs (20,22). In our study, the statistically significant reduction in ESVI was noticed from day 7 after pimobendan treatment, although other echocardiographical parameters also favorably reduced. This suggested the beneficial therapeutic effect might start from the improved left ventricular systolic function. Statistically significant improvement in other echocardiographical parameters except %FS was more clearly evident from day 56, suggesting that the beneficial therapeutic effect from pimobendan might be time-dependent, so that pimobendan should be administered for certain period of time, to achieve therapeutic effects in dogs with CMVI.

Potential adverse effects from long-term use of pimobendan in dogs have been reported, although all reported side-effects were self-limiting and were not critical (7). The reported adverse effects were gastrointestinal signs (6/252 dogs), abnormal behavior (3/252), seizure (3/252) and

hepatic enzyme elevation (2/252). Two other studies also warned pimobendan could induce dose-related sinus tachycardia and could develop or worsen ventricular tachyarrhythmias (3,19). However, one anecdotal report from the University of Georgia Veterinary Teaching Hospital (12) indicated that pimobendan was virtually free of overt adverse effects in dogs with either DCM or CMVI, based on the data prescribing pimobendan in more than 100 dogs. There were no remarkable adverse effects from dogs having pimobendan in this study, although one dog showed transient restless after pimobendan treatment. Furthermore we could not find any evidence indicating increase in sino-atrial firing (causing sinus tachycardia) and Q-T prolongation (causing ventricular tachyarrhythmias) after pimobendan treatment.

Our study limitations were that i) the study period was too short to evaluate long-term therapeutic and adverse effects in dogs with CMVI from pimobendan treatment, ii) this study was not a survival study so that we could not evaluate whether the pimobendan might decrease mortality from CMVI and might lengthen survival period after pimobendan treatment, iii) this study was not a placebo-controlled blinded study so that we could not clearly declare the significant improvement in clinical scores and echocardiographical parameters might be entirely achieved from the pimobendan alone or interactive effects with other cardiac therapeutics administered concurrently. Therefore the long-term and more controlled study is required to clarify these study limitations.

In conclusion, this study provides clear evidence that pimobendan has beneficial therapeutic effects in dogs with advanced CMVI, without particular adverse effects. However, further studies are warranted to address the drug interaction with other cardiac therapeutics and to assess therapeutic effects in CHF from other type of heart diseases in dogs and other animals.

References

1. Beardow AW, Buchanan JW. Chronic mitral valve disease in cavalier King Charles spaniels: 95 cases (1987–1991). *J Am Vet Med Assoc* 1993; 203: 1023–1029.
2. Bonagura JD, Herring DS. Echocardiography; Acquired heart disease. *Vet Clin North Am Small Anim Pract*. 1985; 15: 1209-1224.
3. Chu KM, Shieh SM, Hu OY. Pharmacokinetics and pharmacodynamics of enantiomers of pimobendan in patients with dilated cardiomyopathy and congestive heart failure after single and repeated oral dosing. *Clin Pharmacol Ther* 1995; 57: 610-621.
4. Fuentes VL, Corcoran B, French A, et al. A double-blind, randomized, placebo-controlled study of pimobendan in dogs with dilated cardiomyopathy. *J Vet Intern Med* 2002; 16: 255-261.
5. Fuentes VL. Use of pimobendan in the management of heart failure. *Vet Clin North Am Small Anim Pract* 2004; 34: 1145-1155.
6. Hagemeyer F. Calcium sensitization with pimobendan: pharmacology, haemodynamic improvement, and sudden

- death in patients with chronic congestive heart failure. *Eur Heart J* 1993; 14: 551-566.
7. Häggström J, Boswood A, O'Grady M, Jöns O, Smith S, Swift S, Borgarelli M, Gavaghan B, Kresken JG, Patteson M, Ablad B, Bussadori CM, Glaus T, Kovačević A, Rapp M, Santilli RA, Tidholm A, Eriksson A, Belanger MC, Deinert M, Little CJ, Kvart C, French A, Rønn-Landbo M, Wess G, Eggertsdottir AV, O'Sullivan ML, Schneider M, Lombard CW, Duker-McEwan J, Willis R, Louvet A, Difruscia R. Effect of pimobendan or benazepril hydrochloride on survival times in dogs with congestive heart failure caused by naturally occurring oxomatous mitral valve disease: The QUEST study. *J Vet Intern Med* 2008; 22: 1124-1135.
 8. Haggstrom J, Hamlin RL, Hansson K. Heart rate variability in relation to severity of mitral regurgitation in Cavalier King Charles spaniels. *J Small Anim Pract* 1996; 37: 69-75.
 9. Haggstrom J, Kvart C, Pedersen HD. Acquired valvular heart disease. In: *Textbook of Veterinary Internal Medicine*, 6th ed. St Louis: Elsevier. 2005: 1022-1039.
 10. Hyun C. Mitral valve prolapse in Cavalier King Charles spaniel: a review and case study. *Vet Sci* 2005; 6: 67-73
 11. Hyun C. Valvular disease. In: *Textbook of Small Animal Cardiology*, Seoul: Panmoon Publishing. 2005: 185-206.
 12. Justin D, Thomason, Tiffany K, Fallaw, Clay A, Calvert. Pimobendan: Understanding its cardiac effects in dogs with myocardial disease. *Vet Med* 2006: 660-667.
 13. Kittleson MD, Kienle RD. Myxomatous atrioventricular valvular degeneration. In: *Small Animal Cardiovascular Medicine*. St Louis: Mosby. 1998: 297-318.
 14. Kleeman R, Lebobinnee G, Bruyere D. Clinical efficacy of the novel inodilator pimobendan in dogs suffering from congestive heart failure, in *Proceedings. Br Small Anim Vet Congress* 1998.
 15. Lefbon BK. Sildenafil and novel cardiovascular therapies, in *Proceedings. Am Coll Vet Intern Med* 2005; 75-80.
 16. Lombard CW, Jons O, Bussadoril CM. Clinical efficacy of pimobendan versus benazepril for the treatment of acquired atrioventricular valvular disease in dogs. *J Am Anim Hosp Assoc* 2006; 42: 249-261.
 17. Moon HS, Choi E, Hyun C. The cardiac sodium-calcium exchanger gene (NCX-1) is a potential canine cardiac biomarker of chronic mitral valvular insufficiency. *J Vet Intern Med* 2008; 22: 1360-1365.
 18. Pouchelon JL, Jamet N, Gouni V, Tissier R, Serres F, Carlos Sampedrano C, Castaignet M, Lefebvre HP, Chetboul V. Effect of benazepril on survival and cardiac events in dogs with asymptomatic mitral valve disease: a retrospective study of 141 cases. *J Vet Intern Med*. 2008; 22: 905-914.
 19. Rosenthal SL, Ferguson MJ, Lefbom BK. Association of pimobendan with ventricular arrhythmias in dogs with congestive heart failure, in *Proceedings. Am Coll Vet Intern Med* 2006; 110-115.
 20. Serres F, Chetboul V, Tissier R, Poujol L, Gouni V, Carlos Sampedrano C, Pouchelon JL. Comparison of 3 ultrasound methods for quantifying left ventricular systolic function: correlation with disease severity and prognostic value in dogs with mitral valve disease. *J Vet Intern Med*. 2008; 22: 566-577.
 21. Smith PJ, French AT, Van Israel N. Efficacy and safety of pimobendan in canine heart failure caused by myxomatous mitral valve disease. *J Small Anim Pract* 2005; 46: 121-130.
 22. Wess G. Assessment of left ventricular systolic and diastolic function in canine myxomatous mitral valve disease using myocardial tissue Doppler imaging. In: *International canine valvular disease symposium*, Stockholm, Sweden. 2008: 44-45.

만성 이첨판 폐쇄부전증 이환된 견에서 피모벤단의 임상적 효과

남소정 · 박인철* · 현창백¹

강원대학교 수의(학부)대학 소동물 내과교실, *강원대학교 수의(학부)대학 방사선학 교실

요약 : 피모벤단은 최근에 발견되어, 만성 이첨판 폐쇄부전증에 의한 중등도에서 심한 울혈성 심부전을 관리하는데 유용하게 사용되는 심장성 약물이다. 아직까지 견에서 피모벤단의 효능과 안전성에 대한 의견이 분분하다. 따라서 본 연구는 최적의 효능과 안전성을 알아보기 위하여 만성 이첨판 폐쇄부전증에 이환된 20마리의 견을 평가하였다. 일반적인 심장 약물 처방에 피모벤단을 추가한 뒤 삶의 질, 호흡부전, 순환부전과 심부전의 상태를 방사선과 심초음파 검사와 함께 두 달간 평가하였다. 본 연구에서는 진행된 만성 이첨판 폐쇄부전증에 이환된 견에서 피모벤단이 특별한 부작용 없이 긍정적인 치료 효과를 보이는 것으로 나타났다. 그러나 다른 심장 처방약과 피모벤단의 상호 작용 효과에 중점을 둔 연구와 이첨판 폐쇄부전증이 아닌 다른 심장질환에 의한 견과 다른 동물의 심부전에 어떠한 치료효과를 보이는지 평가하는 추가적인 연구가 필요할 것이다.

주요어 : 피모벤단, 심부전, 만성 이첨판 폐쇄부전증, 견.