

원저

형태 계측학적 분석과 ThinPrep® 액상 소변세포검사를 이용한 악성 요로상피 세포 검출

고려대학교 구로병원 병리과,¹ 고려대학교 구로병원 동결폐조직은행²

신봉경^{1,2} · 이 영석¹ · 정희선^{1,2} · 이상호^{1,2} · 김현철¹ · 김애리^{1,2} · 김인선¹ · 김한겸^{1,2}

Detecting Malignant Urothelial Cells by Morphometric Analysis of ThinPrep® Liquid-based Urine Cytology Specimens

Bong Kyung Shin, M.D.,^{1,2} Young Suk Lee, M.D.,¹
Hoiseon Jeong, M.D.,^{1,2} Sang Ho Lee, M.D.,^{1,2}
Hyunchul Kim, M.D.,¹ Aree Kim, M.D.,^{1,2},
Insun Kim, M.D.,¹ and Han Kyeom Kim., M.D.,^{1,2}

Department of Pathology, Guro Hospital,
Korea University Medical College¹ and
Korea Lung Tissue Bank (KLTB)², Seoul, Korea

논문접수 : 2007년 7월 18일
논문수정 : 1차 : 2007년 11월 20일,
2차 : 2008년 2월 22일,
3차 : 2008년 7월 14일
게재승인 : 2008년 7월 28일

책임저자 : 김 한 겸
주 소 : (152-703) 서울 구로구 구로동 80번지,
고려대학교 구로병원 병리과
전 화 : 02-818-6872
팩 스 : 02-818-6239
E-mail address : hankkim@korea.ac.kr

*이 연구는 2006년 6월 대한세포병리학회로부터 연구비 지원을 받아 진행되었습니다.

Urothelial carcinoma accounts for 90% of all the cases of bladder cancer. Although many cases can be easily managed by local excision, urothelial carcinoma rather frequently recurs, tends to progress to muscle invasion, and requires regular follow-ups. Urine cytology is a main approach for the follow-up of bladder tumors. It is noninvasive, but it has low sensitivity of around 50% with using the conventional cytopsin preparation. Liquid-based cytology (LBC) has been developed as a replacement for the conventional technique. We compared the cytomorphometric parameters of ThinPrep® and cytopsin preparation urine cytology to see whether there are definite differences between the two methods and which technique allows malignant cells to be more effectively discriminated from benign cells. The nuclear-to-cytoplasmic ratio value, as measured by digital image analysis, was efficient for differentiating malignant and benign urothelial cells, and this was irrespective of the preparation method and the tumor grade. Neither the ThinPrep® nor the conventional preparation cytology was definitely superior for distinguishing malignant cells from benign cells by cytomorphometric analysis of the adequately preserved cells. However, the ThinPrep® preparation showed significant advantages when considering the better preservation and cellularity with a clear background.

(*Korean J Cytopathol* 2008;19(2):136-143)

Key Words : Liquid-based urine cytology, Urothelial carcinoma, Cytomorphometric analysis, Digital image analysis, Nuclear-to-cytoplasmic ratio.

INTRODUCTION

According to the report of the National Cancer Information Center of Korea in 2001, the occurrence rates of bladder cancer in Korea are 7.67 and 2.00 per

100,000 in men and women, respectively. Urothelial carcinoma was the most common histologic subtype in this report, and it comprised 81.8% of the newly diagnosed bladder tumors. Urothelial carcinoma can easily be managed by local excision when it is diagnosed

early;¹ however, these tumors recur rather frequently. According to Saad A et al., about 70% of superficial bladder urothelial carcinomas will recur in the first five years following transurethral resection (TUR), and 10-20% will progress to muscle invasion.² Therefore, those patients treated for bladder urothelial carcinoma should be closely followed up to detect recurrent diseases.

Although cystoscopy with biopsy is the gold standard for the diagnosis and follow-up of bladder cancers, this process requires the combined use of other diagnostic approaches because of the invasiveness of the cystoscopy procedure, the considerable discomfort to the patients and the inability to detect all carcinoma in situ cases and lesions of the upper urinary tract.^{3,4} Therefore, urinary cytology is another important approach for making the diagnosis and follow-up of bladder cancer. This procedure is noninvasive and quite sensitive for high grade urothelial lesions irrespective of their location in the urinary tract.^{3,4} However, urinary cytology has a mean sensitivity of just around 50% for low grade tumors urinary cytology, and this procedure is hampered by the large number of non-diagnostic samples.^{5,6}

Liquid-based cytology (LBC) using a filtration process and thin layer deposition of cells has been developed to replace the conventional cytospin preparation technique, and it is expected to improve the cell recovery capabilities and offer better cell preservation.⁵ Many studies have shown that preparation with the Cystic ThinPrep® 2000 (Cystic Corp, Boxborough, Massachusetts, USA) resulted in increased cellularity and a pronounced reduction of inflammatory debris, red blood cells and crystals.⁷⁻¹¹ However, the advantages of LBC have been questioned by other studies that compared LBC with the cytospin preparation. For example, Nassar et al., in their analysis of seventy-nine urine samples, calculated that although the ThinPrep® method was simpler to perform and it produced clean, easier-to-read slides, the cytospin preparation was more efficient for detecting malignant cells with less technical artifacts.¹² Piaton et al. also proposed that the cytocentrifugation method

still offered the highest quality for the current treatment of urinary samples, when considering both the diagnostic performance and the cost.³

For urine cytology, further investigation is needed to determine the efficiency of liquid-based cytology to detect urothelial carcinoma cells. Besides the change in preparation technique, cytomorphometric analysis of urothelial cells that includes the DNA contents, the nuclear area, the cytoplasmic area and the nuclear-to-cytoplasmic ratio has been proposed as another sensitive and specific tool for detecting malignant cells in urine cytology.^{13,14} Van der Poel et al., in their study that compared digital image analysis and conventional microscopic examination of urinary washing cytology, they measured the DNA contents and nuclear morphology of Feulgen-stained urothelial cells with using an automated image analysis system, i.e. QUANTICYT, and they concluded that cytomorphometric analysis was superior to conventional urine cytology for detecting malignant cells.¹⁴ However, van der Poel et al.'s study used bladder washing specimens instead of the conventional voided urine, and this required Feulgen-stained slides rather than the usual Papanicolaou stain, and they used the DNA content and nuclear morphology as measured by a specific karyometric system QUANTICYT as the major parameters for detecting malignant cells. When considering the invasiveness of acquiring the specimens, the requirement for specific equipment and the complex process for measuring and interpreting the morphometric parameters, van der Poel et al.'s approach may not be easily applied to the present clinical environment. Another study by Bishop and Sims evaluated the feasibility and utility of a thin-layer cytology preparation for morphometric analysis of non-gynecologic specimens, including urine. They proposed that the thin-layer preparation cytology had significant advantages for morphometric studies over the conventional preparation, although any differences of the morphologic measures were not observed between the two cytology procedures.¹³

In this study we investigated whether the cytomor-

phometric analysis of urothelial cells can adequately discriminate malignant urothelial cells from benign urothelial cells. We also compared the cytomorphometric parameters of ThinPrep® with those of cytopspin preparation urine cytology to determine whether there are definite differences between the two techniques and which technique is better for discriminating benign cells from malignant cells.

MATERIAL AND METHODS

Case Selection

Thirty-four ThinPrep® urine cytology specimens and 50 conventional cytopspin preparation urine cytology specimens were selected from the pathology files of Korea University Guro Hospital, and all of these were cytologically and histologically confirmed as urothelial carcinoma. The urine cytology specimens of 100 benign cases, (50 ThinPrep® and 50 conventional preparations) were also selected for comparison. Of the 34 ThinPrep® preparation cases of urothelial carcinoma, 17 were high-grade and 17 were low-grade tumors, while the 50 cytopspin preparation cases of carcinoma were composed of 28 high and 22 low grade tumors. All the slides were the same Papanicolaou-stained ones that were examined at the time of the original diagnostic process with conventional light microscopy.

Digital Image Analysis

All the slides were submitted to digital image analysis with using ImagePro® 6 software. Morphometric parameters such as the cell size, the nuclear area, the cytoplasmic area and the nuclear/cytoplasmic area ratio were measured for both the benign and malignant urothelial cells. Well-preserved, non-overlapping and/or individually scattered cells were usually selected, and some loosely clustered, easily discernable cells were also accepted and measured. Tight three-dimen-

sional clusters or papillae were excluded; squamous cells, either contamination or metaplastic, were not submitted to digital image analysis. In the ThinPrep® preparation group, the number of malignant cells, both in the high- and low-grade tumors that were adequate for image analysis, was usually between 20 and 50 observed per slide, and only rarely did they exceed 100. In the benign group, 10 to 30 urothelial cells were usually observed per slide, including both the superficial and intermediate cells, except for a few inflammatory conditions that showed more than 50 or rarely 100 cells per slide, including numerous severely degenerated ones. In the cytopspin group, the number of adequately preserved cells was markedly smaller. The malignant group still showed more than 20 cells; however, the benign group usually produced less than 10 sufficiently well-preserved cells, including both the superficial and intermediate cells. Up to 50 adequate, superficial or intermediate urothelial cells were analyzed from one slide.

In each of the ThinPrep® and cytopspin groups, the differences in morphometric parameters were separately compared between the benign and malignant cells, with and without classifying the malignant tumors into high and low grade. Those parameters that were significantly different between the benign and malignant cells were again compared between the ThinPrep® and cytopspin groups to investigate which preparation produced more distinct differences between the benign and malignant cells.

Statistics

T-tests were used to determine the p values, and p values ≤ 0.05 were considered significant.

RESULTS

Both the liquid-based and cytopspin preparation techniques yielded individual cells that were suitable for

Table 1. Comparison of ThinPrep® with cytospin preparation urine cytology in malignant and benign urothelial lesions

	ThinPrep®		Conventional	
	Malignant	Benign	Malignant	Benign
Nuclear-to-cytoplasmic area ratio (%)	29,5	17,2	29,2	16,4
P value	<0,05		<0,05	

Table 2. Comparison of malignant with benign urothelial lesions by ThinPrep® and conventional cytospin technique

	Malignant		Benign	
	ThinPrep®	Conventional	ThinPrep®	Conventional
Nuclear-to-cytoplasmic area ratio (%)	29,5	29,2	17,2	16,4
P value	>0,05		>0,05	

morphometric analysis. In some of the malignant cases, the urine cytology showed cell clusters of papillae with irregular borders, variable sized and shaped nuclei with fine granular chromatin and small nucleoli (Fig. 1A). In the higher grade malignant cases, the cells were significantly pleomorphic and individually scattered or they formed small, loose clusters or syncytials; the cells displayed coarse chromatin, prominent nucleoli and frequent apoptosis in a rather dirty background of inflammation, hemorrhage and/or necrosis (Fig. 1C). The ThinPrep® liquid-based preparation generally presented well-preserved cells with a relatively clean background in both the malignant and benign cases (Fig. 1 and Fig. 3). In the malignant cases, the cytospin preparation showed an adequate number of atypical cells for making the diagnosis in spite of the occasional cases with a dirty background and cellular degeneration (Fig. 2). However, in the benign cases, the cytospin preparation generally displayed lower cellularity and more cellular degeneration than did the ThinPrep® preparation (Fig. 3).

On the digital image analysis, the nuclear-to-cytoplasmic area ratio showed significantly distinct values between the benign and malignant urothelial cells in both the ThinPrep® and conventional urine cytology. In the cytospin preparation, the mean nuclear-to-cytoplasmic area ratio was higher for the malignant urothelial cells than that for the benign urothelial cells (29.2% versus 16.4%, respectively ($p < 0.05$)) (Table 1). In the

ThinPrep®, the mean value of the nuclear-to-cytoplasmic area ratio was also significantly higher for the malignant urothelial cells (29.5%) than that for the benign (17.2%) urothelial cells ($p < 0.05$) (Table 1). However, on comparing the value of the nuclear-to-cytoplasmic area ratio of the ThinPrep® with that of the conventional cytospin urine cytology for the malignant urothelial carcinoma group, they were very similar to each other (29.5% versus 29.2%, respectively). Further, the values of the nuclear-to-cytoplasmic area ratio for the benign group were not significantly different between the ThinPrep® and conventional cytospin urine cytology (17.2% versus 16.4%, respectively) (Table 2).

On classifying the urothelial carcinoma into the high- and low-grade groups, the mean nuclear-to-cytoplasmic area ratios of the malignant cells of the two groups were 32.3% and 28.7% in the ThinPrep® preparation, and these values were 31.7% and 26.5% in the conventional preparation cytology, respectively. In both preparations, the mean nuclear-to-cytoplasmic area ratio of the high-grade tumor cells was higher than that of the low-grade cells, and the latter value was still significantly higher than that of the benign urothelial cells. However, on comparing the nuclear-to-cytoplasmic area ratios of the malignant cells between the two preparation techniques, there were still no significant differences regardless of the grade of malignant cells.

As for the cellularity, the degree of degeneration and

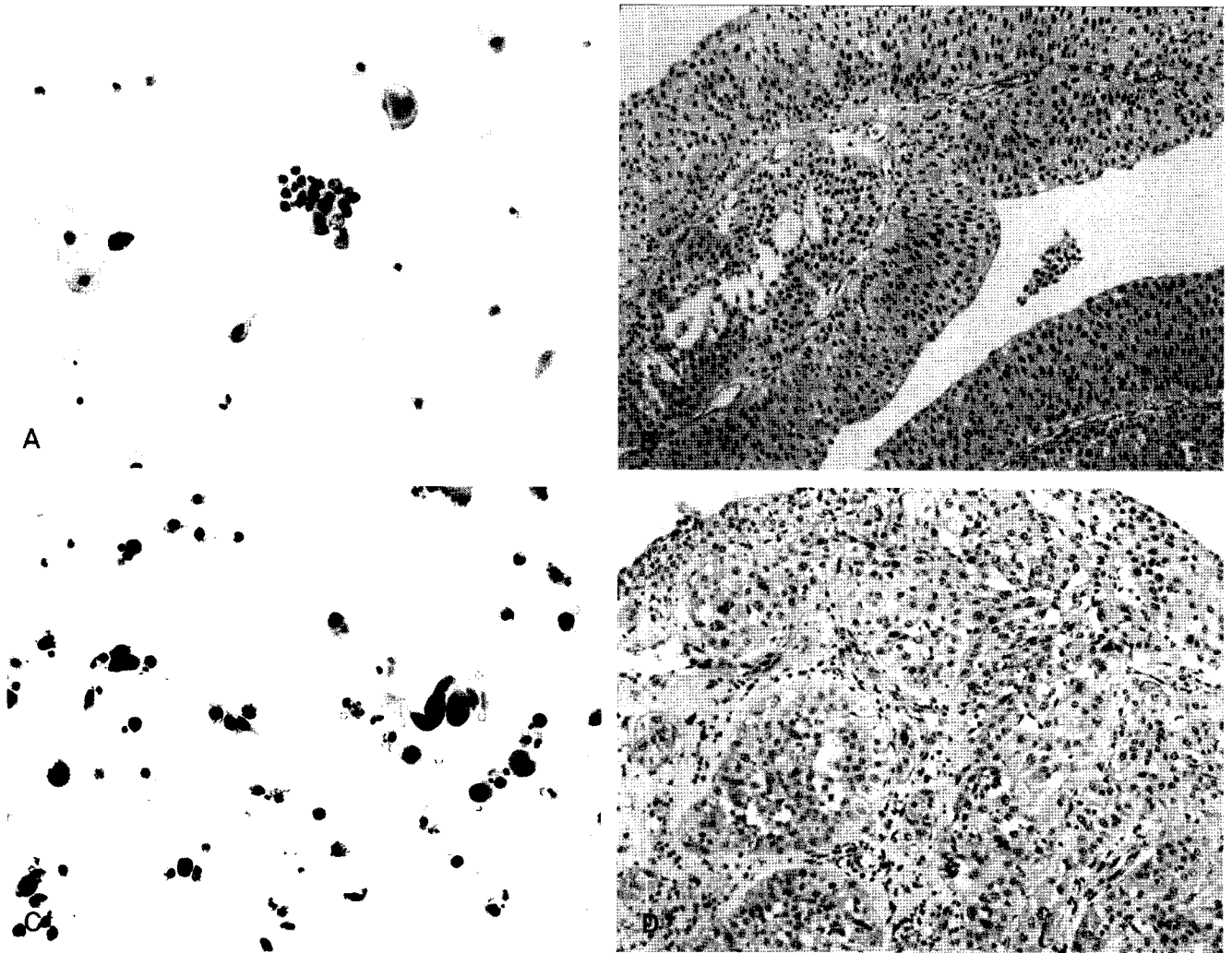


Fig. 1. ThinPrep® preparation cytology of urothelial carcinomas. (A) The cytological findings of a low grade urothelial carcinoma include cell clusters of papillae with irregular borders, variability in size and shape or nuclei with fine granular chromatin and small nucleoli (Papanicolaou stain). (C) In a higher grade tumor, the cells are significantly pleomorphic, individually scattered, or form small, loose clusters or syncytia in rather dirty background of inflammation, hemorrhage and/or necrosis (Papanicolaou stain). B and D are the correspondant histologic findings of A and C, respectively (H&E).

the background, the ThinPrep® preparation technique seemed to have some advantages. Although both the ThinPrep® and conventional cytology produced sufficient numbers of cells for making a diagnosis, preservation of the individual cells seemed to be better with the ThinPrep® preparation, which demonstrated more easily measurable single cells. The lack of an interfering background inflammation, blood and/or necrosis was also helpful in selecting interesting cells (Fig. 1 and 2). Moreover, in the benign urine specimens, the cellularity and preservation were significantly superior in the ThinPrep® cytology (Fig. 3).

In summary, the value of the nuclear-to-cytoplasmic

area ratio, as measured by digital image analysis, was efficient for differentiating malignant urothelial cells from benign urothelial cells irrespective of the preparation method and the tumor grade. Neither the ThinPrep® nor conventional cytopsin preparation cytology was definitely superior to the other technique for distinguishing malignant cells from benign cells by cytomorphometric analysis of the adequately preserved cells. However, upon considering the better preservation and cellularity with a clear background, the ThinPrep® preparation seemed to have some advantage.

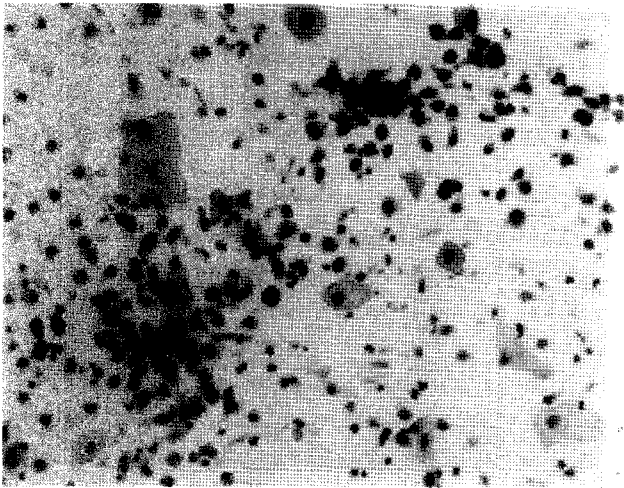


Fig. 2. Conventionally prepared cytology of urothelial carcinoma. In malignant cases, cytospin preparation shows an adequate number of atypical cells for diagnosis in spite of the dirty background and cellular degeneration (Papanicolaou stain).

DISCUSSION

Although liquid-based urine cytology, with its definitively superior cellularity and cell preservation, was once expected to replace the conventional cytology, the results of many studies that compared the efficiency of the two preparation techniques didn't agree one another.^{3,7-12} Van der Poel et al, proposed in one study that image analysis was superior to cytological analysis for predicting tumor recurrence after obtaining normal

findings via cystoscopic examination.¹⁴ Bishop and Sims measured similar morphometric parameters of various non-gynecological specimens, including body fluids, urine, respiratory aspirates and fine needle aspirates, and they compared the ThinPrep® and conventional preparation techniques, but they didn't focus on urine specimens.¹³ In this study we attempt, with using digital image analysis (ImagePro® 6 software) and measuring the cytomorphometric parameters, to compare the effectiveness of the ThinPrep® and cytospin preparation urine cytology for detecting urothelial cell carcinoma.

In the definitely confirmed urothelial carcinomas, the malignant cells were clearly discriminated by a cytomorphometric parameter (the nuclear-to-cytoplasmic area ratio) from the benign urothelial cells in both the ThinPrep® and cytospin preparations. The nuclear-to-cytoplasmic area ratio by itself may be a sensitive and specific discriminator to detect malignant cells in the urine cytology of any preparation technique. Yet when comparing the malignant urothelial cells observed in the ThinPrep® and the cytospin preparation, there were no significant differences in the cytomorphometric parameters measured by digital image analysis. Therefore, it cannot be claimed that for detecting malignant cells by cytomorphometric analysis, one preparation is definitively superior to the other if an adequate

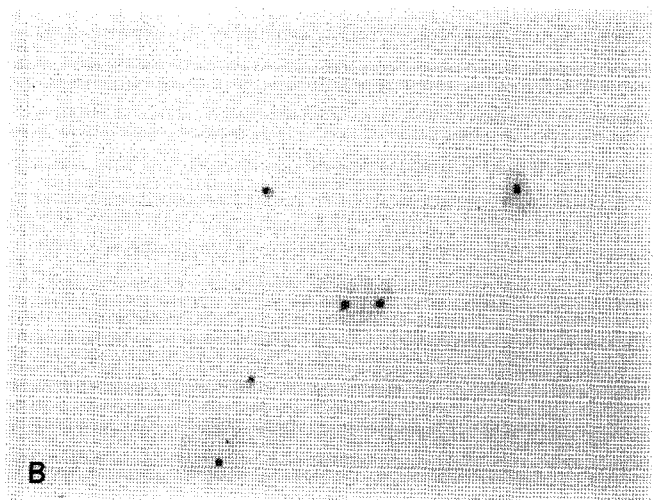


Fig. 3. ThinPrep® and conventional preparation cytology of a benign condition ("negative for malignancy"). ThinPrep® preparation shows well-preserved cells with relatively clean background in benign cases as well as in malignant ones (A) while the cytospin preparation presents a lower cellularity and more degeneration (B). (Papanicolaou stain).

number of cells is observed. This result was not surprising when considering the variable results of previous studies that compared the liquid-based preparation and conventional cytology.

In this study, the nuclear-to-cytoplasmic ratio values of the malignant and benign urothelial cells were around 30% and 17%, respectively, in both the ThinPrep® and cytopsin preparation techniques. In contrast, those values measured in the study of Bishop and Sims were 70% and 100%, respectively, for malignant cells in the thin-layer and filter cytopsin preparation, while they were 22% and 19%, respectively, for benign cells.¹³ The values of the nuclear-to-cytoplasmic ratio of urothelial cells were remarkably higher in the latter and especially in the malignant cells, while the values for the benign cells were similar in both studies. In this study, the analyzed cells were individually scattered or very loosely clustered ones with more flattened cytoplasm; in individual cases and even in the high-grade carcinoma, there were variable numbers of low-grade cells with relatively large cytoplasm and small nuclei scattered among the typical high-grade malignant cells. These cells were included in the analysis and this may partially explain the significantly lower nuclear-to-cytoplasmic ratio values. We couldn't find other studies that measured the nuclear-to-cytoplasmic ratio in urothelial cell to help us judge which of the values is more correct. Thus, we still cannot completely understand the reason for such a discrepancy, although we suspect that unknown differences in the details of the preparation techniques and/or the analysis software may have also influenced the final results.

Nonetheless, many articles have admitted that the ThinPrep® or the other liquid-based preparation techniques produce an adequate number of well-preserved diagnostic cells. Wright et al. and Luthra et al. also claimed the ThinPrep® urine cytology was less time-consuming and less labor-intensive with better cell recovery and morphology.^{11,15} As for the cellularity, the degree of degeneration and the background, the ThinPrep® preparation seemed to have significant

advantages in this present study too, like was reported by some previous studies.^{13,14} Considering the cost effectiveness, Piaton et al. still claim that conventional cytology is the most appropriate approach for the current treatment of urine samples.^{3,16} Elsheikh et al. recently suggested that ThinPrep® cytology is more cost-effective than conventional cytology for evaluating exfoliative cytology specimens.¹⁷ Besides, it has been shown that ThinPrep®-processed samples could be used for molecular studies and chromosomal analysis because they allow efficient recovery of the DNA, RNA and protein even after several months of storage at -20 °C.^{18,19}

The result of the present study suggested that digital image analysis of urine cytology specimens can discriminate the malignant urothelial cells, both high- and low-grade, from the benign ones with good sensitivity and specificity. This study could not demonstrate the definite superiority of ThinPrep® preparation urine cytology over the conventional technique for discriminating malignant cells from benign cells by cytomorphometric analysis of the well-preserved cells. However, the other qualities of the ThinPrep® preparation, including the generally better cellularity and cell preservation and the clear background, suggest this may be the more effective technique with great potential for not only cytomorphometric analysis, but also as a first-screening tool for detecting malignancy in urine cytology specimens.

CONCLUSION

The digital image analysis did not demonstrate a distinct difference of the cytomorphometric features between the ThinPrep®- and conventionally processed malignant cells; however, the cytomorphometric measurement of the nuclear-to-cytoplasmic area ratio may be a sensitive and specific discriminator for detecting malignant cells in urine cytology. Nonetheless, the ThinPrep® liquid-based preparation technique had

some advantages, such as more numerous, easily measured single cells and a clean background, and these advantages are significant when conducting morphometric studies.

REFERENCES

- Xin W, Raab SS, Michael CW. Low-grade urothelial carcinoma: reappraisal of the cytologic criteria on ThinPrep. *Diagn Cytopathol* 2003;29:125-9.
- Saad A, Hanbury DC, McNicholas TA, Boustead GB, Woodman AC. The early detection and diagnosis of bladder cancer: a critical review of the options. *Eur Urol* 2001;39:619-33.
- Piaton E, Hutin K, Faynel J, Ranchin MC, Cottier M. Cost efficiency analysis of modern cytocentrifugation methods versus liquid based (Cytoc Thinprep) processing of urinary samples. *J Clin Pathol* 2004;57:1208-12.
- Planz B, Jochims E, Deix T, Caspers HP, Jakse G, Boecking A. The role of urinary cytology for detection of bladder cancer. *Eur J Surg Oncol* 2005;31:304-8.
- Bastacky S, Ibrahim S, Wilczynski SP, Murphy WM. The accuracy of urinary cytology in daily practice. *Cancer* 1999;87:118-28.
- Lotan Y, Roehrborn CG. Sensitivity and specificity of commonly available bladder tumor markers versus cytology: results of a comprehensive literature review and meta-analyses. *Urology* 2003;61:109-18; discussion 18.
- Anagnostopoulou I SH, Rammou-Kinnia R, Karakitsos P, Gianni I, Georgoulakis J, Kittas C. Comparative study of Thinprep and conventional voided urine cytology (Abstract). *Cytopathology* 2000;11:373.
- Nicol TL, Kelly D, Reynolds L, Rosenthal DL. Comparison of TriPath thin-layer technology with conventional methods on nongynecologic specimens. *Acta Cytol* 2000;44:567-75.
- Papillo JL, Lapen D. Cell yield. ThinPrep vs. cytocentrifuge. *Acta Cytol* 1994;38:33-6.
- Pondo A CB, Gupta PK. Use of Thinprep in urine cytology (Abstract). *Acta Cytol* 1992;37:584.
- Wright RG, Halford JA. Evaluation of thin-layer methods in urine cytology. *Cytopathology* 2001;12:306-13.
- Nassar H, Ali-Fehmi R, Madan S. Use of ThinPrep mono-layer technique and cytospin preparation in urine cytology: a comparative analysis. *Diagn Cytopathol* 2003;28:115-8.
- Bishop JW, Sims KL. Cellular morphometry in nongynecologic thin-layer and filter cytologic specimens. *Anal Quant Cytol Histol* 1998;20:257-67.
- van der Poel HG, Boon ME, van Stratum P, et al.: Conventional bladder wash cytology performed by four experts versus quantitative image analysis. *Mod Pathol* 1997;10:976-82.
- Luthra UK, Dey P, George J, et al.: Comparison of ThinPrep and conventional preparations: urine cytology evaluation. *Diagn Cytopathol* 1999;21:364-6.
- Piaton E, Faynel J, Hutin K, Ranchin MC, Cottier M. Conventional liquid-based techniques versus Cytoc Thinprep processing of urinary samples: a qualitative approach. *BMC Clin Pathol* 2005;5:9.
- Elsheikh TM, Kirkpatrick JL, Wu HH. Comparison of ThinPrep and cytospin preparations in the evaluation of exfoliative cytology specimens. *Cancer* 2006;108:144-9.
- Skacel M, Fahmy M, Brainard JA, et al.: Multitarget fluorescence in situ hybridization assay detects transitional cell carcinoma in the majority of patients with bladder cancer and atypical or negative urine cytology. *J Urol* 2003;169:2101-5.
- Tisserand P, Fouquet C, Marck V, et al.: ThinPrep-processed fine-needle samples of breast are effective material for RNA- and DNA-based molecular diagnosis: application to p53 mutation analysis. *Cancer* 2003;99:223-32.