

## Case Report

# Spontaneous Spinal Epidural Hematoma in an Infant : A Case Report and Review of the Literature

Jae Joon Lim, M.D., Soo Han Yoon, M.D., Ki Hong Cho, M.D., Sang Hyun Kim, M.D.

Department of Neurosurgery, Ajou University School of Medicine, Suwon, Korea

Spontaneous spinal epidural hematoma (SSEH) is rare in children, especially in infants, in whom only 12 cases have been reported. Because of the nonspecificity of presenting symptoms in children, the diagnosis may be delayed. We report herein a case of SSEH in a 20-month-old girl who initially presented with neck pain, and developed lower extremity motor weakness and symptoms of neurogenic bladder 2 weeks prior to admission. The magnetic resonance imaging showed an epidural mass lesion extending from C7 to T4, and the spinal cord was severely compressed by the mass. After emergency decompressive surgery the neurologic function was improved immediately. Two months after surgery, the neurological status was normal with achievement of spontaneous voiding. We suggest that surgical intervention can provide excellent prognosis in case of SSEH in infants, even if surgery delayed.

**KEY WORDS :** Spontaneous · Spinal epidural hematoma · Infant · Laminotomy.

## INTRODUCTION

Spontaneous spinal epidural hematoma (SSEH) is a rare clinical entity. The incidence of SSEH is 0.1 patients per 100,000 per year<sup>8,11</sup>. Although this condition occurs in all ages, it has a preponderance in older aged patients who have received anticoagulants or antiplatelet drugs and therefore have bleeding or coagulation defect tendencies. SSEH is rare in children and only 12 infant cases have been reported in the literature<sup>4,10,12,15-17,19,21,24,26</sup>. While the lesion is located in the thoracolumbar lesion in older patients, the cervicothoracic site is more common in children<sup>21</sup>.

Presenting symptoms in children are usually nonspecific irritability and crying, making diagnosis difficult, but early surgical intervention has been reported to result in more favorable outcome compared to adults<sup>17,22</sup>. We report a case of a 20-month-old female with SSEH who received surgery within 14 days onset of symptoms, and who recuperated well, suggesting that even delayed surgery is important in the management of SSEH.

## CASE REPORT

A 20-month-old girl was transferred to our institution due to neck pain for 2 weeks, progressive leg weakness for 1 week, and voiding difficulty. She was evaluated at another hospital by computed tomography (CT) scan and magnetic resonance imaging (MRI) of the head with contrast, both of which were normal. At our institution, the spinal tap showed high protein content in the cerebrospinal fluid. Past history did not reveal any trauma to the head or spine, nor any bleeding disorder or pertinent family history. The patient was afebrile, and the neurological examination showed normal upper extremity motor and tone, and normal cranial nerve examination. She demonstrated hypotonic lower extremities, and motor weakness in the lower limbs. The deep tendon reflex was increased in both lower limbs. Sensory change was difficult to evaluate. In the presence of a neurogenic bladder, spontaneous voiding was not possible, and an indwelling urinary catheter had been inserted.

The CT of the spine did not show any evidence of destructive change or fracture of the vertebral body and neural arch. MRI demonstrated a posterior, extradurally lobulated mass extending from the 7<sup>th</sup> cervical spine to the 4<sup>th</sup> thoracic spine. The mass showed high signal intensity on the T1 weighted image and low signal intensity on the T2 weighted images (Fig. 1, 2). The spinal cord was displaced anteriorly and

• Received : February 5, 2008 • Accepted : July 24, 2008  
• Address for reprints : Soo Han Yoon, M.D.  
Department of Neurosurgery, Ajou University School of Medicine, San 5  
Woncheon-dong, Yeongtong-gu, Suwon 443-721, Korea  
Tel : +82-31-219-5233, Fax : +82-31-219-5238,  
E-mail : ee80@ajou.ac.kr

**Table 1.** Thirteen cases of infants with spontaneous spinal hematomas in the literature

	Sex/Age (months)	Symptom to operation interval (days)	Clinical history and symptom	Spinal level	Outcome
Shenkin, et al. <sup>24)</sup>	F/20	14	Fever, irritability, progressive Paraplegia for 10 days	T1–T7	Complete recovery
Jackson, et al. <sup>12)</sup>	F/14		Progressive paraparesis	T1–T5	Complete recovery
Hehman, et al. <sup>10)</sup>	M/21	NA	Irritability, neck stiffness, quadriplegia	C3–T9	Right knee hyperreflexia
Vallee, et al. <sup>26)</sup>	F/22	10	Irritability, neck pain, quadriplegia	C5–T1	Complete recovery
Licata, et al. <sup>16)</sup>	M/18	6	Quadriplegia	T1–T2	Complete recovery
Caldarelli, et al. <sup>4)</sup>	F/24	3	Progressive flaccid paraplegia	C5–T4	Complete recovery
Caldarelli, et al. <sup>4)</sup>	F/16	9	Fever, irritability, neck pain	C4–T7	Complete recovery
Patel, et al. <sup>21)</sup>	M/18	7	Irritability, neck pain, quadriplegia	C1–T1	Marked improvement 1wk
Patel, et al. <sup>22)</sup>	F/22	NA	Fever, progressive paraparesis	C7–T10	Complete recovery
Pai, et al. <sup>19)</sup>	M/15	2	Loss of neck control, weakness of upper limbs	C4–T3	Complete recovery
Liao, et al. <sup>15)</sup>	NA/7	NA	Irritability, crying	C2–T4	Complete recovery
Lee, et al. <sup>17)</sup>	M/4	5	Irritability	C4–T4	Complete recovery
Authors' case	F/20	14	Neck pain, paraplegia	C7–T4	Marked recovery

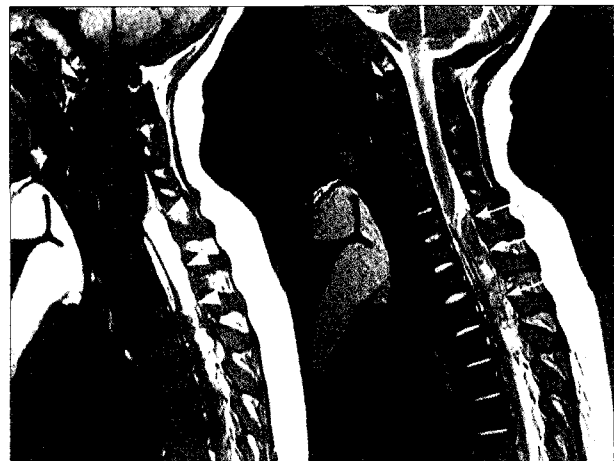NA : non-available. C : cervical spine, T : thoracic spine

compressed by the lesion. The patient underwent surgery using a posterior approach. Second and 3<sup>rd</sup> thoracic spine laminotomies were performed utilizing a high speed air drill with a 1 mm-size cutting bur<sup>8)</sup>. Upon laminotomy, an epidural hematoma was observed. The dural pulsation returned after removal of the hematoma and the engorged epidural venous network. The compressed dura of the spinal cord also returned to normal. After complete hematoma removal we performed a modified procedure as described by Abbott et al.<sup>1)</sup> in which the spinous processes and bilateral paraspinal muscles are fixed with absorbable suture, and also rostral and caudal end of the spinous processes fixed to the adjacent spinous processes<sup>20)</sup>. Histopathological examination of the hematoma including the vascular structure revealed no evidence of tumors, abnormal blood vessels, or vascular malformations.


The patient demonstrated improved motor weakness and tones a month after the surgery but the neurogenic bladder remained to a mild degree. She was able to stand independently, with improvement of the voiding difficulty 2 months later. The patient showed further improvement at 12 months follow up to the extent that running was possible, and spontaneous voiding was achieved to the extent that average residual volume was only 27 cc.

## DISCUSSION

Most reported cases of SSEH in the literature occurred in adult. Only 35 pediatric cases have been previously described reported in the past literature, and among them only 13, including our case, have been reported in infants<sup>6,29)</sup>, and there is no sexual preponderance in toddlers (Table 1)<sup>8,21)</sup>.



**Fig. 1.** Initial sagittal magnetic resonance imaging demonstrating a posterior, extradurally lobulated contour from the 7th cervical spine to the 4th thoracic spine, which is seen as a high signal intensity lesion (arrow heads) on the T1 weighted image and low signal intensity lesion (arrows) on the T2 weighted image.



**Fig. 2.** Initial axial magnetic resonance imaging showing the compressed and displaced spinal cord (arrow heads and arrows) due to this lesion.

In adults, possible etiologies of SSEH are the administration of anticoagulants causing bleeding diastasis, or coagulation disorders such as leukemia, lymphoma, spinal arteriovenous malformations, ankylosing spondylitis, Paget's disease, and hypertension<sup>9,18,23,29</sup>. In children, coagulopathies and vessel rupture from increased venous pressure within the intraspinal space caused by sudden increase in intra-abdominal and thoracic pressure, may result in subsequent hemorrhage<sup>19,21</sup>. In infants, bleeding may be due to rupture of small vascular malformations such as venous angiomas, hemangiomas, or epidural varices<sup>4,19</sup>.

The site of the hematoma in adults are mainly thoracolumbar lesions, while in children lesions are mostly cervicothoracic lesion<sup>21</sup>, and in toddlers all reported cases have been cervicothoracic lesion, as shown in our patient. Disproportion of the weight ratio of the head to the body in the pediatric population, and increased cervical spine mobility in the presence of undeveloped muscular capacity of the neck in toddler attribute to this lesional difference<sup>17</sup>.

Presenting symptoms of SSEH are usually a consequence of spinal cord compression and roots compression, resulting in sudden onset of back or neck pain. In adults, the pain and neurological deficits are characteristically specific and localized, but in children, particularly those under the age of 2 years, the initial symptoms are nonspecific, such as irritability or crying. Therefore, accurate and early diagnosis may be difficult<sup>3,4,19</sup>. Review of the past 13 infant cases of SSEH indicates that an average duration of the symptoms prior to surgery was 7.1 days among the 10 patients in whom the duration was known while the shortest was 2 days and the longest duration was 14 days (2 patients including our patient).

MRI is the choice of imaging modality and plays an important role in diagnosis and evaluation of SSEH<sup>5,19</sup>. The signal intensity difference in the MRI allows estimation of the stage of hematoma. In our case, the hematoma was seen as a posterior bright high signal intensity lesion on the T1 weighted image, and on the T2 weighted image as a low signal intensity lesion suggesting a subacute type hemorrhage of more than 3 days progression, and thus coincides with the 14 days duration of symptom onset.

Rapid surgical evacuation has been recommended as a treatment of choice for the symptomatic SSEH<sup>4,14,15</sup>. In exceptional cases where the neurologic deficit is minor conservative management may be undertaken, such as coexistence of a serious coagulopathy, anticipated risks of operative treatment, the refusal of operation by patient, and the presence of tetraplegia for more than 7 days<sup>7</sup>.

It is unclear whether a laminectomy or laminotomy is superior in terms of outcome for spinal stability due to lack

of comparative studies. According to Yasuoka et al. it was shown that the incidence of postlaminectomy deformity was 46% in patients under 19 years of age<sup>27,28</sup>, and other authors have recommended that laminotomy rather than laminectomy is preferable in children<sup>4,19,20</sup>. Laminotomy is divided into two types; preserving the upper or lower interspinous ligament and ligament flavum, or completely separating the ligament and bone forming a free lamina flap and then approximating again<sup>1,13,25</sup>. The difference in terms of instability between the above two methods are not yet known. In our case, we employed a 1 mm high speed drill and then formed a free lamina flap. After the hematoma was removed, it was reconstructed, similar to the method described by Abbott et al.<sup>1,20</sup>.

The most significant factors that determine neurological outcome are interval from symptom onset to surgery, and the degree of neurological deficits prior to surgery. The shorter interval from symptom onset to surgery, and minor neurological deficit has been reported to result in more favorable outcome<sup>14</sup>. Opinions regarding the optimal interval from symptom onset to surgery varies from within 12 hours to within 48 hours<sup>8,15</sup>. Patients with pre-operative incomplete spinal dysfunction are known to have more favorable prognosis than those with complete spinal dysfunction, suggesting that surgery should be performed early and when neurological deficit is less severe<sup>2,8,15</sup>. In infants diagnosis is often delayed for 3 days, but surgery performed within 3 days seems to result in good recovery<sup>17</sup>. Even though surgery is late and grave prognosis is expected when the diagnosis is delayed for 2 weeks in adults, the 2 cases (including the present patient) in whom the diagnosis and surgery was 2 weeks after the onset of symptoms, showed good functional recovery and minimal minor neurologic deficits, suggesting that, even if diagnosis is delayed in infants, prompt surgical intervention will afford good outcome.

## CONCLUSION

SSEH in infants is a rare condition, and while presenting symptoms are mostly nonspecific making early diagnosis difficult, good recovery may be envisaged even with late surgery. In infant patients with non-traumatic motor weakness, this condition should be considered as a differential diagnosis on MRI.

## References

1. Abbott R, Feldstein N, Wisoff JH, Epstein FJ : Osteoplastic laminotomy in children. *Pediatr Neurosurg* 18 : 153-156, 1992
2. Alexiadou-Rudolf C, Ernestus RI, Nanassis K, Lanfermann H, Klug N : Acute nontraumatic spinal epidural hematomas. An important

- differential diagnosis in spinal emergencies. *Spine* 23 : 1810-1813, 1998
3. Beatty RM, Winston KR : Spontaneous cervical epidural hematoma. A consideration of etiology. *J Neurosurg* 61 : 143-148, 1984
  4. Caldarelli M, Di Rocco C, La Marca F : Spontaneous spinal epidural hematoma in toddlers : description of two cases and review of the literature. *Surg Neurol* 41 : 325-329, 1994
  5. Crisi G, Sorgato P, Colombo A, Scarpa M, Falasca A, Anqari P : Gadolinium-DTPA-enhanced MR imaging in the diagnosis of spinal epidural hematoma. Report of a case. *Neuroradiology* 32 : 64-66, 1990
  6. Fountas KN, Kapsalaki EZ, Robinson JS : Cervical epidural hematoma in children : a rare clinical entity. Case report and review of the literature. *Neurosurg Focus* 20 : E6, 2006
  7. Groen RJ : Non-operative treatment of spontaneous spinal epidural hematomas : a review of the literature and a comparison with operative cases. *Acta Neurochir (Wien)* 146 : 103-110, 2004
  8. Groen RJ, van Alphen HA : Operative treatment of spontaneous spinal epidural hematomas : a study of the factors determining postoperative outcome. *Neurosurgery* 39 : 494-509, 1996
  9. Hamre MR, Haller JS : Intraspinal hematomas in hemophilia. *Am J Pediatr Hematol Oncol* 14 : 166-169, 1992
  10. Hehman K, Norrell H : Massive chronic spinal epidural hematoma in a child. *Am J Dis Child* 116 : 308-310, 1968
  11. Holtas S, Heiling M, Lonntoft M : Spontaneous spinal epidural hematoma : findings at MR imaging and clinical correlation. *Radiology* 199 : 409-413, 1996
  12. Jackson FE : Spontaneous spinal epidural hematoma coincident with whooping cough. Case report. *J Neurosurg* 20 : 715-717, 1963
  13. Kehrl P, Bergamaschi R, Maitrot D : Open-door laminoplasty in pediatric spinal neurosurgery. *Childs Nerv Syst* 12 : 551-552, 1996
  14. Lawton MT, Porter RW, Heiserman JE, Jacobowitz R, Sonntaq VK, Dickman CA : Surgical management of spinal epidural hematoma : relationship between surgical timing and neurological outcome. *J Neurosurg* 83 : 1-7, 1995
  15. Liao CC, Lee ST, Hsu WC, Chen LR, Lui TN, Lee SC : Experience in the surgical management of spontaneous spinal epidural hematoma. *J Neurosurg* 100 (Suppl Spine) : 38-45, 2004
  16. Licata C, Zoppetti MC, Perini SS, Bazzan A, Gerosa M, Da Pian R : Spontaneous spinal haematomas. *Acta Neurochir (Wien)* 95 : 126-130, 1988
  17. Lee JS, Yu CJ, Huang KC, Lin HW, Huang CC, Chen HH : Spontaneous spinal epidural hematoma in a 4-month-old infant. *Spinal Cord* 3 : 1-5, 2006
  18. Muhonen MG, Piper JG, Moore SA, Menezes AH : Cervical epidural hematoma secondary to an extradural vascular malformation in an infant : case report. *Neurosurgery* 36 : 585-588, 1995
  19. Pai SB, Maiya PP : Spontaneous spinal epidural hematoma in a toddler-a case report. *Childs Nerv Syst* 22 : 526-529, 2006
  20. Park SW, Yoon SH, Cho KH, Shin YS, Ahn YH : Infantile lumbosacral spinal subdural abscess with sacral dermal sinus tract. *Spine* 32 : E52-55, 2007
  21. Patel H, Boaz JC, Phillips JP, Garq BP : Spontaneous spinal epidural hematoma in children. *Pediatr Neurol* 19 : 302-307, 1998
  22. Patel H, Garg BP : Increasing irritability with sudden onset of flaccid weakness. *Semin Pediatr Neurol* 3 : 192-197, 1996
  23. Penar PL, Fischer DK, Goodrich I, Bloomqarden GM, Robinson F : Spontaneous spinal epidural hematoma. *Int Surg* 72 : 218-221, 1987
  24. Shenkin HA, Horn RC, Grant FC : Lesions of the spinal extradural space producing cord compression. *Arch Surg* 51 : 125-146, 1945
  25. Shikata J, Yamamuro T, Shimizu K, Saito T : Combined laminoplasty and posterolateral fusion for spinal canal surgery in children and adolescents. *Clin Orthop Relat Res* 259 : 92-99, 1990
  26. Vallee B, Besson G, Gaudin J, Person H, Le Fur JM, Le Guvader J : Spontaneous spinal epidural hematoma in a 22-month-old girl. *J Neurosurg* 56 : 135-138, 1982
  27. Yasuoka S, Peterson HA, Laws ER Jr, MacCarty CS : Pathogenesis and prophylaxis of postlaminectomy deformity of the spine after multiple level laminectomy : difference between children and adults. *Neurosurgery* 9 : 145-152, 1981
  28. Yasuoka S, Peterson HA, MacCarty CS : Incidence of spinal column deformity after multilevel laminectomy in children and adults. *J Neurosurg* 57 : 441-445, 1982
  29. Zuccarello M, Scanarini M, D'Avella D, Andrioli GC, Gerosa M : Spontaneous spinal extradural hematoma during anticoagulant therapy. *Surg Neurol* 14 : 411-413, 1980