

Effects of fibrin glue on bone formation in combination with deproteinized bone xenografts in humans

Moon-Su Kim¹, Su-Gwan Kim¹, Sung-Chul Lim², Hak-Kyun Kim¹, Seong-Young Moon¹

¹Department of Oral & Maxillofacial Surgery, College of Dentistry, Chosun University

²Department of Pathology, College of Medicine, Chosun University, Gwangju, Korea

Abstract

Thirty-six sinus grafts were performed in 34 patients with an alveolar crest bone height in the posterior maxilla of 3 to 5 mm before grafting. The sinuses were grafted using Bio-Oss alone or mixed with fibrin glue. Group 1 was the control group and included 25 patients who received a xenograft mixed in saline. Group 2 comprised 9 patients who received a xenograft and fibrin glue. The study was further subdivided at the time of 9 months. This histologic study evaluated by hematoxylin-eosin (H&E) and histomorphometric analysis whether fibrin glue in combination with Bio-Oss enhances bone regeneration in sinus floor elevation in humans. The new bone formation was better in Group 2 than in Group 1, but the difference was not significant. The absorption of the graft material was faster in Group 2 than in Group 1, in the short term, but better in Group 1 over the long term, although the difference was not significant. Lamellar bone was formed earlier in Group 1 compared to Group 2, but the difference was not significant. Overall, the surgery site stabilized earlier with new bone formation in Group 2 than in Group 1, but the difference was not significant. Combining a fibrin sealant and Bio-Oss could lead to improved scaffolds for bone tissue engineering based on the synergistic effects of the biomaterials. Therefore, Bio-Oss or Bio-Oss plus Tisseel may be used depending on the situation.

Key words

Fibrin glue; Bone formation; Deproteinized bone xenografts

INTRODUCTION

When considering a lateral approach to the sinus, the major differences between the various surgical methods are the type of graft material used and the choice of immediate or delayed implant placement¹. In case of severe atrophy of the maxillary alveolar process, sinus floor elevation and implant insertion are usually performed in two stages². When an autogenous bone graft is used, it takes approximately 6 months following augmentation for the transplanted bone to be integrated and substituted by osteoconduction (creeping substitution).

Alternatively, autogenous bone transplants can be replaced by bone substitutes, such as Bio-Oss (Geistlich, Wolhusen, Switzerland), to avoid donor site morbidity³.

Bio-Oss, a frequently used alternative bone substitute, has been evaluated in several animal^{4,5} and clinical studies^{6,7}. This bone substitute is derived from porous bovine bone material processed to yield natural bone material lacking the organic component; it is reported to have good tissue acceptance and to provide a scaffold for new bone deposition with natural osteotrophic properties⁸.

Histologic data regarding the outcomes of treatments involving sinus grafting in humans are scarce⁹. Even when specimens were obtained at different clinical centers, they were retrieved from patients for whom the surgical procedure was successful.

In implant dentistry, numerous techniques have been studied for promoting and accelerating the osseous healing of dental implants and bone grafts by increasing the

* Corresponding author

Su-Gwan Kim

Dept. of OMFs, College of Dentistry, Chosun University
421, Seosuk-dong, Dong-Gu, Gwangju, 501-825, Korea
Tel: 82-62-220-3815 Fax: 82-62-228-7316
E-mail: sgckim@chosun.ac.kr

bone regenerative potential¹⁰. These techniques include the application of platelet-rich plasma (PRP)¹¹, bone morphogenetic protein¹², growth factors¹³, and fibrin glue^{14,15}.

Fibrin glue in various formulations has been used widely in various surgical procedures by means of establishing hemostasis and for tissue approximation. Fibrin sealants have been used in such diverse locations as the heart and pericardial cavity, lung, bowel, ovary, nasal sinuses, and skin. Formulations include both autologous preparations, which require peri-operative preparation, and prepackaged commercial kits¹⁶.

Fibrin glue is a physiological matrix whose principal component, fibrin, plays fundamental roles in the process of blood clotting and wound healing¹⁷. It is a potentially suitable biological vehicle for cell transplantation since it has proven biocompatibility, biodegradability, and binding capacity to cells¹⁸. Fibrin-stabilizing factor XIII, contained in fibrin glue, favors the migration of undifferentiated mesenchymal stem cells (MSCs) on the highly cross-linked structure of the glue, and it enhances the proliferation of these cells¹⁹.

The use of fibrin glue to improve bone regeneration is well documented²⁰⁻²⁸, and platelet-rich fibrin (PRF) is an autologous fibrin matrix used to enhance bone generation²⁰. Tayapongsak et al.¹⁴ found that it facilitates the placement of graft material in the recipient cavity by preventing the displacement of the bone graft particles during placement. It also helps the remodeling process begin earlier by accelerating the migration of fibroblasts and the revascularization process.

In bone reconstruction, the combination of bioceramics and fibrin glues may have synergistic effects. The mechanical strength of the composite is superior to that of the ceramic alone²¹. Furthermore, the bioceramic/fibrin glue composite is stabilized initially through its adaptation and adhesion to the walls of the bone defect. The fibrin might also enhance its biological properties by acting positively on angiogenesis, cell attachment, and proliferation²².

Few study has examined composites consisting of Bio-Oss and fibrin glue. Therefore, this histologic study evaluated whether fibrin glue in combination with Bio-Oss enhances bone regeneration in sinus floor elevation in humans.

MATERIALS AND METHODS

Thirty-six sinus grafts were performed in 34 patients

with an alveolar crest bone height in the posterior maxilla of 3 to 5 mm before grafting. The sinuses were grafted using Bio-Oss alone or mixed with fibrin glue. Informed consent was obtained from all patients.

Group 1 was the control group and included 25 patients who received a xenograft mixed in saline. Group 2 comprised 9 patients who received a xenograft and fibrin glue. The study was further subdivided at the time of 9 months.

Patient selection

Patients were enrolled in this study if they had no systemic or local contraindications: no history of uncontrolled diabetes, no radiation therapy to the head or neck in doses over 5,000 rads, no chemotherapy within the 12 months preceding surgery, no active sinus infection, no uncontrolled periodontal disease, and no psychological problems that would prevent long-term treatment. Smokers were advised to reduce or refrain from smoking.

Surgical technique

Immediately before surgery, the patients rinsed with a 0.2% chlorhexidine digluconate solution for 2 minutes. Local anesthesia was obtained with lidocaine containing epinephrine 1:100,000.

A crestal incision, slightly displaced toward the palate, was made, and a vertical releasing incision was placed in the canine area to facilitate flap elevation. A mucoperiosteal flap was elevated, exposing the lateral wall of the sinus. A bony window, averaging 15 × 10 mm, was outlined using a no. 6 round carbide bur without perforating the sinus membrane. After mobilizing the window, the sinus membrane was elevated starting from the inferior border of the osteotomy site. The lateral window was pushed inward and elevated superiorly, creating a new horizontal ceiling, as the membrane was carefully dissected from the medial and inferior walls of the sinus.

The graft material (Bio-Oss) was hydrated with saline solution and gently packed into the sinus until it filled the entire cavity. In Group 2, the Bio-Oss was mixed with fibrin glue. Immediate implant placement was indicated when sufficient native bone was available to achieve primary stability after placement. The procedure was delayed 6 to 18 months after grafting for cases in which it was considered impossible to anchor and stabilize an

implant in the subsinus ridge. Screw-type, machined-surface implants were used in the patients.

All the implants were submerged. The abutments were connected during two distinct postoperative periods, at 6 and 18 months post-implant placement. Bone cores from the graft sites were taken for histologic examination. Three to 4 weeks after soft tissue healing, the final abutments were connected, implant stability was tested manually, and prosthetic treatment was carried out.

Histologic examination

Bone cores were harvested from the lateral wall using a 2-mm-diameter trephine bur under sterile saline irrigation. The biopsies were retrieved from areas located between the implants, about 10 mm from the alveolar ridge, at a mean depth of 7 mm.

Microscopic examination and histomorphometric analysis

After fixing the harvested bone in 10% formalin using the conventional method and treating the bone in nitric acid (De-Cal Rapid, Pational Diagnosis, Atlanta, GA) for approximately 4 hours to decalcify, blocks were made to obtain representative sections. After washing and processing the tissues using an autoprocesing machine (Hypercenter XP, Shandon, UK), the blocks were embedded in paraffin. The embedded blocks were cut into 4- μ m-thick slices, stained with hematoxylin-eosin (H&E), and observed under an optical microscope. The degree of new bone formation (bone forming activity) and composition ratio of the tissue sample were determined by measuring and comparing the area of new bone formation using computer-assisted histomorphometry³⁾.

Images of each tissue sample were taken with a digital camera (Polaroid, Cambridge, MA) and analyzed using Image Pro Plus (Media Cybernetics, Silver Spring, MD).

- Bone forming activity = area of new bone formation / whole surface area of the specimen \times 100 (%)
- Composition ratio = areas of woven bone : lamellar bone : residual implant material (%)

Statistical analysis

To confirm the significance after measuring the area of new bone formed, Student's t-test was performed. $P < 0.05$ was considered statistically significant.

RESULTS

Group 1, <9 months

New bone was formed around the implanted Bio-Oss chips. Under higher magnification, organized trabecular woven bone around the implanted Bio-Oss chips was noted (Figs. 1, 2). The bone forming activity was $46.3 \pm 30.0\%$ (Table I). The composition ratio of the tissue sample was 47.7 : 14.6 : 37.7 (areas of woven bone : lamellar bone : residual implant material, Table 1).

Group 1, ≥ 9 months

New bone was formed around the implanted Bio-Oss chips. The new bone forming activity increased slightly ($56.5 \pm 31.5\%$) compared to Group 1 at <9 months (Table I), although the difference was not significant ($p=0.21$). Under higher magnification, organized trabecular woven bone was seen around the implanted Bio-Oss chips.

Table 1. Bone forming activity and composition ratio after implant surgery in Group 1

Time (months)	n	Bone forming activity (%) [*]	Composition ratio (%) [#]		
			Woven bone	Lamellar bone	Bio-Oss
<9	12	46.25 \pm 30.01	47.73 \pm 25.63	14.55 \pm 12.34	37.73 \pm 32.97
≥ 9	13	56.54 \pm 31.45	63.46 \pm 24.70	13.46 \pm 16.12	23.85 \pm 25.91
P value		0.20608	0.0703	0.429	0.13

^{*}Bone forming activity = area of new bone formation/area of total sample \times 100 (%)

[#]Composition ratio = area of woven bone : lamellar bone : residual implant materials (%)

Table 2. Bone forming activity and composition ratio after implant surgery in Group

Duration (months)	n	Bone forming activity (%)*	Composition ratio (%) [#]		
			Woven bone	Lamellar bone	Bio-Oss
<9	4	57.70 ± 39.26	80.00 ± 20.00	3.33 ± 5.77	16.67 ± 20.82
≥ 9	5	82.00 ± 18.91	53.00 ± 31.31	14.00 ± 19.88	31.00 ± 8.22
P value		0.1271	0.0377	0.04953	0.1718

*Bone forming activity = area of new bone formation/area of total sample × 100 (%)

[#]Composition ratio = area of woven bone : lamellar bone : residual implant materials (%)

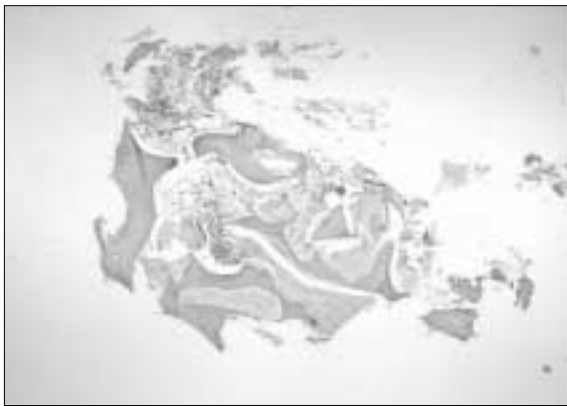

Fig. 1. New bone was seen around the implanted Bio-Oss chips (asterisks) (hematoxylin and eosin stain, original magnification × 40).

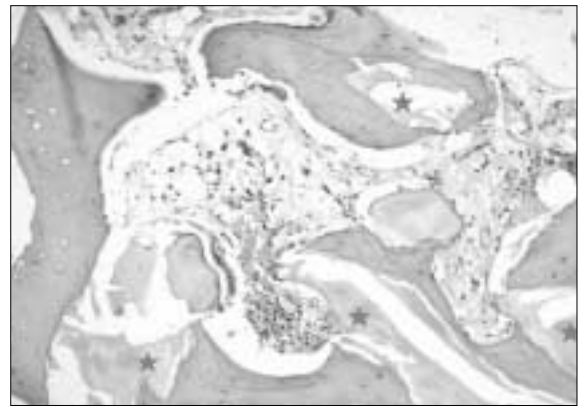


Fig. 2. Higher magnification of the histopathologic findings. Organized trabecular woven bone (open asterisks) was seen around the implanted Bio-Oss chips (closed asterisks) (hematoxylin and eosin stain, original magnification × 100).

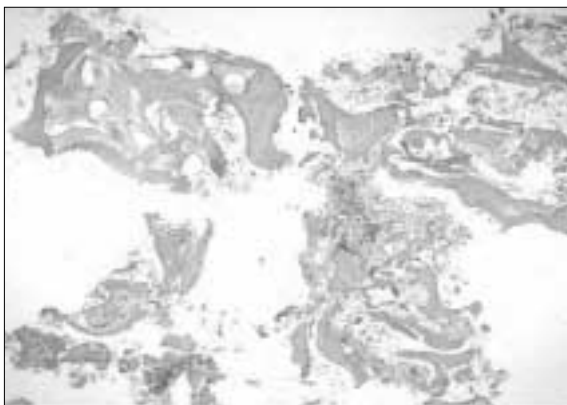


Fig. 3. New bone was seen around the implanted Bio-Oss chips (asterisks). The new bone forming activity increased slightly (hematoxylin and eosin stain, original magnification × 40).




Fig. 4. Higher magnification of the histopathologic findings. Organized trabecular woven bone (open asterisks) was seen around the implanted Bio-Oss chips (closed asterisks). Focal lamellar bone formation (arrows) is noted (hematoxylin and eosin stain, original magnification × 100).




Fig. 5. New bone was seen around the implanted Bio-Oss chips (asterisks) (hematoxylin and eosin stain, original magnification $\times 40$).

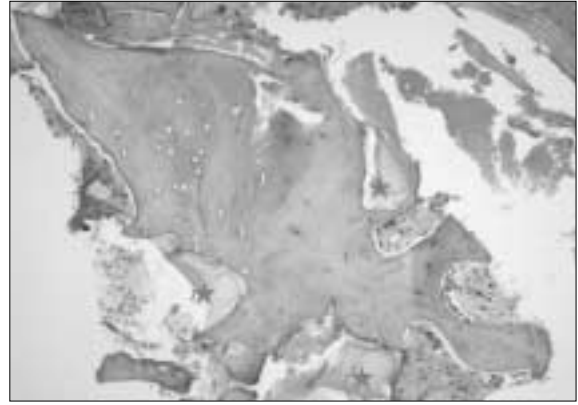


Fig. 6. Higher magnification of the histopathologic findings. Organized woven bone (open asterisks) was seen around the implanted Bio-Oss chips (closed asterisks) (hematoxylin and eosin stain, original magnification $\times 100$).

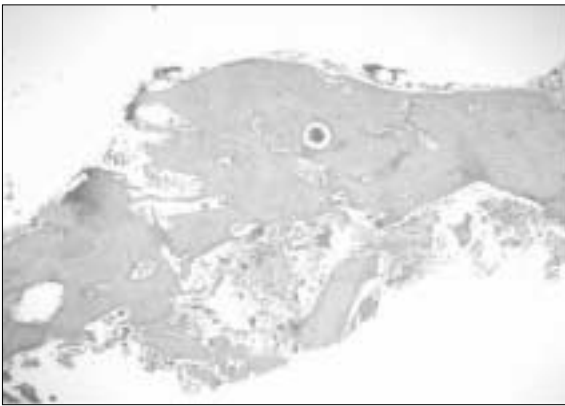


Fig. 7. Thick woven bone around a few implanted Bio-Oss chips (asterisks) is seen. The new bone forming activity increased markedly (hematoxylin and eosin stain, original magnification $\times 40$).

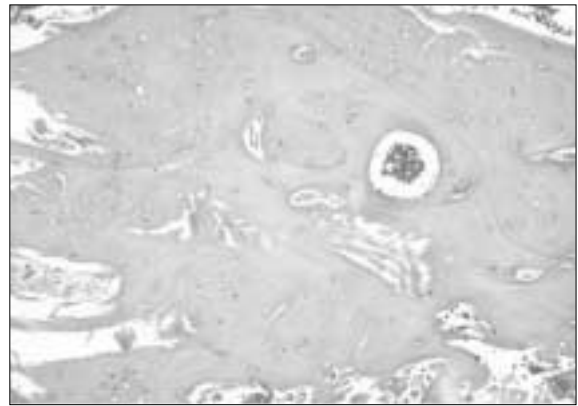


Fig. 8. Higher magnification of the histopathologic findings. Thick woven bone is seen with a few implanted Bio-Oss chips. (hematoxylin and eosin stain, original magnification $\times 100$).

Focal lamellar bone formation was also noted (Figs. 3, 4).

The composition ratio of the tissue sample was 63.5 : 13.5 : 23.9 (Table 1). In this group, the proportion of woven bone formation increased compared to Group 1 at <9 months, although the difference was not significant ($p=0.07$).

Group 2, <9 months

New bone was seen around the implanted Bio-Oss chips. Under higher magnification, organized woven bone formation was seen around the implanted Bio-Oss chips (Figs. 5, 6). The new bone forming activity

increased slightly ($57.7 \pm 39.3\%$) compared to Group 1 at <9 months (Table 2), but the difference was not significant ($p=0.277$; Table 3).

The composition ratio of the tissue sample was 80.0 : 3.3 : 16.7 (Table 2). In this group, the proportion of woven bone increased significantly ($p=0.034$) compared to Group 1 at <9 months (Table 4).

Group 2, ≥ 9 months

Thick woven bone was seen around a few implanted Bio-Oss chips. Although the new bone forming activity (82.0 ± 18.9) increased (Table 2), it was not significantly

Table 3. Comparison of the bone forming activity after implant surgery between Groups 1 and 2

Duration (months)	Bone forming activity (%)*		P value
	Group 1	Group 2	
<9	46.3±30.0	57.7±39.3	0.277
N	12	4	
≥9	56.5±31.5	82.0±18.9	0.056
N	13	5	

* Bone forming activity = area of new bone formation/area of total sample × 100 (%)

Table 4. Comparison of the composition ratio after implant surgery between Groups 1 and 2

Duration (months)	Composition ratio (%)*		P value
	Group 1	Group 2	
<9			
woven bone	47.7±25.6	80.0±20.0	0.034
lamellar bone	14.6±12.3	3.3±5.8	0.080
Bio-Oss	37.7±33.0	16.7±20.8	0.161
≥9			
woven bone	63.5±24.7	53.0±31.3 [†]	0.198
lamellar bone	13.5±16.1	14.0±19.9 [‡]	0.472
Bio-Oss	23.9±25.9	31.0±8.2	0.291

* composition ratio=percentage area of woven bone formation vs. percentage area of lamellar bone formation vs. percentage area of residual implant materials (%)

[†] The proportion of woven bone was statistically significant decreased compared to Group 2, <9 months, p< .05.

[‡] The proportion of lamellar bone was statistically significant increased compared to Group 2, <9 months, p< .05.

different from Group 1 at ≥9 months (p=0.056, Table 3) or from Group 2 at <9 months (P=0.13). Under higher magnification, thick woven bone with a few implanted Bio-Oss chips was seen (Figs. 7, 8).

The composition ratio of the tissue sample was 53.0 : 14.0 : 31.0 (Table 2). The proportion of woven bone decreased significantly (p=0.038) compared to Group 2 at <9 months, while the proportion of lamellar bone increased significantly (P=0.049).

DISCUSSION

Autografts are the ideal material for reconstructing hard tissue defects. They undergo osteogenesis, osteoinduction, and osteoconduction, do not pose a risk of immune rejection, and require short recovery times. However, only a small amount of tissue can be harvest-

ed, and absorption and the secondary defects at the donor site are major drawbacks. To avoid harvesting an autograft and thereby eliminating the additional surgical procedure and associated risks, bone grafting materials and substitutes are used as alternative grafting materials for ridge augmentation²³. The ideal grafting materials should be biocompatible, noncarcinogenic, and nonallergenic; show early vascularization; be replaced by new host bone tissue; strength, resist infection, and be sterile; and undergo surface resorption by the host²⁴.

The use of bovine hydroxyapatite (Bio-Oss) has been suggested for maxillary sinus grafting procedures before or in conjunction with implant placement²⁵. Bio-Oss is deproteinized, sterilized bovine bone with 75 to 80% porosity and a crystal size of approximately 10 nm in the form of cortical and cancellous granules and blocks. It has inner macropores of similar size to natural cancellous

bone, appears to be replaced by host bone more readily than hydroxyapatite when used in alveolar ridge restoration, and appears to undergo physiological remodeling with incorporation into the host bone. Moreover, Bio-Oss is highly biocompatible with oral hard tissues in animals and humans and meets the criteria of an osteoconductive material²⁵. The maturation of Bio-Oss can take up 9 months when used for sinus augmentation. Therefore, the study period was divided at 9 months.

Fibrin tissue adhesive material (FAM) is available as fast (about 5 seconds) and slow (about 1 min) setting types. FAM is supplied in two vials. One contains fibronectin, fibrinogen, factor XIII, and aprotinin (an anti-fibrinolytic agent), while the other contains thrombin and calcium chloride. The components become a gel when mixed. FAM acts as both a tissue adhesive and a hemostatic material. It also enhances wound healing²⁶.

Fibrinogen is obtained from pooled, single-donor, or autologous blood. Pooled fibrinogen products such as Tisseel, Tissucol, and Fibrin Sealant (Immuno AG, Vienna, Austria) are available commercially and are used widely in Europe and Canada, but not in the United States because of the possible risks of transmitting hepatitis, human immunodeficiency virus, and other diseases. Therefore, US practitioners turn to single-donor fresh-frozen plasma or autologous blood¹⁴.

Fibrin is believed to stimulate the growth of fibroblasts and osteoblasts¹⁵. Bosch et al.²⁷ demonstrated that fibrin adhesive improved bone graft incorporation and remodeling by significantly reducing the size of the gaps between bony fragments and accelerating revascularization. Moreover, the multiplication of bacteria in the fibrin clot is significantly slower than in a comparable blood clot¹⁴.

In addition to the physical benefit of using fibrin glue in reconstructive bone surgery, the glue also accelerates the bone graft healing process^{14,28}, as the fibrin network acts as a scaffold for invading cells³³ and as a carrier for bone induction²⁹.

In general, the smaller a bone defect is, the more easily periodontal tissue regeneration is achieved²⁶. Ohazama et al.²⁶ studied simple bone defects, involving buccal bone, which extended halfway into the interproximal and inter-radicular regions, whereas Warrer and Karring³⁰ studied deep, complex bone defects that involved inter-radicular bone only. FAM might be suitable for small bone defects, such as dehiscences and bony clefts. The differences in the experimental jaw

could also have contributed to the differences in results. Ohazama et al.²⁶ studied the mandible only, while Warrer and Karring³⁰ studied both the mandible and maxilla.

Ohazama et al.²⁶ reported that FAM produced significant differences in new bone formation by 8 weeks after surgery compared to the control sites ($P < .05$). This suggests that FAM enhances the osteogenic potential. The results of experiment 2 suggested that FAM indeed enhances bone formation. In our study, the histomorphometric analysis showed that the bone structures in the control (Bio-Oss alone) and test (Bio-Oss plus fibrin glue) groups were similar.

FAM might act as a material for creating space. It might also act in conjunction with a growth factor, such as bone morphogenic protein (BMP), insulin-like growth factor, or platelet-derived growth factor.

The histologic analyses highlight other advantages of using Tisseel. Tisseel with Bio-Oss enhances the graft volume without affecting the maturation of the new bone.

In this study, the histologic similarities observed between the two groups (Bio-Oss alone, Bio-Oss plus fibrin glue) should enable sinus floor augmentation surgery with a shorter healing period before implant placement. Furthermore, the quantity of the bone material used to fill the sinus cavity can be reduced safely without negatively affecting the final bone density. Finally, the fibrin glue appears to be suitable for treating sinus membrane perforation, permitting the surgery to be completed. The use of fibrin glue, in addition to a bone graft material, to perform sinus floor augmentation is attractive from a histologic perspective.

CONCLUSIONS

Thirty-six sinus grafts were performed in 34 patients with an alveolar crest bone height in the posterior maxilla of 3 to 5 mm before grafting. The sinuses were grafted using Bio-Oss alone or mixed with fibrin glue. Informed consent was obtained from all patients.

Group 1 was the control group and included 25 patients who received a xenograft mixed in saline. Group 2 comprised 9 patients who received a xenograft and fibrin glue. The study was further subdivided at the time of 9 months.

This histologic study evaluated by hematoxylin & eosin (H&E) and histomorphometric analysis whether fibrin

glue in combination with Bio-Oss enhances bone regeneration in sinus floor elevation in humans. The degree of new bone formation (bone forming activity) and composition ratio of the tissue sample were determined by measuring and comparing the area of new bone formation using computer-assisted histomorphometry.

The following results were obtained;

1. Compared to Group 1, in which biopsies were performed at various times, long-term observations were conducted in Group 2, mainly after 7 months, making it difficult to compare the early changes in the two groups.
2. The new bone formation was better in Group 2 than in Group 1, but the difference was not significant.
3. The absorption of the graft material was faster in Group 2 than in Group 1, in the short term, but better in Group 1 over the long term, although the difference was not significant.
4. Lamellar bone was formed earlier in Group 1 compared to Group 2, but the difference was not significant. The long-term difference was not evident in lamellar bone formation.
5. Overall, the surgery site stabilized earlier with new bone formation in Group 2 than in Group 1, but the difference was not significant.

New bone was seen in Bio-Oss and with Bio-Oss plus Tisseel, although the difference was not significant.

Combining a fibrin sealant and Bio-Oss could lead to improved scaffolds for bone tissue engineering based on the synergistic effects of the biomaterials. Therefore, Bio-Oss or Bio-Oss plus Tisseel may be used depending on the situation.

REFERENCES

1. Cordaro L: Bilateral simultaneous augmentation of the maxillary sinus floor with particulated mandible. Report of a technique and preliminary results. *Clin Oral Implants Res* 2003;14:201-206.
2. Boyne PJ, James RA: Grafting of the maxillary sinus floor with autogenous marrow and bone. *J Oral Surg* 1980; 38:613-616.
3. Jeong TY, Kim SG: Histologic study of sinus grafting with Bio-Oss for implant placement. *Hosp Dent (Tokyo)* 2005;17:87-92.
4. Pinholt EM, Bang G, Haanaes HR: Alveolar ridge augmentation in rats by Bio-Oss. *Scand J Dent Res* 1991;99:154-161.
5. Jensen SS, Aaboe M, Pinholt EM, Hjorting-Hansen E, Melsen F, Ruyter IE: Tissue reaction and material characteristics of four bone substitutes. *Int J Oral Maxillofac Implants* 1996;11:55-66.
6. Valentini P, Abensur D: Maxillary sinus floor elevation for implant placement with demineralized freeze-dried bone and bovine bone (Bio-Oss): a clinical study of 20 patients. *Int J Periodontics Restorative Dent* 1997;17:232-241.
7. Hurzeler MB, Kirsch A, Ackermann KL, Quinones CR: Reconstruction of the severely resorbed maxilla with dental implants in the augmented maxillary sinus: a 5-year clinical investigation. *Int J Oral Maxillofac Implants* 1996; 11:466-475.
8. Hising P, Bolin A, Branting C: Reconstruction of severely resorbed alveolar ridge crests with dental implants using a bovine bone mineral for augmentation. *Int J Oral Maxillofac Implants* 2001;16:90-97.
9. Valentini P, Abensur D, Densari D, Graziani JN, Hammerle C: Histological evaluation of Bio-Oss in a 2-stage sinus floor elevation and implantation procedure. A human case report. *Clin Oral Implants Res* 1998;9:59-64.
10. Sanchez AR, Sheridan PJ, Eckert SE, Weaver AL: Influence of platelet-rich plasma added to xenogeneic bone grafts in periimplant defects: a vital fluorescence study in dogs. *Clin Implant Dent Relat Res* 2005;7:61-69.
11. Marx RE, Carlson ER, Eichstaedt RM, Schimmele SR, Strauss JE, Georgeff KR: Platelet-rich plasma: Growth factor enhancement for bone grafts. *Oral Surg Oral Med Oral Pathol Oral Radiol Endod* 1998;85:638-646.
12. Niedhart C, Maus U, Redmann E, Schmidt-Rohlfing B, Niethard FU, Siebert CH: Stimulation of bone formation with an in situ setting tricalcium phosphate/rhBMP-2 composite in rats. *J Biomed Mater Res* 2003;65:17-23.
13. Stefani CM, Machado MA, Sallum EA, Sallum AW, Toledo S, Nociti FH Jr: Platelet-derived growth factor/insulin-like growth factor-1 combination and bone regeneration around implants placed into extraction sockets: a histometric study in dogs. *Implant Dent* 2000;9:126-131.
14. Tayapongsak P, O'Brien DA, Monteiro CB, Arceo-Diaz LY: Autologous fibrin adhesive in mandibular reconstruction with particulate cancellous bone and marrow. *J Oral Maxillofac Surg* 1994;52:161-165.
15. Matras H: Fibrin seal: the state of the art. *J Oral Maxillofac Surg* 1985;43:605-611.
16. Diamond MP, Kruger M, Saed GM: Effect of Tisseel on expression of tissue plasminogen activator and plasminogen activator inhibitor-1. *Fertil Steril* 2004;81:1657-1664.
17. Yamada Y, Boo JS, Ozawa R, Nagasaka T, Okazaki Y, Hata K, Ueda M: Bone regeneration following injection of mesenchymal stem cells and fibrin glue with a biodegradable scaffold. *J Craniomaxillofac Surg* 2003;31:27-33.
18. Keller J, Andreassen TT, Joyce F, Knudsen VE, Jorgensen PH, Lucht U: Fixation of osteochondral fractures. Fibrin sealant tested in dogs. *Acta Orthop Scand* 1985;56:323-326.
19. Marktl W, Rudas B: The effect of factor XIII on wound granulation in the rat. *Thromb Diath Haemorrh* 1974; 32:578-581.
20. Choukroun J, Diss A, Simonpieri A, Girard MO, Schoeffler C, Dohan SL, Dohan AJ, Mouhyi J, Dohan DM: Platelet-rich fibrin (PRF): a second-generation platelet concentrate. Part V: histologic evaluations of PRF effects on bone allograft maturation in sinus lift. *Oral Surg Oral Med Oral Pathol Oral Radiol Endod* 2006;101:299-303.
21. Wittkampf AR: Fibrin glue as cement for HA-granules. *J Craniomaxillofac Surg* 1989;17:179-181.
22. Nakamura K, Koshino T, Saito T: Osteogenic response of the rabbit femur to a hydroxyapatite thermal decomposition product-fibrin glue mixture. *Biomaterials* 1998;19:1901-1907.
23. von Arx T, Cochran DL, Hermann JS, Schenk RK, Buser D: Lateral ridge augmentation using different bone fillers and barrier membrane application. A histologic and histomorphometric pilot study in the canine mandible. *Clin Oral Implants Res* 2001;12:260-269.
24. Kim MJ, Kim YK, Kim SG: Various bone grafting materials

- in the dental surgery, Narae Publishing Inc., 2004.
25. Piattelli M, Favero GA, Scarano A, Orsini G, Piattelli A: Bone reactions to anorganic bovine bone (Bio-Oss) used in sinus augmentation procedures: a histologic long-term report of 20 cases in humans. *Int J Oral Maxillofac Implants* 1999;14:835-840.
 26. Ohazama A, Isatsu K, Hatayama J, Okamatsu Y, Tachikawa T, Hasegawa K: Periodontal tissue regeneration using fibrin tissue adhesive material in vitro and in vivo. *Periodontal Clin Investig* 1996;18:26-38.
 27. Bosch P, Lintner F, Arbes H, Brand G: Experimental investigations of the effect of the fibrin adhesive on the Kiel heterologous bone graft. *Arch Orthop Trauma Surg* 1980; 96:177-185.
 28. Thorn JJ, Sorensen H, Weis-Fogh U, Andersen M: Autologous fibrin glue with growth factors in reconstructive maxillofacial surgery. *Int J Oral Maxillofac Surg* 2004;33:95-100.
 29. Kawamura M, Urist MR: Human fibrin is a physiologic delivery system for bone morphogenetic protein. *Clin Orthop Relat Res* 1988;235:302-310.
 30. Warrer K, Karring T: Effect of Tisseel on healing after periodontal flap surgery. *J Clin Periodontol* 1992;19:449-454.