

## Case Report

# Intracranial Metastases of Cervical Intramedullary Low-Grade Astrocytoma without Malignant Transformation in Adult

Se Youn Jang, M.D.,<sup>1</sup> Min Ho Kong, M.D.,<sup>1</sup> Kwan Young Song, M.D.,<sup>1</sup> John G. Frazee, M.D.<sup>2</sup>

Department of Neurosurgery,<sup>1</sup> Seoul Medical Center, Seoul, Korea

Department of Neurosurgery,<sup>2</sup> University of California at Los Angeles, California, USA

The first case of intracranial metastases of a cervical intramedullary low-grade astrocytoma without malignant transformation in adult is presented in this report. Seven years ago, a 45 year-old male patient underwent biopsy to confirm pathologic characteristics and received craniocervical radiation and chemotherapy for a grade II astrocytoma in the cervical spinal cord. Two years later, posterior fusion was necessary for progressive kyphosis in the cervical spine. He was well for approximately 7 years after the primary surgery. Two months ago, he presented with partial weakness and incoordination with gait difficulty. MRI Scan demonstrated multiple small lesions in the cerebellar vermis and left hemisphere. After suboccipital craniectomy and posterior cervical exposure, the small masses in the cerebellar vermis and hemispheres were excised to a large extent by guidance of an intraoperative navigation system. The tumor at the cervical and brain lesions was classified as an astrocytoma (WHO grade II). When a patient with low-grade astrocytoma in the spinal cord has new cranial symptoms after surgery, radiation, and chemotherapy, the possibility of its metastasis should be suspected because it can spread to the intracranial cavity even without malignant transformation as shown in this case.

**KEY WORDS :** Astrocytoma · Intramedullary · Spinal cord tumor · Cranial metastases.

## INTRODUCTION

Spinal cord astrocytomas are uncommon, accounting for less than 1% of all primary neoplasms in the central nervous system<sup>4,7,8,10,20</sup>. Cerebral metastases of a primary spinal astrocytoma have rarely been reported<sup>1,6,13,17,19,22,24,25</sup>. Of the spinal cord gliomas reported to have metastasized to the brain, most were anaplastic astrocytomas or glioblastoma multiforme<sup>7,13,19,20,24,25</sup>. Seeding to cranial sites from intramedullary low-grade astrocytoma has been reported in only a few cases; these have reported intracranial spread of intramedullary pilocytic astrocytoma without malignant transformation in a child<sup>1,17</sup> and with malignant transformation in an adult<sup>6,19,24</sup>.

We report the case of a metastatic spread to the cerebellum of a low-grade astrocytoma without malignant transformation

in a 52 year-old male. In this case, despite the presence of multiple small lesions, the authors were able to safely remove several lesions with the guidance of an intraoperative navigation system. The goal of this report is to alert neurosurgeons to the possibility of intracranial spread of primary spinal cord astrocytomas even without malignant transformation in those patients who have cranial symptoms, especially those with a history of incomplete removal at the cervical levels.

## CASE REPORT

This patient was a 45-year-old male who had presented 7 years ago with a history of increasing pain and weakness in the right upper extremity, particularly in proximal region. An MRI scan revealed a mass infiltrating through the cervical spinal cord from C2 to C4. A laminectomy from C1 to C6 and biopsy of the tumor was carried out. But, the authors couldn't get the initial cervical MR images. After first operation (biopsy), T2-weighted cervical MRI (Fig. 1A) was taken immediately, and it showed solid intrinsic tumor of

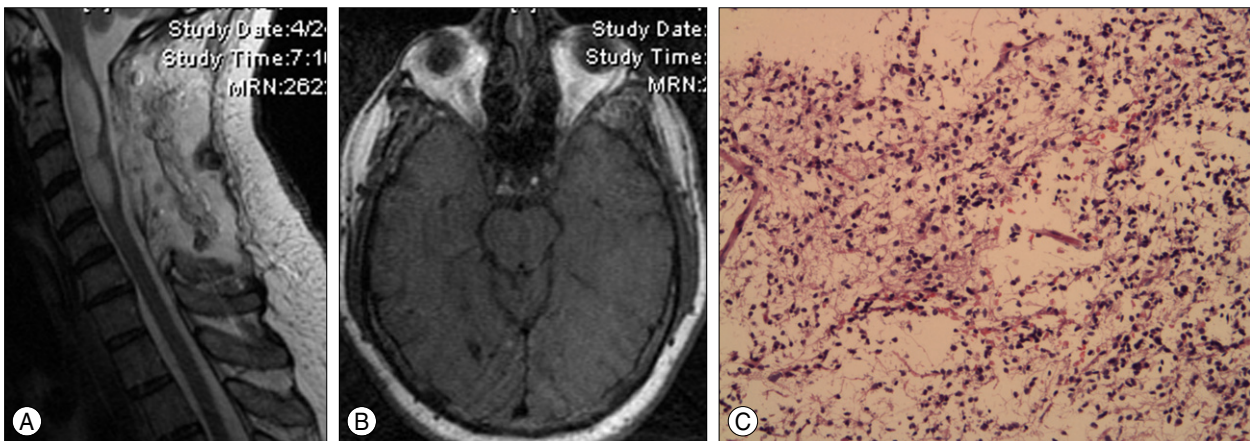
• Received : September 1, 2008 • Accepted : May 18, 2009

• Address for reprints : Min Ho Kong, M.D.

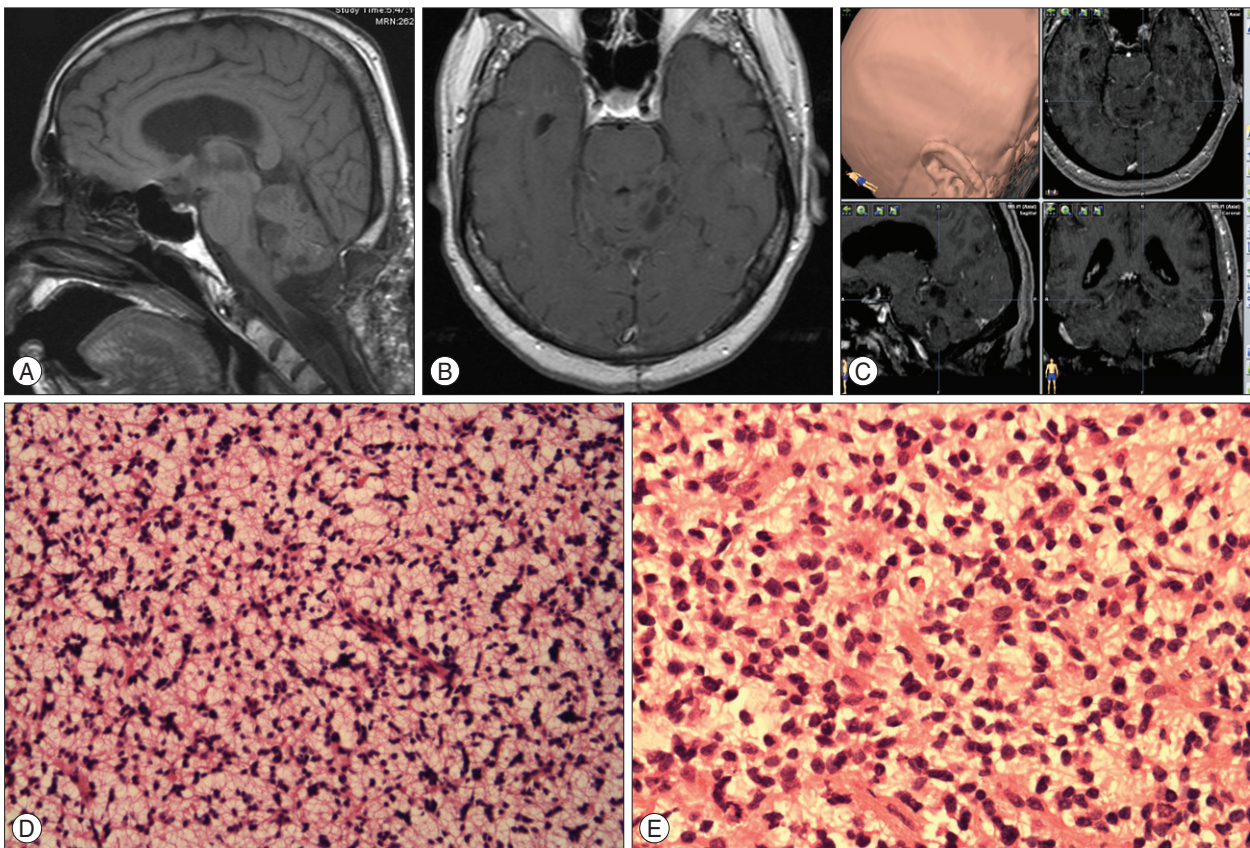
Department of Neurosurgery, Seoul Medical Center, 171-1 Samseong-dong, Gangnam-gu, Seoul 135-740, Korea

Tel : +82-2-3430-0645, Fax : +82-2-557-8207

E-mail : davidmhkong@gmail.com



**Fig. 1.** T2-weighted cervical magnetic resonance image (MRI) (A) taken immediately after first operation (biopsy) showing solid intrinsic tumor of the cervical spinal cord (C2-4). At the same time, brain MRI (B) shows no evidence of spread of tumor and dilation of ventricle. Photomicrograph of biopsy of cervical cord lesion at the first operation demonstrates small hyperchromatic astrocytic cells in a loose, fibrillary background (C). Individual tumor cells are moderately pleomorphic and contain round or angulated hyperchromatic nuclei with irregular contours. Endothelial hyperplasia and necrosis are not present. Mitoses are inconspicuous. Fairly large blood vessels are present, but appear to have a normal appearance (Hematoxylin-eosin, original magnification,  $\times 200$ ).



**Fig. 2.** Brain magnetic resonance image (MRI) scans showing multiple small lesions located in the vermis and hemispheres of the cerebellum, and midbrain (A). The lesions of cerebellar vermis are multiple and hypointense on T1-weighted axial images of brain MRI with no contrast enhancement (B). Intraoperative navigation MRI of T1-weighted enhanced images shows multiple metastatic lesions with low signal in the posterior fossa (C). Photomicrograph demonstrates Grade II astrocytoma of the cerebellar vermis (D) (Hematoxylin-eosin, original magnification,  $\times 200$ ) and which is compatible with cervical cord lesion (E) (Hematoxylin-eosin, original magnification,  $\times 400$ ).

the cervical spinal cord. At the same time, brain MRI (Fig. 1B) showed no evidence of spread of tumor and dilation of ventricle. Histologic sections of the tumor showed small hyperchromatic astrocytic cells in a loose, fibrillary back-

ground. Individual tumor cells were moderately pleomorphic and contained round or angulated hyperchromatic nuclei with irregular contours (Fig. 1C). Endothelial hyperplasia and necrosis were not present, and mitoses were inconspicuous.

cuous. Glial fibrillary acidic protein (GFAP) immunostaining showed the tumor cells to be diffusely positive, thereby confirming the astrocytic origin of the tumor and confirming the diagnosis of a grade II astrocytoma. In the regions of highest nuclear reactivity the MIB-1 proliferation index was estimated at approximately 2-3% of tumor cells. Overall, the proliferation index was estimated to be approximately 1% of tumor cells. After first operation, craniospinal irradiations were conducted with a total dose of 50 Gy and followed by chemotherapy (12 cycles of Temodar and 6 cycles of CCNU, and 12 cycles of carboplatin). Severe kyphosis was shown on plain X-ray 2 years after the first surgery. C2 to C6 instrumentation and posterolateral fusion with harvesting of bone graft from the iliac crest was conducted due to cervical instability.

After having done well for approximately 7 years, the patient presented with new complaints 2 months ago. The patient was developing some weakness and gait difficulty with incoordination. He also complained of vertigo and vomiting. He felt that he was becoming weaker and more unstable when walking, and that his hands were becoming weaker, particularly his right hand, which caused difficulty with writing. He also complained of headaches in the morning for a few hours and neck pain. The patient does not smoke but drinks alcohol only occasionally. His family history is insignificant for tumors of the brain or spinal cord. He had no concurrent infection or transient ischemic attacks. MRI Scan (Fig. 2A, B) demonstrated multiple small lesions in the cerebellar vermis and left cerebellar hemisphere along with ventricular dilatation. Intraoperative T1-weighted enhanced brain MRI scan showed multiple small hypointense lesions in posterior fossa (Fig. 2C). When these scans were repeated 1 month ago, it appeared that some of these had enlarged in size.

A suboccipital craniectomy and posterior cervical exposure were conducted. The small masses in the cerebellar vermis and left hemisphere were excised completely by guidance of an intraoperative navigation system (Vector-Vision, BrainLAB). The cervical cord showed substantial amount of tumor growing out dorsally from the pia-arachnoid at C2. A biopsy was conducted at the site of the bulged cervical mass.

The microscopic exam sections (Fig. 2D) of the cerebellar lesions showed a glial tumor on a myxoid background. The tumor cells were bland and arranged in patternless sheets on a focally microcystic background. The tumor cells were small to medium in size with small round-oval, monotonous, hyperchromatic nuclei and eosinophilic and fibrillary cytoplasm. Mitoses, necrosis, and endothelial hyperplasia were inconspicuous. In some areas the tumor was quite well

demarcated from the surrounding parenchyma. The tumors at the cervical (Fig. 2E) and brain lesions were both classified as astrocytomas (WHO grade II). On immunohistochemistry stain, GFAP was positive in tumor cells at both locations. Ki-67 was positive in 10-20% of tumor cells. After surgery, he had respiratory difficulty due to cervical cord swelling, but respiratory function was recovered after using steroids.

## DISCUSSION

Spinal cord tumors account for 2-5% of central nervous systems neoplasms in adults<sup>1,7,20</sup>. Intramedullary spinal cord astrocytomas represent only 6-8% of spinal cord tumors<sup>4,15,16</sup>. Dissemination of tumor cells has been reported in virtually all types of primary central nervous system neoplasms. Spinal spread of primary intracranial tumors is not unusual, and autopsy series have found such spread in anywhere from 20 to 36% of supratentorial tumors and up to 60% of infratentorial lesions<sup>19</sup>. This phenomenon is predominantly observed in malignant tumors, especially medulloblastomas, germ cell tumors, and high-grade gliomas.

Leptomeningeal dissemination from intracranial low-grade glioma is less common and has been estimated to occur in 5% at presentation and 7 to 10% with disease progression of all cases. Spinal cord gliomas have many unusual features which distinguish them from their intracranial counterparts. Most of the metastases of spinal cord gliomas were generally anaplastic astrocytomas or glioblastomas and there have been only a few reports on intracranial metastases of spinal cord gliomas to date<sup>24</sup>. Santi et al.<sup>20</sup> reported that there is a high risk of central nervous system dissemination in patients with spinal cord malignant astrocytoma. Intracranial dissemination of spinal cord low-grade gliomas has been reported very few times<sup>6,19</sup>.

When intramedullary low-grade astrocytomas metastasize intracranially, most of them have malignant transformation<sup>6,19</sup>. In most of the cases reported up until now, spinal cord tumors that spread intracranially had previous malignant transformation or were high-grade gliomas<sup>7,21,24,25</sup>, even though in children, some cases without malignant transformation have been reported<sup>1,2,5,9,11,17</sup>. In 1995, Claus et al.<sup>6</sup> reported the case of a 43-year-old man with intracranial dissemination of a WHO Grade I pilocytic astrocytoma of the cauda equina. Two years after initial resection of the tumor, a second resection was performed for recurrence, and the histological findings from this operation revealed a transformation to a WHO Grade II astrocytoma. More recently, in 2004, Peraud et al.<sup>19</sup> reported the case of a 14-year-old boy who presented with an intramedullary spinal



cord tumor at the T11-12 level. No intracranial lesion was present at that time; the histological diagnosis made after the first resection was an atypical pilocytic astrocytoma (WHO Grade II). Four years after the initial presentation, MRI images revealed contrast-enhancing lesions around the third and fourth ventricles and recurrence of the spinal cord tumor at the initial resection site. A pathological evaluation was consistent with an anaplastic pilocytic astrocytoma (WHO Grade III). In our patient, we had been concerned that malignant transformation of an adult astrocytoma may have occurred, but this is a rare case of an intracranial spread of spinal cord low-grade astrocytoma without malignant transformation in an adult.

The mechanism of metastasis of spinal cord low-grade astrocytomas is a debatable issue, and many hypotheses have been proposed. The dissemination of neuroepithelial tumors occurs by means of either local spread, metastasis by the cerebrospinal fluid (CSF) pathway, or remote metastasis<sup>5)</sup>. Several mechanisms have been proposed to explain the spread of intracranial tumors by CSF pathways. Intraspinous metastases can occur in patients with cerebral astrocytomas through the CSF pathways. The same mechanism of tumor cell distribution via the CSF may contribute to the inverse situation of cranial seeding of a primary spinal tumor. It has been hypothesized that malignant transformation, cellular anaplasia, surgical manipulation, natural history, or multiplicity may contribute to the spread of the tumor<sup>11)</sup>.

Progressive tumors tend to spread. However, in this case intracranial metastases were found without any malignant transformation. Several other mechanisms of spread can be considered for this case. One such possibility is that metastatic spread may have been enhanced by surgical manipulation as, in this case, surgery of the primary tumor did precede the intracranial metastases<sup>22)</sup>. Abel et al.<sup>1)</sup> reported that tumor manipulation would contribute to dissemination through the exposure of tumor cells to the CSF<sup>3)</sup>. But, in this case, after surgery, 7 years had passed without recurrence so this hypothesis is unlikely.

Other reports have paid attention to the pathological characteristics of the tumor. The hypothesis is that there is an aggressive phenotype in spinal cord low-grade gliomas that has a poor outcome<sup>1)</sup>. It was supported by the observation that overexpression of epidermal growth factor receptor could cause low-grade gliomas, or perhaps a subset of cells within the tumor, to act more aggressively, and lead to leptomeningeal dissemination<sup>18)</sup>. Some investigators reported that certain variants of pilocytic astrocytoma and pilomyxoid astrocytomas of the spinal cord had more aggressive patterns than pilocytic astrocytomas<sup>12)</sup>. Kopelson et al.<sup>13)</sup> reported that two of six patients with intracranial seeding from low-

grade spinal cord astrocytomas had mixed oligodendrogliomatous elements and such mixed tumors have an increased propensity for subarachnoid seeding. But, in this case, the tumor did not contain mixed component.

There is also a report of intracranial seeding of a spinal cord tumor occurring in immunosuppressed patients. Yamashita et al.<sup>25)</sup> reported intracranial dissemination from a thoracic spinal cord anaplastic astrocytoma in an immunosuppressed patient with idiopathic CD4-positive T lymphocytopenia. They reported that clinical awareness of metastatic events of spinal cord tumors in immunosuppressed patients is clearly important<sup>25)</sup>. Radiation and chemotherapy made our patient immunosuppressed, but he stopped receiving those 6 years before the occurrence of intracranial spread so this possibility is also unlikely.

Surgical resection using an operating microscope often leads to an improvement in the resulting neurological deficits. But, the value of aggressive resection in high-grade spinal cord astrocytomas is unclear<sup>10)</sup>. Infiltrating astrocytomas of the spinal cord pose a treatment challenge because they usually are not amenable to total resection due to the high morbidity of surgery. The tissue of low-grade astrocytoma is similar to normal tissue and difficult to differentiate grossly. Compared to the more circumscribed ependymoma, the infiltrative nature of spinal cord astrocytomas frequently limits the extent of resection. The majority of spinal cord astrocytomas tends to progress slowly but is not well-demarcated and difficult to completely remove without neurological injury<sup>23)</sup>. The intention of authors in the first surgery was to do a minimal resection and get pathologic specimens while avoiding risk of neurological deterioration. In this case, it was impossible to remove the whole pathologic lesion in the cervical cord, due to the critical function of this area in respiration. Thus, this cervical cord intramedullary tumor was incompletely removed. Even when tumor removal is accomplished there is no doubt that microscopically residual fragments remain<sup>4)</sup>. Additional radiation or chemotherapy should be considered for tumors with clinically progressive lesions and in which a complete resection could not be achieved<sup>10)</sup>. Its prognosis is dependent on the long-term behavior of the residual tumor. When the authors tried to find the cause of the intracranial metastases without any signs of malignant transformation, we concluded that the tumor remaining after incomplete removal was the source of seeding, and that the volume of the remaining tumor might have contributed to the intracranial spread.

Some reports indicate that patients with a spinal tumor may also present with signs and symptoms of increased intracranial pressure without evidence of dissemination due to tumor mass interfering with CSF dynamics, arachnoid

villi fluid absorption blocked by high CSF protein levels, and exudation of fluid from the tumor<sup>24</sup>). Maurice-Williams and Lucey<sup>1,14</sup>) reported that hydrocephalus is associated with leptomeningeal fibrosis which might predispose a patient to secondary implantation of neoplastic elements, such as “neoplastic arachnoiditis” in the subarachnoid spaces of the intracranial compartment. This patient presented concurrently with hydrocephalus and intracranial spread, but due to the cerebellar location of the multiple metastatic lesions, the exact cause of hydrocephalus is unclear.

## CONCLUSION

The first case of intracranial metastases of a cervical intramedullary low-grade astrocytoma without malignant transformation in adult is presented in this report. When a patient with a low-grade astrocytoma in the spinal cord and a history of minimal resection of the tumor has new cranial symptoms, intracranial metastases should be suspected because the remaining tumor may contribute to intracranial spread through the CSF.

### • Acknowledgements

The authors thank to Dr. Yun Kyung Lee from the Department of Pathology in the Seoul Medical Center, Duc H. Do (BS) in the David Geffen School of Medicine at UCLA, and to Dr. Harry V. Vinters from the Department of Pathology & Laboratory Medicine & Neurology in the University of California at Los Angeles for their assistance to thoughtful comments on the manuscript.

## References

1. Abel TJ, Chowdhary A, Thapa M, Rutledge JC, Geyer JR, Ojemann J, et al : Spinal cord pilocytic astrocytoma with leptomeningeal dissemination to the brain. Case report and review of the literature. *J Neurosurg* 105 : 508-514, 2006
2. Aryan HE, Meltzer HS, Lu DC, Ozgur BM, Levy ML, Bruce DA : Management of pilocytic astrocytoma with diffuse leptomeningeal spread : two cases and review of the literature. *Childs Nerv Syst* 21 : 477-481, 2005
3. Bell WO, Packer RJ, Seigel KR, Rorke LB, Sutton LN, Bruce DA, et al : Leptomeningeal spread of intramedullary spinal cord tumors. Report of three cases. *J Neurosurg* 69 : 295-300, 1988
4. Bouffet E, Amat D, Devaux Y, Desuzingues C : Chemotherapy for spinal cord astrocytoma. *Med Pediatr Oncol* 29 : 560-562, 1997
5. Cinalli G, Sainte-Rose C, Lellouch-Tubiana A, Sebag G, Renier D, Pierre-Kahn A : Hydrocephalus associated with intramedullary low-grade glioma. Illustrative cases and review of the literature. *J Neurosurg* 83 : 480-485, 1995
6. Claus D, Sieber E, Engelhardt A, Rechlin T, Neubauer U, Volk B : Ascending central nervous spreading of a spinal astrocytoma. *J Neurooncol* 25 : 245-250, 1995
7. Elsamaloty H, Zenooz NA, Mossa-Basha M : Glioblastoma multiforme (GBM) of the conus medullaris with brain and brain stem metastases. *European Journal of Radiology Extra* 58 : 59-62, 2006
8. Epstein FJ, Farmer JP, Freed D : Adult intramedullary astrocytomas of the spinal cord. *J Neurosurg* 77 : 355-359, 1992
9. Gajjar A, Bhargava R, Jenkins JJ, Heideman R, Sanford RA, Langston JW, et al : Low-grade astrocytoma with neuraxis dissemination at diagnosis. *J Neurosurg* 83 : 67-71, 1995
10. Henson JW : Spinal cord gliomas. *Curr Opin Neurol* 14 : 679-682, 2001
11. Kanda M, Tanaka H, Shinoda S, Masuzawa T : Leptomeningeal dissemination of pilocytic astrocytoma via hematoma in a child. Case report. *Neurosurg Focus* 13 : 1-6, 2002
12. Komotar RJ, Carson BS, Rao C, Chaffee S, Goldthwaite PT, Tihan T : Pilocytic astrocytoma of the spinal cord : report of three cases. *Neurosurgery* 56 : 191, 2005
13. Kopelson G, Linggood RM : Intramedullary spinal cord astrocytoma versus glioblastoma. : the prognostic importance of histologic grade. *Cancer* 50 : 732-735, 1982
14. Maurice-Williams RS, Lucey JJ : Raised intracranial pressure due to spinal tumours : 3 rare cases with a probable common mechanism. *Br J Surg* 62 : 92-95, 1975
15. Minehan KJ, Shaw EG, Scheithauer BW, Davis DL, Onofrio BM : Spinal cord astrocytoma : pathological and treatment considerations. *J Neurosurg* 83 : 590-595, 1995
16. Nakamura M, Chiba K, Ishii K, Ogawa Y, Takaishi H, Matsumoto M, et al : Surgical outcomes of spinal cord astrocytomas. *Spinal Cord* 44 : 740-745, 2006
17. Ng HK, Leung CH, Boet R, Poon WS : Spinal cord pilocytic astrocytoma with cranial meningeal metastases. *J Clin Neurosci* 8 : 374-377, 2001
18. Penar PL, Khoshyomn S, Bhushan A, Tritton TR: Inhibition of epidermal growth factor receptor-associated tyrosine kinase blocks glioblastoma invasion of the brain. *Neurosurgery* 40 : 141-151, 1997
19. Peraud A, Herms J, Schlegel J, Müller P, Kretschmar H, Tonn JC : Recurrent spinal cord astrocytoma with intraventricular seeding. *Childs Nerv Syst* 20 : 114-118, 2004
20. Santi M, Mena H, Wong K, Koeller K, Olsen C, Rushing EJ : Spinal cord malignant astrocytomas. Clinicopathologic features in 36 cases. *Cancer* 98 : 554-561, 2003
21. Strik HM, Effenberger O, Schäfer O, Risch U, Wickboldt J, Meyer-mann R : A case of spinal glioblastoma multiforme : immunohistochemical study and review of the literature. *J Neurooncol* 50 : 239-243, 2000
22. Tijssen CC, Sluzewski M : Spinal astrocytoma with intracranial metastases. *J Neurooncol* 18 : 49-52, 1994
23. Townsend N, Handler M, Fleitz J, Foreman N : Intramedullary spinal cord astrocytomas in children. *Pediatr Blood Cancer* 43 : 629-632, 2004
24. Umezū H, Seki Y, Aiba T, Matsuya S : Intracranial seeding following surgery for spinal cord astrocytoma--case report. *Neurol Med Chir (Tokyo)* 32 : 281-284, 1992
25. Yamashita Y, Kumabe T, Jokura H, Tominaga T, Yoshimoto T : Intracranial dissemination from thoracic spinal cord anaplastic astrocytoma in a patient with idiopathic CD4-positive T lymphocytopenia : a case report. *Surg Neurol* 56 : 39-41, 2001