

## Case Report

Jae-Hoon Kim, M.D.<sup>1</sup>Hyeong-Joong Yi, M.D.<sup>2</sup>

# Contralateral Intraparenchymal Hemorrhage Following Aneurysmal Clipping

Post-clipping intraparenchymal hemorrhage of the contralateral hemisphere is a very unusual phenomenon in a patient with aneurysmal subarachnoid hemorrhage, unless there is an underlying condition. We report a complicated case of 47-year-old man, who underwent uneventful clipping of ruptured aneurysm and experienced vasospasm two weeks later. Vasospasm was treated by intra-arterial nimodipine and systemic hyperdynamic therapy. One week thereafter, he became unconscious due to intraparenchymal hemorrhage on the anterior border-zone of contralateral hemisphere, but intraoperative and pathologic findings failed to disclose any vascular anomaly. We suggest that the anti-spastic regimens cause local hemodynamic redistribution through the vasodilatory effect and in turn, resulted in such an unexpected bleeding.

**KEY WORDS :** Border-zone · Cerebral aneurysm · Hyperdynamic therapy · Intraparenchymal hemorrhage (Intra-arterial) Nimodipine injection · Vasospasm.

Department of Neurosurgery<sup>1</sup>  
Nowon Eulji Hospital  
Seoul, Korea

Department of Neurosurgery<sup>2</sup>  
Hanyang University  
Medical Center, Seoul, Korea

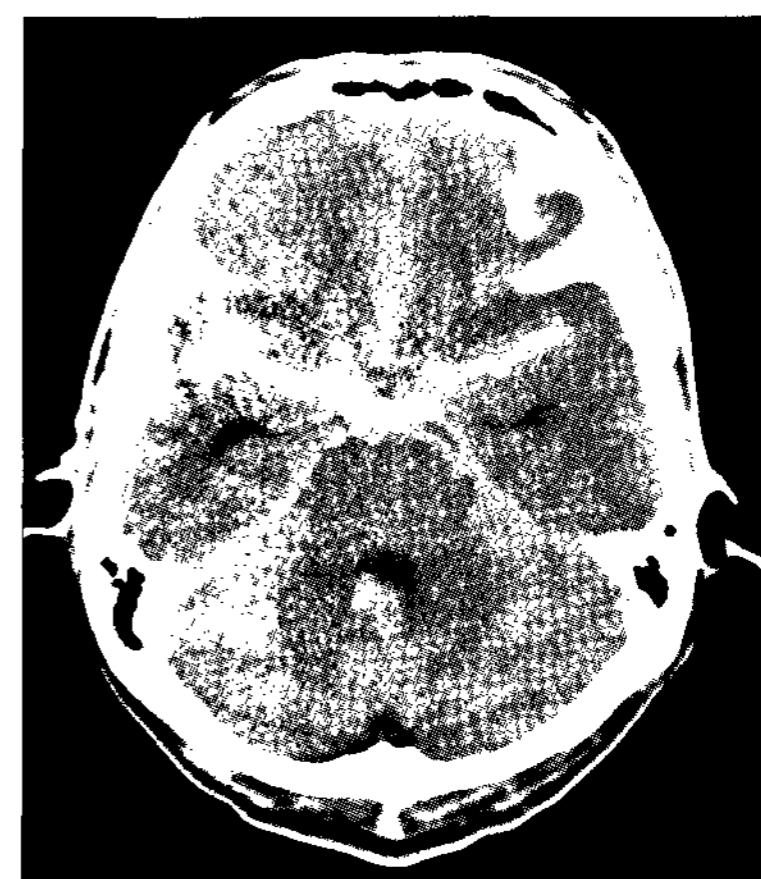## INTRODUCTION

Intracranial hemorrhage occurs following aneurysm surgery, usually within or adjacent to the site of the initial operative field, but sometimes it happens apart from the craniotomy site. In most instances, a certain causative factor is present or at least, can be assumed<sup>2,8</sup>. As an established strategy against vasospasm following aneurysmal subarachnoid hemorrhage (SAH), both hyperdynamic therapy and pharmacological endovascular reversal have been currently utilized. However, they may cause a potential risk of intracranial bleeding<sup>7</sup>. Once occurred, this post-treatment hemorrhage should be seriously managed to avoid consequent morbidity and mortality<sup>9,11</sup>. We report a case of contralateral intraparenchymal hemorrhage (IPH) following endovascular reversal with nimodipine injection and aggressive hyperdynamic therapy in a patient who suffered from cerebral vasospasm after unremarkable aneurysmal clipping.

## CASE REPORT

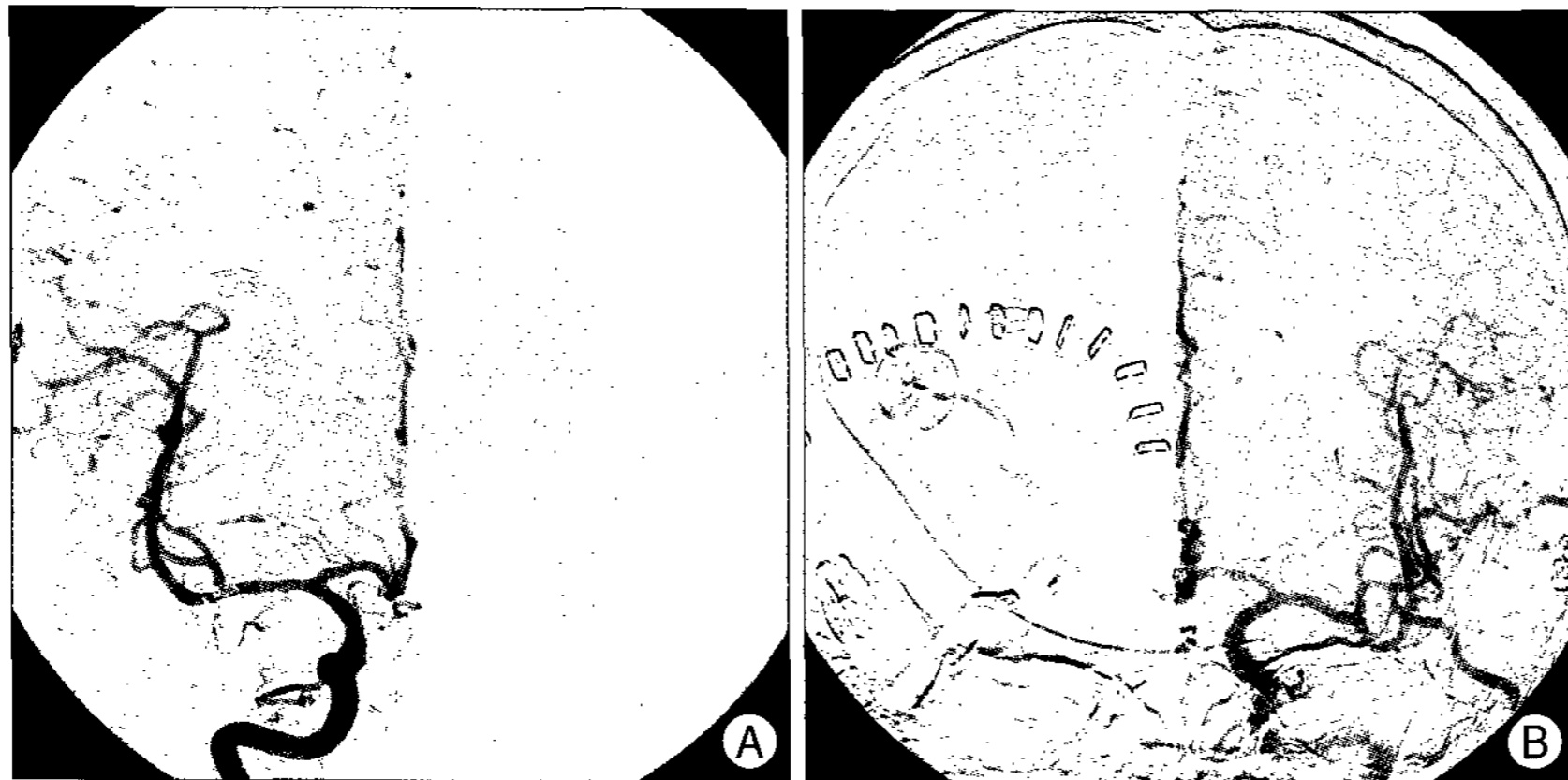
A 47-year-old, previously healthy man presented with a Hunt-Hess grade III SAH from a ruptured saccular aneurysm of the right middle cerebral artery (MCA), (Fig. 1). After uneventful aneurysmal clipping, the patient was able to respond to verbal commands well with full movements of all extremities. Usual prophylactic anti-spastic regimens including systemic nimodipine and crystalloid infusion were provided. Femoral catheter angiograms on postoperative day 3 did not show any residual aneurysm, vasospasm or vascular anomalies elsewhere in the brain (Fig. 2).

On postoperative day 14, it was noted that the patient became obtunded and left hemiparetic (Grade 3/Grade 4), but a brain computed tomography (CT) scan revealed no pathologic findings within the brain. Subsequent catheter angiograms showed a moderate

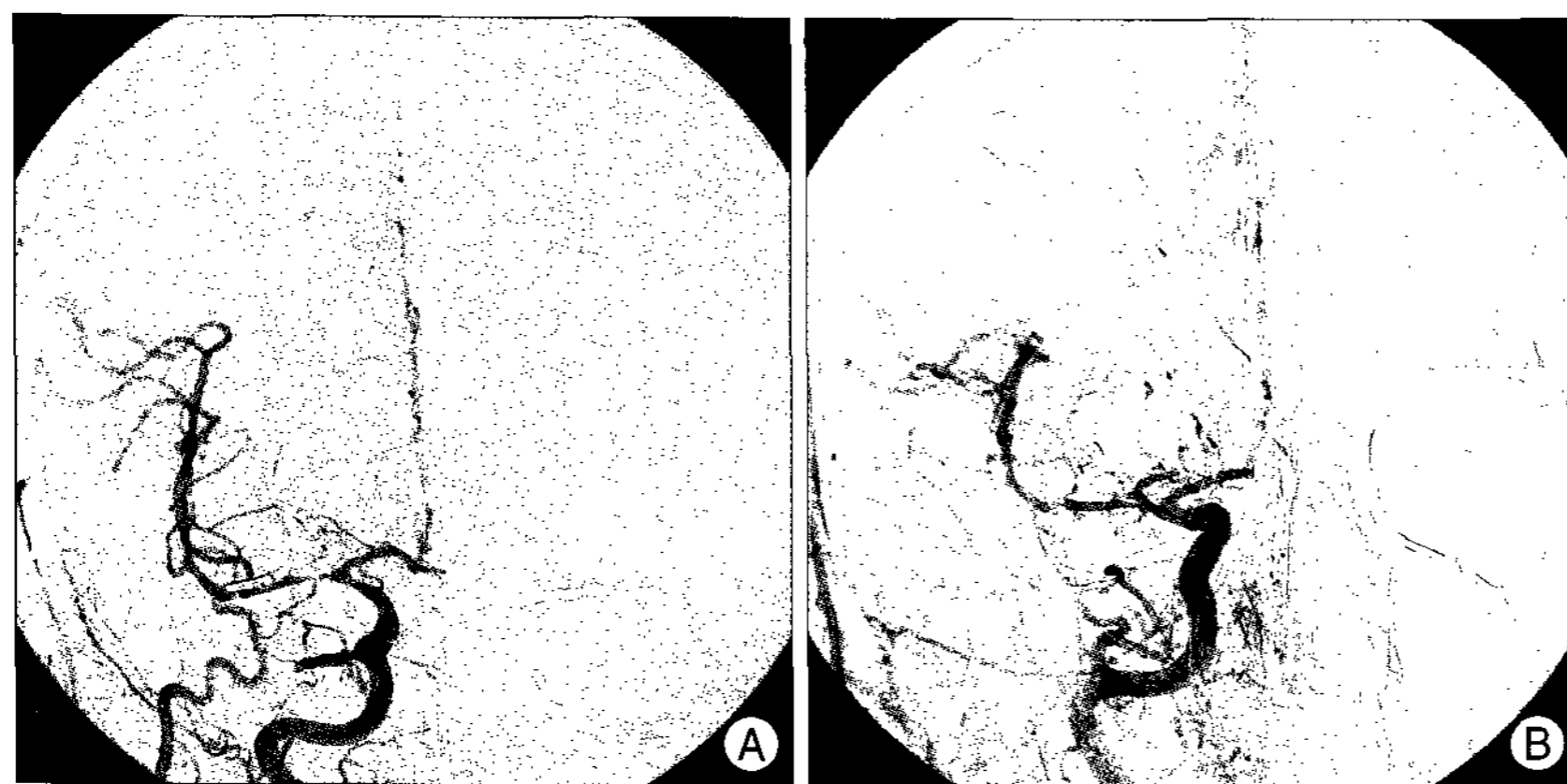

**Fig. 1.** Non-enhanced axial computed tomogram shows diffuse subarachnoid hemorrhage, with slightly thicker hemorrhage on the right Sylvian fissure.

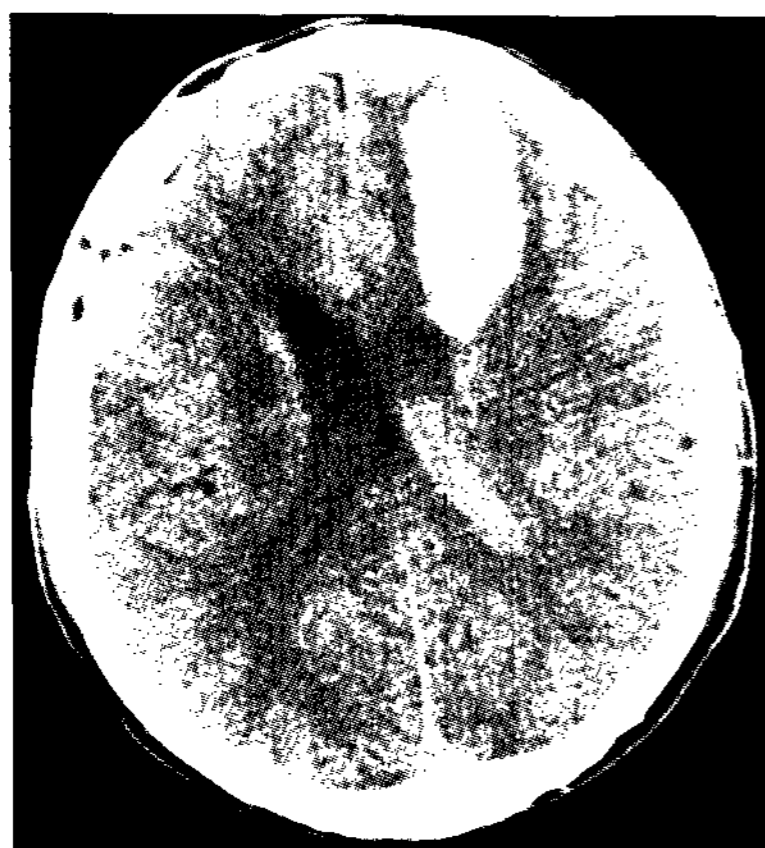• Received : December 11, 2007  
• Accepted : March 18, 2008  
• Address for reprints :  
Hyeong-Joong Yi, M.D.  
Department of Neurosurgery  
Hanyang University Medical Center  
17 Haengdang-dong  
Seongdong-gu, Seoul 133-792, Korea  
Tel : +82-2-2290-8499  
Fax : +82-2-2281-0954  
E-mail : hjyi8499@hanyang.ac.kr



**Fig. 2.** Transfemoral catheter arteriograms of both carotid arteries on postoperative day 3 show no residual aneurysmal sac, vasospasm (A), or vascular anomalies (B).



**Fig. 3.** Transfemoral catheter arteriograms on postoperative day 14 show a moderate vasospasm on the right proximal middle cerebral artery and proximal carotid artery (A). Note the resolution of vasospasm following intra-arterial nimodipine injection and prominent flow through the posterior communicating artery channel (B).



**Fig. 4.** Brain computed tomographic scan on postoperative day 21 shows a wedge-shaped intraparenchymal hemorrhage on the left anterior border-zone with mass effect.

4 L/day of intravascular fluid, and induced-hypertension with dopamine and dobutamine were provided. The patient gradually regained motor power up to the baseline level. Transcranial Doppler ultrasonography was performed twice,

vasospasm at the right proximal MCA (M1) segment, and 5 mg of nimodipine was slowly injected via the arterial route. Meanwhile, there was no significant hemodynamic change, and vasospasm was consequently resolved (Fig. 3). During the intensive care unit (ICU) stay, a hyperdynamic therapy constituting

first and fourth day of ICU stay, but the velocity was normal and flow was bilaterally symmetric.

On postoperative Day 21, 7th day in the ICU, he became unresponsive and brain CT scan showed an IPH on the contralateral frontal lobe (Fig. 4). Because there was no culprit evidence of this unusual intracranial bleeding in prior imaging studies, additional radio-contrast agent was not used. Moreover, his blood pressure did not exceed 180 mmHg during his ICU stay and laboratory results indicated that all hematologic and coagulation profiles were within normal range. We rushed the patient into the operating room for decompression. Throughout the operative procedure, any vascular anomaly or unexpected situation was not encountered, and pathologic examination also verified only organizing hematoma. He is now fully awakened but still has some degrees of abulia, dysphasia and moderate motor weakness on the right side after ventriculo-peritoneal shunting for hydrocephalus.

## DISCUSSION

Post-craniotomy IPH remote from the operative site might result from sustained hypertension, iatrogenic trauma, abnormal blood coagulation, and occult vascular malformation<sup>8)</sup>. Additionally, brain shift due to excessive drainage of the cerebrospinal fluid or cerebral circulatory dysfunction, diaschisis can also result in a certain type of hemorrhage such as in the cerebellum or in the distant hemisphere<sup>4,6)</sup>. In the present case, there was no pertinent cause explaining IPH in the contralateral hemisphere on the basis of clinical data, laboratory results and radiographic images. There was also no any traumatic episode. This situation made us believe that a hemodynamically induced perfusion abnormality might play a critical role in inducing an unusual bleeding. Although we did not obtain real-time perfusion images such as perfusion CT scan or single photon emission CT and contralateral carotid angiography at that time, location of the hemorrhage was approximately anterior border-zone between anterior and middle cerebral arteries. This fact prompted us the possibility of vasospasm on the opposite carotid artery and subsequent vasodilation and resulting

reperfusion injury.

Cerebral vasospasm or delayed ischemic neurologic deficit causes high rate of morbidity and mortality, although established strategies are present<sup>3,5,7</sup>. Patients suffering severe vasospasm have a higher risk for subsequent IPH development<sup>10</sup>. Hyperdynamic therapy, also known as triple-H therapy, or anti-spastic regimen in popular use, is not without risk and requires intensive cardio-pulmonary surveillance for detecting systemic as well as intracranial complications. Hypertensive episodes following aneurysmal SAH must carry a definite risk of intracranial bleeding event and therefore, induced-hypertension should be conducted on an individual basis<sup>1,9-11</sup>. Careful hemodynamic monitoring during the ICU management is, thus of utmost importance to prevent complications and guarantee successful anti-spastic treatment.

Endovascular techniques have been advocated for the refractory cerebral vasospasm. Intra-arterial pharmaceutical injection is simple, and can be done repetitively on diffuse spasm in addition to acting on distal cerebral vessels, irrespective of drugs utilized. Although many investigators advocated immediate effectiveness and safety of nimodipine infusion, its beneficial effect is not permanent, lasting no more than 24 hours, and long-term efficacy and safety, especially combined with hyperdynamic therapy have not been thoroughly assessed<sup>3,5</sup>. In the current case, we are not sure that intra-arterial nimodipine exerted on such a delayed bleeding if we consider its short action time, although vasodilatory effect could extend to the opposite carotid artery through the anterior communicating artery.

To avoid this kind of adverse effect, angiogram of the contralateral side should be obtained when there is diffuse SAH on admission, and bedside monitoring should be performed to follow up cerebral perfusion on daily base. This strategy of consecutive monitoring is very crucial even when there is no evidence of impending ischemia or no clue of vasospasm on the opposite hemisphere, particularly in patients with sustained vasospasm.

## CONCLUSION

We suggest that local hemodynamic redistribution following injection of intra-arterial nimodipine and vigorous hyperdynamic therapy results in increased cerebral perfusion and eventual IPH in the vicinity of the impaired cerebral autoregulation, susceptible border-zone. A careful, individualized approach is mandatory to avoid such complications of combined treatment of hyperdynamic therapy and endovascular treatment against vasospasm.

## References

1. Amin-Hanjani S, Schwartz RB, Sathi S, Stieg PE : Hypertensive encephalopathy as a complication of hyperdynamic therapy for vasospasm : report of two cases. *Neurosurgery* 44 : 1113-1116, 1999
2. Brisman MH, Bederson JB, Sen CN, Germano IM, Moore F, Post KD : Intracerebral hemorrhage occurring remote from the craniotomy site. *Neurosurgery* 39 : 1114-1121, 1996
3. Firat MM, Gelebek V, Orer HS, Belen D, Firat AK, Balkanci F : Selective intraarterial nimodipine treatment in an experimental subarachnoid hemorrhage model. *AJNR Am J Neuroradiol* 26 : 1357-1362, 2005
4. Honegger J, Zentner J, Spreer J, Carmona H, Schulze-Bonhage A : Cerebellar hemorrhage arising postoperatively as a complication of supratentorial surgery : a retrospective study. *J Neurosurg* 96 : 248-254, 2002
5. Hui C, Lau KP : Efficacy of intra-arterial nimodipine in the treatment of cerebral vasospasm complicating subarachnoid haemorrhage. *Clin Radiol* 60 : 1030-1036, 2005
6. Jang JW, Joo SP, Kim JH, Kim SH : Remote cerebellar hemorrhage after supratentorial aneurysmal surgery. Report of six cases. *J Korean Neurosurg Soc* 39 : 370-377, 2006
7. Janjua N, Mayer SA : Cerebral vasospasm after subarachnoid hemorrhage. *Curr Opin Crit Care* 9 : 113-119, 2003
8. Kalfas IH, Little JR : Postoperative hemorrhage : a survey of 4992 intracranial procedures. *Neurosurgery* 23 : 343-347, 1998
9. Rutherford SA, Jallul T, Holland JP : Remote hypertensive intracranial haematoma following clipping of an intracranial aneurysm. *Br J Neurosurg* 17 : 74-77, 2003
10. Sakaki T, Tsunoda S, Morimoto T, Hoshida T, Hashimoto H, Konishi N, et al : Spontaneous intracerebral hemorrhage in cases of severe angiospasm following ruptured aneurysm-a pathological study. *Neurol Med Chir (Tokyo)* 31 : 498-502, 1991
11. Shimoda M, Oda S, Tsugane R, Sato O : Intracranial complications of hypervolemic therapy in patients with a delayed ischemic deficit attributed to vasospasm. *J Neurosurg* 78 : 423-429, 1993