

Technical Note

Ealmaan Kim, M.D., Ph.D.¹Sung-II Nam, M.D., Ph.D.²

Staging in Vestibular Schwannoma Surgery : A Modified Technique

The authors herein propose the staged excision as a novel strategy to preserve facial nerve and minimize complication during microsurgery of large vestibular schwannoma (VS). At the first stage, for reducing mass effect on the brain stem and cerebellum, subtotal tumor resection was performed via a retrosigmoid craniotomy without intervention of meatal portion of tumor. With total resection of the remaining tumor, the facial nerve was decompressed and delineated during the second stage translabyrinthine approach at a later date. A 38-year-old female who underwent the staging operation for resection of her huge VS is illustrated.

KEY WORDS : Vestibular schwannoma · Surgical approach · Operative technique · Two-stage excision · Facial nerve · Outcome.

Skull Base Division
Departments of Neurosurgery¹
Otorhinolaryngology²
Dongsan Medical Center
Keimyung University
School of Medicine
Daegu, Korea

INTRODUCTION

The optimal approach for vestibular schwannoma (VS) surgery depends on the tumor size and exact location, the patient's age and hearing, and skill of the surgeon. For all patients with large VSs, especially those causing brain stem and cerebellum compression with significant symptoms, microsurgery is the treatment of choice³⁾. However, surgical removal of large VSs has been associated with higher complication rates, poor facial nerve function, and high tumor recurrence rate^{16,17)}. With prime goal of reducing the risk to brain and facial nerve, we performed the first stage through a retrosigmoid craniotomy whereas the second stage was via a translabyrinthine approach to allow for virgin dissection planes. Technical details and advantages of the staged surgical resection of larger VS will be stressed on this report.

CASE REPORT

This patient was a 36-year-old woman who presented with a progressive headache, difficulty in balancing, and hearing loss. Her face was symmetric on both resting and expression. Magnetic resonance (MR) imaging revealed an enhancing 5 cm-sized vestibular tumor that had markedly displaced the brain stem. The tumor also occupied lateral internal auditory canal (IAC) (Fig. 1A). The majority of the tumor was carefully debulked during a first stage of suboccipital craniectomy under active facial nerve stimulation. There was a portion of the tumor that was very adherent to the facial nerve more laterally towards the IAC. The facial function was a House-Brackmann (H-B) grade 4 after the suboccipital surgery. MR taken after a staging interval of 4 weeks demonstrated the residual tumor in the IAC and normalization of the brain stem and cerebellum. She subsequently underwent total tumor resection via a translabyrinthine route with new dissection planes. The tumor was found to be soft and relatively avascular, and the facial nerve was preserved anatomically. The patient had an uneventful recovery and showed a H-B grade 2 facial function at the most recent clinic visit. One year after the last operation, follow-up MRI showed no residual tumor (Fig. 1E).

SURGICAL TECHNIQUE

During the stage I retrosigmoid resection, the tumor was decompressed medially and internally, but the IAC was left intact and the tumor around porus acousticus was not touched (Fig. 1B). The patient was put under three-quarters prone position with left side up and then the facial nerve electrodes were placed on the lesion side of the face. The laryngeal nerve was monitored

• Received : October 29, 2007
• Accepted : January 2, 2008
• Address for reprints :
Ealmaan Kim, M.D., Ph.D.
Skull Base Division
Department of Neurosurgery
Dongsan Medical Center
Keimyung University
School of Medicine
194 Dongsan-dong, Jung-gu,
Daegu 700-712, Korea
Tel : +82-53-250-7823
Fax : +82-53-250-7356
E-mail : bach1158@dsmc.or.kr

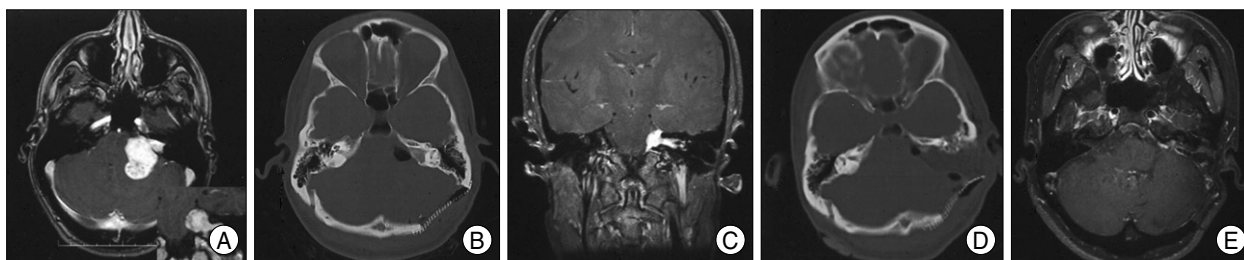


Fig. 1. A patient with large vestibular schwannoma who underwent a staged retrosigmoid-translabyrinthine approaches with one month interval between operations. An enhanced magnetic resonance (MR) image reveals a tumor deeply embedded into the brain stem and cerebellum. The lateral portion of tumor is also prominent (inset) (A). The bony defect of the left occipital region is noted on computed tomography (CT) scan after stage-one procedure. The internal auditory meatus is widened, but not drilled (B). The coronal MRI before stage-two resection shows a lateral remnant of the tumor (C). The bone window CT reveals resection of the mastoid and bony labyrinth through the second stage approach (D). The MR obtained at one year after the surgery demonstrates no evidence of residual tumor (E).

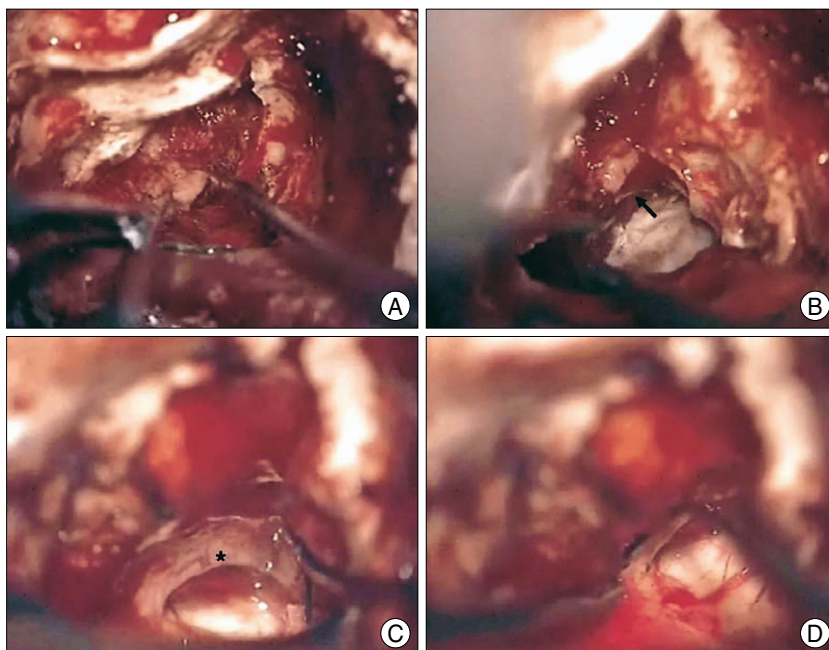


Fig. 2. Operative photographs showing the translabyrinthine resection of the tumor of the staged vestibular schwannoma surgery. The lateral remaining tumor is removed and the silastic sheet (arrow) placed during the suboccipital approach is freed from the brain stem (A, B). At the end of operation, the facial nerve (asterisk) is dissected completely and it is intact grossly from the root entry zone to the lateral end (C, D).

intraoperatively using an electrode embedded in the endotracheal tube. A curvilinear scalp incision was made around the auricle in the usual manner. A 4-cm suboccipital craniectomy and additional posterior mastoidectomy was then performed using high-speed drill. The transverse and sigmoid sinuses were markedly decompressed to gain maximal anterior exposure. The dura was opened and the large tumor was easily seen. By utilizing a surgical suction irrigation, the medial and internal portion of the tumor was then debulked with caution to preservation of vascular and neural structures. The tumor began to collapse on itself. As occurred happened, the facial nerve was identified and appeared to be in the superior and anterior portion of the tumor. The lower cranial nerves were identified and protected with cotton paddies. The fifth cranial nerve was also separated from the tumor. After dissecting the

tumor off the brain stem, the facial nerve root entry zone was noted, then the facial nerve was followed up towards the IAC. We continued to take out the tumor until there was had only the intrameatal portion of the tumor. At this point, the facial nerve appeared healthy, but it was quite twisted at the point as it curved into the IAC. Approximately 90% of the tumor was removed through this approach. The remaining tumor was the portion adherent to the facial nerve as well as more laterally towards the IAC. At the conclusion of the dissection, a gelfoam sponge and silastic sheet was placed within the cerebellopontine angle (CPA) to maintain dissection planes and protect the underlying structures at reentry during the second stage. The dura was reapproximated in a watertight fashion. Exposed air cells were then waxed, and a titanium mesh was placed

over the cranial defect.

After the suboccipital surgery, the brain stem and cerebellum appeared normally and some residual tumor was confirmed on the repeat MR scanning (Fig. 1C). One month later, with tumor left in the IAC and around the meatus, we performed the second operation utilizing the translabyrinthine approach through virgin planes of dissection (Fig. 1D). A lumbar drain was placed and the facial nerve electrodes were placed. The previous circular incision was reopened and the mesh was removed. We then began drilling the bone just anterior to the sigmoid sinus. An extradural bony work involving mastoidectomy and labyrinthectomy was done by an otologist. The bone along the widened IAC was drilled and then curetted away to fully expose the IAC dura. With identifying the Bill's bar, the vestibular nerve was seen to be

avulsed. The intrameatal tumor was easily identified and separated from the facial nerve most distally (Fig. 2A). Lumbar drain was opened at this time, and the brain was quite relaxed. The dura was then opened around the Trautmann's triangle exposing the CPA. A piece of silastic sheet placed during the first stage was identified and removed (Fig. 2B). Utilizing the stimulator, we have estimated the facial nerve and found its continuity. It was still adhered just at the meatus. The residual tumor around the porus was remarkable with its discoloration and less vascularity. We then continued to operate carefully with microdissection techniques to resect the tumor and its fragments from medial to lateral and lateral to medial. Following this, the entire residual tumor was removed with intact facial nerve, and it was stimulated at 0.1 mA (Fig. 2C, D). The middle ear space and the Eustachian orifice were then occluded with muscle. Abdominal fat graft was placed within the defect to prevent cerebrospinal fluid leaks. Cranioplasty using a mesh and bone cement was done.

DISCUSSION

For the VS patients of large and giant tumors compressing the brain stem, the only treatment is surgical removal by the expert. The main aim of surgery for larger VSs is the radical tumor removal with conservation of the facial nerve function without additional morbidity or mortality. These objects can be obtained by choosing the proper individualized approach and performing the tumor resection by an experienced multi-disciplinary surgical team⁵. Occasionally, however, in some cases of large VSs in which safe total resection may be not possible, the tumor is resected near totally or subtotally. Those patients undergoing nontotal resection are closely followed with serial MR scans to detect further growing of the tumor remnant. More practically, small recurrences usually could be controlled by stereotactic radiosurgery, and the outcomes are very good¹⁰.

In order to expose and resect large and giant VSs, neurosurgeons and neuro-otologists have to familiarize themselves with different approaches and use the approach that allows them to achieve the best results. With an exceptional VS cases treated by combined petrosal approach, the suboccipital retrosigmoid transmeatal and enlarged translabyrinthine approaches are mainly being used for removal of large VSs^{6,8,11}. However, because of its adherence to the brain stem, cerebellum, and cranial nerves, regardless of approaches, surgery of large VSs is associated with higher rate of neural-vascular morbidity and risk of residual tumor with incomplete resection^{2,6}. On outcome review of VS surgery, an excellent facial nerve function has been reported in only 50% of patients with large VSs³. Secondarily, the completeness of

tumor removal is the ideal goal in surgery of a large VSs as shown in this case. A near total resection in which remnant within the IAC or adhering to facial nerve or brain stem would be an optional strategy in surgical resection of large VSs¹⁴. However, subtotal tumor removal with large residuals should be avoided due to high regrowth rates and requiring unplanned revision surgery with increased morbidity and mortality^{4,8,13}. Recently, it has been reported that the major neurological and surgical complications can occur in up to 20% of patients with large vestibular tumors^{7,9}.

These above-mentioned topics such as, complete tumor resection, preservation of facial nerve, and minimal surgical morbidity, are major practical issues in the microsurgery of large VSs. A staged surgery using translabyrinthine-translabyrinthine, retrosigmoid-translabyrinthine and retrosigmoid-retrosigmoid approaches enjoys acceptance in the literature as the procedure of choice in dealing with large or giant VSs^{1,3,12,15}. Although it has not been defined definitely, interval between operations less than 1 month appear to be a reasonable time to allow patient recovery while minimizing scar formation as in our case. We used a staged combined microsurgery by using the standard retrosigmoid and translabyrinthine fractions and all procedures for this technique were performed in collaboration with an experienced otologist. The key technical modification in the first operation of our planned staged surgery was not drilling of IAC to minimize scar tissue formation at the porous acousticus. Data from prior reports did not favor one approach over another, but our staged technique has some merits of two conventional approaches to VSs. First, with a panoramic view of the posterior fossa, retrosigmoid tumor resection in staging for large VS surgery has an advantage of medial tumor debulking and decompression of the cerebellar hemisphere and lateral brain stem. Second, it is much more realistic that the second stage for lateral tumor removal could be done through a fresh surgical plane. The lateral facial nerve and remaining tumor inaccessible with retrosigmoid route is readily identified at the meatal foramen. With an intrameatal facial nerve decompression, the likelihood and severity of delayed facial palsy can be more reduced. Third, with re-expansion of the previously compressed brain stem and cerebellum, the residual tumor attached to the brain stem moved toward the CPA over the time of staging. In general, because this smaller remaining tumor is less vascular and no longer densely adherent to the brain stem and the facial nerve, it can be safely removed with identification of the facial nerve root entry zone. If the residual tumor is not excised completely, near total resection may be a good option. Fourth, it is more important that the facial nerve is less splayed and more resistant to stretch injury during the second stage. The injured facial nerve could be

also repaired using graft during the second visit. Fifth, it is another merit of the staging surgery that the long and tedious procedure can be converted into two shorter operations that are easier for both the patient and surgeon. With reduced surgeons' fatigue and stress, the productivity of the surgical team during the critical stages of the procedure is increased much better. Sixth, by the radical tumor resection with no remnants, the necessity of revision surgery or radiosurgery can be eradicated. However, from a practical standpoint, despite the potential benefits of staged treatment, there are drawbacks to this approach, such as two separate hospitalizations, additional costs, and possible surgical morbidity with multiple operations.

When a patient presents with a large VS, the surgeon and patient may decide in advance that a staged operation will be likely and be safer. It is also informed that the amount of tumor removed during the first stage is depend on tumor characteristics and ease of dissection from the adjacent neurovascular structures. A staged surgery could be recommended for the following situations. The patients with VS that is highly vascular, dense and fibrous, and extensively engulfing into the brain stem are candidate for a staged resection^{1,3)}. During the suboccipital stage, the unexpected events like as cerebellar swelling or vital sign changes are noted, a decision to stage the operation can also be made^{15,17)}. The facial nerve status which is risky to its preservation; thinning out, twisting around the IAC, drape over the tumor, unstability on monitoring, or preoperative facial weakness is the main reason for staged resection of VSs¹²⁾.

CONCLUSION

A staging operation, stage I via a suboccipital craniotomy and stage II via a translabyrinthine approach, was performed for resection of large VSs in a young patient. With this modified surgical technic for large or giant VSs, an otoneurosurgical team can give the patients better chance of maintaining normal facial function and minimizing the tumor recurrence with complete resection.

References

1. Abe Takumi, Izumiyama H, Imaizumi Y, Kobayashi S, Shimazu M, Sasaki K, et al : Staged resection of large hypervascular vestibular schwannomas in young adults. *Skull Base* 11 : 199-206, 2001
2. Anderson DE, Leonetti J, Wind JJ, Cribari D, Fahey K : Resection of large vestibular schwannomas : facial nerve preservation in the context of surgical approach and patient-assessed outcome. *J Neurosurg* 102 : 643-649, 2005
3. Comey CH, Jannetta PJ, Sheptak PE, Jho HD, Burkhart LE : Staged removal of acoustic tumors : techniques and lessons learned from a series of 83 patients. *Neurosurgery* 37 : 915-921, 1995
4. El-Kashlan HK, Zeitoun H, Arts HA, Hoff JT, Telian SA : Recurrence of acoustic neuroma after incomplete resection. *Am J Otol* 21 : 389-391, 2000
5. Fayad JN, Brackmann DE : Treatment of small acoustic tumors (vestibular schwannomas). *Neurosurg Q* 15 : 127-137, 2005
6. Gormley WB, Sekhar LN, Wright DC, Kamerer D, Schessel D : Acoustic neuromas : results of current surgical management. *Neurosurgery* 41 : 50-60, 1997
7. Jung S, Kang SS, Kim TS, Kim HJ, Jeong SK, Kim SC, et al : Current surgical results of retrosigmoid approach in extralarge vestibular schwannomas. *Surg Neurol* 53 : 370-378, 2000
8. Kang JH, Hwang SK, Gwak HS, Kim DK, Jung HW : Presigmoid transpetrosal approach for recurrent acoustic neurinomas : indications and surgical results. *J Korean Neurosurg Soc* 31 : 419-423, 2002
9. Kim WH, Park CK, Kim DG, Jung HW : Management of recurrent vestibular schwannomas. *J Korean Neurosurg Soc* 39 : 87-91, 2006
10. Liu D, Xu D, Zhang Z, Zhang Y, Zheng L : Long-term outcomes after Gamma Knife surgery for vestibular schwannomas : a 10-year experience. *J Neurosurg (Suppl)* 105 : 149-153, 2006
11. Mamikoglu B, Wiet RJ, Esquivel CR : Translabyrinthine approach for the management of large and giant vestibular schwannomas. *Otol Neurotol* 23 : 224-227, 2002
12. Patni AH, Kartush JM : Staged resection of large acoustic neuromas. *Otolaryngol Head Neck Surg* 132 : 11-19, 2005
13. Ramina R, Neto MC, Bordinon KC, Mattei T, Clemente R, Aguiar PHP : Treatment of large and giant residual and recurrent vestibular schwannomas. *Skull Base* 17 : 109-117, 2007
14. Seol HJ, Kim CH, Park CK, Kim CH, Kim DG, Chung YS, et al : Optimal extent of resection in vestibular schwannoma surgery : relationship to recurrence and facial nerve preservation. *Neurol Med Chir (Tokyo)* 46 : 176-181, 2006
15. Sheptak PE, Jannetta PJ : The two-stage excision of huge acoustic neurinomas. *J Neurosurg* 51 : 37-41, 1979
16. Sluyter S, Graamans K, Tulleken CAF, Van Veelen CWM : Analysis of the results obtained in 120 patients with large acoustic neuromas surgically treated via the translabyrinthine-transtentorial approach. *J Neurosurg* 94 : 61-66, 2001
17. Yamakami I, Uchino Y, Koyabashi E, Yamaura A, Oka N : Removal of large acoustic neurinomas (vestibular schwannomas) by the retrosigmoid approach wit no mortality and minimal morbidity. *J Neurol Neurosurg Psychiatry* 75 : 453-458, 2004