

## Case Report

Woo-Tack Rhee, M.D.  
Seung-Hoon You, M.D.  
Suk-Kyoung Kim, R.N.  
Sang-Youl Lee, M.D.

Department of Neurosurgery  
Gangneung Asan Hospital  
College of Medicine  
Ulsan University  
Gangneung, Korea

## Troublesome Occipital Neuralgia Developed by C1-C2 Harms Construct

Recently, Harms and Melcher modified Goel's approach, the C1 lateral mass and C2 pedicle screw fixation, and the new technique is currently in favor among neurosurgeons. Comparing to the advantages of Harms construct, the disadvantages were not extensively investigated. We experienced a patient with severe occipital pain developed after the C1 lateral mass screw placement for the traumatic atlantoaxial instability. We reviewed literatures about Harms construct with focus on the occipital neuralgia as a postoperative complication and suggest here technical tips to avoid the troublesome pain.

**KEY WORDS :** Occipital neuralgia · Lateral mass screw · Atlantoaxial instability.

### INTRODUCTION

Various techniques have been described for stabilization of the C1-C2 joint in the patients with atlantoaxial instability<sup>3,5,6,8</sup>. Recently, Harms modified Goel's technique, the C1 lateral mass (C1LM) and C2 pedicle (C2P) screw fixation, using polyaxial screw and rod system<sup>8</sup>.

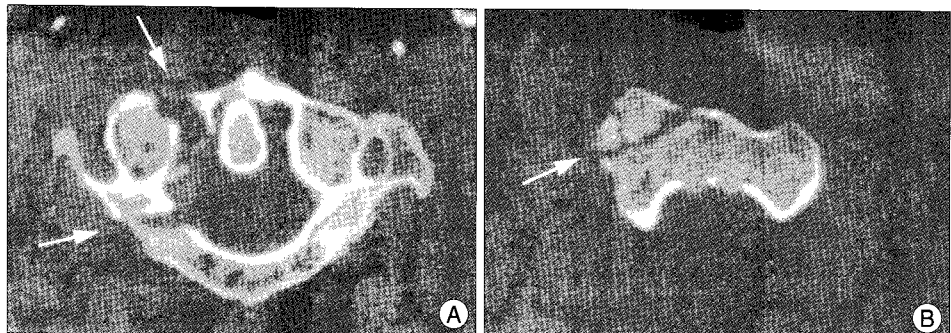
According to the pioneers of the technique, advantages include lower risk of injury to the vertebral artery and intraoperative reduction of the atlantoaxial complex in comparison with transarticular screw fixation<sup>8</sup>. To date, however the disadvantages of the new approach were not extensively investigated.

We experienced a patient with severe and long-standing occipital pain ipsilaterally developed after unilateral Harms surgery for the traumatic atlantoaxial instability.

We carefully reviewed our operation itself as well as the literatures with focus on the occipital neuralgia as a complication of the Harms construct. We felt that the postoperative occipital neuralgia should be considered as a troublesome complication induced by placing a screw in the first cervical foraminal area. We suggest several points implicated in the complication.

### CASE REPORT

A 56-year-old coal miner was brought to the emergency room with severe neck pain. His head was hit by a cross bar of the roof while driving down the tunnel. Except a contusive wound on his forehead, he was stable physically and neurologically. Computed tomography (CT) demonstrated fractures of anterior and posterior arches of the right side of C1 (Fig. 1A) and base fracture of the odontoid process extending to the right lateral mass and right transverse foramen of C2 (Fig. 1B). Therefore, the right side of C1-C2 complex was not suitable for



**Fig. 1.** Preoperative computed tomography. A : Fractures of unilateral anterior and posterior arches on the right side of the atlas (arrows). B : Fractures of odontoid base extending to the right lateral mass (arrow).

- Received : November 5, 2007
- Accepted : January 16, 2008
- Address for reprints :  
Woo-Tack Rhee, M.D.  
Department of Neurosurgery  
Gangneung Asan Hospital  
College of Medicine  
Ulsan University, 415 Bangdong-ri  
Sacheon-myeon, Gangneung  
210-711, Korea  
Tel : +82-33-610-3259  
Fax : +82-33-641-8070  
E-mail : seasons@gnah.co.kr

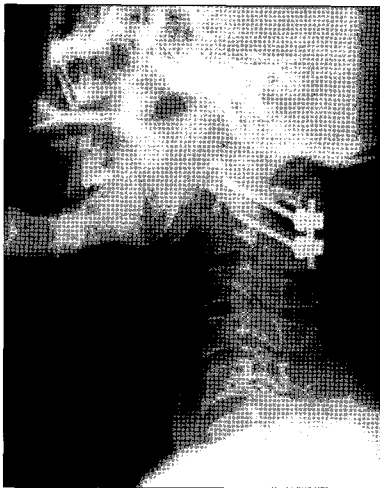

Fig. 2. Postoperative lateral radiograph.

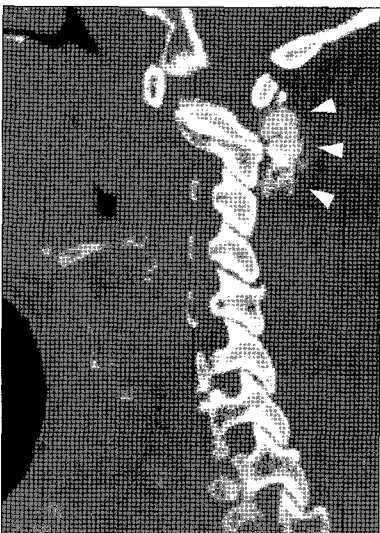


Fig. 3. Postoperative 3D-computed tomography six months after surgery. Arrow heads mark bone fusion mass over the C1-C2.

screw purchase. We planned the C1-C2 stabilization with C1LM-C2P screw fixation on the left side because Harms construct was thought to be stronger than transarticular screw for the unilateral fixation.

Midline incision was made at the level of C1-C3. Muscle dissection was done subperiosteally on the left side. Venous complex over the C2 nerve was coagulated by electrocauterization and distal portion of the nerve was carefully dissected from surrounding muscles. The bleeding venous complex around the C1-C2 facet joint was controlled with bipolar cautery and compression with absorbable hemostats. After identification of medial and

lateral borders of the C1 lateral mass, 4.0 mm-diametered, 32 mm-long entirely threaded screw (Vertex, Medtronic Sofamor Danek, TN, USA) was inserted into the C1 lateral mass medially 10° and superiorly toward anterior tubercle under the fluoroscopic guidance. A 3.5 mm-diametered, 26 mm-long threaded screw was inserted 20° medially under the direct inspection of C2 pedicle and superiorly under the fluoroscopic guidance (Fig. 2). The C2 nerve was distorted by the C1 LM screw when we released the nerve, therefore more dissection of the nerve from the muscle was done to release further.

Postero-inferior aspect of C1 posterior arch and C2 lateral mass were decorticated with a pneumatic drill. The iliac bone was harvested and applied on the fusion bed. The wound was massively irrigated and closed.

A few days after the operation, the patient stated that he

had severe dull pain on the left occipital area. He also had paroxysmal pain extending to the forehead only on the left side. He told "I did not recognized the pain because of wound pain. I thought it was wound pain. However now, surgical wound pain much subsided but this pain is going on".

We tried a greater occipital nerve block and he had partial improvement of the pain. He discharged with carbamazepine prescription. However, the occipital dull pain extending to the forehead was his chief complaint on the regular follow-up visits. He did not felt comfortable by the block of the greater occipital nerve and medications any more. Six months after the operation, we recommended removal of the screw since follow-up CT scan had demonstrated solid bone fusion (Fig. 3). He refused operation and underwent C2 ganglion blocks a few times by pain clinician under the fluoroscopic guidance. Twelve months later after the surgery, he was still with the pain but felt much better. He said "It's currently tolerable".

## DISCUSSION

A myriad techniques for atlantoaxial fixation have been described due to the unique anatomy of C1-C2 complex<sup>3,5,6,8</sup>. Grob and Magerl<sup>6</sup> introduced the atlantoaxial transarticular screw fixation technique and demonstrated acceptable fusion rates by more rigid fixation than posterior wiring techniques in 1987. Recently, Goel and Laheri<sup>5</sup> have first described a method of C1-C2 fixation using a plate-screw system for the C1LM and C2P as an alternative to transarticular screw fixation in 1994. Furthermore, Harms and Melcher<sup>8</sup> modified Goel's technique using a polyaxial screw-rod construct in 2001 and this approach is widely adopted by many surgeons<sup>7-9,11</sup>.

C1LM-C2P fixation has advantages over the transarticular screw fixation technique. First of all, individual placement of screws in C1 and C2 allows intraoperative reduction of C1-C2 subluxation<sup>8,9</sup>. Harms construct also has biomechanically superior or at least equivalent stability in comparison with transarticular screw fixation on the all dimensions of motion<sup>4,10,13</sup>. C2 pedicle screw insertion has the lower risk of vertebral artery injury than transarticular screw placement<sup>7,8</sup>. Additionally, C1LM-C2P screw fixation requires smaller incision than transarticular screw fixation due to more vertical trajectory to the axis.

Regarding the complications of the approach, however, seldom has been reported. One of questions about C1LM screw placement is the possibility of C2 neuralgia development<sup>7,8</sup>. To our knowledge, the only case of severe C2 neuralgia was reported by Gunnarsson et al.<sup>7</sup> recently. They performed the surgery for twenty-five patients and three of

their patients developed C2 neuralgia. One patient suffered from significant bilateral C2 neuralgia and two other patients were mild<sup>7</sup>.

Harms, a pioneer of the approach, admitted that placing a screw into the C1 lateral mass can cause irritation of the C2 ganglion, even though there was no instances of occipital neuralgia in his thirty-seven patients<sup>8</sup>. He guessed that the space remaining around the C2 root after screw placement may be sufficient. In addition, he suggested that their C1 screw with the unthreaded upper portion might be useful to avoid potential neural irritation from screw threads<sup>8</sup>. Then, Gunnarsson et al.<sup>7</sup> also used partially threaded screw with a smooth shank to minimize irritation to the C2 nerve, however, they could not avoid the trouble-some complication.

Generally speaking, surgery is possible by retracting the nerve caudally while placing the screw to expose the entry point for the C1 screw. Normally, the C2 ganglion is left between the C1 screw superiorly and C2 lamina inferiorly. Not uncommonly, the height of the first cervical foraminal area is not enough to place the C1LM screw without significantly distorting the C2 nerve.

According to the literatures, the C2 ganglion lies in the intervertebral space, which is bordered superiorly by the posterior arch of the atlas, inferiorly by the lamina of the axis, anteriorly by the atlantoaxial joint and its posterior capsule and posteriorly the posteromedial corner between the arch of the atlas and the lamina of the axis<sup>1,2,12</sup>. The shape of ganglion was defined in three types : 70% were oval, 20% were spindle-like, and 10% were spherical<sup>1</sup>. According to Lu and colleague's cadaveric study, the heights of the C2 ganglion is  $5.7 \pm 0.8$  mm and the heights of the foramen is  $7.7 \pm 1.2$  mm. The ratio of the height of the C2 foramen to the height of the C2 ganglion is 1 : 0.76. The C2 ganglion occupies from 50% to 76% of the foramen in height<sup>1,12</sup>. If we use 4.0 mm-diametered screw, it will take the half of the foraminal height.

In addition, the width and height of the first intervertebral space alter with the position of C1 and C2. As the head hyperextends, the height of this space between the posterior arch of the atlas and the lamina of axis reaches its minimum because the height of the intervertebral space is reduced up to 23%<sup>1</sup>.

Even though our experiences of Harms construct are very limited, we speculate that simple contact of the screw with the nerve may be safe from the C2 neuralgia. Although contact of the screw with the nerve is virtually inevitable, only a proportion of the patients seem to have the C2 neuralgia<sup>7,8</sup>.

We summarize several tips to avoid C2 neuralgia through our experiences and review of the literatures. First, avoid hyperextension of the neck. Normally, C2 ganglion occupies

76% of the foramen in height<sup>12</sup> and hyperextension will reduce the foraminal height. Second, place the head of the C1 screw sufficiently dorsally not to take much space in the foraminal area for the C2 ganglion as well as to allow easy rod connection to the C2 screw head<sup>7,8</sup>. Third, if available, use partially threaded C1 screws with a smooth shank to minimize irritation to the C2 nerve<sup>7,8</sup>. Fourth, if the C2 nerve looks tense around C1 screw, additional mobilization of the C2 nerve root from surrounding tissue should be done<sup>7</sup>. Fifth, if all the above methods are not enough, use a higher entry point and insert the screw into the arch of C1 if it can accommodate the screw<sup>7</sup>. Finally, carefully place the fusion materials like bone chips on the decorticated C1-C2 posterior arches.

## CONCLUSION

While performing the C1-C2 fixation with Harms construct, surgeons should be aware of the development of occipital neuralgia. If the pain is severe and not satisfactorily responsive to the medications, the best treatment seems repetitive C2 ganglion blocks. Extensive investigation of this complication from Harms construct is warranted.

## References

1. Bilge O : An anatomic and morphometric study of C2 nerve root ganglion and its corresponding foramen. *Spine* 29 : 495-499, 2004
2. Bogduk N : An anatomical basis for the neck-tongue syndrome. *J Neurol Neurosurg Psychiatry* 44 : 202-208, 1981
3. Brooks AL, Jenkins EB : Atlanto-axial arthrodesis by the wedge compression method. *J Bone Joint Surg Am* 60 : 279-284, 1978
4. Claybrooks R, Kayanja M, Milks R, Benzel E : Atlantoaxial fusion : a biomechanical analysis of two C1-C2 fusion techniques. *Spine J* : 682-688, 2007
5. Goel A, Laheri V : Plate and screw fixation for atlanto-axial subluxation. *Acta Neurochir (Wien)* 129 : 47-53, 1994
6. Grob D, Magerl F : Surgical stabilization of C1 and C2 fractures. *Orthopade* 16 : 46-54, 1987
7. Gunnarsson T, Massicotte EM, Govender PV, Raja Rampersaud Y, Fehlings MG : The use of C1 lateral mass screws in complex cervical spine surgery : indications, techniques, and outcome in a prospective consecutive series of 25 cases. *J Spinal Disord Tech* 20 : 308-316, 2007
8. Harms J, Melcher RP : Posterior C1-C2 fusion with polyaxial screw and rod fixation. *Spine* 26 : 2467-2471, 2001
9. Kim YS, Lee JK, Kim JH, Kim SH : Post-traumatic atlantoaxial rotatory dislocation in an adult treated by open reduction and C1-C2 transpedicular screw fixation. *J Korean Neurosurg Soc* 41 : 248-251, 2007
10. Kuroki H, Rengachary SS, Goel VK, Holekamp SA, Pitkanen V, Ebraheim NA : Biomechanical comparison of two stabilization techniques of the atlantoaxial joints : transarticular screw fixation versus screw and rod fixation. *Neurosurgery* 56 : 151-159, 2005
11. Lee DY, Chung CK, Jahng TA : Atlantoaxial fixation using rod and screw for bilateral high-riding vertebral artery. *J Korean Neurosurg Soc* 37 : 380-382, 2005
12. Lu J, Ebraheim NA : Anatomic considerations of C2 nerve root ganglion. *Spine* 23 : 649-652, 1998
13. Melcher RP, Puttlitz CM, Kleinstueck FS, Lotz JC, Harms J, Bradford DS : Biomechanical testing of posterior atlantoaxial fixation techniques. *Spine* 27 : 2435-2440, 2002